

Cardiac amyloidosis: Recent advances in the diagnosis and therapy

Kardiyak amiloidoz: Tanı ve tedavide yenilikler

Yüksel Çavuşoğlu, M.D.,¹ Ebru Özpelit, M.D.,² Ahmet Çelik, M.D.,³ Barış İkitimur, M.D.,⁴

Meral Kayıkçoğlu, M.D.,⁵ Lale Tokgözoğlu, M.D.,⁶ Omaç Tüfekçioğlu, M.D.,⁷ Mehmet Birhan Yılmaz, M.D.²

¹Department of Cardiology, Eskişehir Osmangazi University Faculty of Medicine, Eskişehir, Turkey

²Department of Cardiology, Dokuz Eylül University Faculty of Medicine, İzmir, Turkey

³Department of Cardiology, Mersin University Faculty of Medicine, Mersin, Turkey

⁴Department of Cardiology, İstanbul University Cerrahpaşa Faculty of Medicine, İstanbul, Turkey

⁵Department of Cardiology, Ege University Faculty of Medicine, İzmir, Turkey

⁶Department of Cardiology, Hacettepe University Faculty of Medicine, Ankara, Turkey

⁷Department of Cardiology, Türkiye Yüksek İhtisas Hospital, Ankara, Turkey

ABSTRACT

Cardiac amyloidosis is a progressive cardiomyopathy in which misfolded endogenous proteins form amyloid fibrils that deposit in the heart as well as kidneys, liver, gastrointestinal tract and soft tissues. The most common forms of cardiac amyloidosis include immunoglobulin light chain (AL) amyloidosis and transthyretin (TTR) amyloidosis. Although cardiac amyloidosis is thought to be a very rare disease, emerging data suggested that 13% of heart failure patients with preserved ejection fraction and 16–26% of advanced aged patients with severe aortic stenosis may have TTR-cardiac amyloidosis. Amyloidosis with cardiac involvement shows poor prognosis with a median survival of 6 months in AL-cardiac amyloidosis and 26–43 months in TTR-cardiac amyloidosis. Early diagnosis and novel therapeutic options have been shown to significantly improve prognosis. Recent diagnostic techniques such as cardiac MR or nuclear scintigraphy using bone isotopes as well as increasingly wide use of echocardiography, genetic testing, biopsy and histopathological analysis allow the clinicians to make early diagnosis of cardiac amyloidosis. The aim of this paper is to provide a comprehensive review including etiology, clinical presentation, diagnosis and management of cardiac amyloidosis and to address recent important advances in noninvasive cardiac imaging techniques and novel therapeutic approaches based on the available data in the literature.

Keywords: Cardiac amyloidosis; diagnosis; treatment.

ÖZET

Kardiyak amiloidoz (KA), katlanması bozulan endojen proteinlerin amiloid fibrilleri şeklinde kalpte ve çoğunlukla beraberinde böbrek, karaciğer, gastrointestinal sistem ve yumuşak dokuda birikmesi sonucu ortaya çıkan ilerleyici bir kardiyomyopati olarak kabul edilir. En sık gözlenen KA formları, immunoglobulin hafif zincir (AL) amiloidozu ve transtretin (TTR) amiloidozudur. Bugüne kadar KA oldukça nadir görülen bir hastalık olarak düşünülmüş olsa da çok yeni veriler korunmuş ejeksiyon fraksiyonlu kalp yetersizliği olgularının %13 ve yüksek riske sahip ciddi aort darlığı bulunan yaşlı olguların %16–26'sında TTR-KA bulunduğunu göstermektedir. Kardiyak tutulumun bulunduğu amiloidozda prognoz kötü olup AL KA'da ortalama survi 6 ay ve TTR-KA'da ortalama survi 26–43 ay bildirilmektedir. Erken tanı ve tedavi yaklaşımları ile prognozun anlamlı düzeltilebildiği gösterilmiştir. Kardiyak MR ve nükleer kemik sintigrafisi gibi yeni tanısal teknikler ile beraber gittikçe kullanımı yaygınlaşan ekokardiyografi, genetik analiz, biopsi ve histopatolojik testler klinisyene KA'nın erken tanı olanağını vermektedir. Bu belge, KA etiyojisi, klinik bulguları, tanı ve yönetimine ilişkin kapsamlı bir değerlendirme ile beraber noninvaziv kardiyak görüntüleme ve yeni tedavi yaklaşımlarıyla ilgili önemli gelişmeleri mevcut verilere dayanarak ele almaktadır.

Anahtar sözcükler: Kardiyak amiloidoz; tanı; tedavi.

Correspondence: Dr. Yüksel Çavuşoğlu. Department of Cardiology, Eskişehir Osmangazi University Faculty of Medicine, 26480 Eskişehir, Turkey.

Tel: +90 222 - 239 29 79 e-mail: yukselc@ogu.edu.tr

© 2019 Turkish Society of Cardiology



1.0 INTRODUCTION – Yüksel Çavuşoğlu

Diagnostic awareness of cardiac amyloidosis is gradually increasing. However, cardiac amyloidosis is often missed or overlooked in everyday clinical practice. As infiltrative myocardial hypertrophy occurs in the clinical course of the disease, occasionally cardiac amyloidosis may be confused with hypertrophic cardiomyopathy or hypertensive left ventricular hypertrophy. Also, diagnostic challenges and limited treatment options specific to amyloid are major barriers for clinicians in diagnosing cardiac amyloidosis.

To date clinicians have remained distant to diagnose amyloid as endomyocardial biopsies or other organ biopsies used to make a definitive diagnosis are invasive and risky procedures, experienced pathologists are needed for histopathological assessments, and genetic analyses are not widely available diagnostic modalities and most importantly, simple and highly accurate methods are lacking. Furthermore, even if diagnosed, lack of amyloid-specific treatments may lead clinicians to overlook the disease. In addition, even cardiac involvement alone presents diagnostic challenges due to the heterogeneity in terms of etiopathology and clinical types, while often a multidisciplinary approach involving cardiologists, nephrologists, neurologists, hematologist, radiologists, genetic and nuclear medicine specialists, and pathologists is needed to make a diagnosis.

However, the diagnosis and management of cardiac amyloidosis have become less challenging owing to recent advances in cardiac imaging technologies including MRI, echocardiography and scintigraphy as well as novel amyloid-specific treatments and organ transplantations. This paper addresses recent advances in the diagnosis and management of cardiac amyloidosis.

2.0 PATHOPHYSIOLOGY AND TYPES OF CARDIAC AMYLOIDOSIS – Lale Tokgözoğlu

Amyloidosis is characterized by aggregation of amyloid fibrils and their deposition in various organs. Under normal conditions, proteins fold to ensure maximum stability in a given environment. Genetic or epigenetic factors or environmental factors such as oxidative stress may impair protein folding, leading to formation and deposition of misfolded protein aggregates.^[1] This deposition and toxic effects of precursor

proteins result in progressive organ dysfunction. Amyloid deposition may be localized in a single organ or systemic with multiple organ involvement.

As various precursor proteins may lead to systemic amyloidosis, organs affected by amyloid deposition, clinical presentation, prognosis and management may vary depending on the type of protein precursor. Amyloid fibrils may deposit in the heart, kidney, liver, gastrointestinal tract, lungs or soft tissues. Cardiac amyloidosis is the organ involvement associated with the worst prognosis in systemic amyloidosis.

To date, 28 individual precursor proteins have been shown to deposit as amyloid.^[2] Only a part of these precursor proteins may accumulate in the heart. So far, nine different proteins have been found to cause cardiac amyloidosis.^[3] Pathological processes and clinical course may vary in cardiac amyloidosis (Fig. 1). The most common form of cardiac amyloidosis may lead to progressive and infiltrative cardiomyopathy. Cardiac amyloidosis is often difficult to diagnose as it is frequently confused with hypertensive or hypertrophic heart disease. In addition to restrictive cardiomyopathy, cardiac amyloidosis may also lead to conduction disorders of the heart and ischemic heart disease. Potential accumulation of amyloid in the sinus node and in the conduction system may result in atrial arrhythmias and atrial fibrillation. Coronary artery disease and acute coronary syndromes may occur

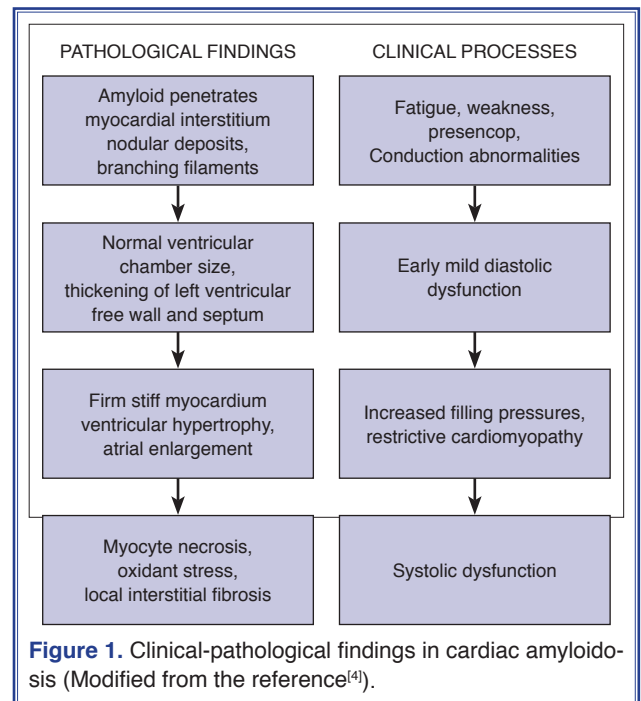


Table 1. Classification of cardiac amyloidosis types^[5]

Amyloidosis type	Precursor	Comment
Light chain or Light chain/heavy chain	Immunoglobulin light chain	Systemic plasma cell dyscrasia
Mutant transthyretin-related	TTR point mutation	Inherited autosomal dominant mutation, expressed after the fifth decade
Wild-type transthyretin-related	None	Formerly known as senile cardiac amyloidosis
Amyloid A	Serum amyloid A	Sustained inflammatory process, cardiac involvement rare
Isolated atrial amyloid	Atrial natriuretic factor	Diagnosis before death rare, features atrial fibrillation
Familial (Fab III) amyloidosis	Apo A1	Coronary artery disease

Modified from reference 5.

as a result of amyloid deposition in intramural coronary arteries. Angiographic differentiation of amyloid deposition in coronary arteries from atherosclerotic heart diseases may be very difficult. For a long-time, cardiac amyloidosis was believed to be a rare condition. However, currently it is understood that cardiac amyloidosis may be concealed in many cases of heart failure with preserved systolic function and this condition may not be as rare as it was believed.

2.1 Classification

Different protein types accumulated in the heart cause different signs and symptoms. A current classification of cardiac amyloidosis is presented in Table 1.

2.2 Light Chain (AL, primary amyloidosis) or Light/Heavy Chain Amyloidosis

Light chain amyloidosis is the most common type of amyloidosis. Although this is a plasma cell disorder, clinical manifestations of multiple myeloma do not occur in most patients. Direct toxic effects of misfolded light chains on myocytes underlie the pathogenesis. Cardiac involvement occurs in 50 to 70% of these patients. In addition, the kidney, liver and nervous system are involved in disease in ~50%, 16% and 10% of patients, respectively.^[6,7]

2.3 Mutant transthyretin amyloidosis (mTTR)

Transthyretin (TTR) is a plasma transport protein synthesized in the liver. TTR has been formerly known as prealbumin and transports the thyroid hormone and retinol in the plasma. Thermodynamic stability is impaired in the mutant protein. In this type of amyloidosis, mutated TTR fibrils induce a proinflammatory

reaction by activating NF- κ B. To date, more than 100 TTR mutations have been defined. The most common 3 mutations are Thr60Ala, Val30Met, and Val122Ile. Cardiac amyloidosis is predominant in Thr60Ala and Val122Ile mutations while neuropathy is the predominant characteristic in the Val30Met mutation (Fig. 2). Val122Ile mutation is inherited in an autosomal dominant pattern and becomes clinically manifested by the age of 8 years in homozygous patients and by the age of 60 to 70 years in heterozygous patients.^[8,9]

2.4 Wild type transthyretin amyloidosis (wtTTR amyloid)

Autopsy series reveal that the condition formerly known as senile cardiac amyloidosis is associated with transthyretin deposition in the heart. This condition rarely occurs under the age of 70 years while it is commonly found in postmortem examinations. wtTTR is more common among men and is commonly con-

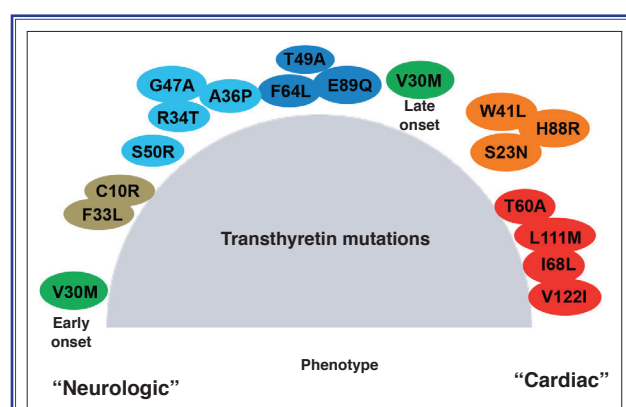


Figure 2. Transthyretin mutations with predominantly cardiac or predominantly neurologic phenotype (Modified from^[11]).

fused with hypertrophic obstructive cardiomyopathy or hypertensive hypertrophy. Carpal tunnel syndrome may occur as a manifestation of amyloid neuropathy. Recent studies have revealed that wtTTR accounts for 10% of cases of heart failure in elderly patients.^[10]

2.5 AA amyloidosis

In this amyloid type, which is also known as reactive systemic amyloidosis, serum protein amyloid A deposits in the thyroid gland, gastrointestinal tract, liver, spleen and kidney. Cardiac involvement is very rare.^[12]

2.6 Isolated atrial amyloidosis

Isolated atrial amyloidosis is characterized by the deposition of atrial natriuretic peptide subunits in the atrium. Atrial fibrillation is the most common manifestation and the condition is very rarely diagnosed before death.^[13,14]

2.7 Familial (FAP III) amyloidosis

Apoprotein A1 is the precursor protein in this rare type of amyloidosis. The deposition of this protein results in coronary artery narrowing leading to signs and symptoms of coronary artery disease.

3.0 EPIDEMIOLOGY – Yüksel Çavuşoğlu

Current epidemiological data indicate that cardiac amyloid may not be a very rare condition. In a very recent prospective study, nuclear scintigraphy scans demonstrated that wtTTR amyloid was the underlying cause in 13.3% of patients aged ≥ 60 years and hospitalized with heart failure (HF) with preserved ejection fraction (pEF) who had the left ventricular hypertrophy (≥ 12 mm).^[10] This finding suggests that cardiac amyloidosis accounts for at least one out of 10 cases of HFpEF. In another study, in 109 patients with an antemortem diagnosis of HFpEF the rate of cardiac amyloidosis was found to be 17% while the rate of cardiac amyloidosis in 131 control patients without HFpEF was found to be 5%, indicating that the incidence of wtTTR cardiac amyloidosis was 3.8 times higher among those previously diagnosed with HFpEF and these patients were more likely to develop cardiac fibrosis.^[15] Autopsy findings suggests that the incidence of amyloid deposition is 32% in people aged >75 years and 8% in people aged <75 years. In a Finish postmortem study, the rate of wtTTR cardiac amyloidosis was found to be 25% in postmortem histological examinations of myocardial tissues from people aged ≥ 85 years.^[16] TTR amyloid

deposition was found to be closely associated with the age, while the association between amyloid deposition and sex remained unclear. However a male tendency has been reported and a more severe amyloid accumulation has been observed in males. In an autopsy series of people aged >90 years who died from many reasons, cardiac amyloid was detected in 66% of males and 65% of females.^[17] However, in 2/3 of the cases, amyloid deposition was in form of atrial involvement, while ventricular involvement was detected in 22% of this population.

Although mTTR amyloid is quite rare, certain mutations have been reported to be relatively higher in certain geographic regions, society, or race.^[18] Overall prevalence of mTTR amyloid is estimated to be 1:100.000 in European countries. The prevalence of Val30Met mutation has been reported at 1:538 in Northern Portugal and 4% in Northern Sweden. However, clinical manifestations occur in 80% of cases of Val30Met mutation while this rate is 11% in Sweden and underlying cause of this difference remain unclear. The prevalence of Thr60AlaTTR mutation has been reported to be 1.1% in Northern Ireland and the prevalence of Val122Ile mutation may increase up to 3 to 4% in African-Americans. The onset of amyloid cardiomyopathy may be delayed until advanced ages and clinical manifestations of the mutation rarely occur.

As mTTR amyloidosis, AL-cardiac amyloidosis is a rare type of amyloidosis. Overall prevalence of the condition is 8 to 12 in a million. The prevalence of AL amyloidosis was estimated at 3 to 5 in a million based on Olmsted County data published in 1992.^[19] Symptomatic cardiac involvement occurs in 30 to 50% of patents with AL amyloidosis while 10 to 15% of cases of AL amyloidosis are associated with multiple myeloma. Estimated AL amyloidosis prevalence in the United Kingdom is 10 in a million based on death reports.^[20] The prevalence of AL amyloidosis was reported to be 3.2 in a million in Sweden, based on inpatients and outpatients data from medical records between 2001 and 2008.^[21]

4.0 PROGNOSIS – Yüksel Çavuşoğlu

Although overall survival rates are poor, survival is much better for TTR amyloid compared to AL amyloidosis. A study in African Americans reported that the mean survival was 27 months in patients with TTR amyloid while it was 5 months in patients with AL amyloi-

dosis.^[22] Previous studies reported an overall survival of 5 years, in patients with wtTTR amyloid^[24] However survival is worst in mTTR amyloidosis compared wtTTR amyloidosis. In the prospective, multicenter Transthyretin Amyloidosis Cardiac Study (TRACS), cardiovascular hospitalization rates and mortality rates were much higher in patients with mTTR (with Val122Ile mutation) compared to patients with wtTTR amyloidosis (64% and 28%; 73% and 22%, respectively).^[25] In this study, median survival was reported to be 43 months for patients with wtTTR amyloidosis and 26 months for patients with mTTR (with Val122Ile mutation). However, the Transthyretin Amyloid Outcome Survey (THAOS) published more recently emphasized that mortality rates were found to be associated with the severity of cardiac involvement rather than the presence of a mutation in TTR amyloidosis.^[26]

AL amyloidosis has the worst prognosis among all types of amyloidosis types. The survival time is limited by months. Prognosis is closely associated with cardiac and other organ involvements. NYHA class III or IV, severe postural hypotension, blood pressure measurements <100 mmHg, increased natriuretic peptide levels, increased cardiac troponin I or T levels are considered poor prognostic indicators.^[27] The median survival is 7 to 8 months if both NT-proBNP and troponin levels are elevated.^[28] The median survival time is estimated 3 months if NT-proBNP levels are >8500 ng/L and blood pressure measurement are <100 mmHg.^[27] The Mayo Clinical Staging System developed for AL amyloidosis is among the most reliable methods to estimate the prognosis.^[29] In this staging system, NT-proBNP levels of ≥ 1800 pg/mL, troponin-T levels of ≥ 0.025 ng/mL and differences between serum light chains (kappa and lambda) ≥ 18 mg/dL are all included in the classification of patients with AL-type amyloidosis, with each scoring 1 point.^[29] Stage III is particularly associated with poor prognosis with an estimated median survival of 3.5–4.1 months. Furthermore, alterations at NT-proBNP levels have been considered as an indicator of clinical progression and response to treatment.^[30]

5.0 CLINICAL PRESENTATION – Ahmet Çelik

5.1 History, signs and symptoms

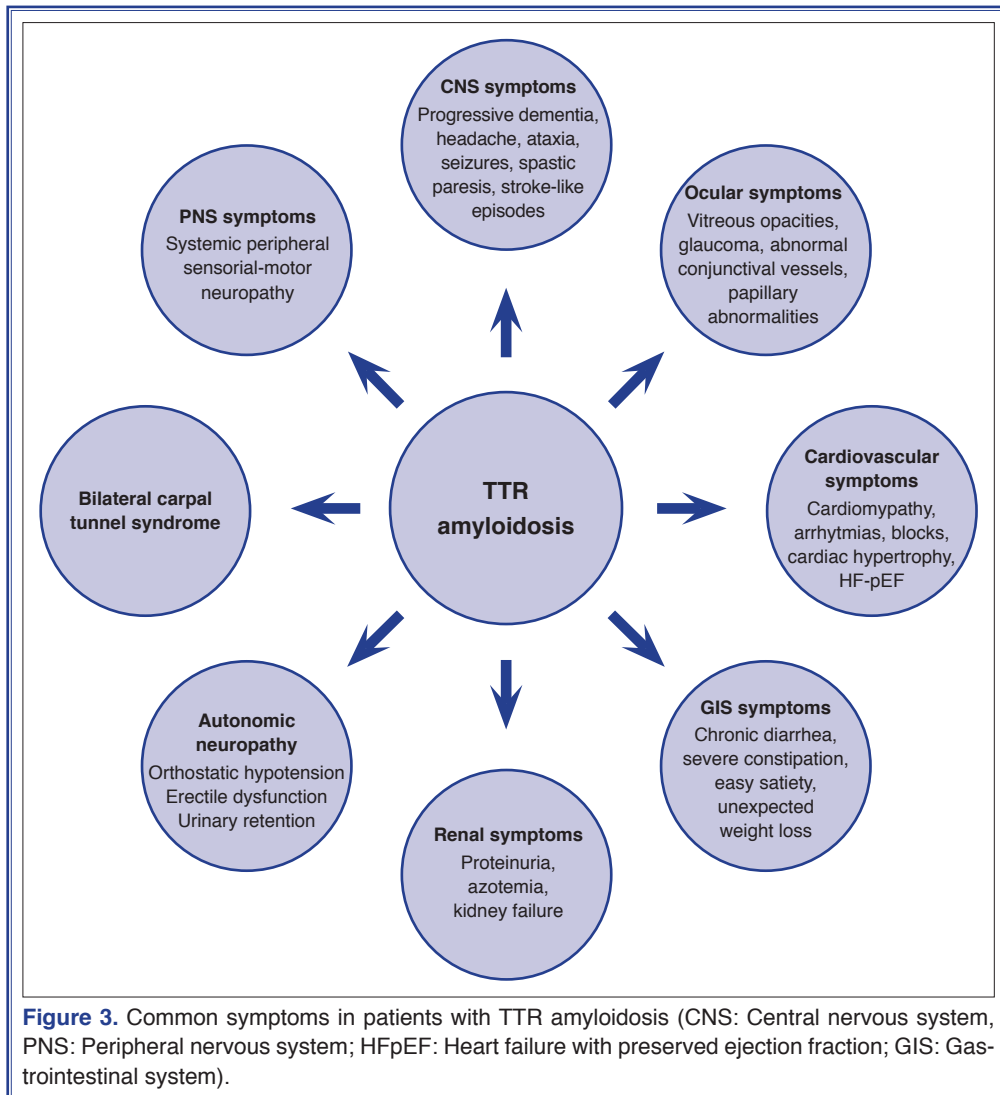
Patients with cardiac amyloidosis usually present with dyspnea and clinical symptoms of HF. Although most patients have HFpEF phenotype, some patients may present with peripheral edema, hepatomegaly

and ascites. Patients may also develop additional signs and symptoms such as fatigue, purpura, macroglossia, atypical chest pain, palpitations and systolic murmurs.^[31] 60 to 65% of patients are males and the chance of developing cardiac amyloidosis under the age of 40 is only 1%.^[32]

Presyncope and syncope may also be presenting symptoms.^[33] Fatigue and weakness may occur as a result of low cardiac output. Exercise-induced syncope may occur as a result of failure to maintain cardiac output and is associated with a high mortality rate.^[34] A number of factors contribute to the development of syncope. Particularly orthostatic hypotension associated with excessive use of diuretics and autonomic dysfunction are among important contributing factors for syncope. Ventricular arrhythmia-induced syncope are rare. Furthermore, results from several studies demonstrate that the placement of an implantable cardioverter defibrillator (ICD) may not improve the survival in patients with cardiac amyloidosis, as the main cause of sudden death in these patients is electromechanical dissociation rather than ventricular arrhythmias.^[35] Conduction system abnormalities may be seen in all forms of amyloidosis. Although mainly the sinus node is affected, based on pathological findings, major electrophysiological problems occur in the His-Purkinje system.^[36] Progressive disorders of the conduction system are rare and when such disorders occur, they may be overlooked as surface electrocardiograms may fail to reveal them in patients with AL cardiac amyloidosis.^[37] Progressive cardiac conduction disease may occur both in wtTTR amyloidosis and mTTR amyloidosis and often necessitate pacemaker implantation.

Amyloid deposition usually becomes manifest as angina, claudication and purpura by affecting smaller vessels. Microvascular angina may occur when small vessel of the heart and intramyocardial vessels are affected and coronary arteries may be normal or non-critical plaques may be reported on coronary angiography.^[38] Amyloid deposition in the pericardium may rarely lead to pericardial effusion.^[39] One should keep in mind that clinical manifestation of cardiac tamponade may occur without echocardiographic signs and symptoms of cardiac tamponade in patients with moderate to large pericardial effusion, as filling pressures are elevated.

Signs and symptoms of TTR amyloidosis are summarized in Figure 3. Signs and symptoms of cardiac



involvement were identified in 42.1% of patients in the THAOS study.^[40] Presenting symptom may be cardioembolic stroke or atrial fibrillation as often observed in patients with wtTTR, in particular. In a study in autopsy or tissue samples of 56 patients with AL amyloidosis and 61 patients with any other type of amyloidosis, patients with AL amyloidosis had an higher incidence of intracardiac thrombosis (51% vs. 16%, $p < 0.001$) and were more likely to experience fatal embolic events (26% vs. 8%, $p = 0.03$), even though they were younger than patients with other types of amyloidosis. The risk for thromboembolism was found to very high in the presence of atrial fibrillation in patients with AL amyloidosis.^[41] Anesthesia, paresthesia and pain, orthostatic hypotension, bladder dysfunction may occur both in AL amyloidosis and mTTR amyloidosis. Carpal tunnel syndrome may oc-

cur in AL, wtTTR or mTTR amyloidosis. Cases of bilateral carpal tunnel syndrome can be observed in TTR amyloidosis and often requires surgical intervention. The estimated incidence of bilateral carpal tunnel is about 33% in patients with wtTTR and 29% in patients with mTTR. Poor appetite, easy satiety and weight loss may be observed due the involvement of other organs in the disease.

The examination of patients with cardiac amyloidosis may reveal a variety of symptoms including increased Jugular venous pressure, edema, ascites, hepatomegaly, low blood pressure, arrhythmia (atrial fibrillation), purpura, cardiac cachexia.^[33]

Hypotension may occur secondary to low cardiac output or other reasons. Blood pressure should be measured in lying, sitting and standing positions to

Table 2. Signs and symptoms suggestive of cardiac amyloidosis

The primary determinant of diagnostic process is the suspicion of cardiac amyloidosis
Heart failure with preserved ejection fraction (particularly in the presence of ventricular hypertrophy in male patients above the age of 60)
Elderly patients with low cardiac output, low-gradient aortic stenosis
Signs of right-sided heart failure including loss of appetite, hepatomegaly and ascites
Hypotension in a patient previously known as having hypertension
Unexplained left ventricular wall thickness of (≥ 12 mm) non-dilated left ventricle
Decreased left ventricular strain with apical sparing on echocardiography
Non-concordance between left ventricular thickness and QRS voltages (absence of low QRS voltage does not rule out cardiac amyloidosis)
A history of bilateral carpal tunnel syndrome in a male patient with ventricular hypertrophy
Unexplained left ventricular hypertrophy in an elderly man without hypertension should suggest wtTTR amyloidosis
Intolerance to medications that are widely used to treat cardiovascular disorders (digoxin, ACE inhibitors, ARB, beta blockers, calcium channel blockers)
Pericardial effusion and atrioventricular conduction block in a patient with left ventricular hypertrophy or hypertrophic cardiomyopathy
Interatrial septal thickening or valvular thickening

ACE: Angiotensin-converting enzyme; ARB: Angiotensin-receptor blocker.

explore a potential orthostatic hypotension. The presence of orthostatic hypotension is an indicator of a severe autonomic neuropathy.

Heart sounds usually are normal and a right-sided S3 sound may be heard in severe right ventricular dysfunction. S4 sound may be heard in the absence of atrial fibrillation. Amyloidosis usually does not cause severe valvular disorder; however, secondary mitral or tricuspid insufficiency may occur and lead to systolic murmurs.

Abdominal examination often reveals hepatomegaly and ascites associated with congestion. Splenomegaly is a rare finding while peripheral edema is a common finding and may occur in the legs and sacral and scrotal areas. Jugular venous pressure is usually elevated and a potential jugular venous distension should be explored both by inspecting the jugular vein and by testing hepatojugular reflux in the semi-recumbent position with the head of the bed elevated to 45 degrees.

The examination of the eyelid is crucial as the appearance of periorbital purpura in association with HF is considered to be pathognomonic for cardiac amyloidosis (particularly for the AL type of amyloidosis).^[42]

5.2 Patient characteristics suggesting cardiac amyloidosis

First, cardiac amyloidosis need to be suspected to make a diagnosis of cardiac amyloidosis. Cardiac amyloidosis may remain undiagnosed if not suspected. Table 2 summarizes patients to be suspected of having cardiac amyloidosis.^[43,44] Patients with AL cardiac amyloidosis are typically aged above the age of 40 and patients with wtTTR amyloidosis are typically aged above the age of 60 and the prevalence is increasing in each successive decade. mTTR amyloidosis may occur at any age between 30 and 70 years.^[23] Patients with AL cardiac amyloidosis usually have other organ involvement. The most common manifestations include nephrotic syndrome, hepatomegaly, peripheral neuropathy, macroglossia, purpura and bleeding diathesis. Out of these, macroglossia and periorbital purpura are pathognomonic for AL.^[33]

Clinical phenotype of mutant TTR amyloidosis varies depending on the location of genetic mutation. Clinical phenotype may be defined as neuropathy only, cardiomyopathy only or neuropathy and cardiomyopathy combined. mTTR amyloidosis should be suspected in any patient aged above the age of 50 who presents with unexplained HF and an increased left ventricular wall thickness or diastolic dysfunction.

In most elderly patients with wild type TTR amyloidosis (senile amyloidosis), amyloid deposition in the heart may not be clinically relevant. However, such deposition is associated with atrial amyloidosis and atrial fibrillation. In very rare cases ventricular deposition may be massive and may lead to HF. Ventricular amyloid deposition increases with age and is more common among blacks. Patients with wtTTR who develop HF are usually older than patient with AL cardiac amyloidosis and are more likely to develop left ventricular thickening. Many patients with wtTTR suffer from carpal tunnel syndrome while TTR deposition may result in spinal canal stenosis.^[45,46]

6.0 BASIC DIAGNOSTIC APPROACHES

Ebru Özpelit

6.1 General diagnostic approaches

Clinical suspicion is the most important stage of diagnostic approach in cardiac amyloidosis. In the presence of clinical findings suggestive of cardiac or systemic amyloidosis, cardiologists should try to confirm the diagnosis of amyloidosis if echo reveals remarkable ventricular hypertrophy and ECG reveals low voltage, as false negative results and low sensitivity constitute an important challenge with all available diagnostic tests. Diagnostic approach may differ on an individual basis on the type of amyloidosis and the organ involved in the disease. However, a suspicion for cardiac amyloidosis is usually based on ECHO and ECG findings accompanying to clinical signs and symptoms. At this point, it is crucial to consider clinical signs and symptoms summarized above. Another factor constituting a challenge in the diagnosis is that amyloid testing requires a multidisciplinary approach (in collaboration with hematology, pathology, radiology, nuclear medicine, neurology, nephrology, cardiology, rheumatology, gastroenterology units) and the awareness and experience on amyloidosis is low across all these branches. The protein amyloid may deposit in many organs and signs and symptoms depend on which organs are affected. Therefore, clinical signs and symptoms are not specific for amyloidosis and manifestations may greatly vary. Furthermore, every complaint of the patient is often assessed as an isolate complaint and treated by the relevant branch and this renders it more difficult to make a diagnosis of systemic amyloidosis.

For instance, a patient who presents with dyspepsia, diarrhea and is treated by a gastroenterologist

accordingly may be seen by an orthopedist for complaints associated with carpal tunnel syndrome and undergo surgery and the same patient may remain undiagnosed and sees many physicians for unexplained weight loss. Such examples are not rare among patients with amyloidosis.

In a study in more than 500 patients with AL type amyloidosis, the mean time from the onset of symptoms to diagnosis was found to be 2 years.^[47] The same study also demonstrated that patients with amyloidosis had to see at least 5 physicians of different specialties until being diagnosed with amyloidosis. Although patients see a cardiologist more frequently compared to hematologists, oncologists and nephrologists, only 18.7% of the cases of amyloidosis are diagnosed by a cardiologist.^[47]

Despite above-mentioned challenges, cardiology has a favorable position in making the diagnosis of amyloidosis compared to other branches. As previously stated, amyloid deposition usually leads to non-specific symptoms according to the organ which is affected while cardiac involvement present with a more pathognomonic symptom that can be identified by a cardiologist at first glance. Cardiac amyloidosis should be thoroughly investigated in each patient presenting with clinical signs and symptoms of amyloidosis along with hypertrophy on ECHO and low voltages on ECG. ECG, serum biomarkers, ECHO, nuclear imaging, MRI scans of the heart, genetic analyses and histopathological assessments should be used in line with Consensus Algorithm for the Diagnosis shown in this paper (see Consensus Algorithm for the Diagnosis). In the diagnostic process, it is crucial to know limitations, specificity and sensitivity of each test used in the diagnosis of cardiac amyloidosis. Factors potentially facilitating to make a diagnosis include an integral approach and patient assessments by multidisciplinary councils, if needed.

Although a tissue diagnosis, i.e. histopathological study, is the gold standard to demonstrate the presence of amyloid, a cardiac biopsy is not preferred very often due to the risk for potential complications. Results from other tissue biopsies (rectum, abdominal fat pad, oral) may vary from patient to patient as organ involvement may show variations among patients and sometimes it may show a patchy pattern. Biopsy site selection should be based on symptomatic organ rather than the easiness of the procedure. Therefore,

a single biopsy negative for amyloid cannot rule out amyloidosis if a high level of clinical suspicion exists.

Sometimes multiple biopsy specimens obtained from various extra-cardiac organs are needed or multifocal cardiac biopsies should be performed by experienced hands to make an accurate diagnosis. Moreover, one should keep in mind that very small and superficial biopsy specimens or improperly prepared histology slides may lead to false negative results. At this point, it is important to inform the pathologist about the high level of suspicion and preferably, histological examinations should be performed by a pathologist experienced in this area.

In short; diagnostic assessments of cardiac amyloidosis consists of 4 steps:

1. Suspicion of amyloidosis based on clinical signs and symptoms,
2. Demonstrating amyloid deposition using specific imaging methods and tissue biopsy, if needed,
3. Detecting the amyloid precursor protein leading to amyloidosis,
4. Assessments of organ involvement

6.2 ECG

Extracellular deposition and electrically silent nature of amyloid fibrils lead to a low-voltage ECG pattern. However, ECG studies meeting criteria defining a low-voltage ECG (a total QRS amplitude of ≤ 0.5 mV in limb leads and QRS amplitude of ≤ 1 mV in pre-

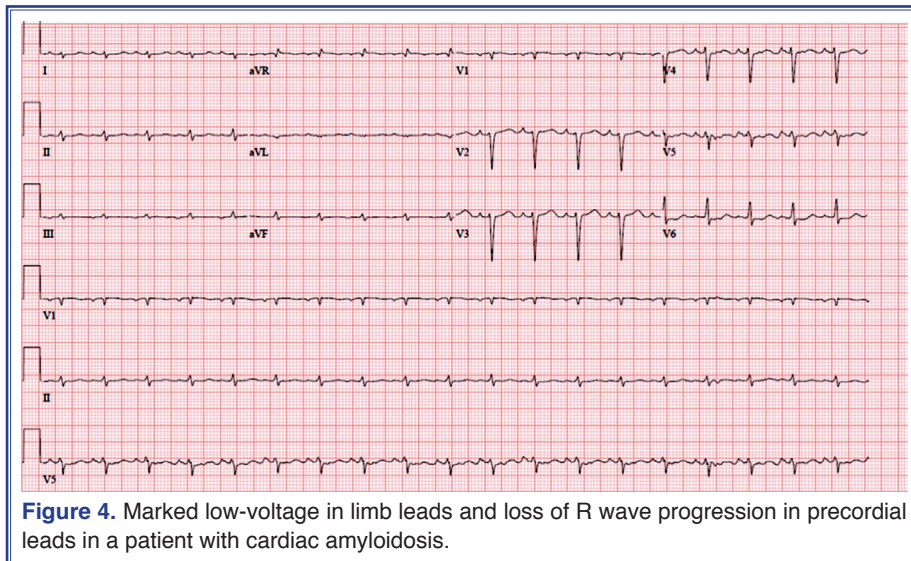


Figure 4. Marked low-voltage in limb leads and loss of R wave progression in precordial leads in a patient with cardiac amyloidosis.

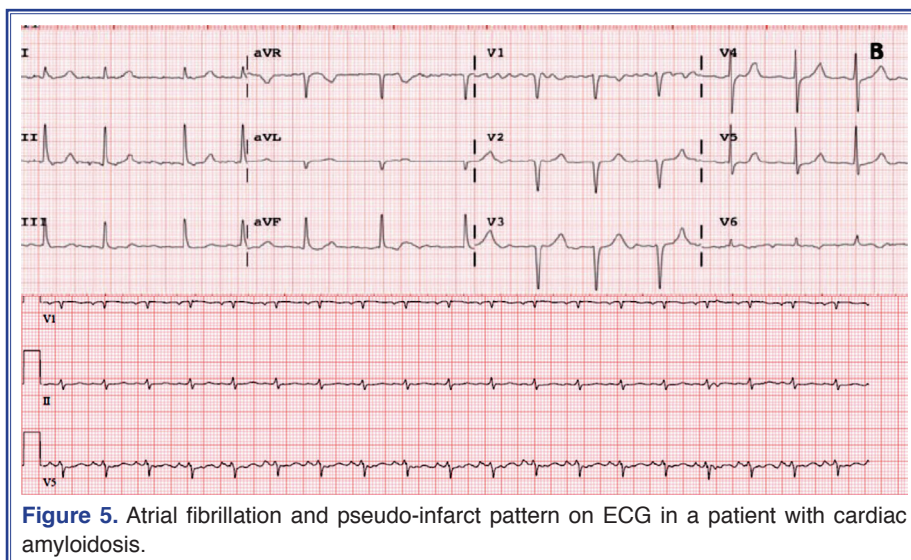


Figure 5. Atrial fibrillation and pseudo-infarct pattern on ECG in a patient with cardiac amyloidosis.

cordial leads) have been reported at different rates in various cardiac amyloidosis series. The frequency of low voltage in the AL cardiac amyloidosis has been reported to be 60% while this rate may be as low as 20% in TTR amyloidosis.^[48,49] In cardiac amyloidosis low voltage is particularly apparent in limb leads (Fig. 4). Poor R wave progression (known as pseudo-infarct pattern) is observed quite often in precordial leads (Fig. 5).^[43] Therefore, a non-concordant left ventricular thickness to QRS voltage ratio may be a more sensitive and specific finding for cardiac amyloidosis compared to classical low voltage findings. Although criteria specific to cardiac amyloidosis such as LV wall thickness/ total QRS voltage ratio have been defined in certain publication, it is not possible to talk about an established threshold yet.^[50] Low voltage ECG is an early symptom of amyloidosis. It occurs before any clinical manifestation of heart failure or even before the left ventricular hypertrophy becomes apparent on ECHO.^[51] Even though atria are also involved in the disease to the same extent as the ventricles, p wave is usually of normal voltage.^[51] Morphological abnormalities may be observed in the p wave. The most frequent abnormalities include slowed conduction and prolonged p wave duration due to the slowed conduction.^[51] Atrial fibrillation, bundle blocks and AV blocks are the other EKG findings that may occur in advanced cases of cardiac amyloidosis.^[52]

6.3 Serum biomarkers

Serum biomarkers are used in the diagnostic process as well as in prognostic evaluation and staging of cardiac amyloidosis and in the assessment of response to treatment. Serum BNP or NT pro-BNP and cardiac troponin are the first biomarkers to be tested in a cardiac amyloidosis. Although NT-proBNP levels are elevated in any patients with heart failure, a disproportionate elevation occurs in cardiac amyloidosis.^[53] BNP elevation results from both compression of myocytes by amyloid tissue and elevated filling pressures.^[51] Furthermore light chains in the circulation may lead to NT-proBNP release via p38 mitogen-activated protein kinase or directly.^[54,55] Therefore, with the same hemodynamic effects higher levels of BNP occurs in AL cardiac amyloidosis, compared to the transthyretin type.^[53]

Damage caused by myocyte compression exerted by amyloid fibrils may lead to increases at troponin levels. Elevation in troponin levels is usually very slight and chronic. Unlike patients with MI, rises

and falls in troponin levels do not occur in these patients.^[51] If a patient is suspected of having cardiac amyloidosis due to disproportionately elevated BNP levels and mildly elevated troponin levels, the next step should be making a tissue diagnosis to reveal the presence and the type of amyloid. As AL cardiac amyloidosis is the most common type of cardiac amyloidosis, first monoclonal protein analysis should be performed in the urine and serum. Although urine and serum protein electrophoresis is the most widely used test for this purpose, the sensitivity of this test is quite low (66%).^[56] Currently, monoclonal protein screening includes serum immunoglobulin free light chain testing and serum and urine immunofixation testing. Combined use of four methods including protein electrophoresis, serum immunofixation, serum immunoglobulin free light chain analysis and urine analysis may increase the sensitivity up to 98%.^[56]

The “Freelite test” which is considered to be the current gold standard, is used for serum free light chain analysis.^[57] However, most patients with amyloidosis suffer from kidney failure leading to an increase at the level of serum free light chains. In this case, it is recommended to calculate the kappa/lambda ratio or the difference between the levels of kappa and lambda chains to prove monoklonal paraproteinemia.^[58] The reference range of the ratio of kappa to lambda is 0.26 to 1.65; values >1.65 indicate kappa light chain involvement while values <0.26 indicate lambda chain involvement.^[58] Lambda chains are more commonly involved in AL-type amyloidosis. The difference between the involved and uninvolved light chains has been described as dFLC. For instance, if lambda free light chain concentration is 300 mg/L and kappa free light chain concentration is 20 mg/L in a patient, then the dFLC will be 280 mg/L. Currently this parameter is used in the diagnosis and staging as well as in treatment response evaluation.^[59] However, it should be kept in mind that an abnormal free light chain ratio or difference does not necessarily indicate AL-type amyloidosis, as the identification of the underlying cause of amyloidosis may be further challenging in a population aged over 65 years, where the rate of MGUS (monoclonal gammopathy of undetermined significance) ranges from 3 to 5%, particularly in the presence of wtTTR.^[60] The use of mass spectrometry which is considered to be the current gold standard becomes mandatory for amyloid subtyping in such patients, although this method has not been widely used yet.^[61]

In addition to these diagnostic tests, routine laboratory workup may show abnormalities due to organ involvement in amyloidosis. In particular, hypoalbuminemia, proteinuria and hypercholesterolemia may occur as a result of albuminuria and nephrotic syndrome which are often present in these patients. Furthermore, serum alkaline phosphatase, bilirubin and uric acid levels may be increased and factor X levels may be reduced if the liver is involved in amyloidosis.^[59]

In addition to diagnostic purposes, serum biomarkers are also used for staging purposes. In the AL cardiac amyloidosis staging developed by Mayo Clinic, each of dFLC (>18mg/L), troponin T (>0.025 ug/l) and NT-proBNP (>1800 ng/l) criteria scores 1 and patients who meet all three criteria are considered Stage 3. The mean survival has been reported as 3.5 to 4 months in Stage 3 patients.^[29]

dFLC and NT-proBNP are also used to assess treatment response. Hematological response correlates with the reduction in the dFLC organ responses correlate with the reduction in NTproBNP levels. Hematological response occurs before the organ response and is predictive of the organ response.^[59] A reduction at NT-proBNP levels is the most significant and objective sign of organ response in clinical practice.^[30] A reduction of >30% and >300 ng/L indicates the presence of organ response provided that the baseline value is ≥ 650 ng/L.^[62] dFLC may be appropriate to assess hematological response in patients with a baseline dFLC value of >50 mg/L; a 50% reduction with treatment signifies a partial response while a reduction down to 40 mg/L indicates a very good response.^[63]

7.0 DIAGNOSTIC IMAGING MODALITIES

Omaç Tüfekçioğlu

Current advances in imaging technologies have increased awareness on cardiac amyloidosis. However, the diagnosis is often delayed until the advanced stages and the prognosis at this stage is poor. In the majority of patients with cardiac amyloidosis, the diagnosis is made on the basis of high degree of clinical suspicion, coupled by history, electrocardiographic and echocardiographic findings.

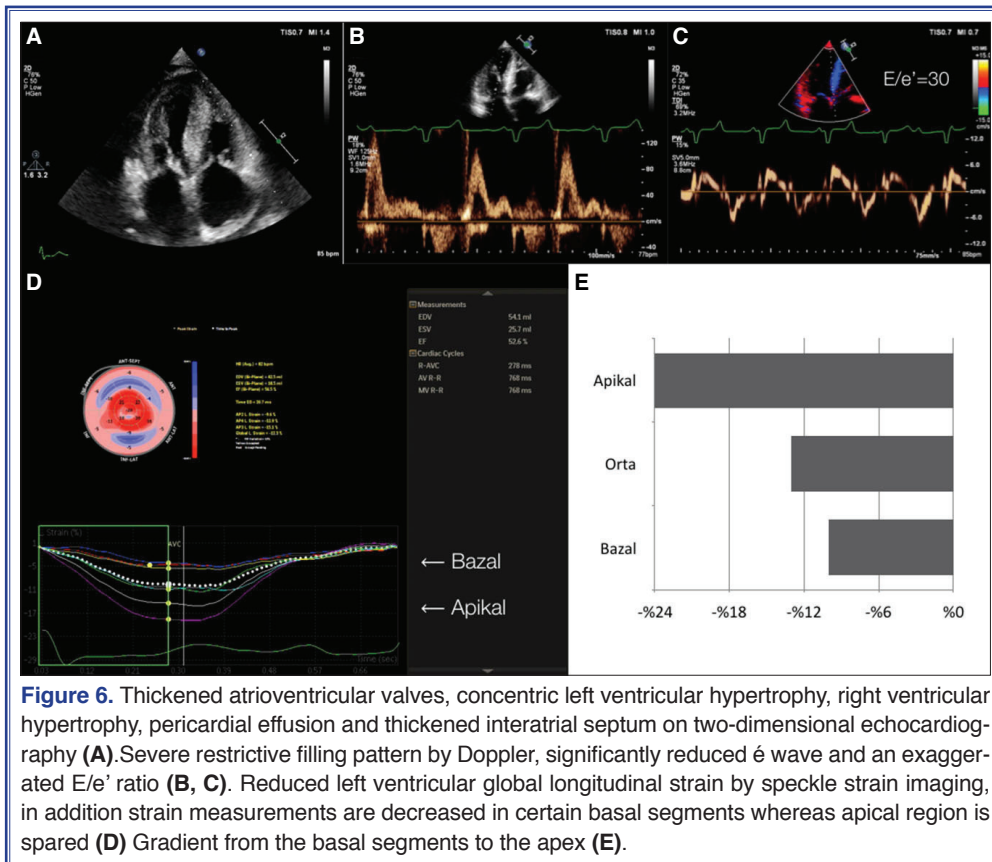
7.1 Echocardiography

Cardiac amyloidosis is characterized by concentric left ventricular hypertrophy with a normal or small left ventricular size. Left ventricular hypertrophy is

more prominent in aTTR amyloidosis compared to AL amyloidosis. However, a normal or near-normal left ventricular wall thickness does not rule out amyloid cardiomyopathy. The main echocardiographic finding is the discordance between left ventricular hypertrophy and ECG findings (normal voltage or low-voltage pattern on ECG, ECG findings of ventricular hypertrophy that are disproportionate to actual ventricular hypertrophy).

The paradox between low-voltage ECG pattern and left ventricular hypertrophy is most prominent in cases of AL amyloidosis. In aTTR, voltage criteria for the ECG diagnosis of left ventricular hypertrophy may be partially met in patients with preexisting hypertension. In spite of early exaggerated fractional shortening, cardiac output calculated by volume measurements is low and diastolic thinning rate of the left ventricular wall is also decreased. Ventricular outflow obstruction may occur at early stages and should be differentiated from other hypertrophic cardiomyopathies. Other findings on two-dimensional echocardiography include biatrial enlargement, papillary muscle hypertrophy, atrioventricular valve thickening, hypertrophy in the right ventricular free wall, interatrial septal thickening (missing “dropout” regions on echocardiography), mild pericardial effusion, intracardiac thrombus despite sinus rhythm and granular, sparkling appearance of hypertrophic left ventricular myocardium that persists after adjustments to reduce the gain. The aortic valve is the most commonly involved valve in amyloidosis. Cardiac amyloidosis is among the causes of low-output, low-gradient aortic stenosis.^[41,64-66]

Diastolic dysfunction precedes systolic dysfunction and signs and symptoms of congestive heart failure are associated with diastolic dysfunction rather than systolic dysfunction. Evidence may often suggest both left ventricular and right ventricular severe diastolic dysfunction and an exaggerated E/e' ratio may be observed even in the presence of early abnormal left ventricular relaxation. A progressive and severe decrease in E' wave by tissue Doppler imaging suggests amyloid cardiomyopathy and may differentiate amyloid cardiomyopathy from constrictive pericarditis and hypertrophic cardiomyopathy which are associated with milder decreases in E' wave. Tissue Doppler imaging may also reveal slower S velocities.^[65,67] Amyloid accumulation is more prominent at basal segments while it is relatively milder at apical segments (sparing apical areas) as a result of myocar-



dial fiber array of the left ventricle. Typical signs of involvement in amyloidosis, including spared apical deformation and severely impaired basal deformation, may be shown by echocardiography imaging modalities using deformation techniques (Fig. 6).

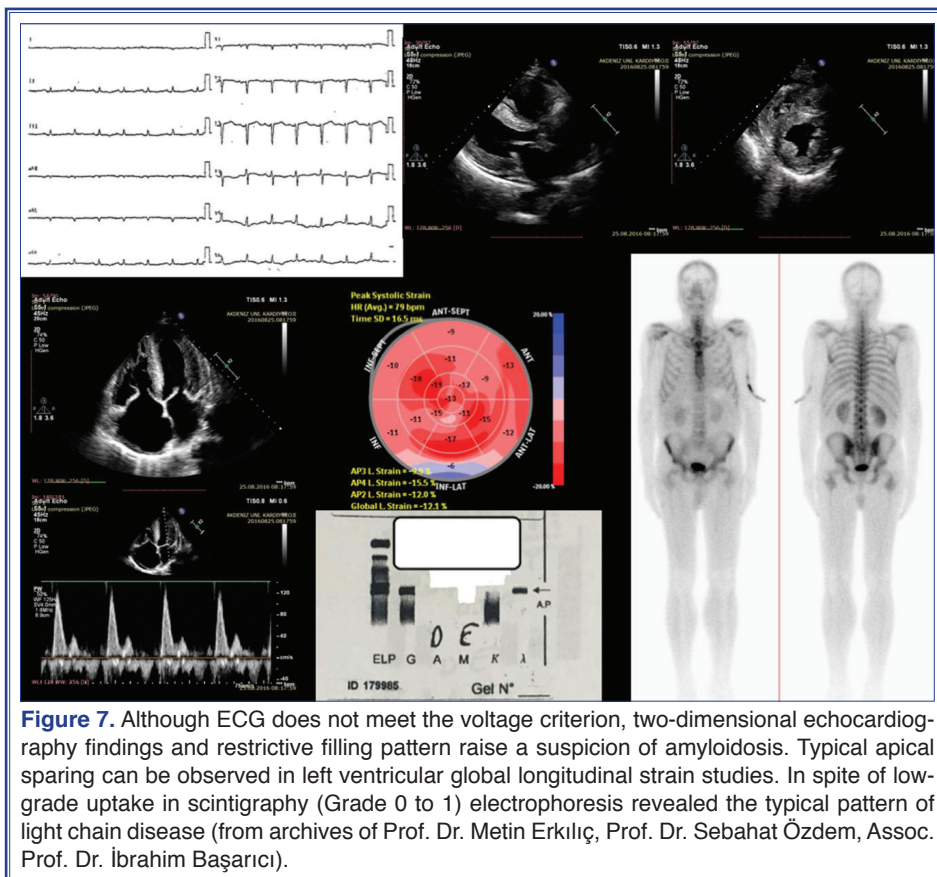
Apical sparing observed in deformation imaging may differentiate amyloidosis from left ventricular hypertrophy associated with aortic stenosis or hypertrophic cardiomyopathy with a sensitivity of 93% and a specificity of 82%.^[68] A septal apical to basal longitudinal strain ratio of >2.1 may differentiate amyloidosis from hypertensive hypertrophy, Fabry disease and Friedreich ataxia. Not only longitudinal strain but also circumferential and radial strains are decreased compared to hypertrophic cardiomyopathy and hypertensive heart disease. Unlike hypertrophic cardiomyopathy, as with the left ventricle, a decreased basal longitudinal strain in the right ventricle with relative apical sparing has been also reported in patients with α TTR amyloidosis.^[69] Higher left ventricular wall thickness measurements, a decreased end-diastolic volume, a reduced fractional shortening ratio and pericardial effusion on two-dimensional echocardiography and low-voltage ECG pattern along with

reduced left ventricular ejection fraction, right ventricular dilation and restrictive filling pattern indicate a poor prognosis in amyloidosis (Fig. 6).^[64,65,67]

7.2 Cardiac MRI

Magnetic Resonance Imaging is used to diagnose, monitor and estimate the prognosis in cardiac amyloidosis. The most widely used MR imaging methods include Cine-MR (CMR), late gadolinium enhancement (LGE) and T1 mapping. CMR has high spatial resolution and is used for anatomical assessment in a similar way to images obtained by 2-dimensional echocardiography. As with two-dimensional echocardiography, CMR is used to assess ventricular hypertrophy and restrictive signs (small or normal chamber size, pericardial effusion, and biatrial dilation and right ventricular hypertrophy). A thickened interatrial septum (>6 mm) is a specific finding but may be seen in 20% of patients with cardiac amyloidosis. Pericardial or pleural effusion may also occur.

Gadolinium enhancement shows a specific pattern based on biological and volume characteristics of myocardial extracellular space. In cardiac amyloidosis, amyloid accumulation results in extracellular



expansion while gadolinium accumulates in the extracellular space. An early epicardial-endocardial gradi-

ent-based contrast enhancement occur following gadolinium injection with a higher enhancement in the

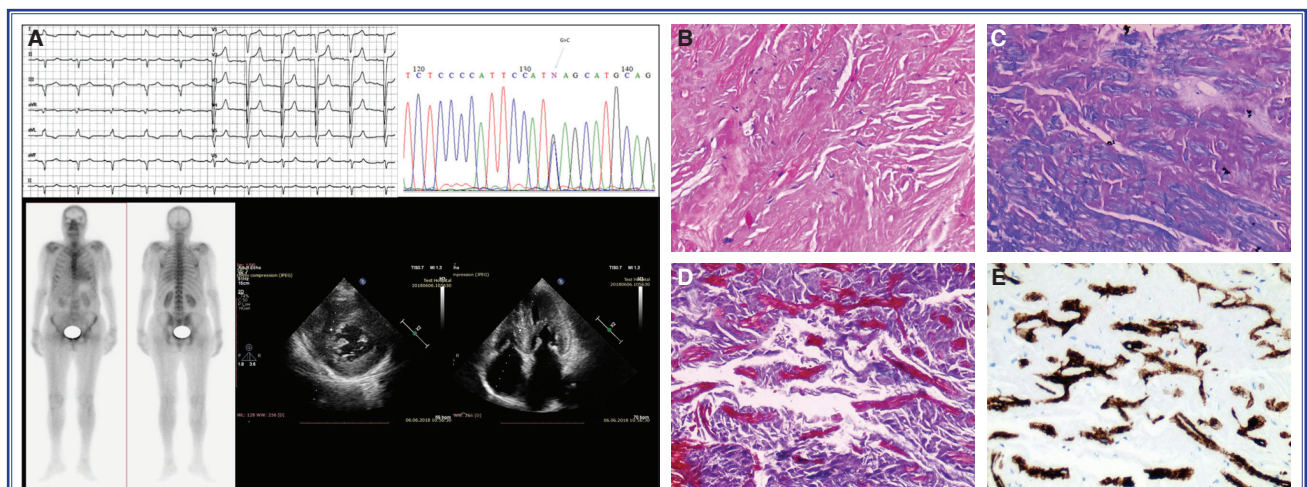
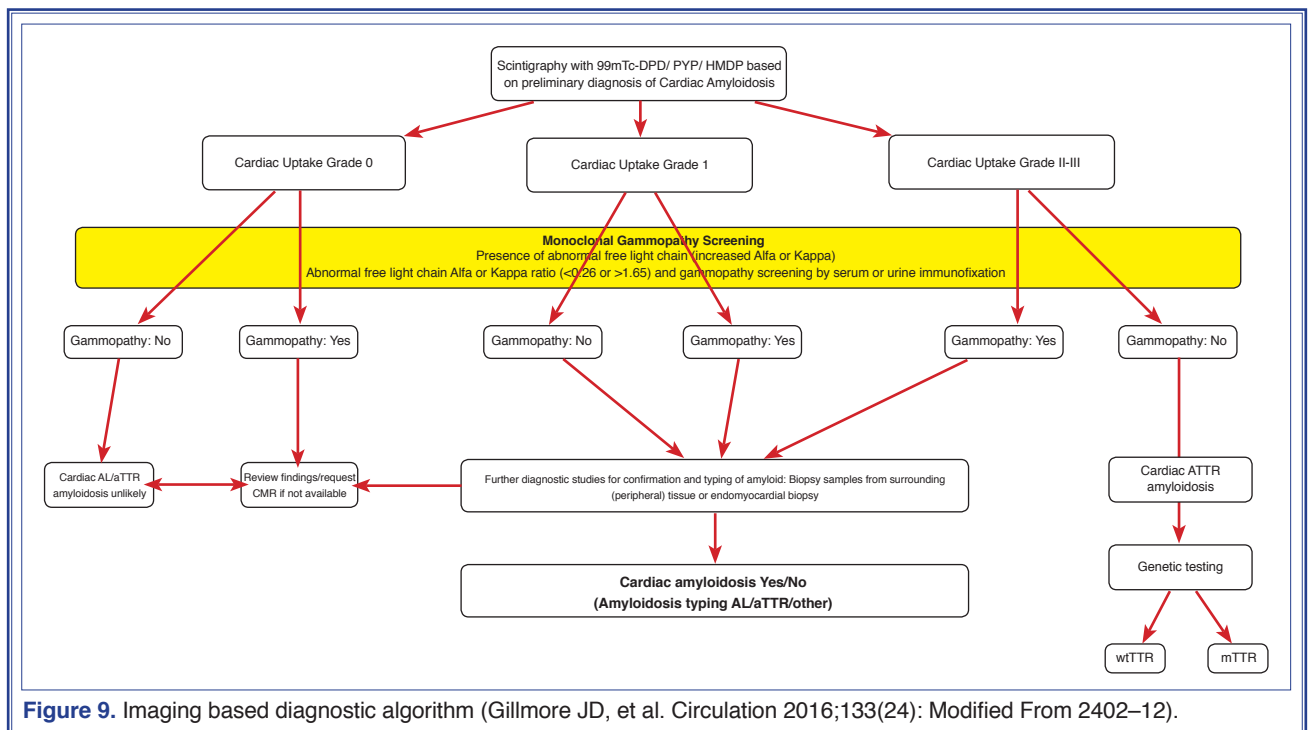


Table 3. Clinical use of cardiac imaging tests

	Clinical suspicion	Subclinical early diagnosis	Diagnosis	AL/aTTR distinction	Prognosis
Two-dimensional and M-Mode echocardiography	✓✓✓	x	✓	x	✓✓✓
Speckle-Strain Imaging	✓✓✓	✓	✓	x	✓✓
MRI	✓	✓✓	✓✓✓	✓	✓✓✓
Bone Scintigraphy	✓	✓✓	✓✓✓	✓✓	x
PET/CT	✓	✓	✓✓	✓	✓

x: Not used; ✓: Rarely used; ✓✓: Not uncommonly used; ✓✓✓: Commonly used.



endocardium. Marked endocardial contrast enhancement occurs in the late phase, later on. Subendocardial or transmural LGE specifically occurs in the entire ventricle. White stripes indicating subendocardial LGE at the interventricular septum with dark, spared mid-myocardial area in between give a “Zebra-like appearance”.^[65,70] Amyloid deposits prolong longitudinal relaxation time (T1) a magnetic property of the heart. A prolonged T1 indicates amyloid deposition in cardiac amyloidosis.^[65] The difference between pre-contrast and post-contrast T1 measurements correlates with extracellular volume and the volume increases as the difference increases. The increase in the extracellular volume is more marked in aTTR vs. AL amyloidosis.^[70,71]

Cardiac amyloid impairs kinetics of gadolinium distribution. Gadolinium rapidly and simultaneously washes out of the blood pool and myocardium, rendering impossible to differentiate left ventricular blood pool from the myocardium. This phenomenon has been defined as lack of “myocardial nulling”. “Nulling” has been described as covering up background images to pronounce pathological areas.^[72]

7.3 Bone scintigraphy

Scintigraphy is a highly sensitive imaging tool to be used in the diagnosis of aTTR amyloidosis, in particular. 99mTc-labelled bisphosphonates including 99mTc-pyrophosphonate (PYP), 99mTc-3,3-diphosphono-1,2-propanodicarboxylic acid (DPD) and

^{99m}Tc-hydroxydiphosphonate (HDP) are used to diagnose amyloidosis. In the event that echocardiography and MR imaging fail to detect amyloid depositions, scintigraphy may reveal the involvement of the heart in amyloidosis with a sensitivity of nearly 100%.

Scintigraphy may also be used to differentiate AL from aTTR amyloid deposition. Although a low-level radiotracer uptake may occur in AL amyloidosis, most of the agents used in bone scanning show a high specificity for aTTR. Furthermore, radiotracer uptake distribution in other parts of the body may show different characteristics between these two types of amyloidosis. In AL, ^{99m}Tc-DPD or ^{99m}Tc-HDP uptake occurs in the viscera (the spleen and the liver) but not in muscles, whereas cardiac uptake occurs in less than 50% of patients with cardiac involvement. However, probably due to the calcium content in amyloid deposits, heart is the most commonly involved organ in aTTR amyloidosis and is followed by skeletal muscles (muscle-rich regions including gluteal region, shoulder, chest wall and anterior abdominal wall).^[65,73] The differential diagnosis between AL and aTTR is made based on the ^{99m}Tc-PYP uptake ratio between the heart shadow and contralateral lung tissue; a ratio of <1.5 favors AL, whereas a ratio of ≥1.5 favors aTTR.^[74] ^{99m}Tc-PYP and ^{99m}Tc-DPD have the highest sensitivity and specificity particularly in aTTR screening.^[74] In scintigraphy, cardiac uptake intensity is graded from 0 to III with no uptake in Grade 0 and a cardiac uptake intensity similar to bone signal in Grade III (Figs.7, 8a-e).

Positron emission tomography (PET) imaging may have a role in the diagnosis of cardiac amyloidosis and may be used in the differential diagnosis between cardiac amyloidosis and other conditions leading to cardiac hypertrophy. However, available data are insufficient to make a distinction among cardiac amyloidosis subtypes.^[75,76]

7.4 Imaging based diagnostic algorithm

Plasma cell dyscrasias should be investigated in every patient suspected of having cardiac amyloidosis based on clinical symptoms; echocardiography and/or MRI findings and bone scintigraphy should be performed for both diagnostic and typing purposes. Patients exhibiting Grade II-III uptake without gammopathy are more likely to have aTTR amyloidosis and TTR genotyping is recommended. Tissue diagnosis is recom-

mended in all patients exhibiting Grade II uptake with gammopathy and patients exhibiting Grade I uptake with or without gammopathy. Tissue diagnosis is recommended in patients exhibiting Grade 0 uptake with gammopathy, while tests results should be reviewed in patients without gammopathy, if clinical suspicion exists.

Clinical use of imaging tests is presented in Table 3 and a diagnostic algorithm is summarized in Figure 9.^[77]

8.0 HISTOPATHOLOGICAL/GENETIC ANALYSIS – Meral Kayıkçoğlu

8.1 Histopathological analysis (tissue biopsies)

Among all diagnostic modalities, histopathological studies demonstrating amorphous amyloid fibril deposits i.e. tissue biopsy is the gold standard in the diagnosis of amyloidosis. Novel modalities have been developed to detect amyloid in any tissues, owing to technological advances. Endomyocardial biopsy (EMB) is a simple, invasive procedure with a low complication rate (1 to 2% in experienced hands) and a sensitivity of almost 100% in appropriate patients.^[78] EMB is not required in most patients, as the diagnosis of amyloidosis can be made based on samples collected from alternative tissues (e.g. abdominal fat tissue, rectal mucosa, minor salivary glands etc.). If a sample biopsy from any alternative tissue is positive for amyloid deposits with typical non-invasive appearance of CA, EMB is not needed. Other organs selected for biopsy are not required to exhibit clinical signs and symptoms of involvement in amyloidosis.^[79] Abdominal fat pad aspirates are stained positive for amyloid in 70% of patients with light chain (AL) amyloidosis, however, false positive results are common in laboratories that do not routinely work with such samples. Based on the diagnostic algorithm, bone marrow biopsy should be done first if AL amyloidosis is suspected,^[78,79] as a bone marrow biopsy may reveal a plasma-cell dyscrasia in 80% of patients and amyloid deposition in 60% of patients. The sensitivity of histological studies in diagnosing hereditary mTTR may vary depending on the site where samples are collected. Diagnostic sensitivity of sural nerve biopsy is 79 to 80%, while sensitivity may reach up to 91% in labial salivary gland biopsy in early onset Val-30Met variant. However, diagnostic sensitivity may largely vary from 14 to 83% in abdominal fat pad bi-

opsies leading to an uncertainty for patients undergoing abdominal fat pad biopsy.^[80]

Amyloid may accumulate anywhere in the heart including myocardium, vessels, endocardium, valves, epicardium or parietal pericardium.

These accumulation sites are not specific and may be involved in any types of cardiac amyloidosis. However, vascular involvement is more common in light chain (AL) amyloidosis where interstitial accumulation is more severe. In amyloid cardiomyopathy, ventricular wall thickening is typically concentric or in the form of disproportional septal thickening. Initially, amyloid protein tends to accumulate in posterior-basal ventricular septum and may mimic coarse appearance of hypertrophic cardiomyopathy. Amyloid deposition becomes more evident and diffuse as the disease progresses. Endocardial amyloid deposition is less pronounced but not rare. The left atrium is the most common amyloid deposition site. Epicardial coronary arteries are commonly involved in amyloidosis although amyloid deposition in these arteries does not generally result in occlusion. Amyloid deposition and vascular occlusion particularly occur in vasa vasorum of epicardial coronary arteries. Apart from vasa vasorum, amyloid related vascular occlusion may only occur in small intramural branches of coronary arteries.^[79]

Histologically, myocardial amyloid deposition is typically irregular and patchy in appearance; may be pericellular or nodular. Deposits are more likely to occur in subendocardial and midmural regions, rather than subepicardial region. Absence of amyloid deposition in biopsy specimens does not rule out amyloidosis due to patchy pattern of deposition.^[78-80]

In amyloidosis, microscopic examination of the myocardium reveals amorphous hyaline deposits, predominantly in the extracellular space, whereas electron microscope reveals that these deposits are made up of non-branching fibrils (7 to 10 nm in diameter). These fibrils bind to Congo red (leading to green birefringence under polarized light), thioflavin (an intense yellow-green fluorescent color) or sulfated alcian blue (green color).

Essential histological approach include the use of a light microscope to examine formalin fixed paraffin embedded (FFPE) sections after using a basic or any special stain used in histology or after immunohistochemical staining. In this conventional diagnostic ap-

proach, the use of special histological stains is recommended while Congo red staining is the gold standard for diagnosis. After binding to Congo red amyloid fibrils exhibit characteristic apple green birefringence when viewed by cross polarized light.

There are also methods directly detecting amyloid in tissue biopsy specimens. These methods may be gathered mainly in two groups including 1. Immunohistochemistry (antibody based), and 2. Proteomics.^[81]

1. Immunohistochemistry (IHC)

Immunohistochemistry is based on labelling with antibodies against amyloid or precursor proteins. Antibody panels may be needed depending on clinical scenario, while the use of more than 40 antibodies may be challenging. Rare or new amyloid proteins cannot be detected by these techniques.

a. Immunoperoxidase (IP) is widely used technique to directly detect amyloid deposits. The IP technique is a relatively rapid procedure and has the advantage of utilizing formalin fixed –paraffin embedded (FFPE) tissues.

b. Immunofluorescence (IF), is a well-established and widely used technique, as with IP, but has a higher sensitivity and specificity than IP. However, frozen tissue sections are required for IF testing. Therefore, this technique may be used in the diagnosis of amyloidosis if only the clinical care team has a strong suspicion of amyloidosis.

c. Immunoelectron microscopy may also be used to successfully diagnose amyloidosis. Its limited availability, higher costs and longer turnaround time restrict the use of immunoelectron microscopy in routine clinical practice, even though it is a reliable and direct method.

2. Proteomics

Proteomics involves direct biochemical analysis of specific proteins forming deposits. Therefore, proteomic has been considered to represent a definitive method of amyloid typing. This chapter includes direct amino acid sequencing of the amyloid fibrils, western blot methodologies or peptide fragment mass and load and the comparison of these techniques with a well-established standard such as mass spectrometry.

Separation of proteins by gel electrophoresis (2D-PAGE) and subsequent mass spectrometry analysis of protein spots excised from the gel is a technique

that has proven effective in identifying amyloid in non-fixed specimens.^[82] However the procedure is labor-intensive and its utility in the heart tissue has not been established yet. Congo-red positive amyloid deposits extracted from FFPE tissue specimens and prepared on plastic slides are subjected to laser microdissection and liquid chromatography-mass spectrometry (LC-MS/MS). As with the IP techniques, this technique has the advantage of using FFPE specimens as a source and does not specially require to use EMB specimens. Furthermore, proteomics can serve as a screening tool to detect underlying genetic alterations. Mass spectrometry (MS)-based methods are novel diagnostic techniques allowing to detect proteins in a very small quantity of tissue. These diagnostic techniques have been developed for the use in FFPE tissue, frozen tissue or fresh adipose tissue specimens. The main advantage of the technique is its ability to use archival FFPE tissue specimens. A

special sampling technique referred to as laser microdissection (LMD) improves the specificity by removing other normal tissue components. The sensitivity and specificity of LMD with liquid chromatography-mass spectrometry reach almost 100%, even in cases of rare hereditary variants. The LMD technique followed by mass spectrometry will potentially allow making an accurate diagnosis by demonstrating amyloid deposits, particularly in indeterminate cases.^[83] However, mass spectrometry technology is only available at specialized centers and unfortunately; this technology is not available in our country yet.

In summary, if there is a suspicion of amyloidosis, the diagnostic algorithm begins with a non-targeted biopsy (the most common sites are abdominal fat pad, rectal mucosa, oral mucosa or a minor labial salivary glands). A targeted biopsy of the relevant organ (the kidney or myocardium) will follow if the initial attempt fails to diagnose amyloidosis. Amyloid

Table 4. The most common 3 TTR mutations and their characteristics

Mutation	Clinical manifestations	Geographic region/ethnicity
Val30Met (Met30)	Peripheral neuropathy >cardiac involvement	Portugal, Sweden, Japan
Thr60Ala (Ala60)	Peripheral neuropathy =cardiac involvement	UK, Northern Ireland
Val122Ile (Ile122)	Peripheral neuropathy <cardiac involvement	Africa, African-American, African-Caribbean

Table 5. General characteristics of cardiac amyloid types

	Amyloid type	Precursor protein	Organ involvement	Etiology	Concomitant diseases	Typing techniques
1	AL	Immunoglobulin light chain	Systemic & localized	Acquired	Plasma cell dyscrasias	IP, IF, MS
2	AH	Immunoglobulin heavy chain	Systemic	Acquired	Plasma cell dyscrasias	IF, MS
3	ATTR	Transthyretin	Systemic	Acquired & Inherited		IP, IF, MS
4	AA	Serum amyloid A	Systemic	Acquired	Chronic inflammation	MS, ELISA
5	A β 2M	β 2-microglobulin	Systemic	Acquired & Inherited	Chronic hemodialysis	IP, MS
6	AApoAI	Apolipoprotein A-I	Systemic & localized	Inherited		SDS-PAGE+ HPLC, MS
7	AApoAII	Apolipoprotein A-II	Systemic	Inherited		Western blot
8	AApoAIV	Apolipoprotein A-IV	Systemic	Acquired		IP, western blot, MS
9	AGel	Gelsolin	Systemic	Inherited		MS
10	AANP	Atrial natriuretic peptide	Localized	Acquired	Atrial fibrillation	MS
11	ALys	Lysozyme	Systemic	Inherited		MSa*

MS: Mass spectrometry; ELISA: Enzyme linked immunosorbent assay; SDS-PAGE+HPLC: Sodium dodecyl sulfate-polyacrylamide gel electrophoresis + high-performance liquid chromatography. *Typing in kidney biopsy sample, only assessed in cardiac involvement.

Table 6. Clinical characteristics by the type of cardiac amyloidosis

Types	AL	mTTR	wTTR	AA	IAA	AB2M
Precursor protein	Light chain (70% x and 30% k)	Mutant TTR	Wild TTR	Serum amyloid A	ANP	B2 microglobulin
Precursor source	B cells	Liver	Liver	Liver	Heart	All cells containing a nucleus or iatrogenic
Associated conditions	Cell dyscrasias (MM, NHL, MGUS)	Depending on the type of mutation	Age-related	Chronic inflammatory conditions	Heart failure	Prolonged hemodialysis
Prevalence of cardiac involvement	50% (varies depending on the type of dyscrasia)	Highest prevalences in V122I, V30M and T60A mutations	8 to 16% in patients over the age of 80 years	1–15%	15%	35% (after 10 years of treatment)
Mean age at clinical presentation	60	40 (52 years, depending on the type of mutation)	76	50–58	70	Variable (after 10 years of treatment)
Major organs involved	Kidney, liver, heart	Peripheral autonomic nerves and heart	Kidney	Thyroid, spleen, GIS, kidney, liver	Only heart	Kidney, heart, GIS
Cardiac signs						
- LV wall thickening	+ (15 mm)	+ (16 mm)	++ (19 mm)	-	-	+
- Low-voltage ECG	++ (60–71%)	+ (25%)	+ (40%)	+ (17%)		I
- Pseudo-ischemia (LV-EF%)	++ (48–63%)	+ (42%)	+ (40%)	+ (17%)	Suboptimal	Low
Diastolic dysfunction	Suboptimal ++	Suboptimal +	Suboptimal +	-		
Related CV findings		Atrial fibrillation	Atrial fibrillation	Hypertension	Atrial fibrillation Hypertension	
Mortality	Average 6 months after HF	?	35% within 5 years after diagnosis by biopsy	31% within 10 years after cardiac involvement		

GIS: Gastrointestinal system; HF: Heart failure; CV: Cardiovascular; EF: Ejection fraction; LV: Left Ventricle; ANP: Atrial natriuretic peptide.

subtyping is important, particularly in determining appropriate therapeutic approaches after the confirmation of the diagnosis of amyloidosis by a tissue biopsy. Serum and urine immunofixation tests and immunoglobulin-free light chains tests have been used historically to classify different types of amyloidosis. However, due to the high prevalences of single clonal gammopathy, particularly in elderly, false positive results are common. Advanced techniques with improved sensitivity and IHC staining are needed to classify amyloid deposits.^[84]

8.2 Genetic analysis

Amyloidosis, which has been considered to result from more than thirty misfolded proteins, may be either acquired or hereditary. There is an increasing understanding that certain types of amyloid disorders show an autosomal dominant inheritance pattern and are associated with inherited abnormalities of precursor proteins, alone.^[85] Furthermore, genetically determined factors may induce the development of acquired amyloidosis. More than 500 mutations and polymorphisms affecting genes relevant to amyloid subunit proteins and their precursors have been defined. Particularly, mutations coding abnormal proteins prone to fibrillogenesis, polymorphisms associated with cofactors such as apolipoprotein E or subunit proteins such as serum amyloid A, hereditary disorders affecting the level or deposition of precursor proteins (e.g. mutations in presenilin in Familial Alzheimer Disease), chronic inflammation in vulnerable populations, disorders leading to a tendency for the deposition of precursor proteins (e.g. pyrin and cryopyrin mutations in Familial Mediterranean Fever [FMF] and Muckle Wells syndrome), all have been linked to amyloidosis.^[86]

In general, hereditary amyloidosis characterized by nephropathy, neuropathy or cardiac involvement, is a dominantly inherited heterozygous condition and both wild-type and mutant molecules may be identified in amyloid deposits. In certain situations, both wild-type and mutant molecules (e.g. transthyretin [TTR], apolipoprotein AI [Apo-AI], amyloid precursor protein [APP] in Alzheimer's disease and prion protein [PRP]) may individually form amyloid fibrils under different conditions (e.g. wild-type TTR, amyloid beta protein (AB), a degradation product of ApoA1 and APP may form deposits associated with a organ-specific aging pathology, in the heart, aorta and brain, respectively).^[87]

More than 130 mutations have been identified in ATTR, which is the most well-known genetic amyloidosis.^[88] Mutations underlying ATTR have also prognostic implications and genetic testing is recommended both to confirm diagnosis and to predict prognosis.

Under special conditions, TTR gene sequencing may be required, particularly to identify new amyloidogenic mutations. Accordingly, a sequence analysis is recommended in the presence of atypical symptoms or it is challenging to confirm amyloidosis. The gene responsible for amyloidosis is a relatively small gene located on the chromosome 18, constituted of 127 amino acids and four exons and it is relatively easy to sequence.^[88]

The most common TTR mutations include Val30Met, Thr60Ala and Val122Ile. Characteristics of these three mutations are summarized in Table 4. The most common TTR mutation is the Val30Met mutation and is associated with neuropathy at the time of diagnosis and CM in the late course of the disease. Cardiac involvement is the main manifestation in patients carrying Val122Ile, Thr60Ala, Ile-68Leu, Leu111Met or Ser77Tyr mutations with the most common mutations being Val122Ile and Thr60Ala. Patients with Val122Ile variant are usually older and the prevalence of cardiac infiltration is higher among these patients compared to those with other mutations. 3.5% of African-Americans carry the Val122Ile variant and this variant is more common in males. Cardiac characteristics do not differ, whereas clinical courses differ among TTR mutations. For example, a TTR variant, Val94Ala substitution is associated with a long-term stable clinical course followed by a rapidly progressive amyloidosis phase characterized by polyneuropathy, gastrointestinal and cardiac involvement. Furthermore, all known TTR mutations may not exhibit a complete penetrance, i.e. all carriers will not necessarily develop the disease.^[88]

Some mutations in the TTR gene have been shown to be protective against amyloidosis. A variant characterized by the substitution methionine for threonine at position 119 (T119M), provides a relative protection against the development of amyloidosis by exerting a stabilizing effect on TTR tetramer.

8.3 Diagnostic tips to differentiate between the types of amyloidosis

After confirming the diagnosis of amyloidosis by biopsy, subtyping of amyloid deposits is necessary, par-

ticularly in determining the best treatment approach. Furthermore, subtyping is also important in terms of family screening. To date, 11 types of amyloid have been reported to affect the heart. Only one of these amyloid types (atrial natriuretic peptide (ANP) type amyloid) is believed to involve the heart alone. General characteristics of cardiac amyloid types are summarized in Table 5.^[4] Once cardiac amyloidosis is suspected, the following considerations should be noted:

1. Any type of amyloidosis may affect any cardiac structures.
2. The differentiation between amyloidosis types cannot be made by conventional histopathological studies as involvement is quite similar.
3. Histologically, myocardial amyloid deposition is irregular and patchy and may be pericellular or nodular. Therefore, false negative results are not uncommon in myocardial biopsies.
4. The AL type amyloidosis is the most common type of cardiac amyloidosis. Therefore, conventional serum and urine immunofixation tests and immunoglobulin-free light chain tests are still used to classify different types of amyloidosis. However, due to the high prevalences of single clonal gammopathy, particularly in elderly, false positive results are common.
5. Advanced techniques with improved sensitivity to detect deposits in the tissue and IHC staining (antibody based) are needed to classify amyloid deposits.

In addition, clinical findings may give clues for typing the amyloidosis (Table 6).^[89] For example, marked enlargement of the tongue and purpura on the eyelids, face and neck may only occur in AL-type amyloidosis. AL-type amyloidosis is the most common type of cardiac amyloidosis and accounts for 80% of all cases of cardiac amyloidosis. It is associated with an underlying plasma-cell dyscrasia and occurs in people over the age of 40 years, with no gender predilection. Cardiac involvement is estimated to occur in 90% of cases of AL-cardiac amyloidosis. Another characteristic of AL amyloidosis is that hypertrophy is less marked in AL-type amyloidosis compared to TTR and this situation may be explained by direct myocytotoxic effects of circulating light chains. Accordingly, even though amyloid deposits do not vanish, cardiac functions improve with treatment of light chain disease.^[90]

wtTTR amyloidosis is associated with a slowly progressive clinical course with less clinical symptoms

compared to mutant or AL amyloidosis. Although wtTTR amyloidosis has been reported to occur typically in males aged 70 years and over, younger patients (e.g. in a patient aged 58 years) with wtTTR amyloidosis have been reported.

9.0 GENERAL THERAPEUTIC APPROACHES

Mehmet Birhan Yılmaz

9.1 The role of medications for heart failure in cardiac amyloidosis

The US and European Guidelines for the management of heart failure (HF) recommend the use of ACE inhibitors, beta blockers and diuretics in all patients with symptomatic HF with reduced ejection fraction (HFrEF) independently from etiology.^[91,92] Although diuretics are used for palliative purposes and to mitigate symptoms of congestion in patients with amyloidosis (cardiac), such patients have not been included or have probably remained undiagnosed in studies providing strong evidence for the use of ACE inhibitors or angiotensin receptor blockers (ARB). At this point, it is important to note that patients with amyloidosis are not included in the evidence pyramid for HFrEF as patients with AL-amyloidosis have been excluded from studies, particularly due to the aggressive behavior of AL-type amyloidosis in patients with amyloid-related HF with a median life expectancy less than 6 months (a life expectancy of <1 year has been considered as an exclusion criteria in large studies) and patients with mTTR or wtTTR amyloidosis have been excluded from studies as restrictive cardiomyopathy or preserved ejection fraction HF (HFpEF) phenotypes are more common among these patients.^[93] Consequently, evidence is clearly lacking for the medical treatment of HF in cardiac amyloidosis, in particular.

Reduced end-diastolic volumes and mild systolic dysfunction resulting from thickened ventricular wall due to amyloid deposition and a slow heart rate may lead to a reduced cardiac output indicating a very poor prognosis.^[94] Therefore cardiac output is highly dependent on heart rate in patients with cardiac amyloidosis.

Sodium restriction along with mild diuretics used cautiously is the rationale first-line choice in palliative treatment of cardiac amyloidosis-related HF. However, due to the narrow therapeutic interval between very high and very low filling pressures, close observation is needed. The use of long-acting torcemide or MRA

containing combinations rather than short-acting furosemide is a rational option to decrease congestion and ensure euvoemia.^[95] On the other hand, as the cardiac output depends on heart rate in all types of cardiac amyloidosis and orthostatic symptoms are highly prevalent, patients may hardly tolerate ACE inhibitors or ARBs or beta blockers that remain unknown in terms of evidence-based medicine.^[96] Digoxin should be avoided due to the increased risk of toxicity. Nondihydropyridine calcium antagonists are contraindicated as this group of medicines strongly bind to amyloid fibrils and may lead to profound hypotension and syncope.^[95] Low-dose digoxin and/or beta-blockers may be considered only in patients with atrial fibrillation or inappropriate sinus tachycardia. Anyway, it is important to establish sinus rhythm due to the need for atrial contribution for ventricular function. An important consideration is that ACE inhibitors or beta blockers have not proven beneficial in cardiac amyloidosis with HFrEF phenotype; therefore, these patients should not be treated empirically. In fact, ACE inhibitors or beta blockers should not be started in these patients.^[97] Furthermore, orthostatic intolerance to low-dose ACE inhibitors or conduction problems with low-dose beta-blockers should suggest cardiac amyloidosis in patients with HFrEF who receive empiric treatment. The use of beta-blockers does not appear rational with the exception of cases of inappropriately rapid heart rate (sinus rhythm or atrial fibrillation). On the other hand, outcomes of electrophysiological catheter ablation therapy are not promising for the management of tachyarrhythmia in this group of patients.^[98] As scientific evidence on this condition is almost absent, a retrospective analysis was conducted based on medical records of 480 patients with cardiac amyloidosis (wtTTR n=242, mTTR n=238); life expectancy was found to be worst in patients with mTTR amyloidosis who had received beta blockers or ACE inhibitors while treatment with beta blockers or ACE inhibitors had no positive (or negative) effect on the prognosis in patients with wtTTR amyloidosis.^[99]

9.2 Pacemaker-ICD

Pacemakers are indicated in the treatment of heart blocks or symptomatic bradycardia that may occur during the course of the disease and indications for the use of pacemakers do not differ from those in general population. The use of ICDs in cardiac amyloidosis is controversial but may be considered in selected patients,^[100,101] whereas electromechanical dissociation

has been considered to be underlying cause of sudden death in patients with cardiac amyloidosis.^[35] Therefore, even though ICD implantation is not be considered beneficial, studies in small samples suggest potential benefits of ICDs in selected patient subgroups.^[10,12] Large registries may provide more definitive results regarding the use of ICD in these patients.^[102]

9.3 LVAD-heart/liver transplantation

Heart transplantations usually have a limited role in the treatment of mTTR amyloidosis which may lead to multiple organ involvement whereas wtTTR amyloidosis is more prevalent in elderly population and limited number of donors makes the candidacy of these patients for heart transplantation unlikely. However, patients with wtTTR amyloidosis under the age of 70 years may be eligible for heart transplantation due to the absence of extracardiac involvement.^[103] An isolated heart transplantation, without liver transplantation should not be considered in patients with mTTR, even though there may be different possibilities in certain special mutations in ATTR.^[104] In particular, the most common mutation in patients with mTTR amyloidosis is Val30Met variant and it is an established fact that patients carrying this variant may benefit from early liver transplantation and life expectancy is very good in these patients.^[105] In these patients, combined liver and heart transplantation may be a treatment option in the presence of severe cardiac involvement.^[106]

Heart transplantation followed by autologous stem cell transplantation may be a rational treatment choice in the presence of severe heart failure in patients with AL amyloidosis who respond well to initial chemotherapy.^[107] However, other organ involvement should be minimal despite the presence of severe, isolated cardiac disease and a plasma cell clone that respond well to chemotherapy is needed. In modern series, this approach may provide a life expectancy similar to that in other patients.^[108]

Mechanical circulatory support devices are also used in patients with advanced cardiac amyloidosis. Although the use of these devices in patients with mTTR or wtTTR amyloidosis is technically possible, supporting evidence is not available in the literature.^[109] On the other hand mechanical support devices may increase 1-year survival up to 64% in selected patients with AL amyloidosis. However, prognosis is worst in patients with a left ventricular cavity diameter less than <46 mm.^[51]

Table 7. Major pharmacotherapies for TTR-amyloidosis

Mechanism of action	Generic name	Patient population	Current use
TTR stabilizers	Tafamidis	wtTTR & mTTR, FAP and CM	Strength of 20 mg is approved in the EU for the treatment of patients with stage 1 TTR-FAP, based on a phase 3 study. ^[129] Mortality data (for strengths of 20 mg and 80 mg) from a phase 3 study referred to as ATTR-ACT have been recently reported. In this study, tafamidis significantly reduced both overall mortality and cardiovascular hospitalization. ^[113]
	Diflunisal	wtTTR & mTTR, FAP and CM	A phase 3 study demonstrated that diflunisal (250 mg b.i.d.) maintained neuropathy impairment scores in patients with TTR-FAP (250 mg bid). ^[123] The open label study in wtTTR and mTTR CM is a short-term study with small sample size and emphasized the reduction in eGFR ^[125]
Agents acting on TTR production	Patisiran	FAP & mTTR-CM	Cardiac involvement was detected in 56% of patients with TTR-FAP in the randomized, placebo controlled phase 3 APOLLO study. Patisiran (0.3 mg/kg) exerted a positive impact on echo parameters and biomarkers. ^[137]
Agents acting on TTR production Antisense Oligonucleotide	Inotersen	wtTTR & mTTR, FAP and CM	A randomized placebo controlled study with a large sample size was conducted in patients with FAP and CM (NEURO-TTR) (cardiac involvement was detected in 63%): No deterioration was detected in echo parameters over 15 months. Inotersen was associated with a higher rate of thrombocytopenia and mortality. ^[139] wtTTR data are limited. ^[138]
ATTR amyloid fibril disrupters	Doxycycline + TUDCA	wtTTR & mTTR, FAP and CM	There are phase 2 studies reporting positive impacts of doxycycline 100 mg b.i.d. and TUDCA 250 mg t.i.d. on biomarkers and echo parameters. ^[124,140] Patients' compliance with treatment was limited due to adverse effects.

In conclusion, considering evidence-based medicine, although the role of ACE inhibitors, ARBs and beta blockers is established in HF, these medicines have no place in the empiric treatment of any types of cardiac amyloidosis. Discontinuation of these medicines should be considered particularly in patients with orthostatic or reduced cardiac output symptoms, in the absence of any other compelling indications. Empiric therapy may include the use of long-acting diuretic combinations to lower congestion, maintenance of sinus rhythm (amiodarone may be used^[110]) and thromboembolism prophylaxis in selected patients (all patients with AF, independently from scores). Favorable outcomes may be obtained with LVAD and/

or heart transplantation in highly selected patients with AL amyloidosis, with heart transplantation in relatively young patients with wtTTR amyloidosis and with combined heart and liver transplantation in highly selected patients with mTTR amyloidosis.

10.0 SPECIFIC THERAPIES FOR AMYLOIDOSIS – Barış İkitimur

Although cardiac amyloidosis has long been ignored due to either the progressive nature of the condition or the belief of having limited efficient treatment options, recent novelties have changed this situation. A reduction in precursor proteins that form amyloid

fibrils is essential for improving the prognosis in cardiac amyloidosis.^[43] Chemotherapy combinations reducing the level of free light-chain proteins may be used in AL-type amyloidosis while anti-fibril therapies acting by different mechanisms may be used for this purpose in TTR-amyloidosis (Table 7).

10.1 Treatment goals

AL-amyloidosis: The ultimate goal in AL amyloidosis is to normalize free light-chain concentrations and to eradicate monoclonal paraproteins in the blood and urine.^[80] Considering organs affected by AL amyloidosis, treatment goals should be to reduce markers of amyloid toxicity such as NT-proBNP levels and anatomical markers such as left ventricular wall thickness in patients with cardiac involvement.^[111] Complete or good partial hematological response and significant response in cardiac biomarkers (such as NT-proBNP) have been linked to a better survival in patients with AL amyloidosis.^[43]

TTR-amyloidosis: Treatments specific to TTR amyloidosis targets preventing and reversing organ dysfunction by acting on 3 stages of amyloid deposition. Stages of amyloid deposition include the production of TTR molecules, maintenance of TTR stabilization and removal of amyloid from tissues, while available and potential therapeutics are classified according to the stage they focus on.^[112] Even though therapies should ideally aim at improving major cardiac endpoints including amyloid TTR cardiomyopathy (ATTR-CM)-related mortality and heart failure (HF) related morbidity, studies testing the efficacy of these therapies are limited. Previous studies have focused on the levels of biomarkers (NT-proBNP, Troponin) which are indirect indicators of cardiac involvement and effects of the disease on the results from non-invasive studies (echocardiographic measurement of cardiac dimensions, strain imaging etc.).^[112] Studies reported in 2018 suggest the start of a new era where mortality and HF-related morbidity are of primary importance in the treatment of ATTR-CM.^[113]

Treatment of AL-amyloidosis

The first-line treatment of AL-type amyloidosis includes alkylating agents (e.g. Melphalan) and proteasome inhibitor bortezomib.^[80] In a retrospective study in AL amyloidosis patients with cardiac involvement and symptomatic heart failure (57% NYHA III-IV) (n=106) three-drug therapy with bortezomib + dexamethasone + an alkylating agent (cyclophosphamide

or melphalan). (BDex+AA) was compared to other treatments, with a median follow-up duration of 465 days and mortality rates with BDex+AA regimen was found to be lower compared to other treatments (48% [median overall survival 821 days] vs. 65% [median overall survival 223 days], $p=0.029$).^[114] A multivariate analysis revealed an association between decreased mortality and BDex+AA administered as a first-line treatment of AL-type amyloidosis in patients with HF (HR: 0.209, %95 CI: 0.069 to 0.636; $p=0.006$). However, it should be kept in mind that NT-proBNP levels higher than 8500 ng/L and advanced cardiac involvement are associated with lower response and survival rates in AL-type amyloidosis even in patients treated with cyclophosphamide + bortezomib+ dexamethasone (CyBorD) regimen.^[115]

Most recent novel treatments of AL amyloidosis include second generation oral proteasome inhibitors ixazomib and carfilzomib, an anti-plasma cell antibody daratumumab, anti-amyloid fibril monoclonal antibody NEOD001 and anti-SAP antibodies developed for the treatment of TTR amyloidosis.^[80] None of these medicines have been studied in patients with AL-cardiac amyloidosis, in placebo controlled, randomized studies with endpoints testing major cardiac events. Ongoing studies in patients with AL-cardiac amyloidosis include TOURMALINE-AL1 (ixazomib, NCT01659658) and NCT028841033 (daratumumab).^[116]

10.2 Specific treatment for TTR amyloidosis

1) TTR stabilizers

TTR is a plasma protein composed of four identical monomers and a carrier of thyroxine and retinol. In TTR amyloidosis, TTR tetramer instability is believed to be responsible for the deposition of fibrils in many tissues, including the heart.^[117] As a consequence of instability, dissociation into monomers results in aggregation into amyloid fibrils that form TTR amyloid deposits. Dissociation of TTR has been considered to be the rate-limiting step of this process.^[118] This mechanism has been accepted as a treatment target after the discovery that a benign polymorphism (Thr119Met) may stabilize TTR, even in the presence of mutations such as Val30Met which normally lead to the formation of amyloid fibrils.^[119,120] Small molecules that are considered as potential stabilizers of TTR tetramer include diflunisal, a non-steroidal anti-inflammatory drug (NSAID), and tafamidis, an analog of diflunisal

without NSAID properties: only these molecules have been shown to be safe and effective in animal studies and human trials.^[121]

Diffunisal: Diflunisal is a NSAID that ensures the maintenance of TTR stability by binding to thyroxine binding sites in TTR. TTR-stabilizing activity of diflunisal has been shown both in animal studies and human trials.^[112,122] As with other medicines specifically used in the treatment of TTR, diflunisal has been first used in patients with ATTR-FAP. A randomized, double blind study in patients with clinical diagnosis of ATTR-FAP (n=130) compared neuropathy impairment scores and quality of life in patients receiving diflunisal at a dose of 250 mg BID to patients receiving placebo.^[123] In this study, diflunisal significantly reduced the progression of neurological deterioration and maintained the quality of life. Although 50% of study patients probably had amyloid CM based on echocardiographic findings at baseline, no significant alterations occurred in echocardiography parameters over time.^[122]

Unlike its use in ATTR-FAP, the use of diflunisal in ATTR-CM has some drawbacks, as this medicine is a NSAID. Diflunisal has potential gastrointestinal and renal side effects as it inhibits cyclooxygenase (COX)-1 and 2 and furthermore, water and salt retention caused by diflunisal may lead to hypertension and may contribute to the pathophysiology of ATTR-CM leading to further deterioration that should be taken into consideration.^[124] A cohort study conducted in 2012 by Castano et al. may give a clue regarding this issue. In this study, 13 patients with ATTR-CM or ATTR-CM treated with diflunisal at a dose of 250 mg BID were followed-up for 0.9±0.3 years.^[125] No alterations were observed in echocardiographic parameters such as left ventricular mass, EF and cardiac biomarkers such as Troponin I and BNP whereas a reduction of 6% (in correlation with treatment duration) was observed in eGFR. Treatment was discontinued in a patient and diflunisal dose was halved in another patient due to volume overload, indicating a need for close monitoring in patients receiving diflunisal.

Tafamidis: Tafamidis is a benzoxazole derivative without NSAID properties and has a good oral bio-availability. Tafamidis binds to transthyretin at the thyroxine-binding sites and ensures kinetic stabilization of circulating tetramers in a dose-dependent fashion and prevents the release of TTR tetramers necessary for amyloidogenesis.^[118,121,126]

The use of tafamidis to ensure stability of serum TTR and relevant clinical outcomes in TTR amyloidosis were first studied mainly in patients with TTR-familial amyloid polyneuropathy (TTR-FAP).^[116] Tafamidis given orally at a dose of 20 mg stabilized TTR in 98% of patients and patients treated with tafamidis demonstrated 52% less neurological deterioration vs. placebo with a side effect profile similar to placebo, in this 18-month study of tafamidis treatment in patients with early-stage V30M transthyretin familial amyloid polyneuropathy (TTR-FAP).^[127]

In the 12-month, open label extension of this study, neurological deterioration process also slowed in patients who had switched from placebo to tafamidis.^[128] These findings led to the approval of tafamidis in the EU for the treatment of patients with Grade I TTR-FAP.^[129]

The effects of 12-month treatment with tafamidis (20 mg) on TTR stability, quality of life, neurological performance, biomarkers such as Troponin and NT-proBNP and echocardiographic findings were investigated in symptomatic patients (62% cardiac amyloidosis) with non-Val30Met and non-Val122Ile TTR amyloidosis, in a 12-month, open label study with small sample size (n=21). At the end of the study, tafamidis provided TTR stability in 94.7% of patients and clinically significant cardiac disease progression or alterations in biomarkers or echocardiographic findings were not found.^[130,131]

Studies of tafamidis in patients with TTR-FAP were followed by studies of tafamidis in patients with amyloid ATTR-CM.^[116] An open-label, phase 2 study investigated the effects of 12-month treatment with oral tafamidis at a dose of 20 mg daily on the progression of ATTR-CM in patients predominantly with wtTTR-CM (n=35). In this study, tafamidis stabilized TTR at a rate of 96.8% and clinical progression (death, cardiovascular hospitalization, AF, an increase of >1000 pg/mL at the level of NT-proBNP, an increase of >0.5 mg/dL at serum creatinine level, a reduction of >50m in 6-minute walk distance) was detected in 48.4% of patients over a 12-month treatment period. Although this study did not include a placebo arm, 12-month rate of progression was found to be lower than the 12-month-rate of clinical progression (72.4%) reported from TRACS study for the natural course in patients with wtTTR amyloidosis.^[132]

A more recent, retrospective, single-center study on the use of stabilizers in patients with ATTR-CM (wtATTR and mATTR) (n=120) patients who were treated with tafamidis (n=16) or diflunisal (n=13) were compared to those who were not treated with stabilizers (n=91).^[121] In this study, the risk of the combined endpoint of death or heart transplantation was found to be lower in patients treated with TTR stabilizers compared to those who were not treated with TTR stabilizers (HR 0.32, 95% CI 0.18 to 0.58, $p < 0.0001$). It should be noted that in the Multivariable Cox analysis, the association between stabilizer and combined endpoint persisted even when adjusted for all non-collinear univariate predictors (HR 0.37, 95% CI 0.19-0.75, $p = 0.003$).

An association between death and TTR stabilizers was detected for the first time in this study and these results further emphasized the need for the confirmation of such associations in randomized studies.

Tafamidis in the ATTR-ACT Study: As with any potential treatment specifically addressing ATTR-CM, tafamidis had not been investigated in a placebo-controlled, double blind, randomized clinical trial with appropriate sample size of tafamidis, until recently. ATTR-ACT was a multicenter, international, double-blind, phase 3 study conducted in patients with ATTR-CM to investigate the effect of tafamidis 20 mg and 80 mg on the clinical primary endpoint of all-cause death and cardiovascular hospitalization over 30 months, in comparison with placebo. Secondary endpoints included change from the baseline in Kansas City Cardiomyopathy Questionnaire scores, 6-minute Walk Test, and in parameters such as NYHA class, NT-proBNP and Troponin I levels. In addition, echocardiography and ECG and TTR stability were also assessed. Eligibility criteria included biopsy-confirmed TTR-CM, the presence of either wtTTR or mTTR amyloid deposits, age between 18 and 90 years, clinical evidence of HF on diuretics or prior hospitalization for heart failure. The presence of cardiac TTR was confirmed by ^{99m}Tc-labeled pyrophosphate, hydroxymethylene diphosphate or 2-propanodicarboxylic acid scintigraphy. Furthermore, an end-diastolic interventricular septum thickness greater than 12 mm on echocardiography was considered as an indicator of cardiac involvement.

Patients who were considered to be less likely to benefit from treatment were excluded from the study as they were required a 6-minute walk test (6MWT)

of >100 meters. Another inclusion criterion was having an elevated NT-proBNP level (≥ 600 pg/mL).

Exclusion criteria included AL-type amyloidosis, an estimated GFR of < 25 mL/min/1.73 m², concurrent treatment with NSAIDs, doxycycline +TUDCA, calcium channel blockers or digitalis.^[133]

A total of 441 patients were included in the ATTR-ACT study and 264 out of 441 patients received tafamidis and 177 patients received placebo, 76.1% of patients in the Tafamidis Group had wtTTR amyloidosis and 23.9% had mTTR amyloidosis. The rate of patients with wtTTR amyloidosis was reported to be 75.7% in the placebo group. All-cause mortality rate was found to be significantly lower in patients receiving tafamidis vs. placebo over the follow-up period (29.5% vs 42.9%; HR,0.70; 95% confidence interval, 0.51–0.96; $p < 0.001$). The risk for cardiovascular hospitalization was also significantly lower in patients receiving tafamidis vs. placebo (Relative Risk: 0.68; 96% confidence interval, 0.56–0.81). The prevalence of wtTTR amyloidosis that reached 13% among patients with HF with preserved ejection fraction (pEF) further emphasized the importance of these mortality data, as stated by the study authors.^[133] Both mortality and hospitalization assessments favored tafamidis in predetermined subgroups (TTR type, NYHA class, tafamidis dose) with the exception of patients with NYHA Class III HF. No statistically significant differences were observed between the Tafamidis Group and Placebo Group in survival of patients who had NYHA Class III HF at baseline, whereas hospitalization rate was higher among patients receiving tafamidis vs. placebo. The authors suggested that this finding might be attributable to longer survival during a more severe period of the disease leading to an increased need for hospitalizations. This finding is believed to emphasize the importance of earlier diagnosis and treatment of the disease.^[133] The analysis for secondary endpoints revealed a reduction in the increase at levels of NT-proBNP with treatment with tafamidis, while the decline in the distance walked during the 6-minute test was reduced in patients treated with tafamidis compared to placebo. Moreover, Tafamidis also reduced the decline in Kansas City Cardiomyopathy Questionnaire scores, compared with placebo, suggesting a positive impact of tafamidis on HF morbidity.^[133]

Both doses of tafamidis used in the ATTR-ACT study significantly reduced mortality and the risk

for hospitalization. Another remarkable result of the study was that no significant interactions were found between TTR-types (wtTTR or mTTR) and treatment. The study reported that the safety profiles of tafamidis and placebo were similar based on the assessment of adverse effects; adverse events previously reported in patients with familial amyloid polyneuropathy, such as diarrhea and urinary tract infections were less common in patients who received tafamidis than patients who received placebo.^[113]

ATTR-ACT investigators reported that positive impacts (functional capacity, Kansas City Cardiomyopathy questionnaire results) of Tafamidis on HF morbidity became prominent at month 6, whereas survival difference favored tafamidis after 18-month treatment.^[113]

As this study was the first large, randomized, placebo-controlled study demonstrating significant effects of a specific medical treatment on mortality and morbidity in patients ATTR-CM, its results are expected to have a significant impact on clinical practice.

Tolcapone: Tolcapone is a catechol-O-methyltransferase inhibitor indicated in the treatment of Parkinson's disease as it increases the bioavailability of levodopa and carbidopa: In vitro studies have been conducted based on predicted affinity of tolcapone for TTR and these studies have demonstrated that tolcapone might strongly inhibit TTR aggregation.^[116] The results from a phase 2 study of tolcapone (NCT 02191826) in patients with ATTR polyneuropathy are expected to provide an understanding of safety of tolcapone, particularly when considering potential hepatic adverse effects associated with long-term use of tolcapone.

AG10: AG10 is believed to reduce the risk for amyloid deposition by decreasing TTR dissociation and stabilizing both wtTTR and TTRm molecules in the serum of patients with ATTR-CM. The results from ongoing phase 1 study (NCT 03294707) of AG10 are expected to be reported.^[112]

2) Medicines acting on the production of TTR

Treatment modalities to be used in patients with TTR amyloidosis include small interfering

RNA (siRNA) that inhibits TTR production such as patisiran and antisense oligonucleotides (ASO) such as inotersen.^[134]

Patisiran and Revusiran: Inhibition of TTR Gene Expression by siRNA: Patisiran (ALN-TTR02) is the double-stranded siRNA (ds-siRNA) that reaches to the liver within lipid nanoparticles to bind to usually untranslated conserved mRNA sequences. Degradation of both wtTTR and mTTR mRNAs in this way results in a reduction in the amount of synthesized TTR, leading to a reduced risk of formation of deposits by monomers.^[134,135] A phase 2 study demonstrated that patisiran could reduce TTR protein in a dose-dependent fashion in patients with mTTR amyloidosis.^[136]

In APOLLO study, patisiran provided significant improvements in clinical endpoints of neuropathy at the end of 18-month follow up in patients with hereditary amyloid neuropathy who were treated with patisiran given intravenously every 3 weeks at a dose of 3 mg per kg of body weight compared to those treated with placebo.^[137] Patients with NYHA III or IV HF were excluded from the study and patients were followed up by echocardiography and NT-proBNP levels over the study duration. An 81% reduction was observed in TTR levels at month 18 in patients who received active treatment, whereas 126 (56%) out of 225 patients in the APOLLO study were included in the subgroup characterized by cardiac involvement. In this subgroup the ratio of the NT-proBNP level at month 18 to the level at baseline was 0.89 in patients receiving patisiran and this ratio was 55% better than those receiving placebo (Rate Ratio, 0.45; $p < 0.001$). Left ventricular mass index was decreased in patients receiving patisiran compared to those receiving placebo (-1.0 ± 0.2 mm vs -0.1 ± 0.3 mm, $p = 0.02$) and there was a significant difference in left ventricular % longitudinal strain, in favor of patisiran (change from the baseline: 0.08 ± 0.28 vs 1.46 ± 0.48 , $p = 0.02$) in the subgroup of patients with cardiac involvement.

No differences were found between patisiran and placebo in serious cardiac adverse effects and HF events. Another consideration was that negative signals such as thrombocytopenia and decreased renal function associated with oligonucleotide drugs were not observed with patisiran.

Experience with first generation siRNA revusiran in patients is not as promising as with patisiran.^[135] After demonstrating that revusiran may effectively decrease TTR levels in patients with mTTR amyloidosis in a phase 2 study, a placebo controlled phase 3 study ENDEAVOUR (NCT02319005) assessing the

effects of Revusiran on 6-minute walk test and serum TTR levels in patients with mTTR-CM (n=206) was discontinued early due to the increased mortality rates and lactic acidosis.^[112]

Inotersen - Antisense Oligonucleotides (ASO): Antisense oligonucleotides are synthetic nucleotide sequences blocking protein translation by binding to and degrading mRNA. ASOs synthesized to target TTR mRNA can be expected to act on both mTTR and wtTTR.^[134] Inotersen is an ASO synthesized to target TTR amyloid and its efficacy in reducing hepatic TTR production and its safety were tested in a 1-year study in patients with biopsy-confirmed ATTR (mTTR and wtTTR) deposition, HF and left ventricular hypertrophy (n=22) who received inotersen SC weekly at a dose of 300 mg.^[138] Inotersen provided an effective and sustained reduction in TTR production, whereas a 20 to 35% reduction was observed in platelet counts. Any alterations consistent with disease progression were not observed in echocardiographic parameters such left ventricular mass and interventricular septum thickness in this non-placebo controlled study conducted in limited number of patients.

An international, randomized, double-blind, placebo-controlled study (NEURO-TTR) was designed to investigate the effects of inotersen on neuropathy impairment scores and quality of life in patients with hereditary amyloidosis with polyneuropathy (n=172).^[139] This recent 15-month study reported that inotersen exerted significantly favorable effects on both neuropathy impairment scores and quality of life and decreased serum TTR levels by a mean of 74%.

Patients with NYHA III and IV HF were not included in this study and 63% of patients had mTTR-CM, while the rate of patients with cardiomyopathy was greater and known disease duration was longer in the inotersen group, at baseline. A difference favoring investigational product over placebo occurred in neurological scores and quality of life, in the CM group. However, no significant differences were found between the inotersen group and the placebo in echocardiographic parameters, including global longitudinal strain. Among patients treated with inotersen in NEURO-TTR study, 3% developed glomerulonephritis and 3% developed thrombocytopenia, with platelet count less than 25.000/mm³. The prevalence of thrombocytopenia (<140.000/mm³) was higher in the inotersen group compared to the placebo group (54% vs. 13%) with one death resulting from intra-

cranial hemorrhage. It should be noted that all of 5 deaths that occurred over the study period were in the inotersen group.

3) Medicines removing TTR-amyloid fibrils from tissues:

The very stable structure of amyloid deposits in tissues does not allow human organism to spontaneously degrade and remove these deposits. Doxycycline and tauroursodeoxycholic acid, epigallocatechin-3-gallate (EGCG) extracted from green tea and antibodies synthesized to target TTR are among therapies that are believed to have the potential to facilitate the clearance of TTR amyloid fibrils that deposit in the heart.^[124]

Doxycycline + tauroursodeoxycholic acid (TUDCA): A phase 2 open label study was designed to monitor the progression of neuropathy and cardiomyopathy over 12 months of treatment with doxycycline 100mg b.i.d. and TUDCA 250 mg t.i.d. in 20 patients with systemic amyloidosis with TTRm amyloidosis predominance, after the demonstration of the activity of doxycycline in disrupting amyloid fibrils and synergistic effect of co-administration of doxycycline and the bile salt TUDCA on fibril removal in amyloid deposits in animal models.^[124,140]

Any clinical progression in cardiac involvement was not reported and neuropathy impairment scores remained substantially stable. Progression was not reported in echocardiographic findings (the mean left ventricular wall thickness). However, there are concerns about the tolerability of this combination as only 7/20 patients completed 12 months of treatment. The doxycycline + TUDCA regimen reduced the deterioration of left ventricular longitudinal strain compared to the placebo, in a phase 2 study (NCT 1855360) conducted by Falk et al. in 30 patients with ATTR-CM (27 wtATTR, 3 mTTR) over a treatment period of 18 months.^[124] In another open, prospective phase 2 trial designed by Merlini et al. (NCT 01171859) a total of 45 patients with TTR amyloidosis (wtTTR and mTTR), including 35 patients with cardiac involvement were treated with doxycycline plus TUDCA over 12 months and lower NT-proBNP levels and a lesser deterioration in the left ventricular strain parameters were reported in the treatment group. Results from this study and many other studies suggest that the main problem associated with doxycycline plus TUDCA regimen is the poor tolerability and subsequent early treatment discontinuation.^[124]

Epigallocatechin-3 gallate (EGCG): EGCG is most abundant in green tea and has reduced amyloid formation and has increased the elimination of existing amyloid deposits in vitro and in animal models. In an observational study, 600 mg of EGCG delivered as capsules over 12 months stabilized the left ventricular mass in patients with wtATTR-cardiac amyloidosis (n=25) based on cardiac MRI findings.^[141]

Anti-Serum Amyloid P (anti-SAP) Antibody Component and CPHPC: Serum amyloid P (SAP) component is a glycoprotein found in all types of amyloid fibrils and has an important role in fibril formation. Therefore, treatments targeting SAP are more likely to be beneficial both in AL-type amyloidosis and TTR-amyloidosis and this makes SAP an attractive treatment target.^[116] Although CPHPC is effective to remove circulating SAP via hepatic elimination by cross-linking SAP molecules, it has minimal effect on existing amyloid deposits in human. An anti-SAP humanized monoclonal antibody has been developed to address this issue and the use of this antibody in combination with CPHPC is believed to promote amyloid clearance from the liver and spleen.

In a study in patients with AL- and AA- types amyloidosis without cardiac involvement (n=15), 6 weeks of treatment with CPHPC + anti-SAP antibody reduced hepatic amyloid deposition, as measured by scintigraphy.^[142] Another open-label phase-2 study has been designed to assess the efficacy of this treatment in patients with AL-type and TTR amyloidosis with cardiac involvement and is still ongoing (NCT03044353).

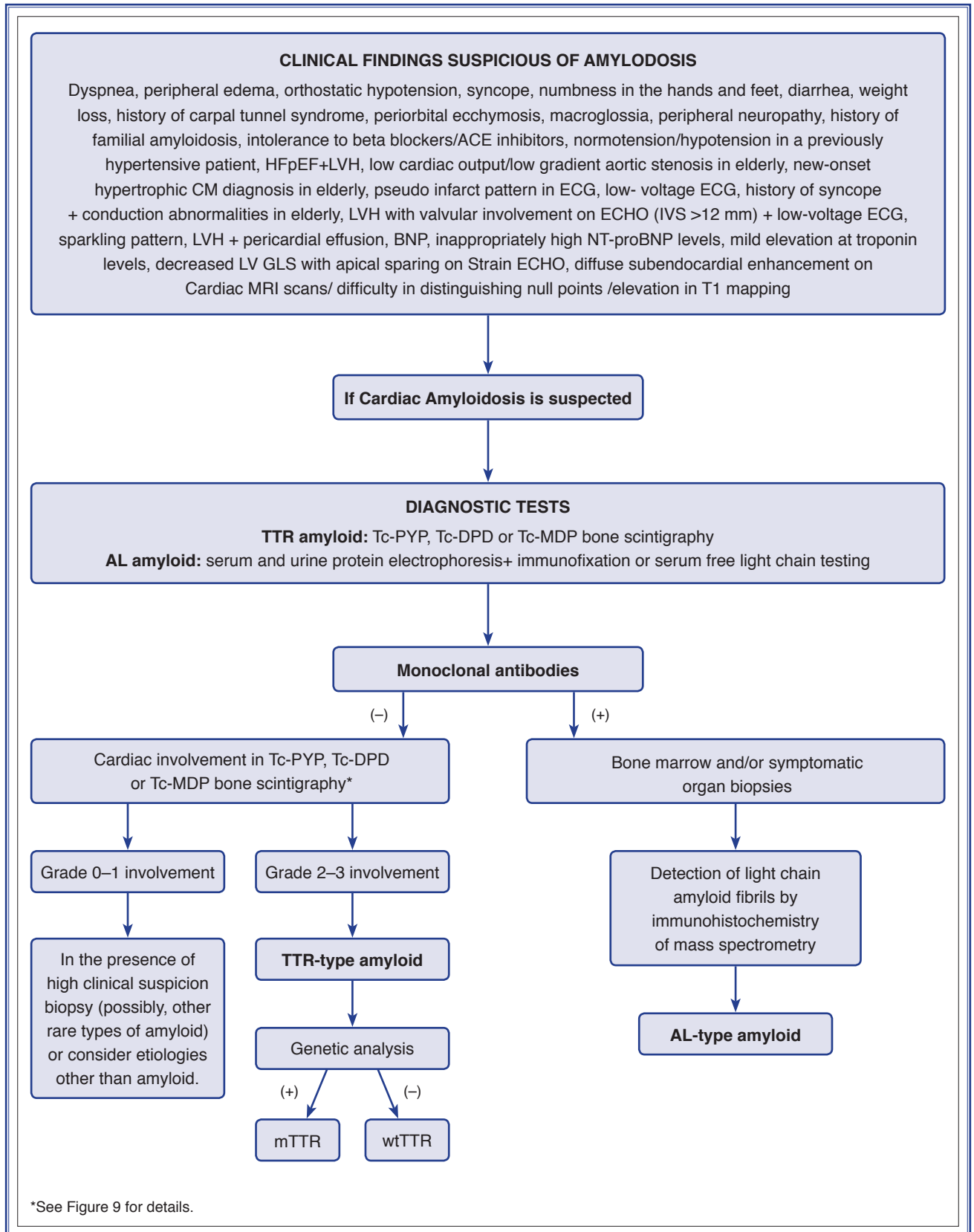
PRX004: PRX004 is a monoclonal antibody facilitating the phagocytosis of misfolded TTR by binding the misfolded TTR without interacting with native TTR. A dose escalation study of PRX004 is planned to be conducted patients with TTR amyloidosis (NCT 03336580).^[112]

10.3 Future expectations

The demonstration of the effects of specific treatments in patients with TTR- cardiac amyloidosis paves the way for the use of specific medicines such as tafamidis in routine clinical practice. Potential effects of combined use of treatments with different mechanisms of action, determination of eligible patients and the method of administration are among the issues to be resolved in the future.

Discovery and validation of non-invasive markers will be a guiding light for clinicians to determine whether or not treatment responses are adequate.^[134] Many medicines (doxycycline plus TUDCA, AG10, tolcapone, EGCEG, anti-SAP antibody and CPHPC, PRX004) under development have not reached phase 3 yet or clinical trials have not been designed as placebo controlled, randomized, double blind studies with adequate sample size, to test major endpoints such as mortality (patisiran, inotersen). When it comes to TTR amyloidosis in particular, many medicines under development are first tested in overall population with amyloidosis or in the FAP population and their effects on amyloid cardiomyopathy are typically limited to secondary endpoints. Particularly, upon the initiation of studies investigating the prevalence of wtTTR underlying the pathophysiology of heart failure with preserved ejection fraction (pEF), many patients that have been deprived from targeted treatment before, find a chance to benefit from specific treatments for amyloidosis. Significant changes should be expected in the treatment of patients with CM and HF, with future phase 4 studies of medicines such as tafamidis conducted in this patient population as well as with studies conducted to test major cardiac endpoints in patients with CM, including those with HFpEF, using medicines at earlier stages of development.

11.0 CONSENSUS ALGORITHM FOR THE DIAGNOSIS



References

1. Parry TL, Melehan JH, Ranek MJ, Willis MS. Functional amyloid signaling via the inflammasome, necrosome, and signalosome: new therapeutic targets in heart failure. *Front Cardiovasc Med* 2015;2:25.
2. Sipe JD, Cohen AS. Review: history of the amyloid fibril. *J Struct Biol* 2000;130:88–98.
3. Guan J, Mishra S, Falk RH, Liao R. Current perspectives on cardiac amyloidosis. *Am J Physiol Heart Circ Physiol* 2012;302:H544–52.
4. Mankad AK, Shah KB. Transthyretin cardiac amyloidosis. *Curr Cardiol Rep* 2017;19:97.
5. Gertz MA, Dispenzieri A, Sher T. Pathophysiology and treatment of cardiac amyloidosis. *Nat Rev Cardiol* 2015;12:91–102.
6. Gertz MA. Immunoglobulin light chain amyloidosis diagnosis and treatment algorithm 2018. *Blood Cancer J* 2018;8:44.
7. Milani P, Merlini G, Palladini G. Light chain amyloidosis. *Mediterr J Hematol Infect Dis* 2018;10:e2018022.
8. Saraiva MJ. Transthyretin mutations in health and disease. *Hum Mutat* 1995;5:191–6.
9. Sattianayagam PT, Hahn AF, Whelan CJ, Gibbs SD, Pinney JH, Stangou AJ, et al. Cardiac phenotype and clinical outcome of familial amyloid polyneuropathy associated with transthyretin alanine 60 variant. *Eur Heart J* 2012;33:1120–7.
10. Gonzalez-Lopez E, Gallego-Delgado M, Guzzo-Merello G, de Haro-Del Moral FJ, Cobo-Marcos M, Robles C, et al. Wild-type transthyretin amyloidosis as a cause of heart failure with preserved ejection fraction. *Eur Heart J* 2015;36:2585–94.
11. Rapezzi C, Quarta CC, Obici L, Perfetto F, Longhi S, Salvi F, et al. Disease profile and differential diagnosis of hereditary transthyretin-related amyloidosis with exclusively cardiac phenotype: an Italian perspective. *Eur Heart J* 2013;34:520–8.
12. Pukitis A, Zake T, Groma V, Ostrovskis E, Skuja S, Pokrotnieks J. Effect of infliximab induction therapy on secondary systemic amyloidosis associated with Crohn's disease: case report and review of the literature. *J Gastrointest Liver Dis* 2013;22:333–6.
13. Louros NN, Iconomidou VA, Tsiolaki PL, Chrysina ED, Baltatzis GE, Patsouris ES, Hamodrakas SJ. An N-terminal proatrial natriuretic peptide (NT-proANP) 'aggregation-prone' segment involved in isolated atrial amyloidosis. *FEBS Lett* 2014;588:52–7.
14. Poddaturi V, Armstrong DR, Hitchcock MA, Roberts WC, Guileyardo JM. Isolated atrial amyloidosis and the importance of molecular classification. *Proc (Bayl Univ Med Cent)* 2013;26:387–9.
15. Mohammed SF, Mirzoyev SA, Edwards WD, Dogan A, Grogan DR, Dunlay SM, et al. Left ventricular amyloid deposition in patients with heart failure and preserved ejection fraction. *JACC Heart Fail* 2014;2:113–22.
16. Tanskanen M, Peuralinna T, Polvikovski T, Notkola IL, Sulkaava R, Hardy J, et al. Senile systemic amyloidosis affects 25% of the very aged and associates with genetic variations in alpha2-macroglobulin and tau: a population-based autopsy study. *Ann Med* 2008;40:232–9.
17. Lie JT, Hammond PI. Pathology of the senescent heart: anatomic observations on 237 autopsy studies of patients 90 to 105 years old. *Mayo Clin Proc* 1988;63:552–64.
18. Wechalekar AD, Gillmore JD, Hawkins PN. Systemic amyloidosis. *Lancet* 2016;387:2641–54.
19. Kyle RA, Linos A, Beard CM, Linke RP, Gertz MA, O'Fallon WM, et al. Incidence and natural history of primary systemic amyloidosis in Olmsted County, Minnesota, 1950 through 1989. *Blood* 1992;79:1817–22.
20. Pinney JH, Smith CJ, Taube JB, Lachmann HJ, Venner CP, Gibbs SD, et al. Systemic amyloidosis in England: an epidemiological study. *Br J Haematol* 2013;161:525–32.
21. Hemminki K, Li X, Försti A, Sundquist K. Incidence and survival in non-hereditary amyloidosis in Sweden. *BMC Public Health* 2012;12:974.
22. Connors LH, Prokaeva T, Lim A, Théberge R, Falk RH, Doros G, et al. Cardiac amyloidosis in African Americans: comparison of clinical laboratory features of transthyretin V122I amyloidosis and immunoglobulin light chain amyloidosis. *Am Heart J* 2009;158:607–14.
23. Rapezzi C, Merlini G, Quarta CC, Riva L, Longhi S, Leone O, et al. Systemic cardiac amyloidosis: disease profiles and clinical courses of the 3 main types. *Circulation* 2009;120:1203–12.
24. Grogan M, Scott CG, Kyle RA, Zeldenrust SR, Gertz MA, Lin G, et al. Natural history of wild-type transthyretin cardiac amyloidosis and risk stratification using a novel staging system. *J Am Coll Cardiol* 2016;68:1014–20.
25. Ruberg FL, Maurer MS, Judge DP, Zeldenrust S, Skinner M, Kim AY, et al. Prospective evaluation of the morbidity and mortality of wild-type and V122I mutant transthyretin amyloid cardiomyopathy: the Transthyretin Amyloidosis Cardiac Study (TRACS). *Am Heart J* 2012;164:222–8.
26. Maurer MS, Hanna M, Grogan M, Dispenzieri A, Witteles R, Drachman B, et al. Genotype and phenotype of transthyretin-related cardiac amyloidosis in the United States: a report from the Transthyretin Amyloid Outcome Survey (THAOS). *J Am Coll Cardiol* 2016;68:161–72.
27. Wechalekar AD, Schonland SO, Kastiris E, Gillmore JD, Dimopoulos MA, Lane T, et al. European collaborative study of treatment outcomes in 346 patients with cardiac stage III AL amyloidosis. *Blood* 2013;121:3420–7.
28. Palladini G, Barassi A, Klersy C, Pacciolla R, Milani P, Sarais G, et al. The combination of high-sensitivity cardiac troponin T (hs-cTnT) at presentation and changes in N-terminal natriuretic peptide type B (NT-proBNP) after chemotherapy best predicts survival in AL amyloidosis. *Blood* 2010;116:3426–30.

29. Kumar S, Dispenzieri A, Lacy MQ, Hayman SR, Buadi FK, Colby C, et al. Revised prognostic staging system for light chain amyloidosis incorporating cardiac biomarkers and serum free light chain measurements. *J Clin Oncol* 2012;30:989–95.
30. Palladini G, Dispenzieri A, Gertz MA, Kumar S, Wechalekar A, Hawkins PN, et al. New criteria for response to treatment in immunoglobulin light chain amyloidosis based on free light chain measurement and cardiac biomarkers: impact on survival outcomes. *J Clin Oncol* 2012;30:4541–9.
31. Kholová I, Niessen HW. Amyloid in the cardiovascular system: a review. *J Clin Pathol* 2005;58:125–33.
32. Gertz MA, Lacy MQ, Dispenzieri A. *Hematol Oncol Clin North Am* 1999;13:1211–33.
33. Dubrey SW, Hawkins PN, Falk RH. Amyloid diseases of the heart: assessment, diagnosis, and referral. *Heart* 2011;97:75–84.
34. Chamarthi B, Dubrey SW, Cha K, Skinner M, Falk RH. Features and prognosis of exertional syncope in light-chain associated AL cardiac amyloidosis. *Am J Cardiol* 1997;80:1242–5.
35. Kristen AV, Dengler TJ, Hegenbart U, Schonland SO, Goldschmidt H, Sack FU, et al. Prophylactic implantation of cardioverter-defibrillator in patients with severe cardiac amyloidosis and high risk for sudden cardiac death. *Heart Rhythm* 2008;5:235–40.
36. Ridolfi RL, Bulkley BH, Hutchins GM. The conduction system in cardiac amyloidosis. Clinical and pathologic features of 23 patients. *Am J Med* 1977;62:677–86.
37. Reisinger J, Dubrey SW, Lavalley M, Skinner M, Falk RH. Electrophysiologic abnormalities in AL (primary) amyloidosis with cardiac involvement. *J Am Coll Cardiol* 1997;30:1046–51.
38. Al Suwaidi J, Velianou JL, Gertz MA, Cannon RO 3rd, Higanos ST, Holmes DR Jr, Lerman A. Systemic amyloidosis presenting with angina pectoris. *Ann Intern Med* 1999;131:838–41.
39. Navarro JF, Rivera M, Ortuño J. Cardiac tamponade as presentation of systemic amyloidosis. *Int J Cardiol* 1992;36:107–8.
40. Coelho T, Maurer MS, Suhr OB. THAOS - The Transthyretin Amyloidosis Outcomes Survey: initial report on clinical manifestations in patients with hereditary and wild-type transthyretin amyloidosis. *Curr Med Res Opin* 2013;29:63–76.
41. Feng D, Edwards WD, Oh JK, Chandrasekaran K, Grogan M, Martinez MW, et al. Intracardiac thrombosis and embolism in patients with cardiac amyloidosis. *Circulation* 2007;116:2420–6.
42. Visconti L, Cernaro V, Ferrara D, Lacava V, Ricciardi CA, Di Mauro E, et al. Periorbital purpura: a pathognomonic but late sign of AL amyloidosis. *G Ital Nefrol* 2015;32. pii: gin/32.5.8.
43. Maurer MS, Elliott P, Comenzo R, Semigran M, Rapezzi C. Addressing Common Questions Encountered in the Diagnosis and Management of Cardiac Amyloidosis. *Circulation* 2017;135:1357–77.
44. Dharmarajan K, Maurer MS. Transthyretin cardiac amyloidosis in older North Americans. *J Am Geriatr Soc* 2012;60:765–74.
45. Hörnsten R, Pennlert J, Wiklund U, Lindqvist P, Jensen SM, Suhr OB. Heart complications in familial transthyretin amyloidosis: impact of age and gender. *Amyloid* 2010;17:63–8.
46. Ng B, Connors LH, Davidoff R, Skinner M, Falk RH. Senile systemic amyloidosis presenting with heart failure: a comparison with light chain-associated amyloidosis. *Arch Intern Med* 2005;165:1425–9.
47. Lousada I, Comenzo RL, Landau H, Guthrie S, Merlini G. Light chain amyloidosis: patient experience survey from the Amyloidosis Research Consortium. *Adv Ther* 2015;32:920–8.
48. Cyrille NB, Goldsmith J, Alvarez J, Maurer MS. Prevalence and prognostic significance of low QRS voltage among the three main types of cardiac amyloidosis. *Am J Cardiol* 2014;114:1089–93.
49. Mussinelli R, Salinaro F, Alogna A, Boldrini M, Raimondi A, Musca F, et al. Diagnostic and prognostic value of low QRS voltages in cardiac AL amyloidosis. *Ann Noninvasive Electrocardiol* 2013;18:271–80.
50. Carroll JD, Gaasch WH, McAdam KP. Amyloid cardiomyopathy: characterization by a distinctive voltage/mass relation. *Am J Cardiol* 1982;49:9–13.
51. Falk RH, Alexander KM, Liao R, Dorbala S. AL (Light-Chain) Cardiac amyloidosis: a review of diagnosis and therapy. *J Am Coll Cardiol* 2016;68:1323–41.
52. Zhao L, Fang Q. Recent advances in the noninvasive strategies of cardiac amyloidosis. *Heart Fail Rev* 2016;21:703–21.
53. Perfetto F, Bergesio F, Grifoni E, Fabbri A, Ciuti G, Frusconi S, et al. Different NT-pro BNP circulating levels for different types of cardiac amyloidosis. *J Cardiovasc Med (Hagerstown)* 2016;17:810–7.
54. Shi J, Guan J, Jiang B, Brenner DA, Del Monte F, Ward JE, et al. Amyloidogenic light chains induce cardiomyocyte contractile dysfunction and apoptosis via a non-canonical p38alpha MAPK pathway. *Proc Natl Acad Sci U S A* 2010;107:4188–93.
55. Brenner DA, Jain M, Pimentel DR, Wang B, Connors LH, Skinner M, et al. Human amyloidogenic light chains directly impair cardiomyocyte function through an increase in cellular oxidant stress. *Circ Res* 2004;94:1008–10.
56. Katzmann JA, Kyle RA, Benson J, Larson DR, Snyder MR, Lust JA, et al. Screening panels for detection of monoclonal gammopathies. *Clin Chem* 2009;55:1517–22.
57. Abraham RS, Katzmann JA, Clark RJ, Bradwell AR, Kyle RA, Gertz MA. Quantitative analysis of serum free light chains. A new marker for the diagnostic evaluation of prima-

- ry systemic amyloidosis. *Am J Clin Pathol* 2003;119:274–8.
58. Palladini G, Milani P, Foli A, Basset M, Russo F, Bosoni T, et al. The impact of renal function on the clinical performance of FLC measurement in AL amyloidosis. *Clin Chem Lab Med* 2016;54:939–45.
 59. Dispenzieri A, Gertz MA, Buadi F. What do I need to know about immunoglobulin light chain (AL) amyloidosis? *Blood Rev* 2012;26:137–54.
 60. Dispenzieri A, Katzmann JA, Kyle RA, Larson DR, Melton LJ 3rd, Colby CL, et al. Prevalence and risk of progression of light-chain monoclonal gammopathy of undetermined significance: a retrospective population-based cohort study. *Lancet* 2010;375:1721–8.
 61. Barnidge DR, Dispenzieri A, Merlini G, Katzmann JA, Murray DL. Monitoring free light chains in serum using mass spectrometry. *Clin Chem Lab Med* 2016;54:1073–83.
 62. Merlini G, Lousada I, Ando Y, Dispenzieri A, Gertz MA, Grogan M, et al. Rationale, application and clinical qualification for NT-proBNP as a surrogate end point in pivotal clinical trials in patients with AL amyloidosis. *Leukemia* 2016;30:1979–86.
 63. Gertz MA. Immunoglobulin light chain amyloidosis: 2014 update on diagnosis, prognosis, and treatment. *Am J Hematol* 2014;89:1132–40.
 64. Koyama J, Ikeda S, Ikeda U. Echocardiographic assessment of the cardiac amyloidoses. *Circ J* 2015;79:721–34.
 65. Habib G, Bucciarelli-Ducci C, Caforio ALP, Cardim N, Charon P, Cosyns B, et al. Multimodality Imaging in Restrictive Cardiomyopathies: An EACVI expert consensus document In collaboration with the “Working Group on myocardial and pericardial diseases” of the European Society of Cardiology Endorsed by The Indian Academy of Echocardiography. *Eur Heart J Cardiovasc Imaging* 2017;18:1090–121.
 66. Falk RH, Quarta CC, Dorbala S. How to image cardiac amyloidosis. *Circ Cardiovasc Imaging* 2014;7:552–62.
 67. Innelly P, Galderisi M, Catalano L, Martorelli MC, Olibet M, Pardo M, et al. Detection of increased left ventricular filling pressure by pulsed tissue Doppler in cardiac amyloidosis. *J Cardiovasc Med* 2006;7:742–7.
 68. Phelan D, Collier P, Thavendiranathan P, Popović ZB, Hanna M, Plana JC, et al. Relative apical sparing of longitudinal strain using two-dimensional speckle-tracking echocardiography is both sensitive and specific for the diagnosis of cardiac amyloidosis. *Heart* 2012;98:1442–8.
 69. Liu D, Hu K, Niemann M, Herrmann S, Cikes M, Störk S, et al. Effect of combined systolic and diastolic functional parameter assessment for differentiation of cardiac amyloidosis from other causes of concentric left ventricular hypertrophy. *Circ Cardiovasc Imaging* 2013;6:1066–72.
 70. Syed IS, Glockner JF, Feng D, Araoz PA, Martinez MW, Edwards WD, et al. Role of cardiac magnetic resonance imaging in the detection of cardiac amyloidosis. *JACC Cardiovasc Imaging* 2010;3:155–64.
 71. Fontana M, Banyersad SM, Treibel TA, Abdel-Gadir A, Maestrini V, Lane T, et al. Differential Myocyte Responses in Patients with Cardiac Transthyretin Amyloidosis and Light-Chain Amyloidosis: A Cardiac MR Imaging Study. *Radiology* 2015;277:388–97.
 72. Maceira AM, Joshi J, Prasad SK, Moon JC, Perugini E, Harding I, et al. Cardiovascular magnetic resonance in cardiac amyloidosis. *Circulation* 2005;111:186–93.
 73. Chen W, Ton VK, Dilsizian V. Clinical Phenotyping of Transthyretin Cardiac Amyloidosis with Bone-Seeking Radiotracers in Heart Failure with Preserved Ejection Fraction. *Curr Cardiol Rep* 2018;20:23.
 74. Bokhari S, Castaño A, Pozniakoff T, Deslisle S, Latif F, Maurer MS. (99m)Tc-pyrophosphate scintigraphy for differentiating light-chain cardiac amyloidosis from the transthyretin-related familial and senile cardiac amyloidoses. *Circ Cardiovasc Imaging* 2013;6:195–201.
 75. Kim YJ, Ha S, Kim YI. Cardiac amyloidosis imaging with amyloid positron emission tomography: A systematic review and meta-analysis. *J Nucl Cardiol* 2018 Jul 18. doi: 10.1007/s12350-018-1365-x.
 76. Castaño A, Manson DK, Maurer MS, Bokhari S. Transthyretin cardiac amyloidosis in older adults: optimizing cardiac imaging to the corresponding diagnostic and management goal. *Curr Cardiovasc Risk Rep* 2017 Jun;11. pii: 17. doi: 10.1007/s12170-017-0541-x.
 77. Nativi-Nicolau J, Maurer MS. Amyloidosis cardiomyopathy: update in the diagnosis and treatment of the most common types. *Curr Opin Cardiol* 2018;33:571–9.
 78. Knowles TP, Vendruscolo M, Dobson CM. The amyloid state and its association with protein misfolding diseases. *Nat Rev Mol Cell Biol* 2014;15:384.
 79. Flodrova P, Flodr P, Pika T, Vymetal J, Holub D, Dzubak P, et al. Cardiac amyloidosis: from clinical suspicion to morphological diagnosis. *Pathology* 2018;50:261–8.
 80. Siddiqi OK, Ruberg FL. Cardiac amyloidosis: An update on pathophysiology, diagnosis, and treatment. *Trends Cardiovasc Med* 2018;28:10–21.
 81. Westermark P. Amyloid diagnosis, subcutaneous adipose tissue, immunohistochemistry and mass spectrometry. *Amyloid* 2011;18:175–6.
 82. Ikeda S, Sekijima Y, Tojo K, Koyama J. Diagnostic value of abdominal wall fat pad biopsy in senile systemic amyloidosis. *Amyloid* 2011;18:211–5.
 83. Vrana JA, Gamez JD, Madden BJ, Theis JD, Bergen HR 3rd, Dogan A. Classification of amyloidosis by laser microdissection and mass spectrometry-based proteomic analysis in clinical biopsy specimens. *Blood* 2009;114:4957–9.
 84. Pereira NL, Grogan M, Dec GW. Spectrum of restrictive and infiltrative cardiomyopathies: Part 1 of a 2-Part Series. *J Am Coll Cardiol* 2018;71:1130–48.
 85. Pereira NL, Grogan M, Dec GW. Spectrum of restrictive and infiltrative cardiomyopathies: Part 2 of a 2-Part Series. *J Am*

- Coll Cardiol 2018;71:1149–66.
86. Sipe JD, Benson MD, Buxbaum JN, Ikeda S, Merlini G, Saraiva MJ, et al. Nomenclature 2014: Amyloid fibril proteins and clinical classification of the amyloidosis. *Amyloid* 2014;21:221–4.
 87. Benson MD, Kincaid JC. The molecular biology and clinical features of amyloid neuropathy. *Muscle Nerve* 2007;36:411–23.
 88. Mucchiano GI, Häggqvist B, Sletten K, Westermark P. Apolipoprotein A-1-derived amyloid in atherosclerotic plaques of the human aorta. *J Pathol* 2001;193:270–5.
 89. Maleszewski JJ. Cardiac amyloidosis: pathology, nomenclature, and typing. *Cardiovasc Pathol* 2015;24:343–50.
 90. Luciani M, Troncone L, Del Monte F. Current and future circulating biomarkers for cardiac amyloidosis. *Acta Pharmacologica Sinica* 2018;39:1133–41.
 91. Ponikowski P, Voors AA, Anker SD, Bueno H, Cleland JG, Coats AJ, et al. 2016 ESC Guidelines for the diagnosis and treatment of acute and chronic heart failure: The Task Force for the diagnosis and treatment of acute and chronic heart failure of the European Society of Cardiology (ESC). Developed with the special contribution of the Heart Failure Association (HFA) of the ESC. *Eur J Heart Fail* 2016;18:891–975.
 92. Yancy CW, Jessup M, Bozkurt B1, Butler J, Casey DE Jr, Colvin MM, et al. 2017 ACC/AHA/HFSA Focused Update of the 2013 ACCF/AHA Guideline for the Management of Heart Failure: A Report of the American College of Cardiology/American Heart Association Task Force on Clinical Practice Guidelines and the Heart Failure Society of America. *Circulation* 2017;136(6):e137–e161.
 93. Perlini S, Mussinelli R, Salinaro F. New and evolving concepts regarding the prognosis and treatment of cardiac amyloidosis. *Curr Heart Fail Rep* 2016;13:267–72.
 94. Damy T, Jaccard A, Guellich A, Lavergne D, Galat A, Deux JF, et al. Identification of prognostic markers in transthyretin and AL cardiac amyloidosis. *Amyloid* 2016;23:194–202.
 95. Palecek T, Fikrle M, Nemecek E, Bauerova L, Kuchynka P, Louch WE, et al. Contemporary treatment of amyloid heart disease. *Curr Pharm Des* 2015;21:491–506.
 96. Chakraborty R, Muchtar E, Gertz MA. Newer therapies for amyloid cardiomyopathy. *Curr Heart Fail Rep* 2016;13:237–46.
 97. Grogan M, Dispenzieri A. Natural history and therapy of AL cardiac amyloidosis. *Heart Fail Rev* 2015;20:155–62.
 98. Barbhaiya CR, Kumar S, Baldinger SH, Michaud GF, Stevenson WG, Falk R, et al. with amyloid cardiomyopathy. *Heart Rhythm* 2016;13:383–90.
 99. Aus dem Siepen F, Hein S, Bauer R, Katus HA, Kristen AV. Standard heart failure medication in cardiac transthyretin amyloidosis: useful or harmful? *Amyloid* 2017;24(Sup1):132–3.
 100. Hamon D, Algalarrondo V, Gandjbakhch E, Extramiana F, Marijon E, Elbaz N, et al. Outcome and incidence of appropriate implantable cardioverter-defibrillator therapy in patients with cardiac amyloidosis. *Int J Cardiol* 2016;222:562–8.
 101. Patel KS, Hawkins PN, Whelan CJ, Gillmore JD. Life-saving implantable cardioverter defibrillator therapy in cardiac AL amyloidosis. *BMJ Case Rep* 2014. pii: bcr2014206600.
 102. Seyler C, Meder B, Weis T, Schwaneberg T, Weitmann K, Hoffmann W, et al. Translational Registry for Cardiomyopathies (TORCH) - rationale and first results. *ESC Heart Fail* 2017;4:209–15.
 103. Gertz MA, Benson MD, Dyck PJ, Grogan M, Coelho T, Cruz M, et al. Diagnosis, prognosis, and therapy of transthyretin amyloidosis. *J Am Coll Cardiol* 2015;66:2451–66.
 104. Ripoll C, Yotti R, Bermejo J, Banares R. The heart in liver transplantation. *J Hepatol* 2011;54:810–22.
 105. Ericzon BG, Wilczek HE, Larsson M, Wijayatunga P, Stangou A, Pena JR, et al. Liver Transplantation for Hereditary Transthyretin Amyloidosis: After 20 Years Still the Best Therapeutic Alternative? *Transplantation* 2015;99:1847–54.
 106. Te HS, Anderson AS, Millis JM, Jeevanandam V, Jensen DM. Current state of combined heart-liver transplantation in the United States. *J Heart Lung Transplant* 2008;27:753–9.
 107. Rosenbaum AN, Edwards BS. Current indications, strategies, and outcomes with cardiac transplantation for cardiac amyloidosis and sarcoidosis. *Curr Opin Organ Transplant* 2015;20:584–92.
 108. Sousa M, Monohan G, Rajagopalan N, Grigorian A, Guglin M. Heart transplantation in cardiac amyloidosis. *Heart Fail Rev* 2017;22:317–27.
 109. Swiecicki PL, Edwards BS, Kushwaha SS, Dispenzieri A, Park SJ, Gertz MA. Left ventricular device implantation for advanced cardiac amyloidosis. *J Heart Lung Transplant* 2013;32:563–8.
 110. Meier-Ewert HK, Sanchowala V, Berk JL, Ruberg FL. Cardiac amyloidosis: evolving approach to diagnosis and management. *Curr Treat Options Cardiovasc Med* 2011;13:528–42.
 111. Madan S, Kumar SK, Dispenzieri A, Lacy MQ, Hayman SR, Buadi FK, et al. High-dose melphalan and peripheral blood stem cell transplantation for light-chain amyloidosis with cardiac involvement. *Blood* 2012;119:1117–22.
 112. Dahm CN, Cornell RF, Lenihan DJ. Advances in treatment of cardiac amyloid. *Curr Treat Options Cardiovasc Med* 2018;20:37.
 113. Maurer MS, Schwartz JH, Gundapaneni B, Elliott PM, Merlini G, Waddington-Cruz M, et al.; ATTR-ACT Study Investigators. Tafamidis Treatment for Patients with Transthyretin Amyloid Cardiomyopathy. *N Engl J Med* 2018;379:1007–16.
 114. Sperry BW, Ikram A, Hachamovitch R, Valent J, Vranian MN, Phelan D, et al. Efficacy of chemotherapy for light-chain amyloidosis in patients presenting with symptomatic heart failure. *J Am Coll Cardiol* 2016;67:2941–8.
 115. Palladini G, Sachchithanatham S, Milani P, Gillmore J, Foli

- A, Lachmann H, et al. A European collaborative study of cyclophosphamide, bortezomib, and dexamethasone in upfront treatment of systemic AL amyloidosis. *Blood* 2015;126:612–5.
116. Alexander KM, Singh A, Falk RH. Novel pharmacotherapies for cardiac amyloidosis. *Pharmacol Ther* 2017;180:129–38.
 117. Quintas A, Vaz DC, Cardoso I, Saraiva MJ, Brito RM. Tetramer dissociation and monomer partial unfolding precedes protofibril formation in amyloidogenic transthyretin variants. *J Biol Chem* 2001;276:27207–13.
 118. Bulawa CE, Connelly S, Devit M, Wang L, Weigel C, Fleming JA, et al. Tafamidis, a potent and selective transthyretin kinetic stabilizer that inhibits the amyloid cascade. *Proc Natl Acad Sci U S A* 2012;109:9629–34.
 119. Hammarström P, Schneider F, Kelly JW. Trans-suppression of misfolding in an amyloid disease. *Science* 2001;293:2459–62.
 120. Hammarström P, Wiseman RL, Powers ET, Kelly JW. Prevention of transthyretin amyloid disease by changing protein misfolding energetics. *Science* 2003;299:713–6.
 121. Rosenblum H, Castano A, Alvarez J, Goldsmith J, Helmke S, Maurer MS. TTR (Transthyretin) stabilizers are associated with improved survival in patients with TTR cardiac amyloidosis. *Circ Heart Fail* 2018;11:e004769.
 122. Castano A, Drachman BM, Judge D, Maurer MS. Natural history and therapy of TTR-cardiac amyloidosis: emerging disease-modifying therapies from organ transplantation to stabilizer and silencer drugs. *Heart Fail Rev* 2015;20:163–78.
 123. Berk JL, Suhr OB, Obici L, Sekijima Y, Zeldenrust SR, Yamashita T, et al.; Diflunisal Trial Consortium. Repurposing diflunisal for familial amyloid polyneuropathy: a randomized clinical trial. *JAMA* 2013;310:2658–67.
 124. González-López E, López-Sainz Á, García-Pavía P. Diagnosis and treatment of transthyretin cardiac amyloidosis: Progress and hope. *Rev Esp Cardiol (Engl Ed)* 2017;70:991–1004.
 125. Castaño A, Helmke S, Alvarez J, Delisle S, Maurer MS. Diflunisal for ATTR cardiac amyloidosis. *Congest Heart Fail* 2012;18:315–9.
 126. Coelho T, Merlini G, Bulawa CE, Fleming JA, Judge DP, Kelly JW, et al. Mechanism of action and clinical application of tafamidis in hereditary transthyretin amyloidosis. *Neurol Ther* 2016;5:1–25.
 127. Coelho T, Maia LF, Martins da Silva A, Waddington Cruz M, Planté-Bordeneuve V, Lozeron P, et al. Tafamidis for transthyretin familial amyloid polyneuropathy: a randomized, controlled trial. *Neurology* 2012;79:785–92.
 128. Coelho T, Maia LF, da Silva AM, Cruz MW, Planté-Bordeneuve V, Suhr OB, et al. Long-term effects of tafamidis for the treatment of transthyretin familial amyloid polyneuropathy. *J Neurol* 2013;260:2802–14.
 129. Scott LJ. Tafamidis: a review of its use in familial amyloid polyneuropathy. *Drugs* 2014;74:1371–8.
 130. Merlini G, Planté-Bordeneuve V, Judge DP, Schmidt H, Obici L, Perlina S, et al. Effects of tafamidis on transthyretin stabilization and clinical outcomes in patients with non-Val30Met transthyretin amyloidosis. *J Cardiovasc Transl Res* 2013;6:1011–20.
 131. Damy T, Judge DP, Kristen AV, Berthet K, Li H, Aarts J. Cardiac findings and events observed in an open-label clinical trial of tafamidis in patients with non-Val30Met and non-Val122Ile hereditary transthyretin amyloidosis. *J Cardiovasc Transl Res* 2015;8:117–27.
 132. Maurer MS, Grogan DR, Judge DP, Mundayat R, Packman J, Lombardo I, et al. Tafamidis in transthyretin amyloid cardiomyopathy: effects on transthyretin stabilization and clinical outcomes. *Circ Heart Fail* 2015;8:519–26.
 133. Maurer MS, Elliott P, Merlini G, Shah SJ, Cruz MW, Flynn A, et al.; ATTR-ACT Study Investigators. Design and Rationale of the Phase 3 ATTR-ACT Clinical Trial (Tafamidis in Transthyretin Cardiomyopathy Clinical Trial). *Circ Heart Fail*. 2017;10.pii: e003815.
 134. Buxbaum JN. Oligonucleotide drugs for transthyretin amyloidosis. *N Engl J Med* 2018;379:82–5.
 135. Sperry BW, Tang WHW. Amyloid heart disease: genetics translated into disease-modifying therapy. *Heart* 2017;103:812–7.
 136. Suhr OB, Coelho T, Buades J, Pouget J, Conceicao I, Berk J, et al. Efficacy and safety of patisiran for familial amyloidotic polyneuropathy: a phase II multi-dose study. *Orphanet J Rare Dis* 2015;10:109.
 137. Adams D, Gonzalez-Duarte A, O’Riordan WD, Yang CC, Ueda M, Kristen AV, et al. Patisiran, an RNAi therapeutic, for hereditary transthyretin amyloidosis. *N Engl J Med* 2018;379:11–21.
 138. Benson MD, Ackermann EJ, Monia BP. Treatment of transthyretin cardiomyopathy with a TTR-specific antisense oligonucleotide (IONIS-TTR(Rx)). *Amyloid* 2017;24(Sup1):134–5.
 139. Benson MD, Waddington-Cruz M, Berk JL, Polydefkis M, Dyck PJ, Wang AK, et al. Inotersen treatment for patients with hereditary transthyretin amyloidosis. *N Engl J Med* 2018;379:22–1.
 140. Obici L, Cortese A, Lozza A, Lucchetti J, Gobbi M, Palladini G, Perlina S, Saraiva MJ, Merlini G. Doxycycline plus tauroursodeoxycholic acid for transthyretin amyloidosis: a phase II study. *Amyloid* 2012;19 Suppl 1:34–6.
 141. Aus dem Siepen F, Bauer R, Aurich M, Buss SJ, Steen H, Altland K, et al. Green tea extract as a treatment for patients with wild-type transthyretin amyloidosis: an observational study. *Drug Des Devel Ther* 2015;9:6319–25.
 142. Richards DB, Cookson LM, Berges AC, Barton SV, Lane T, Ritter JM, et al. Therapeutic clearance of amyloid by antibodies to serum amyloid P component. *N Engl J Med* 2015;373:1106–4.