

CASE REPORT

Open Access



# Chronic lower extremity wound infection due to *Kerstersia gyiorum* in a patient with Buerger's disease: a case report

Irmak Baran<sup>1,3\*</sup> , Arife Polat Düzgün<sup>2</sup>, İpek Mumcuoğlu<sup>1</sup> and Neriman Aksu<sup>1</sup>

## Abstract

**Background:** *Kerstersia gyiorum* is an extremely rare pathogen of human infection. It can cause chronic infection in patients with underlying conditions. It can easily be misdiagnosed if proper diagnostic methods are not used.

**Case presentation:** A 47-year-old male patient with a history of Buerger's Disease for 28 years presented to our hospital with an infected chronic wound on foot. The wound was debrided, and the specimen was sent to Microbiology laboratory. Gram staining of the specimen showed abundant polymorphonuclear leukocytes and gram-negative bacilli. Four types of colonies were isolated on blood agar. These were identified as *Kerstersia gyiorum*, *Proteus vulgaris*, *Enterobacter cloacae*, *Morganella morganii* by Maldi Biotyper (Bruker Daltonics, Germany). The identification of *K. gyiorum* was confirmed by 16S ribosomal RNA gene sequencing. The patient was successfully recovered with antimicrobial therapy, surgical debridement, and skin grafting.

**Conclusions:** This is the first case of wound infection due to *K. gyiorum* in a patient with Buerger's Disease. We made a brief review of *K. gyiorum* cases up to date. Also, this case is presented to draw attention to the use of new and advanced methods like MALDI-TOF MS and 16S rRNA gene sequencing for identification of rarely isolated species from clinical specimens of patients with chronic infections and with chronic underlying conditions.

**Keywords:** *Kerstersia gyiorum*, Buerger's Disease, Thromboangiitis obliterans, MALDI-TOF MS, 16S rRNA gene sequencing, Chronic wound infection

## Background

*Kerstersia gyiorum* was first identified in 2003 by Coenye et al. as a distinct species by examination of the isolates obtained from nine clinical specimens such as leg ulcer, sputum, and faeces by cellular fatty acid analysis and 16S rRNA gene sequencing [1]. It belongs to *Alcaligenaceae* family and is closely related to *Alcaligenes*, *Bordetella*, *Achromobacter* spp. [2, 3]. After its first description, there have been publications reporting its isolation from chronic otitis media [2, 4–6], urinary tract infection [3], chronic leg ulcer [2], post-ulcer bacteraemia and sepsis [7] and bronchoalveolar lavage fluid [8].

Here we present a case of chronic foot and ankle infection due to *K. gyiorum* in a 47-year-old patient with Buerger's Disease and we have made a brief review of *K. gyiorum* cases in literature so far.

## Case presentation

A 47-year-old male patient who was previously followed up at the Chronic Wound Clinic of our hospital presented with a 10 × 15 cm wound on the dorsolateral surface of the right foot and a 2 × 3 cm wound on the outside of the right ankle (Figs. 1 and 2). The patient had a history of Buerger's Disease (Thromboangiitis obliterans) for 28 years. It has been learned that the patient continues smoking and lives in bad hygienic conditions. The patient received debridement of the wound at the Chronic Wound Clinic, and the sample was sent to our hospital's Medical Microbiology laboratory for microscopy and culture. Before getting culture results, oral

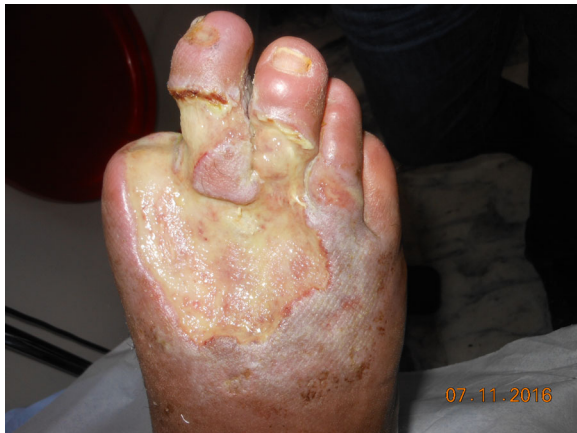\* Correspondence: irmakmor@yahoo.com

<sup>1</sup>Medical Microbiology Department, Ankara Numune Research and Training Hospital, Hacettepe Mahallesi Talatpasa Bulvarı No: 44 Altındag, Ankara, Turkey

<sup>3</sup>Esat Caddesi 101/3 Kucukesat, 06660, Ankara, Turkey

Full list of author information is available at the end of the article





**Fig. 1** Appearance of wound on the foot

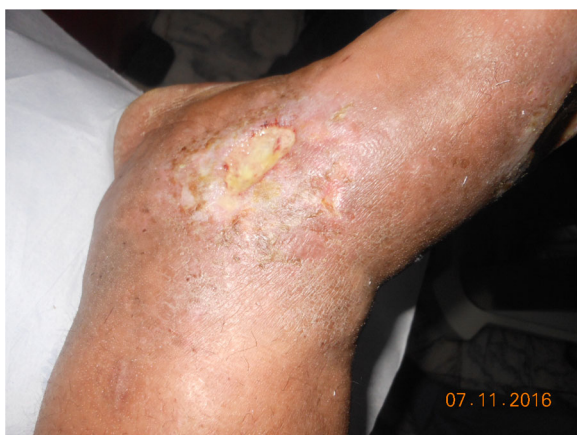ampicillin sulbactam, ciprofloxacin, and topical mupirocin treatment were started to the patient empirically.

When we questioned the patient he said that he had previously applied to the Chronic Wound Clinic nine months before this admission. The patient had first come to the Department of Cardiovascular Surgery because stem cell treatment was being considered. The patient had his toe amputated at another medical centre one month before that. The patient was referred to the Chronic Wound Clinic for the treatment of the infected chronic wound at his foot before stem cell treatment. In the blood tests performed at the first visit, the white blood cell count was 9500/ $\mu$ L (65.1% neutrophils), hemoglobin 12.3 g/dl, hematocrit 38.9%, platelets 348.000/ $\mu$ L. Both the patient's fasting blood glucose (95 mg/dL) and % HbA1c (6.1%) levels were found to be normal. The patient had higher than normal levels of CRP (12 mg/L) and erythrocyte sedimentation rate (55 mm/h). The patient's coagulation tests were within normal limits (aPTT 31.8 s, prothrombin time 11 s, INR

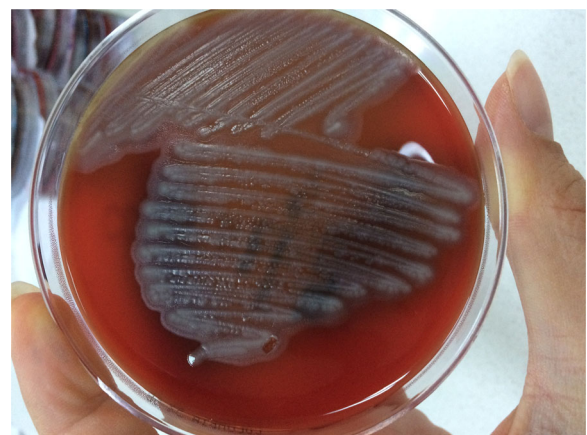
0.99). The patient's HBsAg, Anti-HIV, and Anti-HCV tests were shown to be negative with ELISA method (ETI-MAX 3000 analyzer; DiaSorin S.p.A., UK). The angiography of the leg showed left deep femoral artery had thin calibration, the right superficial femoral artery was occluded at the level of the  $\frac{1}{2}$  middle of the thigh, and there were intense collateral arteries on leg and thigh. Microscopic examination of the specimen taken from the wound revealed 4–5 polymorphonuclear leucocytes in each area. *Pseudomonas aeruginosa* was isolated from wound culture. When antibiotic sensitivity tests were made this microorganism was found to be sensitive to tobramycin, colistin, ceftazidime, and gentamicin. The patient was given iv ceftazidime and metronidazole treatment for 14 days. The patient was hospitalized for one month, and treated with hyperbaric oxygen therapy. After skin grafting, the patient was discharged.

This time the previous graft was found to be lysed, and the wound was re-infected. The blood tests were performed and white blood cells were found 8200/ $\mu$ L (70% neutrophils), hemoglobin 14 g/dl, hematocrit 43.7%, and platelets 306.000 / $\mu$ L. The patient's CRP (7 mg / L) and erythrocyte sedimentation rate (65 mm / h) were found to be high.

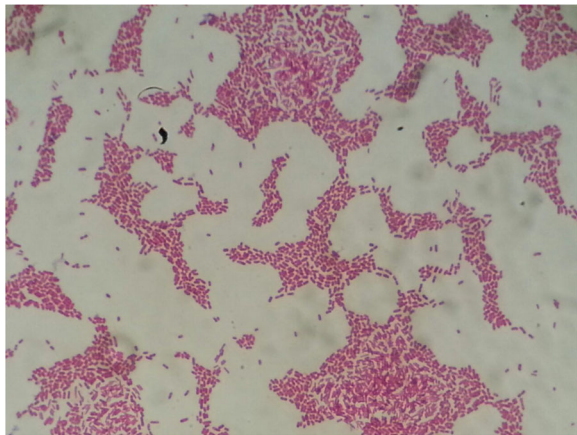
Plenty of polymorphonuclear leukocytes and gram-negative bacilli were present in the Gram stained sample taken from the patient's wound which was sent to our hospital's Medical Microbiology laboratory. The material was inoculated on to blood agar and Eosin methylene blue (EMB) agar and incubated. Four different types of colonies were identified after 24 h of incubation at 37 °C on bloody agar and EMB agar. Out of these four colony types, the colonies predominantly grown on blood agar were light gray, had a dry appearance, and were large colonies with indented edges that tended to merge with each other, resembling *Alcaligenes*. However, unlike *Alcaligenes* there was no fruity odour and oxidase test



**Fig. 2** Appearance of wound on ankle



**Fig. 3** *Kerstersia gyiorum* on blood agar



**Fig. 4** Gram stain from the pure culture of *Kerstersia gyiorum*. Gram-negative, short rods were seen

was negative. These colonies were found to be indole-negative, urease-negative and strongly catalase-positive. The colonies grown on blood agar with second density were gray coloured and had swarming around the colony, were indole positive, urease positive, oxidase negative, hydrogen sulphide producing colonies. The third colony type was dirty-white-coloured, mucoid with smooth edges. They were indole negative, Voges-Proskauer test positive. The fourth colony type was smooth-edged, whitish mucoid colonies. Urease test was positive, indole positive and Voges-Proskauer test was negative. On EMB medium a mixed growth of one lactose-positive and three lactose-negative colonies corresponding to these four types of colonies was observed. Single colony passages were made from each of these four colony types in order to identify with Maldi

Biotyper (Bruker Daltonics, Germany) system, a matrix-assisted laser desorption ionization-time of flight mass spectrometry (MALDI-TOF MS) system in our Medical Microbiology Laboratory. Antibiotic susceptibility tests of the bacteria were carried out on a Phoenix 100 (Beckton Dickinson, USA) device.

The passages made from the first colony type produced dry, light gray, opaque colonies, with irregularly indented, protruding edges, and swarming around the colonies on blood agar (Fig. 3), and lactose-negative colonies on EMB. Gram-negative, short bacilli were seen in Gram staining of colonies from blood agar (Fig. 4). These colonies were identified as *Kerstersia gyiorum* by Maldi Biotyper (Bruker Daltonics, Germany) system with 2.348 Biotyper score (excellent identification). The identification of *K. gyiorum* with Maldi Biotyper was confirmed by 16S ribosomal RNA gene sequencing according to the predefined methodology [9, 10]. Briefly, the following steps were taken for this procedure. DNA was isolated from pure culture using DNeasy Blood & tissue kit (Qiagen, Germany). 16S rRNA gene amplification was performed using universal 27F (AGAGTTT GATCMTGGCTCAG) and 1492R (GGTTACCTTGT TACGACTT) primers. In the PCR reaction, 1XTaq buffer, 2 mM MgCl<sub>2</sub>, 0.2 mM dNTP, 0.4 pmol of primers and 1.25 U Taq polymerase (Thermo Fisher Scientific, USA) were used in a volume of 50 µL. DNA sequencing of the resulting product was performed using the Bigdye Cycle Sequencing Kit v.3.1 (Applied Biosystems, USA). Sequence analyzes were compared to the GenBank NCBI gene library data using the BLAST program (<https://blast.ncbi.nlm.nih.gov/Blast.cgi>). The sequence was found 100% identical to *K. gyiorum*. Antibiotic susceptibility tests for *K. gyiorum* were performed using the Phoenix 100

**Table 1** Antimicrobial susceptibility profile of *Kerstersia gyiorum* as determined by Phoenix 100 and E-test

Antimicrobial agent	Phoenix 100		E-test	
	MIC (µg/mL)	Result	MIC (µg/mL)	Result
Amikacin	≤4	Susceptible	–	–
Aztreonam	≤1	Susceptible	–	–
Ceftazidime	≤0.5	Susceptible	–	–
Ceftriaxone	–	–	0.25	Susceptible
Ciprofloxacin	≤0.125	Susceptible	0.25	Susceptible
Colistin	>4	Resistant	>256	Resistant
Gentamicin	2	Susceptible	1	Susceptible
Imipenem	–	–	2	Susceptible
Meropenem	≤0.125	Susceptible	–	–
Netilmicin	2	Susceptible	–	–
Piperacillin	≤4	Susceptible	–	–
Piperacillin-tazobactam	≤4/4	Susceptible	–	–
Trimethoprim-sulfamethoxazole	≤1/19	Susceptible	≤2/38	Susceptible

(Beckton Dickinson, USA) device and the E-test (Liofilchem, Italy) for six antimicrobial agents (ceftriaxone, ciprofloxacin, colistin, gentamicin, imipenem, trimethoprim-sulfamethoxazole) on Mueller-Hinton agar in accordance with the manufacturer's specifications. The results were evaluated according to the MIC breakpoints established by Clinical and Laboratory Standards Institute for other non-*Enterobacteriaceae* [11]. The results of antibiotic susceptibility tests for *K. gyiorum* are shown in Table 1.

Other microorganisms were identified as *Proteus vulgaris*, *Enterobacter cloacae*, *Morganella morganii* by Maldi Biotyper system, respectively. Antibiotic susceptibility results of *P. vulgaris*, *E. cloacae*, *M. morganii* are shown in Table 2.

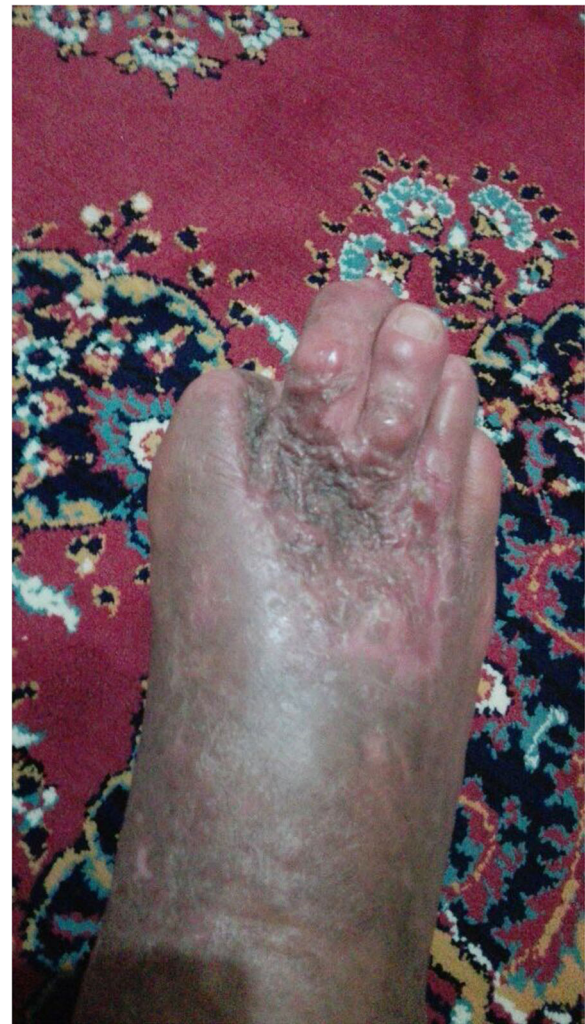Oral ampicillin-sulbactam and ciprofloxacin treatment was continued because the microorganisms were susceptible to these antibiotics. Hyperbaric oxygen therapy was used. Wound debridement and skin grafting were applied. The patient was discharged after one month of hospitalization. The patient was doing well in follow-up examination three-months later (Fig. 5). Figure 6 shows a timeline of events.

## Discussion

*K. gyiorum*'s name was derived from the Greek word "gyion", which means "limb" since it was often isolated from leg and ankle wounds when it was first described

**Table 2** Antimicrobial susceptibility results of *Proteus vulgaris*, *Enterobacter cloacae*, *Morganella morganii*

	<i>Proteus vulgaris</i>	<i>Enterobacter cloacae</i>	<i>Morganella morganii</i>
Amikacin	Susceptible	Susceptible	Susceptible
Amoxicillin-clavulanic acid	Susceptible	Resistant	Resistant
Ampicillin	Resistant	Resistant	Resistant
Ampicillin-sulbactam	Susceptible	Susceptible	Susceptible
Ertapenem	Susceptible	Susceptible	Susceptible
Gentamicin	Susceptible	Susceptible	Susceptible
Imipenem	Intermediate	Susceptible	Susceptible
Levofloxacin	Susceptible	Susceptible	Susceptible
Meropenem	Susceptible	Susceptible	Susceptible
Piperacillin-tazobactam	Susceptible	Susceptible	Susceptible
Cefepime	Susceptible	Susceptible	Susceptible
Cefoxitin	Susceptible	Susceptible	Susceptible
Cefotaxime	Susceptible	Susceptible	Susceptible
Ceftriaxone	Resistant	Susceptible	Susceptible
Cefuroxime	Susceptible	Susceptible	Susceptible
Ciprofloxacin	Susceptible	Susceptible	Susceptible
Tobramycin	Susceptible	Susceptible	Susceptible
Trimethoprim-sulfamethoxazole	Resistant	Resistant	Susceptible

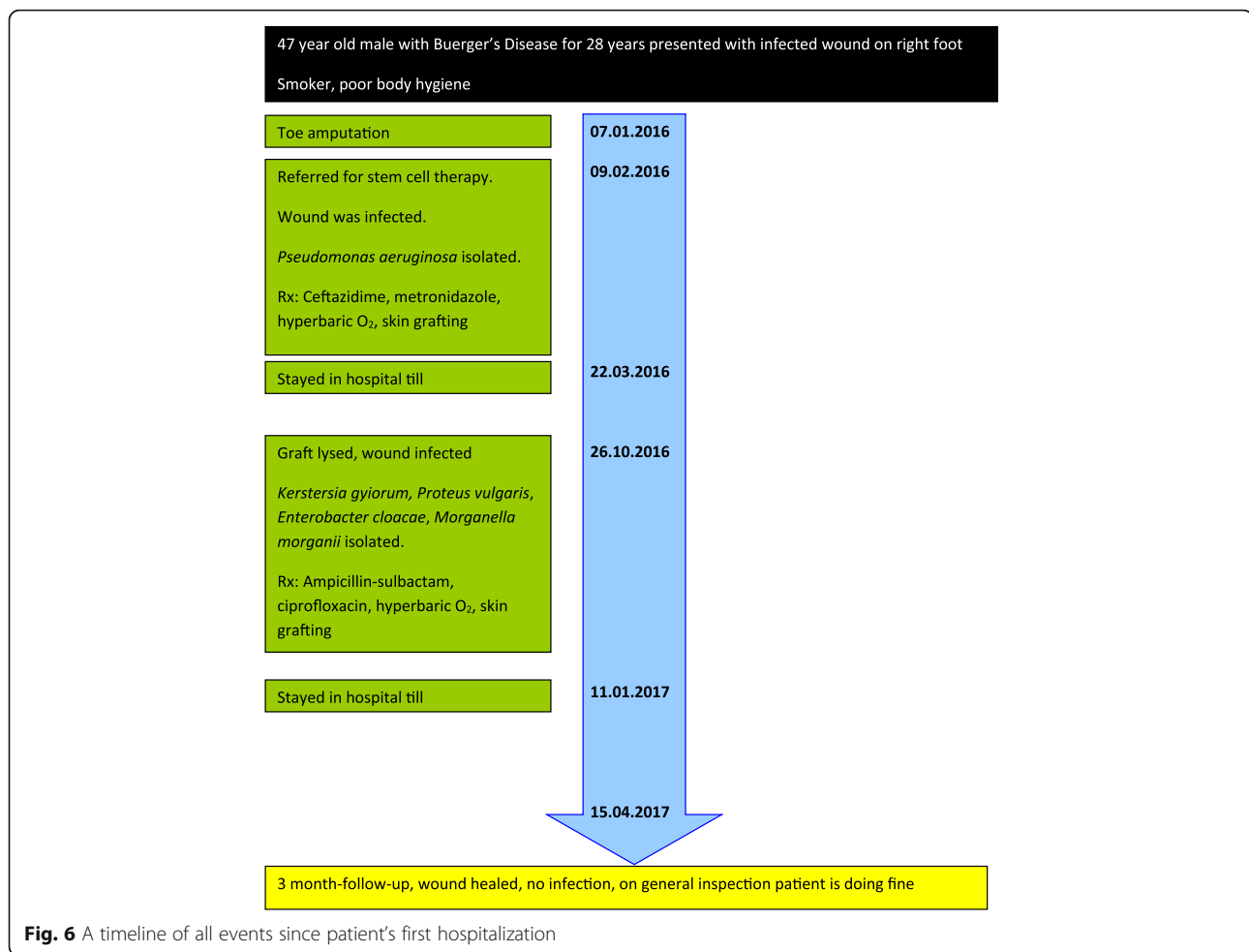


**Fig. 5** Appearance of the patient's foot at the three-month follow-up

[1–3, 6, 7]. *K. gyiorum* belongs to *Alcaligenaceae* family, and it is related to *Alcaligenes*, *Bordatella*, *Achromobacter*, and *Pigmentiphaga* genera [1, 3–7]. *K. gyiorum* colonies are known to show an appearance similar to *Alcaligenes faecalis*. However, *K. gyiorum* isolates are oxidase negative and lack the characteristic fruity odor [3, 7]. *K. gyiorum* is highly catalase positive but urease and  $\beta$ -galactosidase negative [1].

When we conducted a search for "Kerstersia gyiorum case report" on PubMed and Medline we found that there were 9 cases since the first time it was defined in 2003 [2–8] Table 3 shows clinical features of these case reports. In 2012, Vandamme et al. identified *Kerstersia similis*, a close species, from the neck abscess of a 54-year-old patient [12].

In our case *K. gyiorum* grew with other types of microorganisms from wound specimen. This was also observed by previous researchers who have reported cases of *K. gyiorum* [2–8]. In seven of the nine cases that have



been reported so far there were polymicrobial infections. *K. gyiorum* was isolated from urinary tract infection together with *P. vulgaris* [3], from chronic otitis media with *Corynebacterium amycolatum*, from chronic lower extremity wound with *Morganella spp.* [2], from bronchoalveolar lavage fluid with *Pseudomonas aeruginosa* and *Stenotrophomonas maltophilia* [8], from chronic suppurative otitis media with *P. aeruginosa* in a case report [5] from our country, and in two different cases from chronic suppurative otitis media with *Proteus mirabilis* and from chronic suppurative otitis media with *Staphylococcus aureus* and *Escherichia coli* [6]. In our case, *K. gyiorum* was seen to be grown more dominantly than other microorganisms in the culture plate. However, since there are a very limited number of reports in the literature on this microorganism, it is difficult to predict the effect of *K. gyiorum* in the disease process in a polymicrobial infection [2]. The virulence factors of this microorganism should be investigated [6]. In our case, the patient's condition got better after antimicrobial therapy. Ogawa et al. reported that *K. gyiorum* is prone to cause infection in situations predisposing to

polymicrobial infection because *Achromobacter* and *Alcaligenes spp.* which are closely related have the same tendency [3].

If we look at the results of antibiotic susceptibility, our *K. gyiorum* isolate was found to be susceptible to aminoglycosides, ciprofloxacin, imipenem and meropenem and broad spectrum cephalosporins. These results were similar to Coenye et al. [1] and Almuzara et al.'s results [4]. However, Pence et al. [2], Uysal et al. [5], Mwalutende et al. [6], Bostwick et al. [7], Deutscher et al. [8], found resistance to ciprofloxacin in *K. gyiorum* isolates.

Our patient was a smoker. He had Buerger's Disease (Thromboangiitis obliterans) for 28 years due to smoking. Thromboangiitis obliterans is a non-atherosclerotic inflammatory disease affecting the small and medium vessels in the limbs and causes circulatory problems [13]. In this disease, ulcers that do not heal especially at the distal end of the extremities are seen [13, 14]. The chronic suppurative otitis media case due to *K. gyiorum* that Mwalutende et al. reported was a chronic smoker [6]. Pence et al. also reported chronic cigarette smoking in their case [2]. We believe that there may be a

**Table 3** Clinical features of reported cases of *Kerstersia* spp. after first identification in 2003 by Coenye et al. [1] (Source: PubMed, Medline)

Year of publication	Reference number	Authors	Patient age	Gender	Smoking history	Clinical condition	Source	Polymicrobial/monomicrobial	Isolated Species	Antibiotic treatment	Outcome
2012	4	Almuzara et al.	16	Male	Absent	Complicated chronic otitis media	Bezold's abscess	Monomicrobial	<i>Kerstersia gyiorum</i>	Iv ampicillin-sulbactam and ceftriaxone (3 days) Oral ciprofloxacin and amoxicillin-clavulanic acid	Recovered
2013	2	Pence et al.	55	Male	Present	Chronic otitis medi	Mastoid cavity specimen	Polymicrobial	<i>Kerstersia gyiorum</i> <i>Corynebacterium amycolatum</i>	Trimethoprim-sulfamethoxazole (14 days)	Recovered
2013	2	Pence et al.	61	Female	Absent	Lower leg ulcer	Wound specimen swab	Polymicrobial	<i>Kerstersia gyiorum</i> <i>Morganella morganii</i>	Ciprofloxacin (10 days)	Unknown
2014	8	Deutscher et al.	63	Female	Absent	Ventilator-dependent chronic respiratory failure, Chronic tracheostomy	Bronchoalveolar lavage	Polymicrobial	<i>Kerstersia gyiorum</i> , <i>Pseudomonas aeruginosa</i> , <i>Stenotrophomonas maltophilia</i>	Piperacillin-tazobactam, doripenem, ciprofloxacin, ceftazidime, colistin	Died from complications
2014	6	Mwalutende et al.	53	Male	Present	Chronic suppurative otitis media	Ear swab	Polymicrobial	<i>Kerstersia gyiorum</i> , <i>Proteus mirabilis</i>	Ciprofloxacin ear drops	Recovered
2014	6	Mwalutende et al.	33	Male	Absent	Chronic suppurative otitis media	Ear swab	Polymicrobial	<i>Kerstersia gyiorum</i> , <i>Escherichia coli</i> <i>Staphylococcus aureus</i>	Ciprofloxacin ear drops	Recovered
2015	5	Uysal et al.	25	Male	Absent	Chronic suppurative otitis media	Ear swab	Polymicrobial	<i>Kerstersia gyiorum</i> <i>Pseudomonas aeruginosa</i> ,	Imipenem (10 days)	Recovered
2015	7	Bostwick et al.	69	Female	Absent	Chronic lower extremity ulcer, bacteremia, sepsis	Blood culture	Monomicrobial	<i>Kerstersia gyiorum</i>	Ciprofloxacin, clindamycin (14 days)	Recovered
2016	3	Ogawa et al.	82	Male	Absent	Urinary tract infection	Urine	Polymicrobial	<i>Kerstersia gyiorum</i> <i>Proteus vulgaris</i>	Levofloxacin (5 days)	Recovered
2012	12	Vandamme et al.	54	Male	Unknown	Unknown	Neck abscess	Unknown	<i>Kerstersia similis</i>	Unknown	Unknown

relationship between chronic smoking and infection due to *K. gyiorum*. However, further work is needed in order to test this hypothesis.

Previous researchers who reported case reports of *K. gyiorum* reported that the associated infection usually develops on a long-standing inflammatory condition [2–4, 6, 8]. Our patient had long-term lower extremity ulcers due to Buerger's Disease.

In our case, we observed that on blood agar *K. gyiorum* forms colonies with a irregular spreading edge morphology. Pence et al., Deutscher et al., and Bostwick et al. reported that they observed colonies with similar appearance to ours [2, 7, 8]. We think that these phenotypical features may be typical for *K. gyiorum*. This morphology can be used to distinguish *K. gyiorum* from *Acinetobacter* spp., which is also a non-fermentative and oxidase-negative bacterium as suggested by previous researchers [2, 8]. Pence et al. referred to the formation of lavender pigment on MacConkey agar [2]. We did not see such pigment formation in our own case. However we used EMB instead of MacConkey agar. In our opinion, the appearance of such a colony type after inoculation of a specimen from a site of chronic inflammation should suggest *K. gyiorum* infection.

Introduction of molecular and genetic identification methods to clinical microbiology has increased the detection of new and rare bacteria in clinical specimens. MALDI-TOF MS and 16S rRNA gene sequencing are two of these new and advanced methods [2, 6, 8]. In our case we detected the presence of *K. gyiorum* by using MALDI-TOF MS. The reliance on solely biochemical identification methods or automated identification systems may lead to misidentification of *K. gyiorum*, because it has common biochemical features with more commonly detected pathogens such as *Acinetobacter* spp. [5–7]. Also *K. gyiorum* is phenotypically similar to *Alcaligenes faecalis* and it may go unnoticed if proper identification methods are not used [5]. The increase in the identification of new and previously unrecognized bacteria has led to two important situations in clinical microbiology laboratories. The first is to determine whether these microorganisms are pathogens or contaminants, and the second is to correctly determine the antibiotic susceptibilities of these microorganisms [2]. The co-operation of the clinician and the laboratory is required to achieve these. As the data in the literature will increase with the studies to be done on this subject, a more accurate perspective will be obtained for approaching these cases. Besides, it is difficult to identify such rare microorganisms by conventional methods. Therefore, when the pathogen cannot be identified by routine biochemical methods in cases of chronic infections that do not heal, MALDI-TOF MS and 16S rRNA

gene sequencing are emerging as fast and reliable alternatives [5, 8].

## Conclusions

We think that *K. gyiorum* should be kept in mind as a possible agent associated with chronic infected lower extremity ulcers in patients with Buerger's Disease.

## Abbreviations

16S rRNA: 16S ribosomal ribonucleic acid; Anti-HCV: Anti hepatitis C virus antibodies; Anti-HIV: Anti human immunodeficiency virus antibodies; aPTT: Activated partial thromboplastin time; CRP: C-reactive protein; ELISA: Enzyme-linked immunosorbent assay; EMB: Eosin methylene blue; E-test: Epsilometer test; HbA1c: Glycated haemoglobin; HBsAg: Surface antigen of the hepatitis B virus; INR: International normalized ratio; MALDI-TOF MS: Matrix-assisted laser desorption ionization-time of flight mass spectrometry; MIC: Minimum inhibitory concentration; NCBI: National Center for Biotechnology Information; PCR: Polymerase chain reaction

## Acknowledgements

The authors wish to acknowledge the patient.

## Funding

The authors declare that funding was not utilized for the preparation of this manuscript.

## Availability of data and materials

All data generated or analysed during this study are included in this published article.

## Authors' contributions

IB isolated the microorganisms, did antimicrobial susceptibility tests and molecular tests, conducted the literature review, collected the data from the patient's medical records and wrote the manuscript. APD followed the patient, made surgical wound debridement and skin grafting, prospectively recorded the patient's clinical data, and took the pictures of the patient. IM conducted E-tests, involved in analysis of data and drafting of the manuscript. NA involved in supervision of the laboratory tests and revised crucially the manuscript for important intellectual content. All authors read and approved the final manuscript.

## Ethics approval and consent to participate

Our ethics committee waived the requirement of ethics approval because all medical and laboratory procedures are routinely carried out and do not affect decisions concerning treatment.

## Consent for publication

Written informed consent was obtained from the patient for publication of this case report. A copy of the written consent is available for review by the Editor of this journal.

## Competing interests

The authors declare that they have no competing interests.

## Publisher's Note

Springer Nature remains neutral with regard to jurisdictional claims in published maps and institutional affiliations.

## Author details

<sup>1</sup>Medical Microbiology Department, Ankara Numune Research and Training Hospital, Hacettepe Mahallesi Talatpasa Bulvarı No: 44 Altindag, Ankara, Turkey. <sup>2</sup>Clinic of General Surgery, Ankara Numune Research and Training Hospital, Ankara, Turkey. <sup>3</sup>Esat Caddesi 101/3 Kucukesat, 06660, Ankara, Turkey.

Received: 27 April 2017 Accepted: 31 August 2017

Published online: 06 September 2017

**References**

1. Coenye T, Vancanneyt M, Cnockaert MC, Falsen E, Swings J, Vandamme P. *Kerstersia gyiorum* gen. nov., sp. nov., a novel *Alcaligenes faecalis*-like organism isolated from human clinical samples, and reclassification of *Alcaligenes denitrificans* R uger and Tan 1983 as *Achromobacter denitrificans* comb. nov. *Int J Syst Evol Microbiol*. 2003;53(Pt 6):1825–31.
2. Pence MA, Sharon J, McElvania Tekippe E, Pakalniskis BL, Ford BA, Burnham CA. Two cases of *Kerstersia gyiorum* isolated from sites of chronic infection. *J Clin Microbiol*. 2013;51(6):2001–4.
3. Ogawa Y, Lee ST, Kasahara K, Koizumi A, Chihara Y, Nakano R, Yano H, Mikasa K. A first case of isolation of *Kerstersia gyiorum* from urinary tract. *J Infect Chemother*. 2016;22(4):265–7.
4. Almuzara MN, Barberis CM, Traglia GM, Ordo nez AM, Famiglietti AM, Ramirez MS, Vay CA. Isolation of *Kerstersia gyiorum* from a patient with cholesteatomatous chronic otitis media. *J Clin Microbiol*. 2012;50(11):3809–11.
5. Uysal EB,  elik C, Tuzcu N, Can F, Dođan M, Ert rk R, Bakici MZ. A case of chronic suppurative otitis media caused by *Kerstersia gyiorum*. *APMIS*. 2015; 123(11):986–9.
6. Mwalutende A, Mshana SE, Mirambo MM, Mushi MF, Chalya PL, Giliyoma JM, Schneiderhan W, Zimmermann O, Gro  U. Two cases of chronic suppurative otitis media caused by *Kerstersia gyiorum* in Tanzania: is it an underappreciated pathogen in chronic otitis media? *Int J Infect Dis*. 2014;29: 251–3.
7. Bostwick AD, Zhang C, Manninen K, Touchberry J, Greene SR, Holland TL. Bacteremia caused by *Kerstersia gyiorum*. *J Clin Microbiol*. 2015;53(6):1965–7.
8. Deutscher M, Severing J, Balada-Llasat JM. *Kerstersia gyiorum* isolated from a Bronchoalveolar lavage in a patient with a chronic tracheostomy. *Case Rep Infect Dis*. 2014;2014:479581.
9. Watson ME Jr, Estabrook MM, Burnham CA. Catheter-associated *Nocardia Higoensis* bacteremia in a child with acute lymphocytic leukemia. *J Clin Microbiol*. 2011;49(1):469–71.
10. Ziga ED, Druley T, Burnham CA. *Herbaspirillum* species bacteremia in a pediatric oncology patient. *J Clin Microbiol*. 2010;48(11):4320–1.
11. Clinical and Laboratory Standards Institute (CLSI). Performance Standards for Antimicrobial Susceptibility Testing; Twenty-fourth Informational Supplement. M100-S24. Wayne, PA, USA: 2014.
12. Vandamme P, De Brandt E, Houf K, De Baere T. *Kerstersia similis* sp. nov., isolated from human clinical samples. *Int J Syst Evol Microbiol*. 2012;62(Pt 9): 2156–9.
13. Rivera-Chavarr a IJ, Brenes-Guti rrez JD. Thromboangiitis obliterans (Buerger's disease). *Ann Med Surg (Lond)*. 2016;7:79–82.
14. Piazza G, Creager MA. Thromboangiitis obliterans. *Circulation*. 2010;121(16): 1858–61.

Submit your next manuscript to BioMed Central and we will help you at every step:

- We accept pre-submission inquiries
- Our selector tool helps you to find the most relevant journal
- We provide round the clock customer support
- Convenient online submission
- Thorough peer review
- Inclusion in PubMed and all major indexing services
- Maximum visibility for your research

Submit your manuscript at  
[www.biomedcentral.com/submit](http://www.biomedcentral.com/submit)

