

# Management of an Adult with Spaced Dentition, Class III Malocclusion and Open-bite Tendency

Demet Kaya<sup>a</sup>  
Tulin Ugur Taner<sup>b</sup>

## ABSTRACT

The aim of this case report was to present the orthodontic treatment of an adult with spaced dentition, Class III malocclusion, and open-bite tendency. A 28.4-year-old adult woman was concerned about the unesthetic appearance of her spaced dentition localized at both upper and lower arches while smiling. She had a mild tongue thrust, hypertropic upper frenum, and mild speech difficulty while pronouncing "s". Her profile was straight with prominent lips. Molar relationship was Class III on both sides. Anterior teeth were in an end-to-end relationship. Lower dental midline was deviated to the left side. Cephalometric analysis revealed a skeletal Class III relationship with hyperdivergent facial pattern. The treatment plan included myotherapeutic exercises for the tongue thrust habit and a diagnostic set-up for closure of diastemas. A strict retention protocol was followed combined with gingivoplasty, fiberotomy, and frenectomy procedures. All spaces were closed successfully, adequate overbite and overjet relationships were obtained, and tongue thrust habit and speech difficulty while pronouncing "s" were eliminated. Clinical and cephalometric results indicated the maintenance of the treatment outcome at 6-months post-retention period. (Eur J Dent 2011;5:121-129)

Key words: Spaced dentition; Tongue thrust; Hypertropic frenum; Open-bite.

## INTRODUCTION

Spaced dentition is characterized by interdental spaces and lack of contact points between the teeth. Spacing can be localized or generalized due

to the number of teeth included.<sup>1</sup> It is a common esthetic problem for many patients. A study in European adults showed that patients with a broad midline spacing were perceived as being less socially successful and having lower intelligence.<sup>2</sup>

Spaced dentition was found as a normal occlusion in almost one third of the population.<sup>3</sup> According to the study of Steigman et al,<sup>4</sup> 21.4% of the general population had spacing in both arches, whereas 50% of people with spacing had spaces in both arches. In studies related to young populations, it was found that spacing in both arches was more common in boys than girls.<sup>4-6</sup> However, in ages older than 16-18 years, spacing incidence is

<sup>a</sup> Clinical Instructor, Karadeniz Technical University, Faculty of Dentistry, Department of Orthodontics, Trabzon, Turkey.

<sup>b</sup> Professor, Hacettepe University, Faculty of Dentistry, Department of Orthodontics, Ankara, Turkey.

Corresponding author: Demet Kaya  
Karadeniz Technical University, Faculty of Dentistry,  
Department of Orthodontics, 61080, Trabzon, Turkey.  
Phone: +90 462 377 47 59  
E-mail: ortodem@hotmail.com

the same in boys and girls.<sup>4</sup>

The causes of generalized spacing may be hereditary, acquired, or functional. Hereditary causes include tooth size-arch size discrepancies, congenitally missing teeth, macroglossia, supernumerary teeth, small teeth, and hypertropic frenum. Functional causes include oral habits. The pathologic conditions increasing tongue size, missing teeth, delayed eruption of permanent teeth, and periodontal disease are classified as acquired problems.

Orthodontics plays an important role in the management of spaced dentition, often in cooperation with other dental departments such as oral surgery, periodontology, esthetic dentistry, and prosthodontics. To achieve the most esthetic and functional result, orthodontists must carefully evaluate the etiologic factors of diastemas in their patients. Diagnostic set-up of dental casts may be useful in treatment planning and informing the patient.<sup>7</sup> Three treatment options are available for generalized spacing: esthetic intervention using composite resin, orthodontic space closure, or closure of anterior spaces and opening posterior spaces, which will be rehabilitated later with prosthetic restoration.<sup>1</sup> After orthodontic treatment, it is frequently necessary to apply fixed retention as these cases have a high risk of relapse.

The aim of this article was to present orthodontic treatment of an adult with spaced dentition, Class III malocclusion and open-bite tendency.

### CASE REPORT

A 28.4-year-old adult woman was concerned about the unesthetic appearance of her spaced dentition localized at both upper and lower arches while smiling. She was reluctant to smile. The patient's medical history did not reveal any systemic disease.

Extraoral examination showed a symmetric face with a prominent lower lip and straight profile. Lip competence was insufficient (Figure 1). Intraoral examination showed Class III molar relationship bilaterally and an end-to-end incisor relationship. Lower dental midline was deviated to the left side. There was generalized spacing on both arches and an upper midline diastema. Blanching test was performed to check the height of the upper frenum. When an intermittent pressure was exerted on the frenum, the location of

the alveolar attachment indicated a high frenum position. A mild tongue thrust while swallowing was noted. There were brown spots on her teeth because of smoking. Also gingiva was colored due to smoking, otherwise periodontal tissues were healthy (Figure 1). There was a mild speech difficulty while pronouncing "s". Panoramic radiograph showed that all teeth were available except upper third molars (Figure 2). Hays Nance Analysis showed 10 mm spacing in the upper arch and 7.5 mm spacing in the lower arch.

According to the cephalometric analysis, she had a skeletal Class III relationship with hyperdivergent facial pattern. Maxilla and mandible were protruded relative to the anterior cranial base. Upper and lower incisors were significantly proclined. Incisor overlap was minimal. Lower lip was prominent (Table 1, Figure 3).

### Treatment planning

The treatment objectives were to level and align the arches, close the diastemas in both arches, obtain positive overjet and overbite, and settle the arches in well-intercusated occlusion. To achieve these treatment objectives, initially, elimination of the tongue thrust habit was planned and then comprehensive orthodontic treatment was proposed. Elimination of the tongue thrust habit included true tongue positioning during functional movements. A diagnostic model set-up was made to obtain a good occlusion with normal overjet and overbite and a Class I molar relationship. According to the diagnostic model set-up, lower anterior teeth were planned to be moved to the right side (Figure 4).

### Treatment progress

The patient was referred to the periodontology department for oral hygiene motivation and removal of brown spots before orthodontic treatment. Afterward, tongue positioning and popping myotherapeutic exercises were begun and continued during orthodontic treatment. She learned normal functional swallowing. Orthodontic treatment was initiated by leveling and alignment with .016 inch NiTi archwires followed by .016 inch and .016x.016 inch stainless steel archwires. Lower spaces were closed with the movement of incisors to the right side one by one. Upper and lower spaces were closed with .016x.022 inch stainless

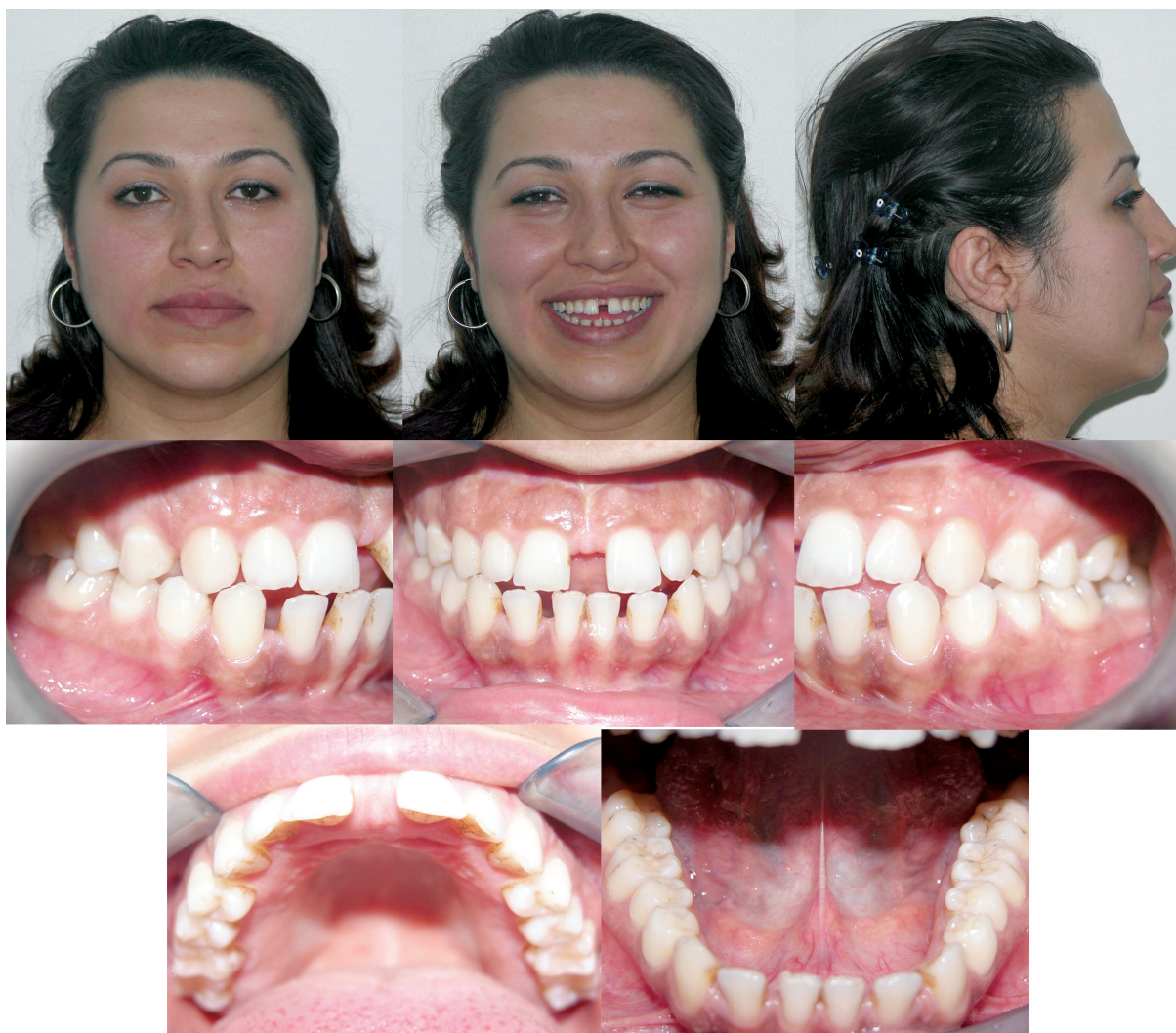

Figure 1. Pre-treatment extraoral and intraoral photographs.

Table 1. Pre-treatment, post-treatment and post-retention cephalometric measurements.

Cephalometric parameters	Pre-treatment values	Post-treatment values	Post-retention values
SNA	81°	81.5°	81.5°
SNB	81°	80°	80°
ANB	0°	2°	1°
Convexity	0 mm	+1 mm	+1 mm
Facial axis	86°	85°	85°
Facial depth	86.5°	83°	84°
Y axis	66°	69°	69°
FMA angle	34°	36°	36°
Lower facial height	54°	56°	56°
Upper incisor to SN	114°	109.5°	109°
Upper incisor to NA	33.5°	28°	27.5°
Upper incisor to APog	33°	30°	30°
IMPA	96°	84°	85°
Lower incisor to NB	33°	22.5°	23°
Lower incisor to APog	34°	21°	23°
FMIA	50	60	60
Lower lip to E line	-1 mm	0 mm	-1 mm
Upper lip to E line	-4.5 mm	-3 mm	-3 mm



steel archwires after correction of the lower dental midline. During treatment, Class III intermaxillary elastics were used to correct molar and canine relationships. Upper incisors were extruded with a .016x.022 inch TMA extrusion base arch

to increase the bite. Total active treatment time from the start to debonding was 21 months. After treatment, a gummy smile tendency was apparent and gingivoplasty was planned to obtain optimum esthetics. In addition, frenectomy and fiberotomy

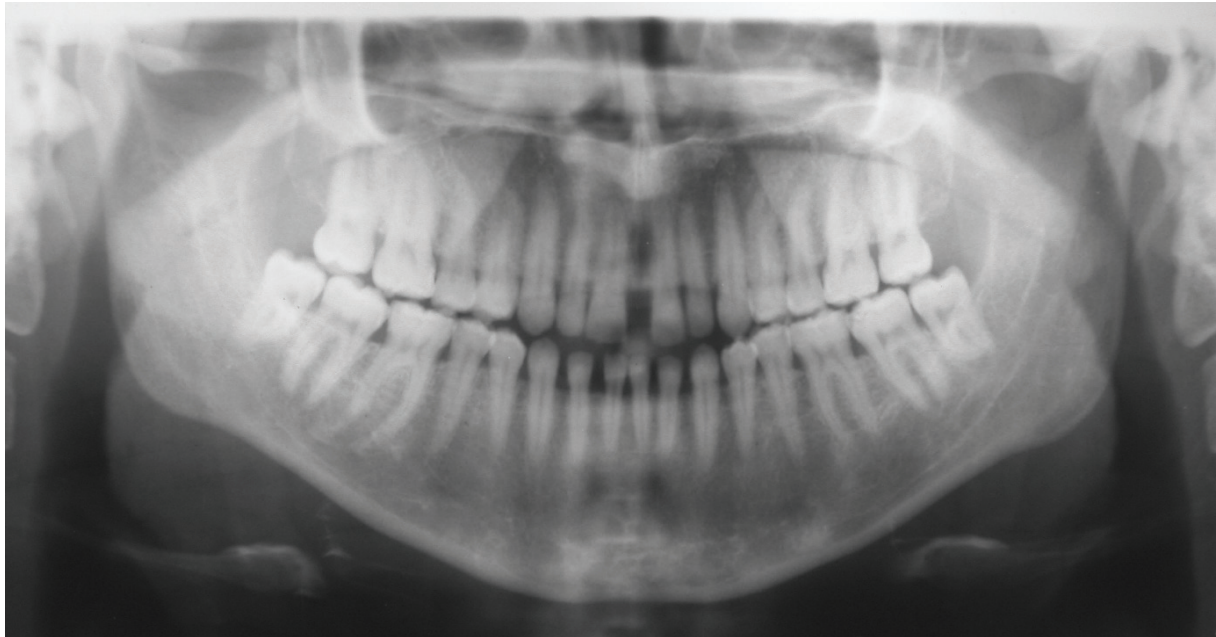


Figure 2. Pre-treatment panoramic radiograph.

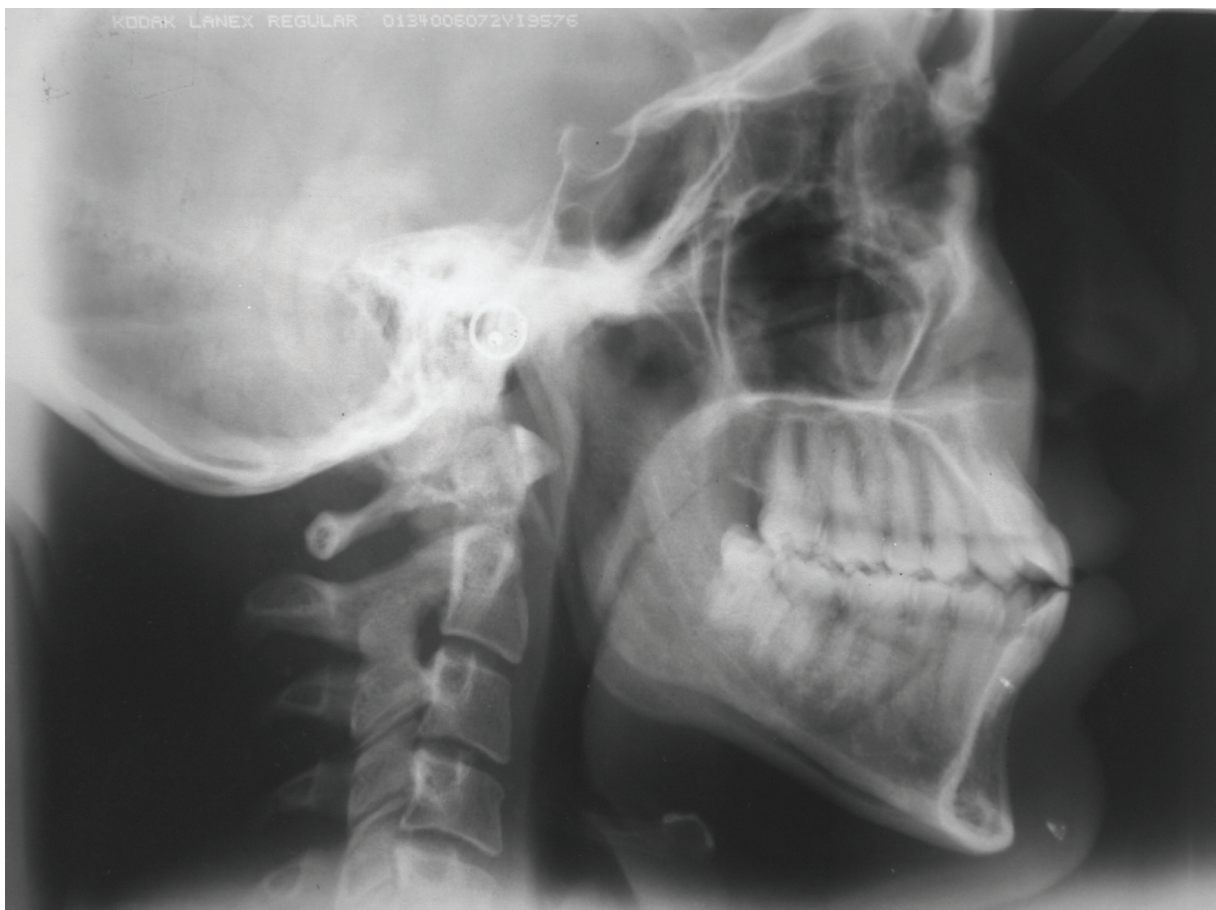

Figure 3. Pre-treatment cephalometric radiograph.



procedures were planned to improve dental stability. An informed written consent was obtained from the patient and gingivoplasty, frenectomy, and fibrotomy procedures were performed under local anesthesia.

Retention was provided by wearing upper and

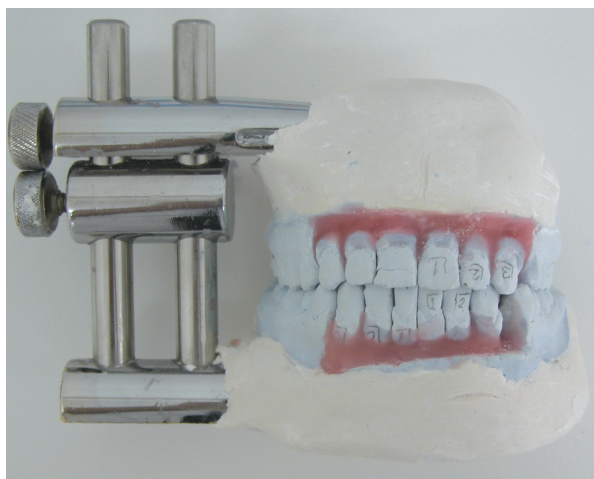

Figure 4. Diagnostic set-up of dental casts.

lower removable retainers in the day time and positioner in the night time. Due to high risk of relapse, upper and lower fixed retainers were placed simultaneously.

#### Treatment results

Post-treatment evaluation showed that patient's complaints had been addressed. Teeth were esthetically pleasing while smiling. Lip competence was improved and soft tissue profile changed favorably due to the correction of lip position (Figure 5). Upper and lower arches were well aligned. All spaces were closed successfully. Posterior occlusion had good overall intercuspation and was well settled in a Class I relationship. Normal overjet and overbite were achieved. Upper and lower dental midlines were compatible with facial midline (Figure 5). Mild speech difficulty while pronouncing "s" was eliminated.

Cephalometric analysis showed that skeletal pattern changed with the clockwise rotation

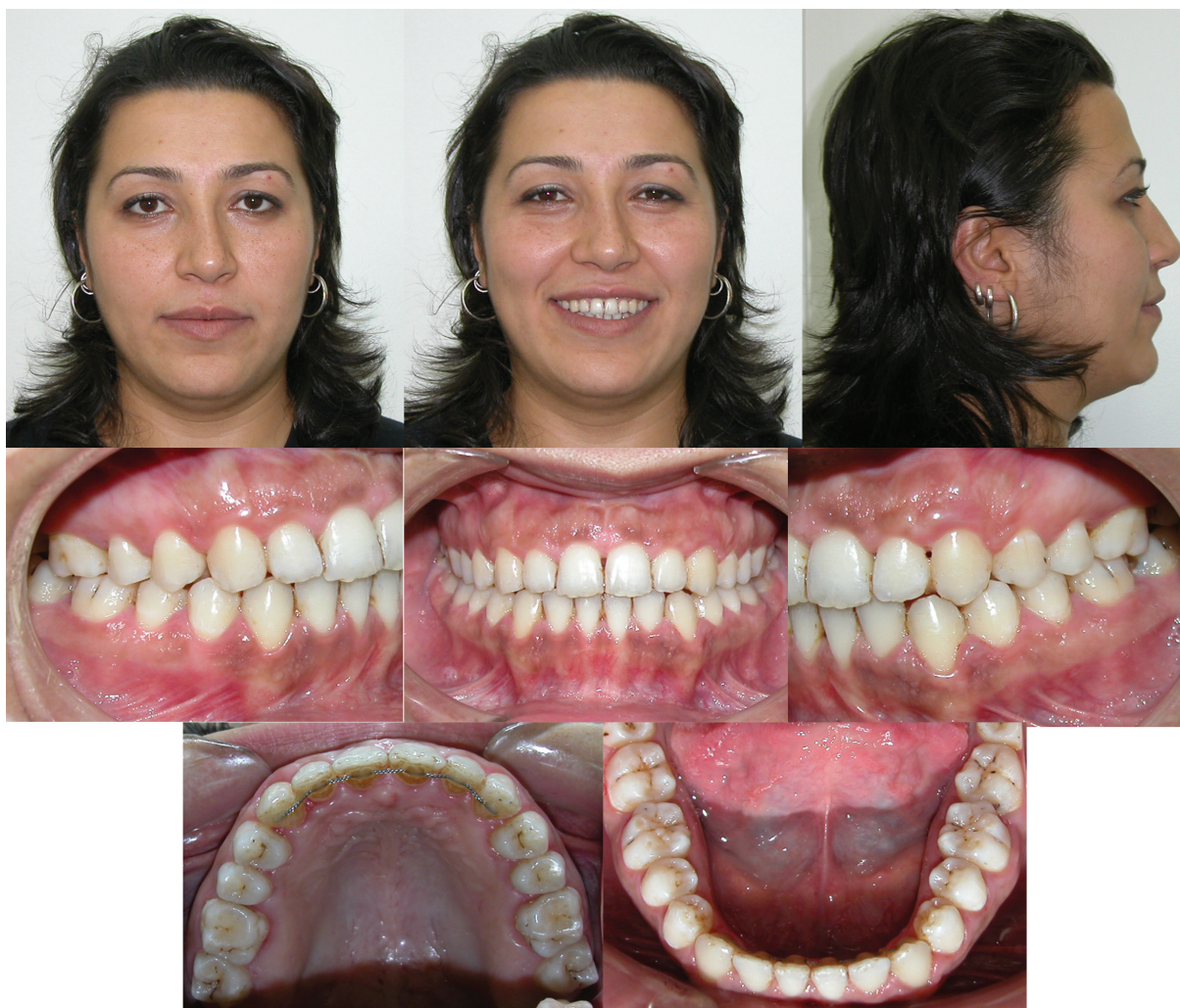

Figure 5. Post-treatment extraoral and intraoral photographs.



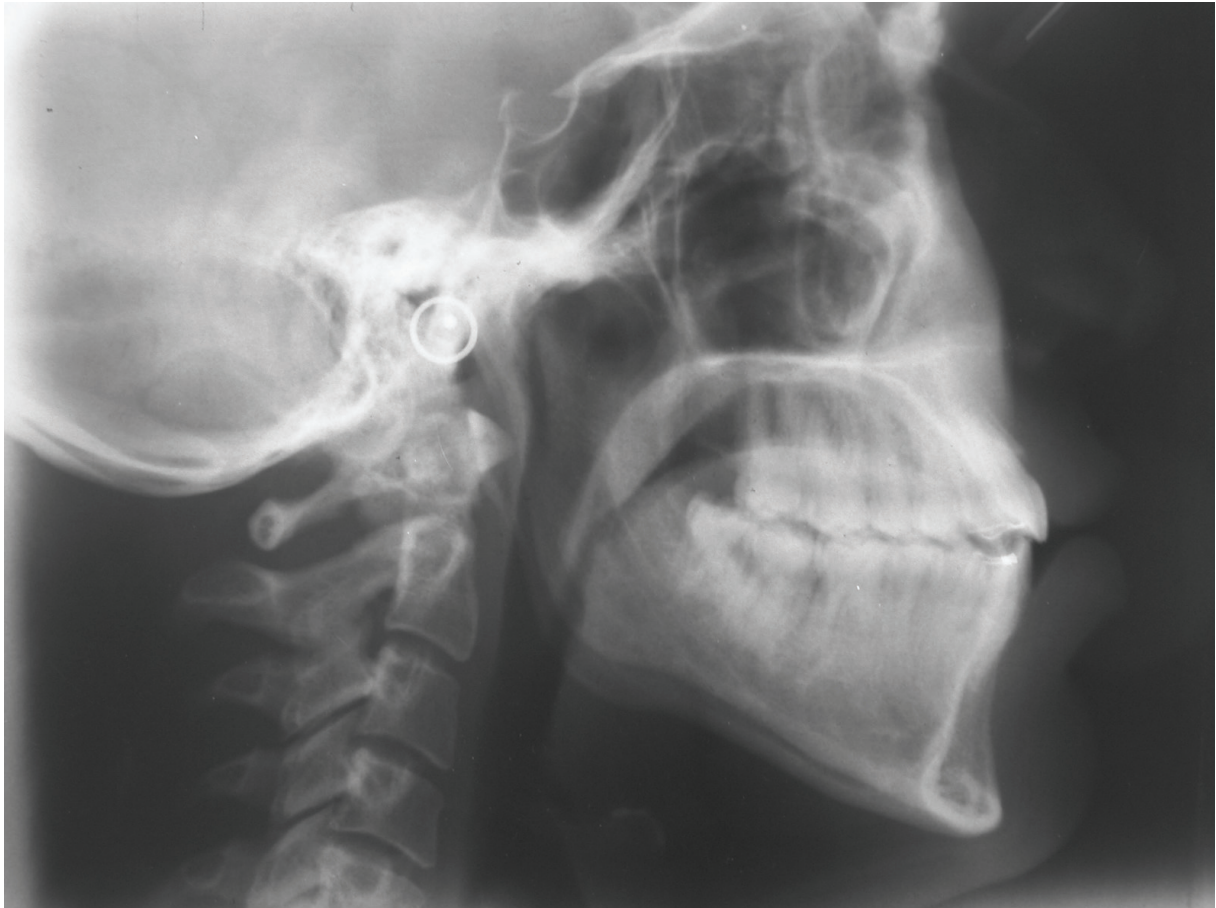

Figure 6. Post-treatment cephalometric radiograph.

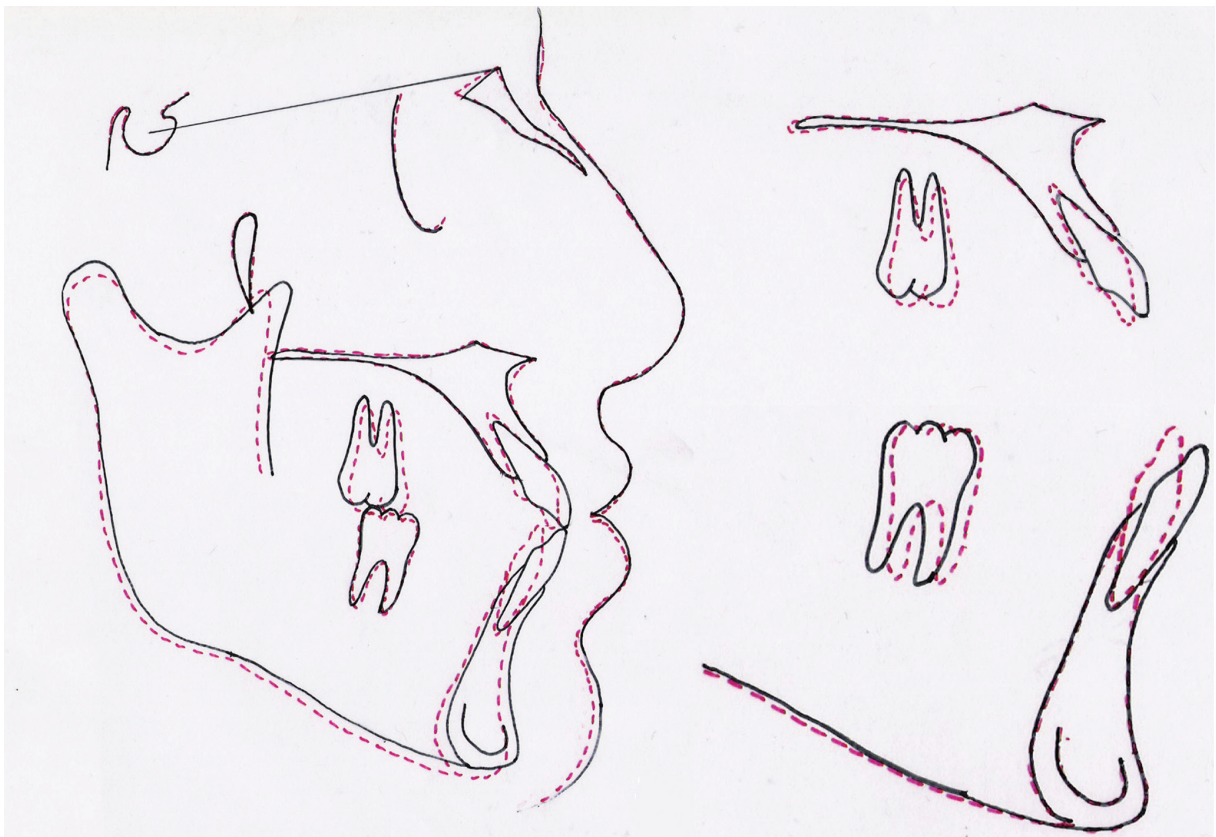


Figure 7. Pre-treatment and post-treatment cephalometric superimpositions.

of mandible. The inclinations of upper and lower incisors were improved. Lower facial height increased slightly (Figure 6, Table 1). Upper first molars moved forward and downward while lower first molars were uprighted (Figure 7).

The 6-month post-treatment stability has been good (Figure 8). Superimposition of post-treatment and post-retention cephalometric radiographs showed that treatment results were stable (Figure 9).

## DISCUSSION

Spacing between anterior teeth is a normal condition most often seen at the mixed dentition stage. It closes during further development. If it does not close with time, there is probably an etiological factor that is genetic, acquired or functional. Spacing between teeth is a common esthetic problem especially for adults.

All forms of spaced dentition may look very

similar to each other, but various factors contribute by different amounts to their etiology. Tongue thrust and abnormal upper lip frenum play an important role in the etiology of spaced dentition in combination with open-bite.<sup>8-10</sup> Thus, it is not surprising that treatment of these patients involves a variety of treatment approaches. Orthodontic space closure has always been considered the most appropriate treatment alternative because prosthetic restorations in spaced dentition cases may sometimes create periodontal problems.<sup>11</sup>

Diagnostic set-up of dental casts may be useful for treatment planning and patient information in cases of spaced dentition.<sup>12</sup> The diagnostic set-up of this patient allowed us to evaluate the dental arches in three dimensions. Orthodontic space closure was planned by retracting labially inclined incisors to achieve normal overjet and overbite relationship.

In patients with oral habits, space closure and

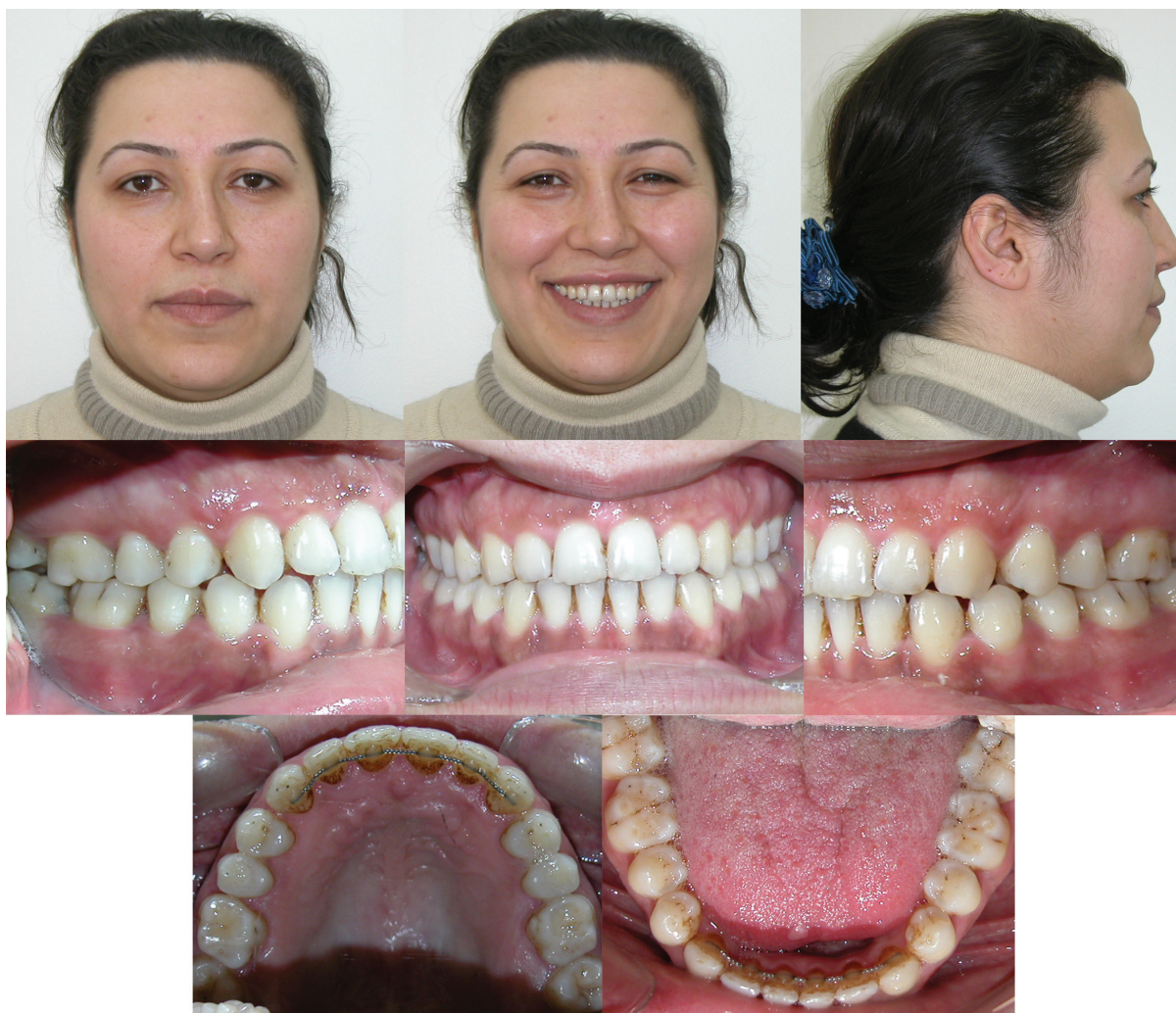

Figure 8. 6-month post-retention extraoral and intraoral photographs.



orthodontic management of teeth should not be attempted unless the patient has stopped the habit.<sup>13,14</sup> Before orthodontic treatment, instruction about true tongue positioning during functional movements like speech and swallowing were given. These exercises were continued during treatment to adapt the musculature to new function.

Class III intermaxillary elastics were used to retract the lower anterior teeth and correct the sagittal Class III relationship in this patient. As a result, a clockwise rotation of the mandible occurred with favorable changes in ANB angle and soft tissue profile. It is known that Class III intermaxillary elastics have an extrusive effect, causing extrusion of the upper molars. Extrusion of upper molars rotates the mandible downward. However, a limited downward rotation of the mandible can assist in correcting Class III malocclusion.<sup>15</sup> In this patient, upper molars extruded slightly due to Class III intermaxillary elastics, but the slight increase in FMA angle did not cause relapse at post-retention 6-month period in this patient. Also, it was useful to solve the problem.

Near the end of treatment, all spacings were closed but enough overbite was not achieved. Thus, upper incisors were extruded with a .016x.022

inch TMA extrusion base arch to achieve a normal overbite. However, the gingival tissues of upper anterior teeth moved downward simultaneously. There is evidence that the alveolar process and gingival tissues move in the same direction with the vertical movement of the tooth.<sup>16,17</sup> Hence, gingivoplasty was performed to eliminate the gummy smile appearance.

Maintaining the treatment results is of major clinical importance in spaced dentition cases. Generalized or localized spacing in combination with open-bite is the most common malocclusion to relapse after treatment if a strict retention protocol is not followed. Removable retainers alone cannot prevent the actual translation of the center of resistance in vertical direction. Stability in open-bite and spaced dentition cases is obtained by following a conservative retention protocol and applying fixed retention.<sup>18</sup> In this patient, upper and lower fixed retainers in combination with Hawley appliances were worn in the day time. Positioner appliance was given to wear in the night time. Positioner appliance was reported to be effective in preventing relapse of open-bite malocclusion.<sup>19</sup>

Procedures to the surrounding periodontium to aid the retention process such as circumfer-

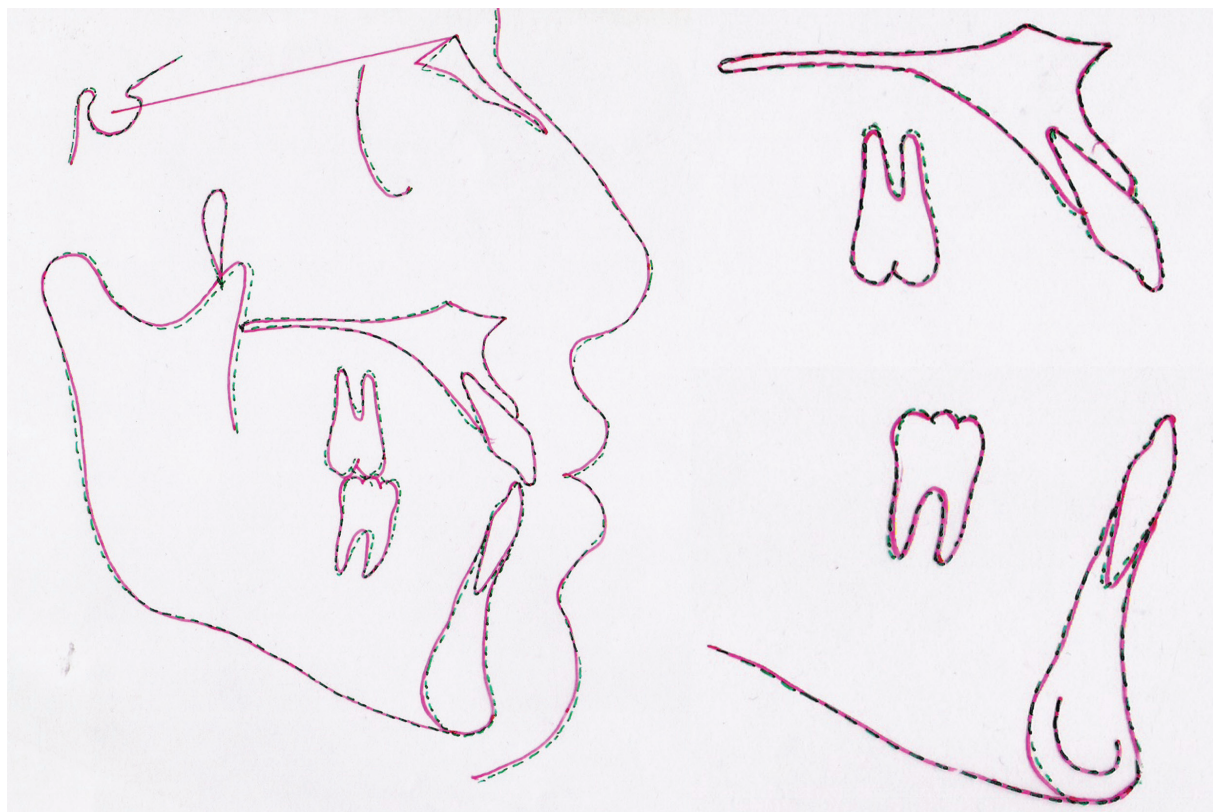


Figure 9. Post-treatment and post-retention cephalometric superimpositions.



ential supracrestal fiberotomy enhance stability.<sup>20</sup> Frenectomy is also a recommended retention procedure to maintain the treatment outcome. In this case, the excision of the upper high frenum was postponed to the end of orthodontic treatment to allow for scar tissue formation and maintaining the closure of diastema.<sup>1,19,15</sup> Treatment outcome was stable after post-retention 6 months.

## CONCLUSIONS

The present case demonstrated treatment and retention procedures in an adult patient with spaced dentition and Class III open-bite tendency to accomplish esthetic, functional, and stable results.

## ACKNOWLEDGMENTS

We thank Dr. Tolga Fikret Tözüm of the Department of Periodontology for the periodontologic phase of treatment for this patient.

## REFERENCES

- Gkantidis N, Psomiadis S, Topouzelis N. Teeth spacing: Etiology and treatment. *Hel Orth Rev* 2007;10:75-92.
- Kerosuo H, Hausen H, Laine T, Shaw WC. The influence of incisal malocclusion on the social attractiveness of young adults in Finland. *Eur J Orthod* 1995;17:505-512.
- Steigman S, Gershkovitz E, Harari D. Characteristics and stability of spaced dentition. *Angle Orthod* 1985;55:321-328.
- Steigman S, Weissberg Y. Spaced dentition. An epidemiologic study. *Angle Orthod* 1985;55:167-176.
- Lavelle CL. A study multiracial malocclusions. *Community Dent Oral Epidemiol* 1976;4:38-41.
- Magnusson TE. An epidemiologic study of dental space anomalies in Icelandic schoolchildren. *Community Dent Oral Epidemiol* 1977;5:292-300.
- Thind BS, Stirrups DR, Forgie AH, Larmour CJ, Mossey PA. Management of hypodontia: orthodontic considerations (II). *Quintessence Int* 2005;36:345-353.
- Moyers R. *Handbook of Orthodontics*. 4th ed. Chicago, USA: Year Book Medical Publishers, 1988.
- Gardiner JH. Midline spaces. *Dent Pract Dent Rec* 1967;17:287-298.
- Oesterle LJ, Shellart WC. Maxillary midline diastemas: a look at the causes. *J Am Dent Assoc* 1999;130:85-94.
- Nordquist GG, McNeill RW. Orthodontic vs. restorative treatment of the congenitally absent lateral incisor: long term periodontal and occlusal evaluation. *J Periodontol* 1975;46:139-143.
- Carlyle LW 3rd, Richardson JT. The diagnostic wax-up: an aid in the treatment planning. *Tex Dent J* 1985;102:10-12.
- Haskell BS, Mink JR. An aid to stop thumb sucking: the "Bluegrass" appliance. *Pediatr Dent* 1991;13:83-85.
- Cipes MH, Miraglia M, Gaulin-Kremer E. Monitoring and reinforcement to eliminate thumbsucking. *ASDC J Dent Child* 1986;53:48-52.
- Proffit WR, Fields HW. *Contemporary orthodontics*. 2nd ed. St. Louis: Mosby-Year Book; 1993.
- Kozlovsky A, Lieberman M. Forced eruption combined with gingival fiberotomy. A technique for clinical crown lengthening. *J Clin Periodontol* 1988;15:534-538.
- Isaacson RJ, Lindauer SJ. Closing anterior open bites: the extrusion arch. *Semin Orthod* 2001;7:34-41.
- Zachrisson BU. Important aspects of long-term stability. *J Clin Orthod* 1997;31:562-583.
- Enacar A, Ugur T, Toroglu S. A metod for correction of open bite. *J Clin Orthod* 1996;30:43-48.
- Taner TU, Haydar B, Kavuklu I, Korkmaz A. Short-term effects of fiberotomy on relapse of anterior crowding. *Am J Orthod Dentofac Orthop* 2000;118:617-623.