

Original

## Effects of bovine lactoferrin in surgically created bone defects on bone regeneration around implants

Ulaş Görmez<sup>1)</sup>, Mehmet Kürkcü<sup>2)</sup>, Mehmet E. Benlidayi<sup>2)</sup>, Kezban Ulubayram<sup>3)</sup>,  
Yaşar Sertdemir<sup>4)</sup>, and Kenan Dağlıoğlu<sup>5)</sup>

<sup>1)</sup>Private Practice in Oral and Maxillofacial Surgery, Antalya, Turkey

<sup>2)</sup>Department of Oral and Maxillofacial Surgery, Faculty of Dentistry, Çukurova University, Adana, Turkey

<sup>3)</sup>Department of Basic Pharmaceutical Sciences, Faculty of Pharmacy, Hacettepe University, Adana, Turkey

<sup>4)</sup>Department of Biostatistics, Faculty of Medicine, Çukurova University, Adana, Turkey

<sup>5)</sup>Medical Experimental Research Centre, Çukurova University, Adana, Turkey

(Received September 29, 2014; Accepted January 15, 2015)

**Abstract:** The aim of this experimental study was to evaluate the effect of bovine lactoferrin (bLF)-loaded gelatin microspheres (GM) used in combination with anorganic bovine bone on bone regeneration in surgically created bone defects around tooth implants. Twenty-four uniform bone defects were created in the frontal bone via an extraoral approach in 12 domestic pigs. Twenty-four implants were placed at the center of the defects. In eight animals one of these defects was filled with 0.3 mL anorganic bovine bone while the other was left empty. In four animals, all defects were filled with 3 mg/defect bLF-loaded GM and anorganic bovine bone. All the defects were covered with collagen membranes. All animals were sacrificed after 10 weeks of healing, and the implants with the surrounding bone defects were removed *en bloc*. Undecalcified sections were prepared for histomorphometric analysis. The mean total area of hard tissue was  $26.9 \pm 6.0\%$  in the empty defect group,  $31.8 \pm 8.4\%$  in the graft group, and  $47.6 \pm 5.0\%$  in the lactoferrin group ( $P < 0.001$ ). The mean area of newly formed bone was  $26.9 \pm 6.0\%$  in the empty defect group,  $22.4 \pm 8.2\%$  in the graft group, and  $46.1 \pm 5.1\%$  in the lactoferrin group ( $P < 0.001$ ). The mean residual graft area was  $9.4 \pm 3.2\%$  in the graft group

and  $1.5 \pm 0.6\%$  in the lactoferrin group ( $P < 0.001$ ). The mean proportion of bone-implant contact in the defect region was  $21.9 \pm 8.4\%$  in the empty defect group,  $26.9 \pm 10.1\%$  in the graft group and  $29.9 \pm 10.3\%$  in the lactoferrin group ( $P = 0.143$ ). These data indicate that a combination of 3 mg bLF-loaded GM and bovine-derived HA promotes bone regeneration in defects around implants.

(J Oral Sci 57, 7-15, 2015)

Keywords: bovine lactoferrin; controlled release; histomorphometry; implant; bone defect.

### Introduction

Implant therapy has become a predictable and reliable treatment protocol for replacement of missing teeth. Immediate implant placement into fresh extraction sockets has also yielded successful clinical results (1-3). When dental implants are placed into fresh extraction sockets, there may be insufficient contact between the alveolar bone and implant surface at the coronal half of the implant. Several treatment modalities and materials have been used for increasing the bone volume around implants. Although autogenous bone is the ideal grafting material, xenogenic bone grafting substitutes have been widely used for bone regeneration around dental implants (4). In order to increase the capabilities of xenogenic bone substitutes, anabolic agents can be combined with the grafting materials (5). The results of basic scientific and clinical studies have shown that different growth and

Correspondence to Dr. Ulaş Görmez, Metin Kasapoglu Cad. Ayhan Kadam İş Merkezi, No: 11 Antalya, Turkey  
E-mail: info@drulasgormez.com

doi.org/10.2334/josnusd.57.7

DN/JST.JSTAGE/josnusd/57.7

differentiation factors enhance the regeneration of bone (5-7). Lactoferrin is an anabolic peptide that has been proven to induce bone growth *in vivo* (8,9). Cornish et al. (10) have suggested that lactoferrin acts on bone cells at periphysiological concentrations and might have a therapeutic role for bone repair. Lactoferrin enhances bone growth through a proliferative and anti-apoptotic effect on osteoblasts while inhibiting osteoclastogenesis (11). The regenerative potential of agents such as lactoferrin is highly dependent on the method of application (12). Controlled release of biomaterials enhances their efficacy and reduces the total protein dosage. Preference for gelatin as a drug delivery system in the biomedical field is very widespread since it is non-toxic, biodegradable, cheap and non-immunogenic (13).

Surgically created bone defects around implants have been widely used by several authors in order to simulate extraction sockets, although there has been some controversy about this approach (14-16).

The aim of this experimental study was to evaluate the bone regeneration effect of gelatin microspheres loaded with bovine lactoferrin used in combination with anorganic bovine bone in surgically created bone defects around implants.

## Materials and Methods

### Preparation of gelatin microspheres loaded with bovine lactoferrin

Gelatin microspheres (GM) containing bovine-derived lactoferrin (bLF) were prepared by adding the bioactive agent (bLF, 50 mg in 1 mL phosphate buffer, 0.01 M, pH = 7.4) to the gelatin solution. These treated microspheres are referred to as GM-bLF hereafter. The microspheres were hardened with glutaraldehyde treatment. For this purpose, aqueous glutaraldehyde solution (1 mL, 5%) was added to a water-oil emulsion of the microspheres. Unreacted glutaraldehyde and paraffin oil were removed by filtering and washing with water and acetone. The obtained microspheres were then dried at room temperature.

### *In vitro* gelatin microsphere degradation

The release of bLF from the microspheres was studied by incubating the samples in phosphate buffer solution (0.01 M, pH = 7.4) using a shaking bath at constant temperature (37°C). In the GM-bLF system, approximately 3 mg of bLF was released during 24 days. By increasing the cross-linking density of the microspheres, it became possible to extend the duration of bLF release from a few hours to weeks.

### Animals

Twelve 6-month-old domestic pigs bred at the Medical Experimental Research Center (TIBDAM) at Çukurova University were used in the study. At the time of surgery their body weight was  $40 \pm 5$  kg. They were kept on high-calorie feed and allowed water *ad libitum*. The study was approved by the local animal ethics committee (DHF2006D7).

### Anesthesia and medication

The animals were premedicated with intramuscular (im) injections of 20 mg/kg ketamine (Alfamyne, Egevet, İzmir, Turkey) and 2 mg/kg xylazine (Rompun, Bayer, İstanbul, Turkey). General anesthesia was induced by intravenous (iv) administration of 15 mg/kg thiopental sodium (Pental Sodium, İbrahim Etım, İstanbul, Turkey). In addition, 4 mL of local anesthetic (Marcaine, Astra Zeneca, İstanbul, Turkey) was injected into the surgically treated region. As a prophylactic antibiotic, 600 mg clindamycin (Klindan, Bilim İlaç, İstanbul, Turkey) was administered i.v. preoperatively to all animals. Post-operatively, all animals received 600 mg clindamycin to prevent infections and 500 mg metamizol sodium (Novalgine, Aventis, İstanbul, Turkey) for pain relief, both intramuscularly for 3 days.

### Surgical procedure

All surgical procedures were carried out with due attention to aseptic precautions. Full-thickness trapezoidal incisions were made at the forehead region over the frontal bone, 5 cm below the superior border. After exposure of the frontal bone, two uniform cylindrical defects 9 mm in diameter and 4 mm in depth were created in each animal using a trephine bur. Twenty-four titanium implants (Aesthetica Euroteknika, Sallanches, France), 3.6 mm in diameter and 8 mm in length, with a sand-blasted acid-etched (SLA) surface were placed at the center of each surgically created uniform defect (Fig. 1). The resulting artificial circumferential bone defects simulated alveolar defects with a circular gap of 2.7 mm. In eight animals, one of the circumferential defects around the implant was filled with 0.3 mL anorganic bovine-derived bone (Unilab Surgibone, Mississauga, Ontario, Canada) (graft group) while the other defects were left empty (empty defect group). In the remaining four animals, eight defects (two defects per animal) were filled with 0.3 mL anorganic bovine-derived bone together with 3 mg GM-bLF (lactoferrin group). All of the surgically created defects were covered with 22×22 mm collagen barrier membranes (Collagen AT, Centro Di Odontoiatria Operativa, Padova, Italy) (Fig. 2). All

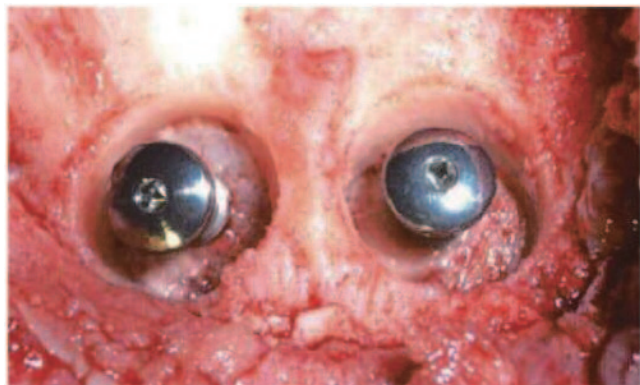


Fig. 1 Placement of dental implants into surgically created defects.

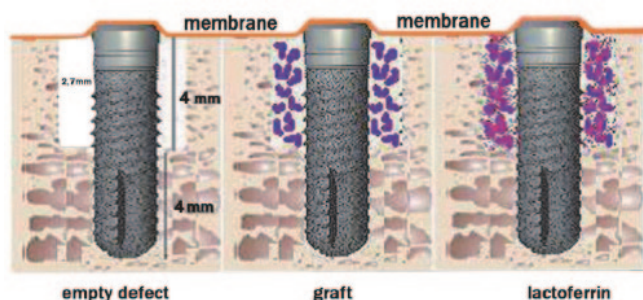


Fig. 2 Schematic drawing of the surgical procedure.

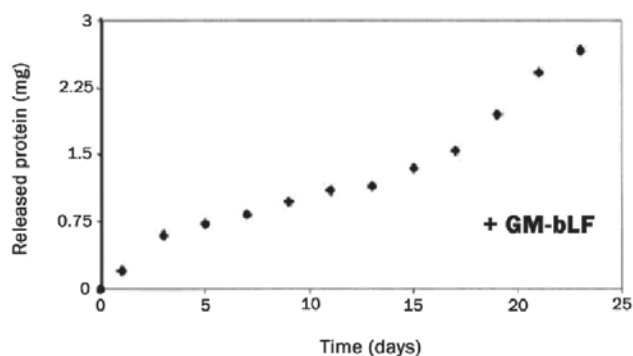


Fig. 3 Degradation of GM.

animals were sacrificed after 10 weeks of healing.

### Histomorphometry

The implants with surrounding defects were removed *en bloc* and immersed in 4% neutral buffered formaldehyde for histologic evaluation. The specimens were dehydrated in a graded series of ethanol and embedded in methyl methacrylate-based resin (Technovit 7200 VLC, Kulzer & Co, Wehrheim, Germany). Undecalcified ground sections from the implants and surrounding bone were prepared according to the method described by Donath and Breuner (17). Sections of each experimental site were taken through the longitudinal axis of each implant and reduced to a thickness of 40  $\mu\text{m}$ . Two sections were

prepared from each block and stained with toluidine blue. All sections were used for histomorphometric evaluation. Digital images of the sections were obtained using a digital camera (Olympus DP 70, Olympus Co., Tokyo, Japan) attached to a microscope (Olympus BX50, Olympus) at a magnification of  $\times 4$ . The obtained images were then transferred to a PC and subjected to histomorphometric analysis using Bioquant Osteo II image analysis software (Bioquant Image Analysis Co., Nashville, TN, USA). The following histomorphometric measurements were made:

1. Total hard tissue in the circumferential bone defect around the implant (proportion of total area of hard tissue relative to total area of the defect).
2. Newly formed bone in the circumferential bone defect around the dental implant (proportion of area of newly formed bone relative to total area of the defect).
3. Residual graft material in the circumferential bone defect around the implants (proportion of area of residual graft material relative to total area of the defect).
4. Bone to implant contact (BIC) along the implant surface in the surgically created bone defect (proportion of linear bone in contact with the implant measured from the top of the implant to the base of the defect).

### Statistical analysis

For statistical analysis of the acquired data, the SPSS 16.0 software package was used. Mean, standard deviation, median, maximum and minimum values were summarized for the percentage values of total hard tissue, newly formed bone, residual graft material and bone to implant contact. The Kruskal-Wallis test was used to compare values among groups, and the Mann-Whitney  $U$  test for comparisons between two groups. Differences at  $P < 0.05$  were accepted to be statistically significant. The Bonferroni correction was applied for multiple group comparisons, and  $P$ -values of  $< 0.017$  were considered to indicate statistical significance.

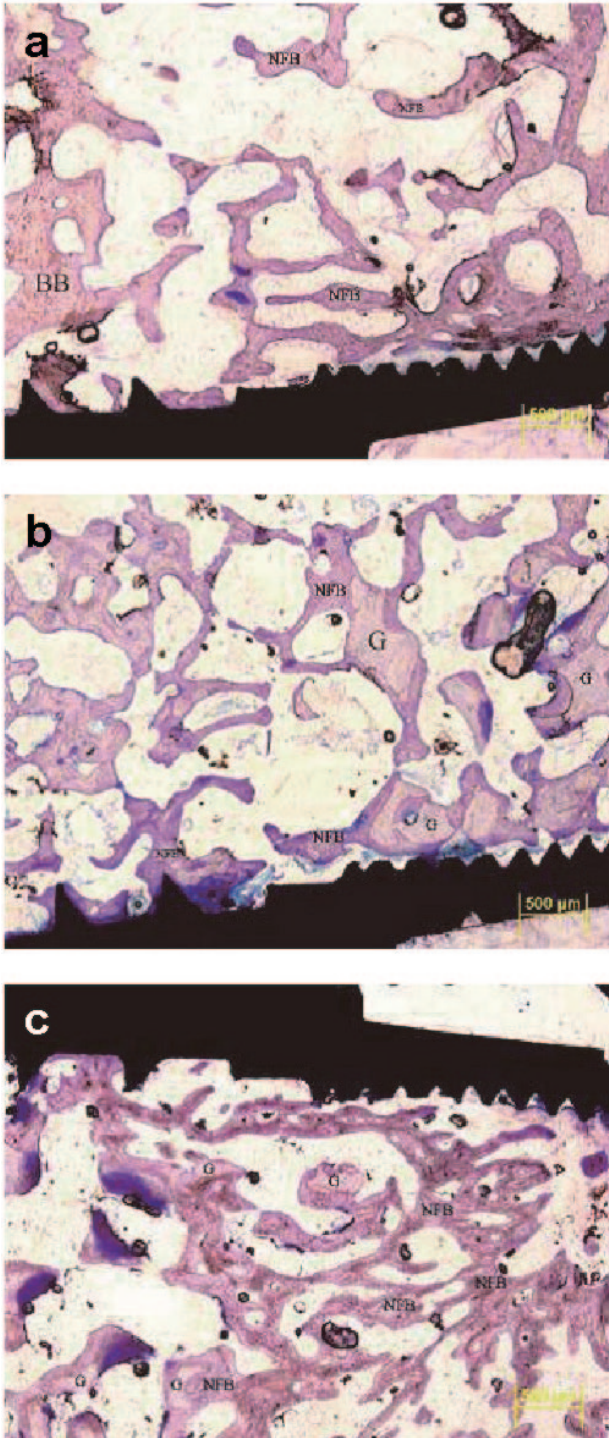
### Results

After 10 weeks of uneventful healing, all the implants showed successful osseointegration. Histological and histomorphometric analyses were performed as described above.

#### *In vitro* degradation of gelatin microspheres

*In vitro* degradation of the gelatin microspheres was progressive, and complete within 24 days (Fig. 3).



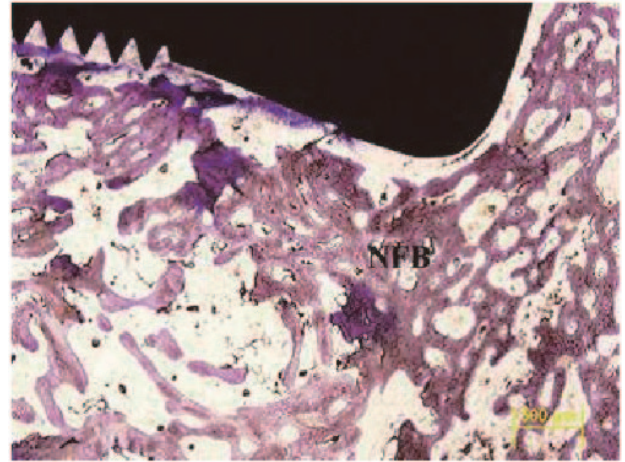


**Fig. 4** Bone regeneration around a dental implant in the empty defect group (a), the graft group (b), and the lactoferrin group (c). Toluidine blue,  $\times 4$  magnification.

BB: basal bone, NFB: newly formed bone, G: graft.

### Histological analysis

All 24 implants were found to be in contact with basal and newly formed bone after 10 weeks of healing (Fig. 4). Staining allowed us to determine the differences between



**Fig. 5** Bone regeneration over the top of an implant in the lactoferrin group.

Toluidine blue,  $\times 4$  magnification. NFB: newly formed bone.

preexisting bone, newly formed bone and residual anorganic bovine bone particles, as basal bone and residual graft particles showed weaker staining. Within the defects filled with anorganic bovine bone, residual graft particles appeared to remain unresorbed after 10 weeks of healing. Different amounts of newly formed bone were evident in the defects of all the treatment groups. In the bovine lactoferrin-treated group, significantly more bone was observed around the implants, and bone growth over the top of the implants was detected (Fig. 5).

### Histomorphometric analysis

After 10 weeks of healing, the mean proportion of the total area of hard tissue was  $26.9 \pm 6.0\%$  in the empty defect group,  $31.8 \pm 8.4\%$  in the graft group, and  $47.6 \pm 5.0\%$  in the lactoferrin group (Table 1). The mean percentage area of total hard tissue in the lactoferrin group was significantly greater than in the other two groups ( $P < 0.001$ ), whereas the difference between the empty defect group and the graft group was not statistically significant ( $P = 0.096$ ) (Fig. 6).

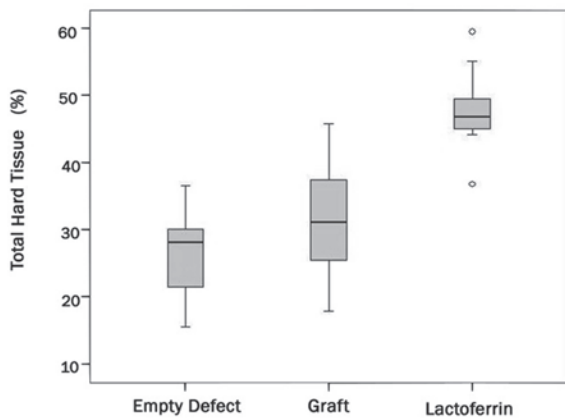
The mean percentage area of newly formed bone after healing was  $26.9 \pm 6.0\%$  in the empty defect group,  $22.4 \pm 8.2\%$  in the graft group, and  $46.1 \pm 5.1\%$  in the lactoferrin group (Table 1). The mean percentage area of newly formed bone in the lactoferrin group was significantly greater than in the other two groups ( $P < 0.001$ ), whereas the difference between the empty defect group and the graft group was not statistically significant (Fig. 7) ( $P = 0.085$ ).

The mean percentage area of residual anorganic bovine bone after healing was measured as  $9.4 \pm 3.2\%$  in the graft group and  $1.5 \pm 0.6\%$  in the lactoferrin group (Table

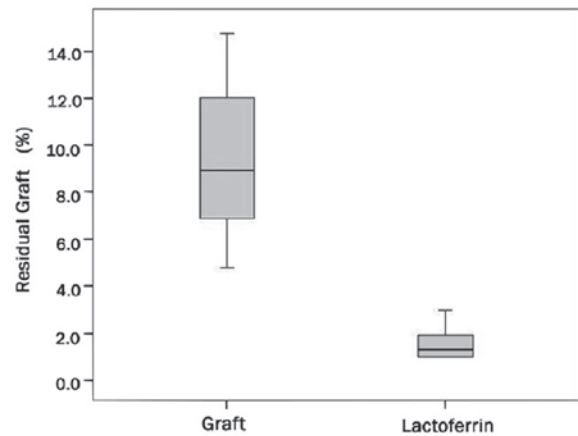
**Table 1** Results of histomorphometric analysis of all parameters

	Empty defect group Mean $\pm$ SD Median (max/min)	Graft group Mean $\pm$ SD Median (max/min)	Lactoferrin group Mean $\pm$ SD Median (max/min)	<i>P</i>
Total hard tissue (%)	26.9 $\pm$ 6.0 <sup>a</sup> 28.2 (37.0/16.0)	31.8 $\pm$ 8.4 <sup>b</sup> 31.1 (46.0/18.0)	47.6 $\pm$ 5.0 <sup>a,b</sup> 46.9 (60.0/37.0)	<0.001
Residual graft (%)	–	9.4 $\pm$ 3.2 8.9 (14.8/4.8)	1.5 $\pm$ 0.6 1.3 (3.0/1.0)	<0.001
Newly formed bone (%)	26.9 $\pm$ 6.0 <sup>a</sup> 28.2 (36.6/15.6)	22.4 $\pm$ 8.2 <sup>b</sup> 21.4 (36.5/10.5)	46.1 $\pm$ 5.1 <sup>a,b</sup> 45.4 (58.7/35.8)	<0.001
BIC (%) (surgically created defect area)	21.9 $\pm$ 8.4 22.3 (37.7/11.0)	26.9 $\pm$ 10.1 29.1 (42.0/10.0)	29.9 $\pm$ 10.3 31.5 (51.1/17.3)	0.143

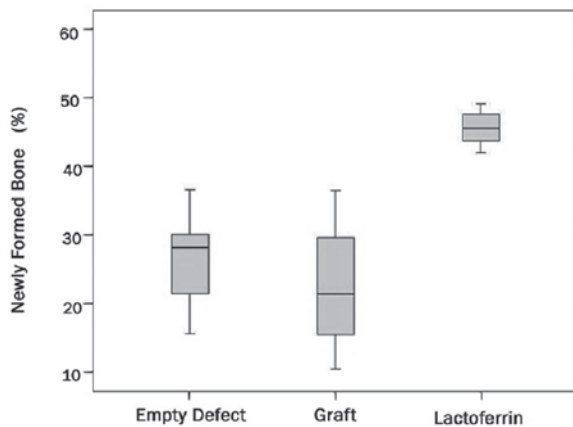
a, b,  $P < 0.017$  (Bonferroni correction)



**Fig. 6** Mean percentage of total hard tissue. Lactoferrin group shows a significantly higher value than the other two groups. ( $P < 0.001$ )



**Fig. 8** Mean residual graft percentage. Lactoferrin group shows a significantly lower value than the graft groups ( $P < 0.001$ ).



**Fig. 7** Mean percentage of new formed bone. Lactoferrin group shows a significantly higher value.

The mean percentage BIC values in the area of the surgically created bone defect were 21.9  $\pm$  8.4%, 26.9  $\pm$  10.1%, and 29.9  $\pm$  10.3% in the empty defect group, graft group and lactoferrin group, respectively ( $P = 0.143$ ) (Table 1).

## Discussion

The results of this histomorphometric study demonstrated the beneficial effect of GM-bLF combined with anorganic bovine bone grafts for bone regeneration in surgically created bone defects around implants in pigs.

The basic characteristic of lactoferrin is its antibacterial activity (18). Lactoferrin also has effects on cell growth and differentiation (8), embryonic development (19), myelopoiesis (20), endothelial cell adhesion (21), cytokine (22) and chemokine (23) production, regulation of the immune system (24) and modulation of the inflammatory response (25). In addition to these complex functions, a recent study showed that lactoferrin promotes osteoblastic activity while inhibiting osteoclastogenesis *in vitro* and *in vivo* (26). Although both human and

1). The mean percentage area of residual anorganic bovine hydroxyapatite (HA) in the lactoferrin group was significantly lower than in the graft group (Fig. 8) ( $P < 0.001$ ).

bovine lactoferrin exerts this bone regeneration effect on cultured rat osteoblasts, bovine lactoferrin yields better results due to the presence of growth factors and lipopolysaccharides (11,26,27). Therefore, bLF was used as an anabolic agent in the present study. We employed the lactoferrin dosage suggested by Cornish (11) in our GM delivery system. This controlled release method was described previously by Ulubayram et al. (13). Use of this drug delivery method is also expected to reduce the total protein dosage, when administered over a time interval of 24 days. As it has been reported that GM alone has no bone-promoting effect (28), control defects treated with GM alone were not used in this study.

Immediate placement of implants into fresh extraction sockets has demonstrated comparable clinical results when conventional procedures are employed (29,30). The surgical procedures used in the present study have already been described by many authors (4,16,31,32). Botticelli et al. (33) demonstrated that extraction sockets and artificially created marginal defects around implants healed in different ways, and that the outcomes also differed. For this reason, the artificial marginal defects created around implants in our study may not have accurately reproduced the post-extraction situation. In previously reported studies, defects of various circumferential sizes have been created. Botticelli et al. (4) suggested that the width of the circumferential defect should be more than 1.25 mm in order to properly evaluate the effectiveness of grafting materials on bone regeneration. This suggestion was supported by Polyzois et al. (32), who used a similar surgical procedure by creating a circumferential defect 2.37 mm in width. In our study, a gap size of 2.7 mm was created in order to prevent spontaneous healing.

To achieve primary stability of implants placed into surgically created defects, at least a half of the full length should be in direct contact with the basal bone (4,14,32). Therefore, we placed the apical half of the implants in direct contact with the basal bone, thus achieving the highest degree of primary implant stabilization.

In the present study, all defects in the three groups were covered with resorbable collagen barriers to provide standardization. Usage of barrier membranes (resorbable or non-resorbable) for these types of defects can enhance the BIC values by preventing ingrowth of soft tissue (34).

To our knowledge, the present study is the first reported to have experimentally assessed the bone-regenerative effect of GM-bLF around implants. The GM-bLF we employed enhanced bone regeneration around dental implants in a similar way to mesenchymal stem cells (31), recombinant bone morphogenetic protein (rhBMP)-2 (5) and parathyroid hormone (PTH) (15)

used in previous studies. A recent study reported by Jung et al. (15) demonstrated the beneficial effect of PTH used in circumferential defects as compared with autogenous bone. Although both bLF and PTH can increase bone mass by expanding the activity and number of osteoblasts, bLF can also regulate and inhibit osteoclastogenesis (26). On the other hand, PTH may decrease bone density by stimulation of osteoclast function when administered in a continuous manner. Therefore, in the study reported by Jung et al. (15), PTH was administered by a pulsed method of controlled release from polyethylene glycol (PEG) gel. Our findings obtained by histomorphometric analysis were also consistent with this report in terms of delivery of the anabolic agent via controlled release.

A number of animal experiments and clinical trials have reported successful results with anorganic bovine bone grafts in peri-implant bone defects (16,32,35,36). The use of anorganic bovine bone as a grafting material yielded results similar to those obtained with autogenous bone transplants in terms of bone regeneration in these types of defects (16). Berglundh and Lindhe (37) reported that anorganic bovine bone showed osteoconductive potential when placed in large self-contained defects in the mandible of beagle dogs, the graft particles becoming surrounded by newly formed bone. The findings of our present study also revealed new bone formation around the graft particles within the defects after 10 weeks of healing.

Although the same amounts of anorganic bovine bone were placed in the defects created in the lactoferrin group and the graft group, the mean percentage area of the residual graft in the lactoferrin group ( $1.5 \pm 0.6\%$ ) was significantly lower than that in the graft group ( $9.4 \pm 3.2\%$ ) ( $P < 0.001$ ). Different results have been reported in terms of the percentage of residual grafts after different healing periods (4,37). Botticelli et al. (4) reported that 13.1% of the graft material remained in circumferential bone defects after 4 months of healing. Although a wider gap size was used in our present study, the percentage of the residual graft area was less than that reported by Botticelli et al. This might be attributable to the higher bone turnover rate in the pig calvaria relative to the canine mandible (38).

Anorganic bovine bone grafts have been reported to gradually become displaced by newly formed host bone during the resorption and remodelling phases (4). Wheeler et al. (39) stated that anorganic bovine bone particles were rapidly replaced by host bone, whereas some authors (40-42) observed slow resorptive activity or no resorption of anorganic bovine bone particles. Our findings are consistent with the hypothesis that



anorganic bovine bone particles show slow resorptive activity. However, in the defects treated with lactoferrin, the resorptive activity of graft particles seemed to be higher. Also, the anorganic bovine bone used in our study contained about 20-29% bovine-derived type I collagen, whereas that used in other studies contained no collagen.

The mean percentage area of total hard tissue in the lactoferrin group was significantly higher than in the other two groups ( $P < 0.001$ ), although the improved values of total hard tissue in the graft group did not reach a statistically significant level. The percentage of newly formed bone in the lactoferrin group was significantly higher than in the other two groups (empty defect and graft group) ( $P < 0.001$ ). There was no significant difference in the percentage of newly formed bone between the empty defect group ( $26.9 \pm 6.0\%$ ) and the graft group ( $22.4 \pm 8.2\%$ ) ( $P = 0.085$ ). This may have been due to the inadequate number of samples employed. In a similar study, Jung et al. (15) reported a value of 49.4% for newly formed bone after 12 weeks of healing around implants using PTH<sub>(1-34)</sub> as an anabolic agent. Although the gap size employed in that study was smaller (1.5 mm), our results were comparable with theirs.

The reported mean BIC of various commercially available dental implants placed into defects of various sizes has ranged from 21% to 74% (43,44). Rough surfaces provide better early BIC than smooth ones (45). Therefore, implants with a rough SLA surface were chosen in the present study. Akimoto et al. (46) reported that as the gap between the bone and implant widened, the amount of BIC decreased and the point of the first BIC shifted apically. Our findings were consistent with theirs. Also this may be the reason for the lack of any significant differences between the groups in terms of the percentage BIC. Although bone regeneration effects of some anabolic agents in circumferential defects have been demonstrated, successful osseointegration has been reported only for MSC (31) and rhBMP-2 (47). However, a recent study (48) concluded that rhBMP-2 did not enhance osseointegration during 12 weeks of healing, in contrast to the results obtained by Cochran et al. (47). In addition, Jung et al. (15) reported that PTH<sub>(1-34)</sub> did not significantly promote osseointegration when compared to an empty defect group. There is no additional information in the literature to support the contention that bLF can enhance osseointegration. In our study, there was no statistically significant difference between the lactoferrin group and the other two groups in terms of BIC value. We consider that the short healing period allowed for bone regeneration around the implants may have been another reason for this result. In the light of our BIC% findings,

further animal studies will be necessary to evaluate the effect of bLF on implant osseointegration.

In conclusion, we have shown that GM-bLF containing 3 mg of bovine lactoferrin used in combination with anorganic bovine bone grafts promotes bone regeneration in large defects (2.7 mm in width) around SLA-surfaced dental implants. In addition, this GM drug delivery system is suitable for controlled release of bovine lactoferrin. However, further studies are required to assess the effectiveness of lactoferrin for different treatment modalities such as those for fractures and osteoporosis.

## Acknowledgments

This study was supported by Çukurova University Research Fund and Çukurova University Faculty of Dentistry Division of Dental Research. We would like to thank SMC Medikal Ltd. for their support.

## References

1. Chen ST, Buser D (2014) Esthetic outcomes of following immediate and early implant placement in the anterior maxilla--a systematic review. *Int J Oral Maxillofac Implants* 29, 186-215.
2. Cooper LF, Reside GJ, Raes F, Garriga JS, Tarrida LG, Wiltfang J et al. (2014) Immediate provisionalization of dental implants placed in healed alveolar ridges and extraction sockets: a 5-year prospective evaluation. *Int J Oral Maxillofac Implants* 29, 709-717.
3. Montoya-Salazar V, Castillo-Oyagüe R, Torres Sánchez C, Lynch CD, Gutiérrez-Pérez JL, Torres Lagares D (2014) Outcome of single immediate implants placed in post-extraction infected and non-infected sites, restored with cemented crowns: a 3-year prospective study. *J Dent* 42, 645-652.
4. Botticelli D, Berglundh T, Lindhe J (2004) The influence of a biomaterial on the closure of a marginal hard tissue defect adjacent to implants. An experimental study in the dog. *Clin Oral Implants Res* 15, 285-292.
5. Jung RE, Glauser R, Schärer P, Hämmerle CHF, Sailer HF, Weber FE (2003) Effect of rhBMP-2 on guided bone regeneration in humans. A randomized, controlled clinical and histomorphometric study. *Clin Oral Implants Res* 14, 556-568.
6. Lynch SE, Buser D, Hernandez RA, Weber HP, Stich H, Fox CH et al. (1991) Effects of the platelet-derived growth factor/insulin-like growth factor-I combination on bone regeneration around titanium dental implants. Results of a pilot study in beagle dogs. *J Periodontol* 62, 710-716.
7. Cho MI, Lin WL, Genco RJ (1995) Platelet-derived growth factor-modulated guided tissue regenerative therapy. *J Periodontol* 66, 522-530.
8. Naot D, Grey A, Reid IR, Cornish J (2005) Lactoferrin--a novel bone growth factor. *Clin Med Res* 3, 93-101.
9. Yoshimaki T, Sato S, Tsunori K, Shino H, Iguchi S, Arai Y et

- al. (2013) Bone regeneration with systemic administration of lactoferrin in non-critical-sized rat calvarial bone defects. *J Oral Sci* 55, 343-348.
10. Cornish J, Palmano K, Callon KE, Watson M, Lin JM, Valenti P et al. (2006) Lactoferrin and bone; structure-activity relationships. *Biochem Cell Biol* 84, 297-302.
  11. Cornish J (2004) Lactoferrin promotes bone growth. *Biometals* 17, 331-335.
  12. Sigurdsson TJ, Nygaard L, Tatakis DN, Fu E, Turek TJ, Jin L et al. (1996) Periodontal repair in dogs: evaluation of rhBMP-2 carriers. *Int J Periodontics Restorative Dent* 16, 524-537.
  13. Ulubayram K, Eroglu I, Hasirci N (2002) Gelatin microspheres and sponges for delivery of macromolecules. *J Biomater Appl* 16, 227-241.
  14. Veis AA, Papadimitriou S, Trisi P, Tsirlis AT, Parissis NA, Kenealy JN (2007) Osseointegration of Osseotites and machined-surfaced titanium implants in membrane-covered critical-sized defects: a histologic and histometric study in dogs. *Clin Oral Implants Res* 18, 153-160.
  15. Jung RE, Cochran DL, Domken O, Seibl R, Jones AA, Buser D et al. (2007) The effect of matrix bound parathyroid hormone on bone regeneration. *Clin Oral Implants Res* 18, 319-325.
  16. Abushahba F, Renvert S, Polyzois I, Claffey N (2008) Effect of grafting materials on osseointegration of dental implants surrounded by circumferential bone defects. An experimental study in the dog. *Clin Oral Implants Res* 19, 329-334.
  17. Donath K, Breuner G (1982) A method for the study of undecalcified bones and teeth with attached soft tissues. The Säge-Schliff (sawing and grinding) technique. *J Oral Pathol* 11, 318-326.
  18. Weinberg ED (2001) Human lactoferrin: a novel therapeutic with broad spectrum potential. *J Pharm Pharmacol* 53, 1303-1310.
  19. Ward PP, Mendoza-Meneses M, Mulac-Jericevic B, Cunningham GA, Saucedo-Cardenas O, Teng CT et al. (1999) Restricted spatiotemporal expression of lactoferrin during murine embryonic development. *Endocrinology* 140, 1852-1860.
  20. Sawatzki G, Rich IN (1989) Lactoferrin stimulates colony stimulating factor production in vitro and in vivo. *Blood Cells* 15, 371-385.
  21. Baveye S, Ellass E, Mazurier J, Legrand D (2000) Lactoferrin inhibits the binding of lipopolysaccharides to L-selectin and subsequent production of reactive oxygen species by neutrophils. *FEBS Lett* 469, 5-8.
  22. Guillén C, McInnes IB, Vaughan DM, Kommajosyula S, Van Berkel PH, Leung BP et al. (2002) Enhanced Th1 response to *Staphylococcus aureus* infection in human lactoferrin-transgenic mice. *J Immunol* 168, 3950-3957.
  23. Ellass E, Masson M, Mazurier J, Legrand D (2002) Lactoferrin inhibits the lipopolysaccharide-induced expression and proteoglycan-binding ability of interleukin-8 in human endothelial cells. *Infect Immun* 70, 1860-1866.
  24. Frydecka I, Zimecki M, Bocko D, Kosmaczewska A, Teodorowska R, Ciszak L et al. (2002) Lactoferrin-induced up-regulation of zeta (zeta) chain expression in peripheral blood T lymphocytes from cervical cancer patients. *Anti-cancer Res* 22, 1897-1901.
  25. Baveye S, Ellass E, Mazurier J, Spik G, Legrand D (1999) Lactoferrin: a multifunctional glycoprotein involved in the modulation of the inflammatory process. *Clin Chem Lab Med* 37, 281-286.
  26. Cornish J, Callon KE, Naot D, Palmano KP, Banovic T, Bava U et al. (2004) Lactoferrin is a potent regulator of bone cell activity and increases bone formation in vivo. *Endocrinology* 145, 4366-4374.
  27. Grey A, Banovic T, Zhu Q, Watson M, Callon K, Palmano K et al. (2004) The low-density lipoprotein receptor-related protein 1 is a mitogenic receptor for lactoferrin in osteoblastic cells. *Mol Endocrinol* 18, 2268-2278.
  28. Hong L, Miyamoto S, Hashimoto N, Tabata Y (2000) Synergistic effect of gelatin microspheres incorporating TGF-beta1 and a physical barrier for fibrous tissue infiltration on skull bone formation. *J Biomater Sci Polym Ed* 11, 1357-1369.
  29. Krump JL, Barnett BG (1991) The immediate implant: a treatment alternative. *Int J Oral Maxillofac Implants* 6, 19-23.
  30. Tolman DE, Keller EE (1991) Endosseous implant placement immediately following dental extraction and alveoloplasty: preliminary report with 6-year follow-up. *Int J Oral Maxillofac Implants* 6, 24-28.
  31. Ito K, Yamada Y, Naiki T, Ueda M (2006) Simultaneous implant placement and bone regeneration around dental implants using tissue-engineered bone with fibrin glue, mesenchymal stem cells and platelet-rich plasma. *Clin Oral Implants Res* 17, 579-586.
  32. Polyzois I, Renvert S, Bosshardt DD, Lang NP, Claffey N (2007) Effect of Bio-Oss on osseointegration of dental implants surrounded by circumferential bone defects of different dimensions: an experimental study in the dog. *Clin Oral Implants Res* 18, 304-310.
  33. Botticelli D, Persson LG, Lindhe J, Berglundh T (2006) Bone tissue formation adjacent to implants placed in fresh extraction sockets: an experimental study in dogs. *Clin Oral Implants Res* 17, 351-358.
  34. Kohal RJ, Mellas P, Hürzeler MB, Trejo PM, Morrison E, Caffesse RG (1998) The effects of guided bone regeneration and grafting on implants placed into immediate extraction sockets: an experimental study in dogs. *J Periodontol* 69, 927-937.
  35. Schou S, Holmstrup P, Jørgensen T, Skovgaard LT, Stoltze K, Hjørting-Hansen E et al. (2003) Anorganic porous bovine-derived bone mineral (Bio-Oss) and ePTFE membrane in the treatment of peri-implantitis in cynomolgus monkeys. *Clin Oral Implants Res* 14, 535-547.
  36. Becker W (2003) Treatment of small defects adjacent to oral implants with various biomaterials. *Periodontol* 2000 33, 26-35.
  37. Berglundh T, Lindhe J (1997) Healing around implants placed



- in bone defects treated with Bio-Oss. An experimental study in the dog. *Clin Oral Implants Res* 8, 117-124.
38. Tudor C, Srour S, Thorwarth M, Stockmann P, Neukam FW, Nkenke E et al. (2008) Bone regeneration in osseous defects-application of particulated human and bovine materials. *Oral Surg Oral Med Oral Pathol Oral Radiol Endod* 105, 430-436.
  39. Wheeler SL, Holmes RE, Calhoun CJ (1996) Six-year clinical and histologic study of sinus-lift grafts. *Int J Oral Maxillofac Implants* 11, 26-34.
  40. Hämmerle CHF, Brägger U, Bürgin W, Lang NP (1996) The effect of the subcrestal placement of the polished surface of ITI implants on the marginal soft and hard tissues. *Clin Oral Implants Res* 7, 111-119.
  41. Schliephake H, Dard M, Planck H, Hierlemann H, Jakob A (2000) Guided bone regeneration around endosseous implants using a resorbable membrane vs a PTFE membrane. *Clin Oral Implants Res* 11, 230-241.
  42. Benlidayi ME, Kürkcü M, Oz IA, Sertdemir Y (2009) Comparison of two different forms of bovine-derived hydroxyapatite in sinus augmentation and simultaneous implant placement: an experimental study. *Int J Oral Maxillofac Implants* 24, 704-711.
  43. Sennerby L, Thomsen P, Ericson LE (1992) A morphometric and biomechanic comparison of titanium implants inserted in rabbit cortical and cancellous bone. *Int J Oral Maxillofac Implants* 7, 62-71.
  44. Wilson TG Jr, Schenk R, Buser D, Cochran D (1998) Implants placed in immediate extraction sites: a report of histologic and histometric analyses of human biopsies. *Int J Oral Maxillofac Implants* 13, 333-341.
  45. Novaes AB Jr, Souza SLS, de Oliveira PT, Souza AMMS (2002) Histomorphometric analysis of the bone-implant contact obtained with 4 different implant surface treatments placed side by side in the dog mandible. *Int J Oral Maxillofac Implants* 17, 377-383.
  46. Akimoto K, Becker W, Persson R, Baker DA, Rohrer MD, O'Neal RB (1999) Evaluation of titanium implants placed into simulated extraction sockets: a study in dogs. *Int J Oral Maxillofac Implants* 14, 351-360.
  47. Cochran DL, Schenk RK, Lussi A, Higginbottom FL, Buser D (1998) Bone response to unloaded and loaded titanium implants with a sandblasted and acid-etched surface: a histometric study in the canine mandible. *J Biomed Mater Res* 40, 1-11.
  48. Salata LA, Burgos PM, Rasmusson L, Novaes AB, Papalexou V, Dahlin C et al. (2007) Osseointegration of oxidized and turned implants in circumferential bone defects with and without adjunctive therapies: an experimental study on BMP-2 and autogenous bone graft in the dog mandible. *Int J Oral Maxillofac Surg* 36, 62-71.