

Case report

An unusual tumor of the neck and mediastinum: lipoblastomatosis resulting in paraparesis

Rıza Dogan^{a,*}, Murat Kara^a, Pinar Firat^b, Gokhan Gedikoglu^b

^aDepartment of Thoracic Surgery, Hacettepe University Faculty of Medicine, 06100 Ankara, Turkey

^bDepartment of Pathology, Hacettepe University Faculty of Medicine, 06100 Ankara, Turkey

Received 18 September 2006; received in revised form 26 October 2006; accepted 7 November 2006; Available online 11 December 2006

Abstract

Lipoblastomatous tumors are quite rare neoplasms deriving from embryonic white fatty tissues, most often seen in infancy and childhood. Lipoblastoma is the focal and well-circumscribed type, whereas lipoblastomatosis is the more infiltrating type of lipoblastomatous tumors. We present a 14-month-old male infant presenting with a mediastinal mass showing paraparesis, who had previously undergone the removal of the cervical part of this mediastinal mass. We removed the mediastinal part of the mass with a posterolateral thoracotomy which proved to be a lipoblastomatosis. We emphasize that this very uncommon tumor located at the neck and mediastinum should be included in the differential diagnosis of infants having gait disturbance.

© 2007 European Association for Cardio-Thoracic Surgery. Published by Elsevier B.V. All rights reserved.

Keywords: Lipoblastomatosis; Neck; Mediastinum; Surgery

1. Introduction

Lipoblastoma and lipoblastomatosis are very rare benign mesenchymal tumors most often found in children less than 3 years old. They may present as a localized well-circumscribed lesion, the so-called lipoblastoma, or as a multicentric, deep and infiltrative type, the lipoblastomatosis. They may arise almost everywhere within the soft tissues, the trunk and the extremities being the most common predilection sites; however, neck is an uncommon location for these tumors [1,2].

Although few cases of lipoblastomas located at the neck have been reported that result in a compression to the spinal cord [3–5], we are not aware of a previous report of a lipoblastomatous tumor with lipoblastomatosis nature presenting with paraparesis as a result of spinal cord compression.

We present a 14-month-old male infant with gait disturbance who underwent excision of the mediastinal part of a tumor of which the cervical part had been removed previously. Histologic examination proved the tumor to be a lipoblastomatosis. We emphasize this very uncommon fatty tissue tumor of fetal origin in the differential diagnosis of

tumors in infancy, which might result in gait disturbance and paraparesis.

2. Case report

A 14-month-old boy was referred with a tumor located at the mediastinum. He presented with gait disturbance and muscle weakness. He had undergone surgical excision of the cervical part of the tumor with posterior hemilaminectomy at the levels of 2–5 thoracic vertebrae 1 month prior to his admission, which was diagnosed as lipoblastomatosis. Laboratory examination showed a borderline hypochromic microcytic anemia with a hemoglobin level as 11.7 g/dl and hematocrit level as 34%. A chest X-ray showed that he had a left-sided mass involving the upper zone of the thorax (Fig. 1A). Computerized chest tomography showed a mass located at the apex of the left hemithorax invading the intercostal spaces. Magnetic resonance imaging revealed that the mass had a wide pedicle at the level of T2 and T3 vertebrae and measured 66 mm × 50 mm × 38 mm in diameters (Fig. 1B). The remaining mediastinal part of the tumor, which involved the first, second and the third intercostal spaces, had been removed by a posterolateral thoracotomy. Histologic diagnosis of the mediastinal part of the tumor was consistent with the previous diagnosis of lipoblastomatosis and showed an immature fetal fatty tissue tumor separated by distinct connective tissue septa.

* Corresponding author. Address: Hacettepe University, Faculty of Medicine, Department of Thoracic Surgery, TR-06100, Sıhhiye, Ankara, Turkey.
Tel.: +90 312 3051773; fax: +90 312 3117377.

E-mail address: rdogan@hacettepe.edu.tr (R. Dogan).

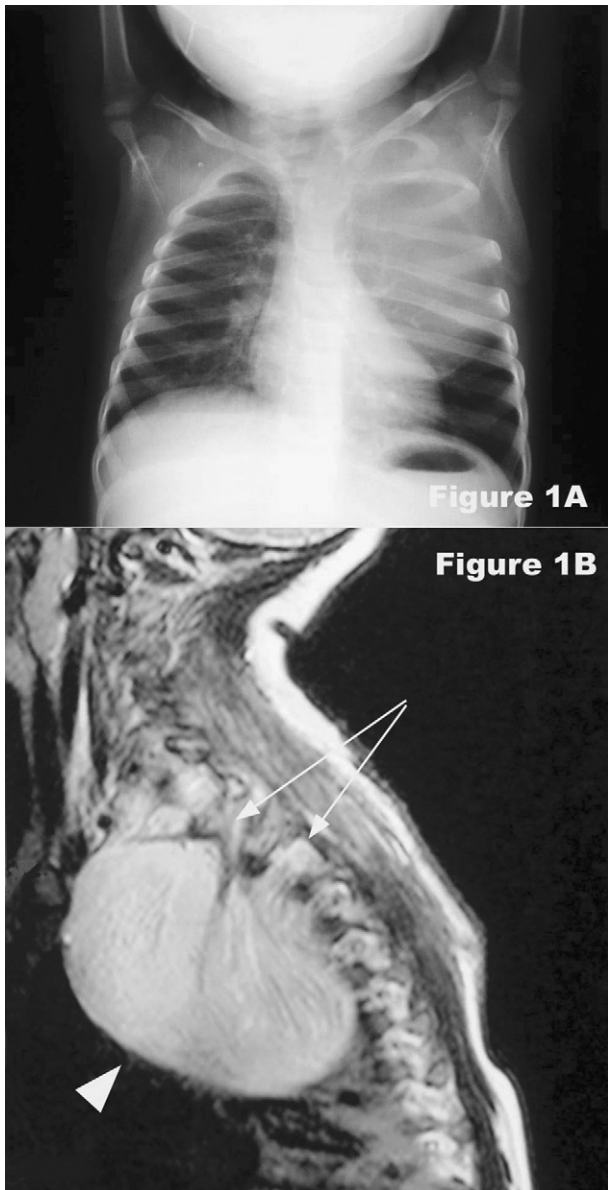


Fig. 1. (A) Chest X-ray showing the mass within the left hemithorax. (B) T-2 weighted magnetic resonance image in sagittal sections showing the mediastinal tumor (arrowhead) with its intervertebral involvements (arrows).

Neoplastic nodules having a myxoid appearance in some areas were composed of partly differentiated lipoblasts and showed prominent vascular pattern (Fig. 2). Postoperative course was uneventful and the patient started creeping as well as walking at postoperative 2 months.

3. Discussion

The most common predilection sites of lipoblastomatous tumors are lower extremities in 32%, upper extremities in 18%, thorax in 18% and the head and neck region in 15% of the cases and other locations such as retroperitoneum, abdomen, parotid gland and tonsillar fossa [1,5]. A very recent review clarified that a total of 37 patients with cervical lipoblas-

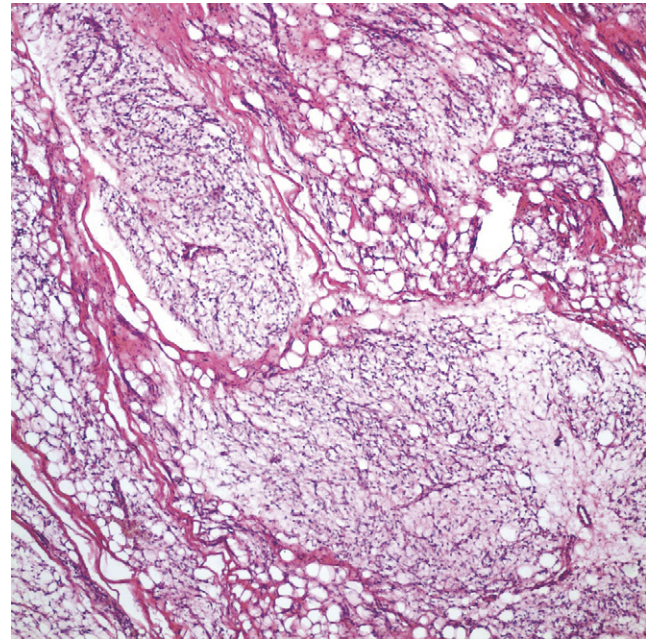


Fig. 2. Histologic view showing lobules of immature adipose tissue separated by thick fibrous septae (H&E \times 100).

tomatous tumors located at the neck have been reported in the English literature [1]. Among these tumors, lipoblastomas constituted 85%, whereas the remaining 15% tumors were lipoblastomatosis [1].

Although lipoblastomatous tumors are benign, they may grow very fast, attain large sizes, and become a painless mass, making it the most common symptom. Tumors located at the neck may also present with stridorous respiration in 31% of the cases, ipsilateral ptosis and miosis or parotid gland involvement [1]. Neurologic symptoms resulting from spinal cord compression are very rare. A total of three cases with lipoblastomas located at the neck showing symptoms of spinal cord compression have been reported previously [3–5]. Among these cases, one presented with hemiparesis [3], one with bilateral lower extremity paresis [5] and another with normal muscle strength [4]. On the contrary, histologic diagnosis was lipoblastomatosis in our case and the presenting symptom was paraparesis, which improved following the excision of the tumor.

On gross histologic examination, lipoblastomas are often well circumscribed, whereas lipoblastomatosis are less well circumscribed with a diffuse and infiltrative growth pattern. The cut surface of these tumors shows a lobulated fatty appearance. Histologic features include myxoid changes with lipomatous cells at different stages of maturity not only within the same lobule but also at varying degrees between lobules. A connective tissue of varying thickness separates the lobules. Moreover, foci of cartilaginous metaplasia may also be observed. Lipoblastomatous tumors may mature to ordinary lipomas with time [6].

Although CT scan may show a tumor of fatty origin, preoperative differential diagnosis between other fatty tumors such as lipoma, liposarcoma and myxoliposarcoma is quite difficult [7]. However, lipoblastomatous tumors differ from lipoma or lipomatosis by their cellular immaturity

histologically, and they have close resemblance to low-grade liposarcomas. On the contrary, liposarcomas are tumors that occur in adults, and are extremely rare in infants. Histologic differential diagnosis between lipoblastomatous tumors and liposarcomas is based on the prominent lobular architecture of lipoblastomatous tumors in addition to the lack of nuclear atypia unlike the myxoid liposarcomas. In addition, myxoid liposarcomas show a characteristic t (12; 16) translocation, which is not present in lipoblastomatous tumors, and recent studies have defined rearrangements of chromosome 8q11-q13 observed as deletions in lipoblastomatous tumors to distinguish from myxoid liposarcomas [8,9].

Malignant transformation has not been reported in lipoblastomatous tumors. However, they show a tendency for local invasion but not for metastasis. Lipoblastomas most often do not recur, whereas lipoblastomatosis are very likely to recur within 2 years following excision [10]. Thus, complete excision is very essential in the surgical treatment to avoid recurrences that occur in almost 15% of the cases. Although these tumors have a potential for local invasion and rapid growth, they show a favorable prognosis. Our patient is free from recurrence at 6-month follow-up.

In conclusion, lipoblastomatosis is a very rare tumor of infancy, resembling fetal fatty tissues. Neck and mediastinum are quite rare sites for these tumors, and tumors at

these locations may present with paraparesis resulting in gait disturbance.

References

- [1] Lorenzen JC, Godballe C, Kerndrup GB. Lipoblastoma of the neck: a rare cause of respiratory problems in children. *Auris Nasus Larynx* 2005;32:169–73.
- [2] Farrugia MK, Fearn C. Benign lipoblastoma arising in the neck. *Pediatr Surg Int* 1998;13:213–4.
- [3] Sun JJ, Rasgon BM, Hilsinger RL. Lipoblastomatosis of the neck causing hemiparesis: a case report and review of the literature. *Head Neck* 2003;25:337–40.
- [4] Duhaime AC, Chatten J, Schut L, Rorke L. Cervical lipoblastomatosis with intraspinal extension and transformation to mature fat in a child. *Childs Nerv Syst* 1987;3:304–6.
- [5] Ko SF, Shieh CS, Shih TY, Hsiao CC, Nq SH, Lee TY, Wan YL, Chen WJ. Mediastinal lipoblastoma with intraspinal extension: MRI demonstration. *Magn Reson Imaging* 1998;16:445–8.
- [6] Van Meurs DP. The transformation of an embryonic lipoma to a common lipoma. *Br J Surg* 1947;34:282–4.
- [7] Stringel G, Shandling B, Mancer K, Ein SH. Lipoblastoma in infants and children. *J Pediatr Surg* 1982;17:277–80.
- [8] Harrer J, Hammon G, Wagner T, Bolkenius M. Lipoblastoma and lipoblastomatosis: a report of two cases and review of the literature. *Eur J Pediatr Surg* 2001;11:342–9.
- [9] Weiss SW, Goldblum JR. *Enzinger and Weiss's soft tissue tumors*, 4th edn., Mosby: St. Louis; 2001. pp. 601–5.
- [10] Dille AV, Patel DL, Hicks MJ, Brandt ML. Lipoblastoma: pathophysiology and surgical management. *J Pediatr Surg* 2001;36:229–31.