



Case Report

Long and wrong way: Unintended pericardial catheter insertion through stomach

Safak Alpat (MD, PhD)^{a,*}, Tuba Sahinoglu (MD)^b, Serkan Uysal (MD)^b, Riza Dogan (MD)^{a,b}

^a Department of Cardiovascular Surgery, Hacettepe University School of Medicine, Ankara, Turkey

^b Department of Thoracic Surgery, Hacettepe University School of Medicine, Ankara, Turkey

ARTICLE INFO

Article history:

Received 18 November 2013

Received in revised form 20 April 2014

Accepted 7 May 2014

Keywords:

Pericardial effusion

Pericardial catheter

Pneumopericardium

Percutaneous

ABSTRACT

Complications of percutaneous pericardial catheter insertion for pericardial effusion are rare. We describe a rare complication of percutaneous pericardial catheter insertion that penetrated the stomach and diaphragm before getting into the pericardial sac in a patient with lymphoma. The misplaced catheter was extracted surgically and subxiphoid pericardial tube insertion with pleural pericardial window was performed.

<Learning objective: Although similar outcomes have been reported with both percutaneous and subxiphoid techniques, major complications may arise with the percutaneous technique. This case emphasizes that percutaneous pericardial catheter insertion may have serious complications and these procedures should be performed by experienced clinicians with the standby of a cardiac team.>

© 2014 Japanese College of Cardiology. Published by Elsevier Ltd. All rights reserved.

Introduction

Many techniques have been defined for the management of pericardial effusion. Of those modalities, the most commonly utilized ones are percutaneous pericardial catheter insertion and open subxiphoid drainage. The current management of pericardial diseases is largely empirical because of the relative lack of randomized trials. The choice between various methods should be based on the individual experience at a particular institution [1]. Deciding on adequate treatment strategy is especially difficult in patients with diagnosed malignancy, since survival is limited to compare outcomes.

Despite current literature reporting a low rate of procedural complications with the percutaneous technique, serious and major complications may be seen [2]. Herein we describe a rare complication of percutaneous pericardial catheter insertion that caused stomach and diaphragm perforation in a 51-year-old male with NK/T-cell lymphoma.

* Corresponding author at: Department of Cardiovascular Surgery, Hacettepe University School of Medicine, 06100 Sıhhiye, Ankara, Turkey.
Tel.: +90 537 241 97 10; fax: +90 312 311 7773.

E-mail addresses: salpat@hacettepe.edu.tr, safakalpat@gmail.com (S. Alpat).

Case report

A 51-year-old male with gastric involvement of NK/T-cell lymphoma was admitted to the hospital for evaluation of lower gastrointestinal bleeding. He stated that bleeding had started after the previous chemotherapy protocol. He had melena with no accompanying hematemesis. He had a history of multiple upper and lower endoscopies, multiple gastrointestinal surgeries, and different chemotherapy protocols. Colonoscopy was performed for evaluating gastrointestinal bleeding. No active bleeding was found. After colonoscopy his clinical status rapidly deteriorated. Physical examination revealed fever and tachycardia. Blood pressure was 80/50 mmHg. He was pale. His expiration time was increased and there were basal crackles. There was no murmur but heart sounds were diminished. He was orthopneic. No other abnormal finding was seen. Biochemical analysis was as follows: leukocyte count, 12,400 cells/mm³; polymorphs, 86%, C-reactive protein, 12 mg/dL; erythrocyte sedimentation rate, 14 mm/h. Arterial blood gas report showed pH 7.44, pO₂ 55 mmHg, SO₂ 89%, and pCO₂ 28 mmHg. Pneumomediastinum was detected in his chest X-ray (Fig. 1). Bedside transthoracic echocardiography was performed and pneumopericardium was confirmed. Moreover, 24 mm pericardial effusion around lateral wall and 28 mm effusion around apex was detected incidentally. Further examination revealed diastolic collapse of right ventricle and increased respiratory variations in mitral and tricuspid flows. Because of the

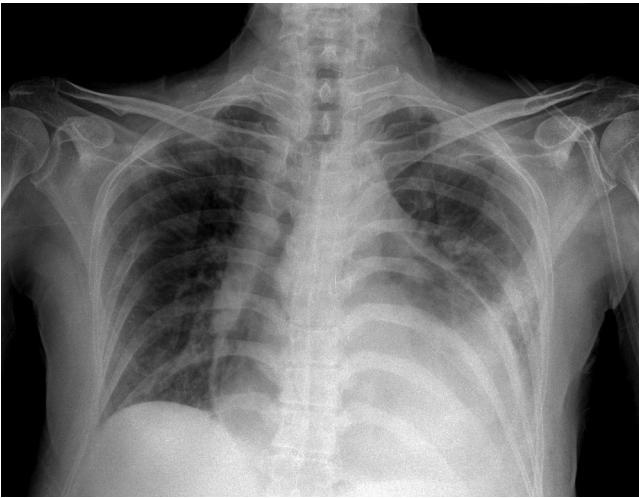


Fig. 1. Chest X-ray of the patient showing pneumomediastinum.

underlying malignancy and possible malignant nature of the pericardial fluid, percutaneous pericardial catheter was inserted with guidance of echocardiography to prevent recurrence. The bedside procedure was accomplished with a portable echocardiography machine under semi-urgent settings (no picture was taken due to lack of printer). As the cardiologist stated, there was no abnormal finding during the procedure. A total of 300 cm³ serous fluid was drained. After this procedure, computed tomography (CT) of the thorax was obtained to exclude pulmonary thromboembolism and for further evaluation of pneumopericardium. CT revealed that there was no pulmonary thromboembolism, but the tip of the percutaneous pericardial catheter had penetrated through the

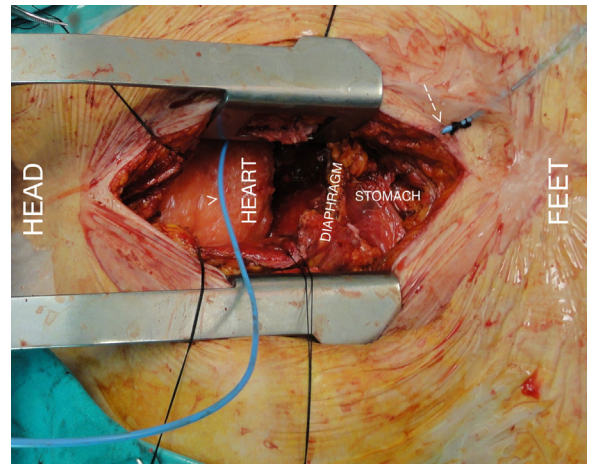


Fig. 3. Intraoperative image of the course of pericardial catheter between the arrow and arrowhead. The catheter penetrated through the stomach and diaphragm before reaching the pericardial space (arrow: insertion site of pericardial catheter; arrow-head: pericardial catheter in the pericardial space).

stomach and diaphragm before getting through into the pericardial sac (Fig. 2A–D). Surgery was planned to remove the catheter and to insert a tube for pericardial fluid drainage. After subxiphoid incision, the catheter was found in the pericardial space after having gone a long distance through the stomach (Fig. 3). The pericardial catheter was extracted and pericardial fluid was drained, pleuropericardial window was created because of effusion's malignant nature and a pericardial tube was inserted. At the same time, total gastrectomy with jejunostomy was performed since the stomach was filled-up with tumor involvement and perforated by the tip of the catheter. Postoperative echocardiography showed that there

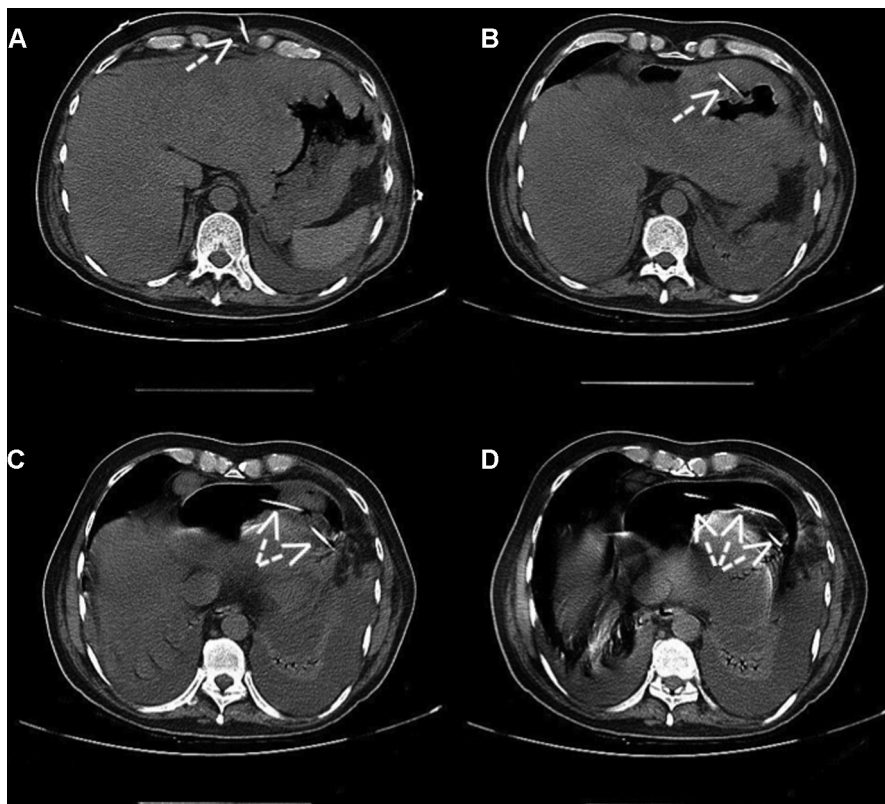


Fig. 2. Computed tomography scan showing course of pericardial catheter (arrow) from skin (A) to pericardial space (D) traversing the stomach and the diaphragm (B and C).

was no effusion and pneumopericardium, but the patient could not be extubated in the intensive care unit and died because of sepsis on the 20th postoperative day.

Discussion

The optimal management of pericardial effusions for symptomatic patients remains controversial. Ideal effusion management should succeed complete and permanent drainage and provide enough histologic, cytologic, and microbiologic material for diagnostic studies. Many treatment options have been previously described for management including systemic chemotherapy, local radiotherapy, pericardiocentesis, pericardial catheter placement with or without sclerosis, percutaneous balloon pericardiostomy, operative subxiphoid drainage with or without pericardioperitoneal window, pleuropericardial window (by thoracotomy or thoracoscopy), and pericardiectomy [3]. Nevertheless, there is a debate on the efficacy and success rates of these various methods.

The procedure should result in minimal morbidity and mortality and would be performed with minimal discomfort to the patient. Open subxiphoid drainage and percutaneous pericardial catheter insertion are the two most commonly used modalities. With open drainage it is easy to resect a portion of the anterior central diaphragm and create a chronically open channel between the pericardium and peritoneum. Moreover, the open approach allows surgeons to break up loculations, place a much larger drainage tube, and stimulate adhesions [4,5]. Percutaneous drainage could be done without the negative respiratory and hemodynamic effects of general anesthesia. It is especially difficult to compare the effect of two methods on overall survival, complications, and recurrence in patients with malignant pericardial effusions since their median survival is limited. However, current evidence suggests that both procedures have limited direct procedural mortality or complications [3,6,7].

The most serious complications of percutaneous pericardiocentesis are laceration and perforation of the myocardium. Complications can be reduced with echocardiographic or fluoroscopic guidance [6]. One series reported that the incidence of major complications is 1.3–1.6% with echocardiographic guidance and 1% with fluoroscopic guidance [2]. Furthermore, in a recent paper it has been reported that the percutaneous technique had a lower rate of postprocedural complications than subxiphoid drainage [8]. But it should be emphasized that these figures are probably valid only for the most experienced cardiologists.

It is possible that even experienced clinicians may encounter some catastrophic complications. In a recent report of transhepatic

pericardial catheter insertion through the hepatic veins, the inferior vena cava ending up in the right atrium was described [9]. In our case, another form of misplacement that ends up with concomitant complications was defined. We think that anatomical difficulties with this case led to complications. Since his stomach was full with tumoral masses and shifted toward the midline, it acted like a solid barrier while trying to reach the pericardium. We noticed no technical mistakes during the procedure. Moreover, since an experienced interventional cardiology team performed the procedure, we exclude human factors. Although the rate of complications with the percutaneous technique has been reported as infrequent, with this case it is pointed out that percutaneous pericardiocentesis is not an innocuous procedure and can cause major complications. Moreover, anatomical factors related to patients' morbidities have to be taken into account during the procedure.

Funding sources

No external funding for this study has been used.

Conflict of interest

The authors declare no conflict of interest.

References

- [1] Imazio M, Spodick DH, Brucato A, Trincherio R, Adler Y. Controversial issues in the management of pericardial diseases. *Circulation* 2010;121:916–28.
- [2] Becit N, Unlu Y, Ceviz M, Kocogullari CU, Kocak H, Gurlertop Y. Subxiphoid pericardiostomy in the management of pericardial effusions: case series analysis of 368 patients. *Heart* 2005;91:785–90.
- [3] McDonald JM, Meyers BF, Guthrie TJ, Battafarano RJ, Cooper JD, Patterson GA. Comparison of open subxiphoid pericardial drainage with percutaneous catheter drainage for symptomatic pericardial effusion. *Ann Thorac Surg* 2003;76:811–5.
- [4] Palatianos GM, Thurer RJ, Pompeo MQ, Kaiser GA. Clinical experience with subxiphoid drainage of pericardial effusions. *Ann Thorac Surg* 1989;48:381–5.
- [5] Lema LE, McHaro ON. Subxiphoid pericardiostomy in the management of pericardial effusions. *East Afr Med J* 1991;68:270–5.
- [6] Allen KB, Faber LP, Warren WH, Shaar CJ. Pericardial effusion: subxiphoid pericardiostomy versus percutaneous catheter drainage. *Ann Thorac Surg* 1999;67:437–40.
- [7] Becit N, Ozyazicioglu A, Ceviz M, Karakelleoglu S, Karapolat S, Kocak H. Clinical experience with subxiphoid pericardiostomy in the management of pericardial effusions: a study of 240 cases. *J Int Med Res* 2003;31:312–7.
- [8] Saltzman AJ, Paz YE, Rene AG, Green P, Hassanin A, Argenziano MG, Rabbani L, Dangas G. Comparison of surgical pericardial drainage with percutaneous catheter drainage for pericardial effusion. *J Invasive Cardiol* 2012;24:590–3.
- [9] Emmert MY, Frauenfelder T, Falk V, Wilhelm MJ. Emergency pericardiocentesis: a word of caution! Accidental transhepatic intracardiac placement of a pericardial catheter. *Eur J Cardiothorac Surg* 2012;42:e31–2.