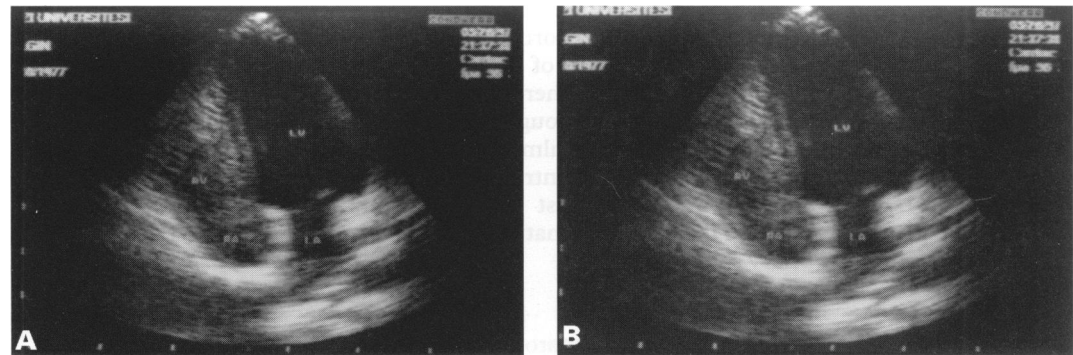


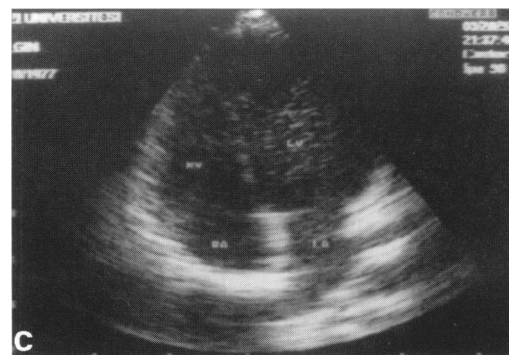
## Liver disease presenting with cyanosis

Gülsan Türköz Sucak, Mustafa Cemri, Tamer Atasever, Bedri Uzunalimoğlu, Şükrü Dumlu, Halis Dörtlemez

A 19-year-old woman was admitted to hospital for the evaluation of central cyanosis. She was complaining of fatigue, progressive dyspnoea, worsening in the upright position, and marked cyanosis of the lips and nail beds. She described a mild bleeding diathesis with epistaxis and prolonged menstrual bleeding during the last 6 months. She had no history of hepatitis, transfusion, alcohol abuse or drug ingestion. Physical examination revealed marked cyanosis of the lips and nail beds and digital clubbing with a few telangiectic vascular lesions on her face and shoulders. A grade 2/6 systolic ejection murmur in the pulmonary area and a systolic thrill and murmur all over the lung area was also present. Spleen was palpable 6 cm below the costal margin. The laboratory investigation showed leucopenia and thrombocytopenia, but normal liver chemistry except a prolonged prothrombin time: haemoglobin 15.7 g/dl, leucocytes  $2.6 \times 10^9/l$ , platelets  $210 \times 10^9/l$ , alanine transaminase 29 IU/l, aspartate transaminase 35 IU/l, lactate dehydrogenase 215 IU/l,  $\gamma$ -glutamyl transpeptidase 25 IU/l, alkaline phosphatase 100 IU/l, conjugated bilirubin 5.8  $\mu\text{mol/l}$ , unconjugated bilirubin 17.1  $\mu\text{mol/l}$ , prothrombin time 20 s, partial thromboplastin time 48 s. Arterial blood gas analysis revealed orthodeoxia with  $\text{pO}_2$  55.6 mmHg,  $\text{pCO}_2$  26.4 mmHg,  $\text{O}_2$  saturation 90.3% in the supine position, and  $\text{pO}_2$  45 mmHg,  $\text{pCO}_2$  24.3 mmHg,  $\text{O}_2$  saturation 85.8% in the upright position. Chest X-ray, thoracic computed tomography, spirometry, closing volume and flow volume curve were all normal. Two-dimensional contrast echocardiography was performed (figure 1). The pulmonary angiogram was completely normal. The results of a pulmonary scintigram with  $^{99\text{m}}\text{Tc}$ -macroaggregated albumin (MAA) are shown in figure 2. Antibodies to hepatitis A, B, and C viruses and HBV-DNA and HCV-RNA were negative. Serum  $\alpha$ 1-antitrypsin level was normal. Abdominal ultrasound revealed a small, irregular, and markedly heterogenous liver with splenomegaly. There were second degree oesophageal varices on endoscopic examination. Liver biopsy revealed hepatoportal sclerosis.



**Figure 1** (A, B, and C) Contrast echocardiography. RA: right atrium, RV: right ventricle, LA left atrium, LV: left ventricle



**Figure 2** Pulmonary perfusion scintigram by  $^{99\text{m}}\text{Tc}$ -macroaggregated albumin

Gazi University School of Medicine, Ankara, Turkey  
Department of Medicine  
G T Sucak  
M Cemri  
Ş Dumlu  
H Dörtlemez  
Department of Nuclear Medicine  
T Atasever

Hacettepe University School of Medicine, Ankara, Turkey  
Department of Pathology  
B Uzunalimoğlu

Correspondence to Gülsan Türköz Sucak, Kader Sok 4/5 06700 Gaziosmanpaşa, Ankara, Turkey

Accepted 25 November 1997

### Questions

- 1 What does the contrast echocardiogram show ?
- 2 What does the pulmonary scintigram show ?
- 3 What is the diagnosis?

## Answers

### QUESTION 1

During a normal contrast echocardiography, microbubbles created with agitated saline are injected into a peripheral intravenous line; after opacification of right atrium and ventricle, microbubbles are expected to be cleared via one passage through the pulmonary circulation without any opacification in the left side of the heart. Two-dimensional contrast echocardiography in our patient (figure 1A) shows normal cardiac chambers, opacification of the right atrium and ventricle by the microbubbles (figure 1B), and delayed opacification of the left atrium and ventricle by the microbubbles (figure 1C), three beats (2 s) after the opacification of the right side of the heart, suggesting an intrapulmonary arteriovenous shunt. A pulmonary angiogram and lung perfusion scintigram were performed to identify the nature of the intrapulmonary shunts.

### QUESTION 2

Figure 2 shows the whole body images of the pulmonary perfusion scintigram by  $^{99m}\text{Tc}$ -macroaggregated albumin. The whole body imaging revealed a significant uptake in the lung and kidneys and a lesser amount in liver and spleen, which confirmed the presence of intrapulmonary shunts. The shunt ratio was estimated to be 50% by a quantitative radionuclide method.<sup>1</sup> Macroalbumin aggregates which exceed 20  $\mu\text{m}$  in diameter are expected to be trapped in the normal pulmonary bed. A scan showing uptake of radionuclide over the brain, kidneys, and other organs confirmed the presence of transit through the intrapulmonary shunt(s). A normal pulmonary angiogram and the intact atrial and ventricular septum demonstrated in the contrast echocardiogram confirmed the functional nature of the intrapulmonary shunts.

### QUESTION 3

The diagnosis is hepatopulmonary syndrome (HPS), a term originally coined by Kennedy and Knudson in 1977,<sup>2</sup> to describe a clinical entity characterised by arterial hypoxaemia in patients with chronic liver disease but no cardiopulmonary disease. The pathogenesis of hypoxaemia in HPS is explained by pulmonary vascular abnormalities, consisting of precapillary dilatation, direct arterial-venous communications, and dilated pleural vessels, causing a ventilation perfusion mismatch.<sup>3</sup>

The young age and presenting symptoms (central cyanosis, digital clubbing and dyspnoea) of our patient suggested congenital cyanotic heart disease. The two dimensional contrast echocardiogram, while excluding the possibility of an intracardiac shunt, suggested an intrapulmonary shunt. The pulmonary angiogram was normal, directing us to the functional nature of the shunt(s). The splenomegaly, cytopenias, oesophageal varices, ultrasonographic appearance of the liver and the prolonged prothrombin time, suggested chronic liver disease with hypersplenism, although no serological indications for this diag-

### Liver diseases associated with HPS<sup>3 4</sup>

- cirrhosis (cryptogenic, alcoholic, postnecrotic, primary biliary, juvenile, macronodular)
- chronic active hepatitis
- biliary atresia
- noncirrhotic portal hypertension
- $\alpha$ 1-antitrypsin deficiency
- Wilson's disease
- tyrosinaemia
- fascioliasis
- nodular regenerative hyperplasia
- primary sclerosing cholangitis

### Box 1

nosis were present. Overt splenomegaly, pancytopenia, portal hypertension and relatively mild abnormalities in liver functions are the characteristic features of patients with hepatoportal sclerosis. Orthodeoxia, defined as a decrease in  $\text{PaO}_2$  of 10% or more when moving from a supine to an upright position, and platypnoea (dyspnoea induced by the upright position), the clinical sign of orthodeoxia, were both observed in our patient. Orthodeoxia and platypnoea are observed in about 5% of cirrhotic patients, however they are reported to be more prevalent in patients with HPS.<sup>4</sup> Finally, an open liver biopsy showed an atrophic liver with a macronodular appearance. The histological examination of a specimen disclosed hepatoportal sclerosis. While the majority (80%) of patients with HPS reported in the literature already have an established diagnosis of cirrhosis,<sup>4</sup> our patient was investigated for cyanosis and was diagnosed to have chronic liver disease only during this investigation.

A wide variety of liver diseases, including hepatoportal sclerosis, may cause HPS (box 1), and no correlation with either the histologic subtype or the clinical severity of the disease has been reported.<sup>4</sup>

Attempts at treatment with agents such as garlic, indomethacin, almitrine, octreotide, and with plasma exchange have been rather disappointing.<sup>3</sup> Embolisation has shown only limited success.<sup>3 5</sup> We referred our patient for liver transplantation, as the recent literature regarding the response of HPS to liver transplantation has been encouraging, although some initial reports were also disappointing.<sup>4 6</sup>

In conclusion, hepatoportal sclerosis is among the various liver disease associated with HPS. HPS should be considered in the differential diagnosis of acquired central cyanosis especially if it is associated with digital clubbing, even if there is no sign and/or history of liver disease. In such cases, platypnoea and orthodeoxia are simple and reliable clinical findings for the diagnosis of HPS. Two-dimensional contrast echocardiogram is a valuable diagnostic tool, together with a pulmonary angiogram, and pulmonary perfusion scintigram with  $^{99m}\text{Tc}$  macroaggregated albumin should be also performed.

**Suggested investigations in patients with HPS<sup>4</sup>**

- chest X-ray\*
- two-dimensional contrast echocardiography\*
- pulmonary angiography\*
- <sup>99m</sup>Tc-macroaggregated albumin lung scintigraphy\*
- high-resolution CT\*(?)
- magnetic resonance imaging (?)

\* Investigations performed in our patient

**Box 2**

- 1 Gang L, Wei-Jen S, Chien X. Tc-99m MAA Total body imaging to detect intrapulmonary right to left shunts and to evaluate the therapeutic effect in pulmonary arteriovenous shunts. *Clin Nucl Med* 1996;21:197–202.
- 2 Kennedy TC, Knudson RJ. Exercise aggravated hypoxemia and orthodeoxia in cirrhosis. *Chest* 1977;72:305–9.
- 3 Lange PA, Stoller JK. The hepatopulmonary syndrome. *Ann Intern Med* 1995;122:521–9.
- 4 Krowka MJ. Clinical management of hepatopulmonary syndrome. *Semin Liver Dis* 1993;13:414–22.
- 5 Poterucha JJ, Krowka MJ, Dickson AR, Cortese DA, Stanson AW, Krom RAF. Failure of hepatopulmonary syndrome to resolve after liver transplantation and successful treatment with embolotherapy. *Hepatology* 1995;21:96–100.
- 6 Krowka MJ. Hepatopulmonary syndrome. *Transplant Proc* 1993;25:1746–7.

**Final diagnosis**

Hepatopulmonary syndrome due to hepatopulmonary sclerosis.

**Keywords:** hepatopulmonary syndrome; hepatopulmonary sclerosis; liver disease; cyanosis