

## Investigation of the protective effect of erdosteine against cyclosporine-induced injury in rat liver with histological and biochemical methods

Ahmet NACAR<sup>1\*</sup>, İhsan KARABOĞA<sup>2</sup>, Hamza Malik OKUYAN<sup>3</sup>, Nebihat KAPLAN SEFİL<sup>4</sup>,  
Emel NACAR<sup>5</sup>, Sedat MOTOR<sup>6</sup>, Seçkin AKKÜÇÜK<sup>7</sup>, Orhan Veli ÖZKAN<sup>8</sup>

<sup>1</sup>Department of Histology and Embryology, Faculty of Medicine, Hacettepe University, Ankara, Turkey

<sup>2</sup>School of Health Sciences, Namık Kemal University, Tekirdağ, Turkey

<sup>3</sup>Vocational School of Health Sciences, Mustafa Kemal University, Hatay, Turkey

<sup>4</sup>Antakya State Hospital, Hatay, Turkey

<sup>5</sup>Vocational School of Health Sciences, Turgut Özal University, Ankara, Turkey

<sup>6</sup>Department of Biochemistry, Faculty of Medicine, Mustafa Kemal University, Hatay, Turkey

<sup>7</sup>Department of General Surgery, Faculty of Medicine, Mustafa Kemal University, Hatay, Turkey

<sup>8</sup>Department of General Surgery, Faculty of Medicine, Sakarya University, Sakarya, Turkey

Received: 01.04.2014

Accepted/Published Online: 20.06.2014

Printed: 31.12.2015

**Background/aim:** In the present study, the protective effect of erdosteine against cyclosporine-induced injury in rat liver was investigated with histological and biochemical methods.

**Materials and methods:** Thirty-two Wistar albino male rats were randomly divided into 4 groups: control (n = 8), cyclosporine (n = 8, 20 mg kg<sup>-1</sup> day<sup>-1</sup> i.p.), cyclosporine + erdosteine (n = 8, erdosteine 12 mg kg<sup>-1</sup> day<sup>-1</sup> orally), and erdosteine (n = 8). At the end of day 12, liver tissues were removed for histological and biochemical analysis. After liver tissues were fixed in 10% buffered neutral formalin, routine histological processes were applied and tissue sections were stained with hematoxylin and eosin, periodic acid-Schiff, and elastic fiber stain methods. One hundred lobules of liver were examined for each group and evaluated statistically. The levels of malondialdehyde and glutathione peroxidase, as well as the activities of superoxide dismutase, were determined.

**Results:** The cyclosporine group showed significant histopathological changes compared to the control. In the cyclosporine + erdosteine group, histopathological changes of hepatic damage were markedly reduced. Histological findings were supported by biochemical results.

**Conclusion:** Erdosteine could attenuate cyclosporine-induced liver injury.

**Key words:** Cyclosporine, erdosteine, antioxidant system, hepatotoxicity

### 1. Introduction

Cyclosporine A (CsA), an immunosuppressive agent, has been used in organ transplantation cases and the treatment of autoimmune diseases for a long time (1,2). It is a cyclic polypeptide with 11 amino acids, which is produced by fermentation of *Trichoderma polysporum* and *Cylindrocarpon* (3). Cyclosporine G, formed by replacement of alpha-aminobutyric acid by norvaline, has an identical effect to that observed with CsA (4,5).

From the 1980s onwards, side effects began to occur with the wide prescription of CsA. These include nephrotoxicity, cardiotoxicity, hypertension, infections, and hepatotoxicity (6–8).

The mechanism of tissue damage caused by CsA has not been fully understood. Several authors have suggested

that reactive oxygen species production, oxidative stress, and depletion of the hepatic antioxidant system are possible mechanisms of CsA hepatotoxicity (9,10).

Although the mechanism of CsA side effects is not fully understood, several studies showed that the use of antioxidant agents can reduce the toxicity (10,11).

Erdosteine [N-(carboxymethylthioacetyl)-homocysteine thiolactone] is a mucolytic agent that was developed for the treatment of chronic pulmonary disease. Erdosteine includes two blocked sulfhydryl groups that are unlocked with hepatic metabolism. The reducing potential of these sulfhydryl groups provides antioxidant activity and free radical scavenging of erdosteine (12,13).

Erdosteine is known to have antioxidant properties and has been used in many studies on account of its

\* Correspondence: drnacar@gmail.com

scavenging activity. Those studies demonstrated the free radical scavenging abilities of erdosteine with biochemical and histological methods (14,15).

Organ transplants are vital for many patients, and the number of patients undergoing organ transplants is increasing. CsA is the most effective drug used in the treatment of organ transplant rejections and autoimmune disease. However, its administration is limited because of its serious side effects. Therefore, it was aimed to investigate the protective effect of erdosteine against CsA-induced hepatotoxicity in rats with histological and biochemical methods in the present study.

## 2. Materials and methods

Our study was approved by the animal ethics committee of Mustafa Kemal University, and experiments were performed in accordance with the principles of the Animal Welfare Act and the Guide for the Care and Use of Laboratories. Thirty-two male Wistar albino rats (aged 8–12 weeks) weighing  $250 \pm 20$  g (mean  $\pm$  standard deviation) were obtained for this study from the Laboratory Animal Production Unit of Çukurova University. The rats were kept in a room under controlled temperature ( $20 \pm 2$  °C) and humidity ( $50 \pm 5\%$ ) with a 12-h light/dark cycle for 1 week before the onset of the experiment. Standard diet and tap water were provided ad libitum.

Rats were randomly divided into 4 equal experimental groups as follows. In the control group, group 1 ( $n = 8$ ), 1 mL of 0.9% NaCl was injected intraperitoneally into the animals. In the CsA group, group 2 ( $n = 8$ ), 20 mg kg<sup>-1</sup> day<sup>-1</sup> of CsA (Sandimmune 50 mg/mL vial, Novartis) was diluted in physiological saline and 2 mL of this solution was administered intraperitoneally. In the CsA + erdosteine group, group 3 ( $n = 8$ ), 20 mg kg<sup>-1</sup> day<sup>-1</sup> of CsA + erdosteine (Sandoz, Erdostin 300 mg/capsule), erdosteine was administered by oral gavage in 10 mg/kg doses for 12 days. Erdosteine was dissolved in distilled water with NaHCO<sub>3</sub> and was given orally once a day. In the erdosteine group, group 4 ( $n = 8$ ), only erdosteine was administered in doses of 10 mg/kg for 12 days by oral gavage.

At the end of day 12, the rats were anesthetized with ketamine hydrochloride (50 mg/kg i.m., Ketalar, Turkey) and sacrificed. The left lobe of the liver was dissected and stored at  $-70$  °C until biochemical analysis. The right lobe of the liver was used for histopathological analysis.

For light microscopic evaluation, liver tissue samples were fixed in 10% neutral buffered formalin. After fixation and routine histological procedure, samples were embedded in paraffin and sectioned at 5  $\mu$ m with a microtome. Afterward, the sections were stained with hematoxylin and eosin (H&E, Sigma-Aldrich MHS 128-HT110180, USA), periodic acid–Schiff (PAS, Sigma-Aldrich 395B, USA), and elastic fiber stain (Sigma-

Aldrich 395B, USA) and were then examined with a BX51 microscope (Olympus, Japan) and photographed.

In total, 100 lobules of liver for each group were examined by two blinded histologists using H&E-stained sections. Histopathological findings such as sinusoidal dilatation, inflammatory cell infiltration, hepatocellular vacuolization, and hemorrhage were identified in 100 lobules of each group and then scored. The histological changes were graded as follows: normal = 0, mild = 1, moderate = 2, severe = 3 (16).

Liver tissues were homogenized for 2 min at 5000 rpm in 4 volumes of ice-cold Tris-HCl buffer (50 mM, pH 7.4) with a homogenizer to measure malondialdehyde (MDA) and protein levels. To obtain the supernatant, the homogenates were centrifuged at  $5000 \times g$  for 60 min. Supernatant fluids were then collected and kept at  $-40$  °C for glutathione peroxidase (GSH-Px) activity determination. The supernatant solutions were treated with an equal volume of a mixture including ethanol and chloroform (5:3 volumes per volume [53]). The mixture was then centrifuged at  $5000 \times g$  for 30 min. The clear upper layer (the ethanol phase) was collected for the measurement of superoxide dismutase (SOD) activity and protein assays.

SOD activity was measured based on a method adapted from Sun et al. (17). With this method, nitroblue tetrazolium reduction is inhibited by the xanthine-xanthine oxidase system. The MDA level was assessed by a method in which MDA reacts with thiobarbituric acid at 90–100 °C (18). GSH-Px (EC 1.6.4.2) activity was determined using a method described by Paglia and Valentine (19). The method of Lowry et al. was utilized for protein assays (20).

In addition to histological methods, hepatic injury was evaluated biochemically using serum aspartate transaminase (AST) and alanine transaminase (ALT) levels. Serum levels of AST and ALT were determined with commercial Beckman Coulter diagnostic kits and automated enzyme analyzers (Synchron LX 20, Ireland).

SPSS 11.5 for Windows was used for the statistical assessment of the obtained data. Results are presented as means  $\pm$  standard error of the mean (SEM);  $P < 0.05$  was regarded as statistically significant.

## 3. Results

MDA levels were significantly higher in the CsA group in comparison to the control ( $P < 0.05$ ). MDA was significantly lower in the CsA + erdosteine group than in the CsA group ( $P < 0.05$ ). SOD and GSH-Px activities were significantly decreased in the CsA group compared to the control group ( $P < 0.001$ ). Additionally, SOD and GPx activities were significantly higher in the CsA + erdosteine group compared to the CsA group ( $P < 0.05$ ). There was a

statistically significant increase in AST and ALT levels in the CsA group when compared to the control group ( $P < 0.05$ ). AST and ALT levels decreased significantly in the CsA + erdosteine group compared to the CsA group ( $P < 0.05$ ) (Figures 1A–1E).

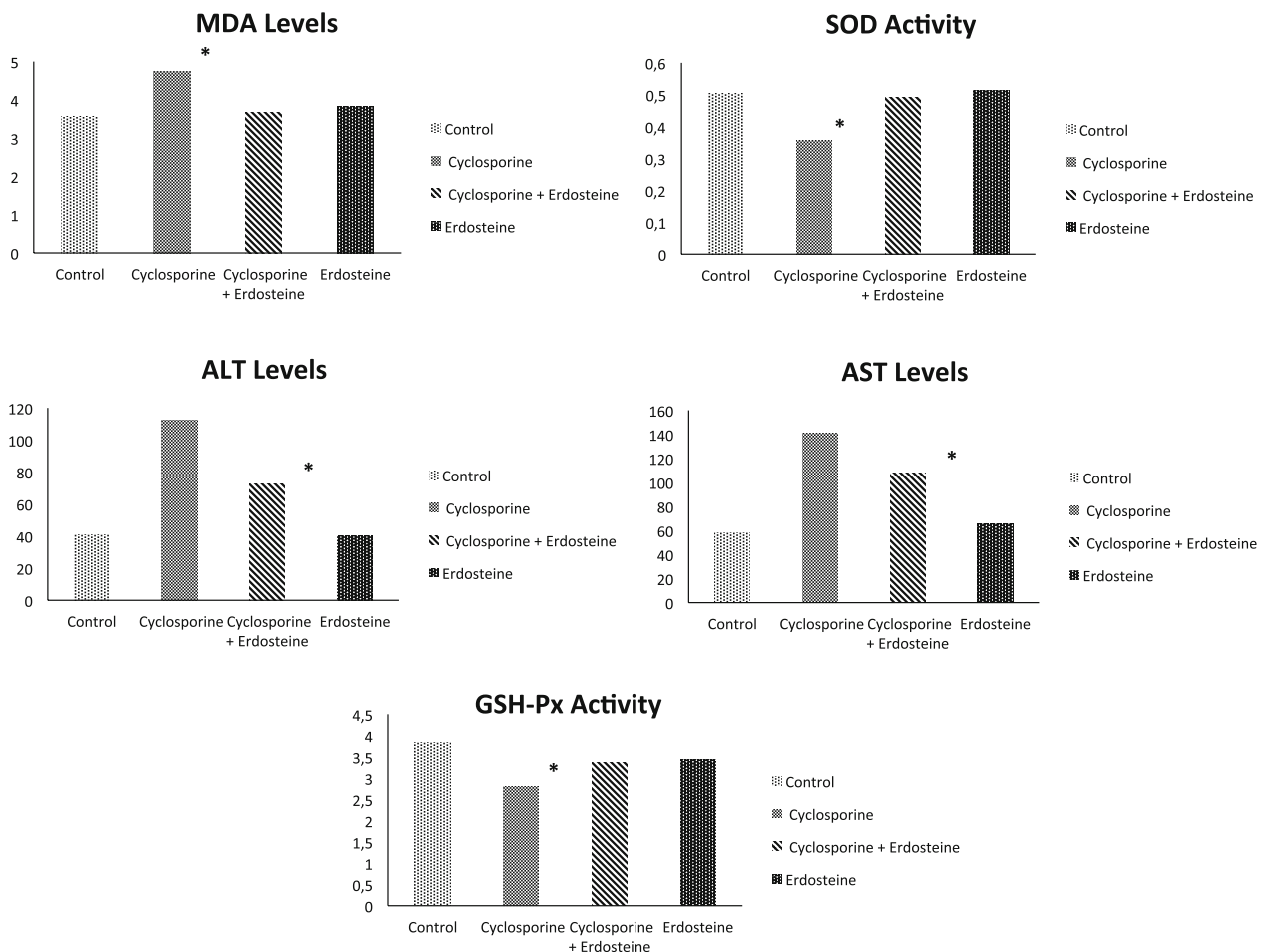
Light microscopic evaluation of the control group revealed a regular morphology of liver parenchyma with intact hepatocytes and sinusoids. In the CsA group, major histopathological changes were the dilatation of the sinusoids, vacuolization of hepatocytes, hemorrhage, and inflammatory cell infiltration of the parenchyma. These histopathological changes were confirmed by PAS and elastic fiber stains. In the CsA + erdosteine group, minimal inflammatory cell invasion and congestion was seen. In the erdosteine group, no pathological changes in liver histology were observed (Figures 2A–2D).

In the CsA group, histopathological scores were significantly higher compared to the control. In the CsA + erdosteine group, a significantly decreased morphological score was obtained compared to the CsA group. All scores are given in the Table.

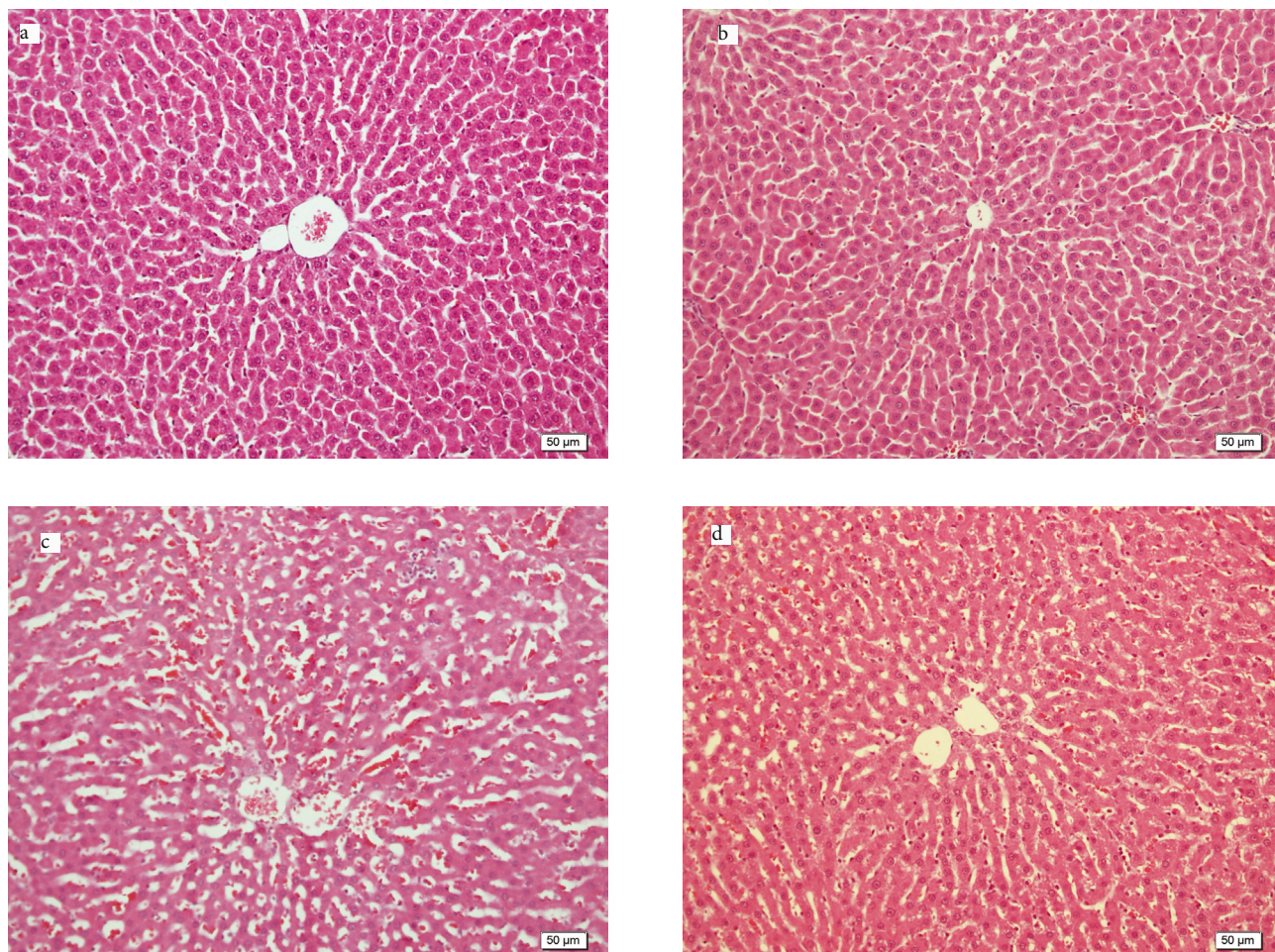
#### 4. Discussion

Since the 1980s, CsA has been used widely in many immunological diseases and in the prevention of rejection reactions in organ transplantation (8). This agent is a fungal cyclic peptide and a strong immunosuppressive (21).

The use of CsA has increased the quality and duration of life in transplantation patients. Its use is limited by significant side effects such as nephrotoxicity, hepatotoxicity, cardiotoxicity, and hypertension (22–25).



**Figure 1. A–B:** SOD and GSH-Px activities were significantly decreased in group 2 compared to the control group ( $P < 0.001$ ). Additionally, SOD and GPx activities were significantly higher in group 3 than in group 2 ( $P < 0.05$ ). **C:** MDA levels were significantly higher in group 2 in comparison to the control group ( $P < 0.05$ ). MDA was significantly lower in group 3 than in group 2 ( $P < 0.05$ ). **D–E:** ALT and AST levels were significantly increased in group 2 as compared to the control group ( $P < 0.05$ ), whereas ALT and AST levels were significantly lower in group 3 than in group 2 ( $P < 0.05$ ). Group 1: Control, 2: cyclosporine, 3: cyclosporine + erdosteine, 4: erdosteine.



**Figure 2.** **A:** Control group showed normal hepatic lobule structure; **B:** erdosteine group showed normal hepatic lobule structure; **C:** congestion (arrow head), sinusoidal dilatation (\*), and inflammatory cell infiltration (arrow) in CsA group; **D:** improved lobule histology in CsA + erdosteine group.

**Table.** Scores of histological changes in all groups.

Groups	Sinusoidal dilatation	Vacuolization of hepatocytes	Hemorrhage	Inflammatory cell infiltration
Control	0	0	0	0
CsA	2.79 ± 0.43	1.24 ± 0.66	2.58 ± 0.47	2.41 ± 0.53
CsA + erdosteine	1.40 ± 0.68	0.88 ± 0.52	1.33 ± 0.62	1.23 ± 0.55
Erdosteine	0	0	0	0
Compared groups	P-values			
Group 1–Group 2	0.000*	0.000*	0.000*	0.000*
Group 1–Group 3	0.000*	0.000*	0.000*	0.000*
Group 1–Group 4	1.000	1.000	1.000	1.000
Group 2–Group 3	0.000*	0.000*	0.000*	0.000*
Group 2–Group 4	0.000*	0.000*	0.000*	0.000*
Group 3–Group 4	0.000*	0.000*	0.000*	0.000*

Results are expressed as the mean ± standard error of the mean (SEM); \*: Statistically significant.

Hepatotoxicity is one of its most dangerous side effects (26).

The mechanism underlying hepatic side effects of the drug has not been fully understood yet despite extensive investigations. Findings indicate that reactive oxygen species (ROS) increase the oxidative damage (21).

In vivo and in vitro studies have shown that CsA, having a lipophilic structure, easily attaches to cell membranes by inducing lipid peroxidation in the membrane to cause free radical formation (27,28).

Free radicals increase lipid peroxidation by reacting with intracellular molecules such as phospholipid, glycolipid, and glycerides. Thus, the cell ion gradient and permeability are disrupted. This results in an increase in ROS synthesis, which can cause irreversible cell damage unless prevented by antioxidant mechanisms (29,30).

A study by Hagar et al. showed that hyperbilirubinemia, cholestasis, increased ALP and transaminases, and inhibition of protein synthesis are the key findings of CsA hepatotoxicity in both laboratory animals and humans (31). We also found increased AST and ALT levels in the CsA group.

MDA is an important end product of lipid peroxidation and is also an indicator of free radical-induced tissue damage. Several studies showed that CsA causes an increase in the liver tissue MDA level (14,32). In our study, there was a statistically significant increase in liver MDA levels of the CsA group compared to the control and the CsA + erdosteine groups.

Antioxidant enzymes, such as SOD and GSH-Px, are protective against free radicals. SOD catalyzes dismutation of the superoxide anion ( $O_2^-$ ) into hydrogen peroxide ( $H_2O_2$ ), which is then detoxified to  $H_2O$  by catalase. GSH and GSH-Px convert  $H_2O_2$  and lipid peroxides to nontoxic products when entering the glutathione redox cycle. CsA decreases the activity of one or more antioxidant systems

with a direct toxic effect, leading to increased oxidative stress and lipid peroxidation (27). In our study, liver SOD and GSH-Px levels decreased significantly in the CsA group compared to the control and CsA + erdosteine group. Similarly, Kaya et al. reported decreased SOD and GSH-Px levels in CsA-treated rats (33).

CsA hepatotoxicity has been shown histologically in many experimental studies. CsA treatment causes disorganization of hepatocyte cords, vacuolization, and dilatation in liver parenchyma (16,34,35). Our histopathological findings are in line with previous studies. Additionally, we performed two more stains to detect histological changes, which supported the H&E findings.

Many experimental studies have used erdosteine against hepatotoxic damage and the protective effect of erdosteine was shown by histological and biochemical methods (36). Sahin et al. demonstrated that oral erdosteine treatment had strong antioxidant activity against vancomycin-induced liver hepatotoxicity in rats (35).

Eraslan et al. demonstrated the protective effect of erdosteine against CsA-induced hepatotoxicity in rats (37). They reported decreased MDA, AST, and ALT levels and improved morphology in the erdosteine-administrated group compared to the CsA group; however, no significant changes in GSH-Px and SOD levels were observed. They supported the antioxidant activity of erdosteine with decreased nitric oxide and increased catalase activities. On the other hand, Andrés et al. and Durak et al. reported that CsA administration significantly reduced the antioxidant capacity in the hepatic tissues of the animals (38,39).

These histological and biochemical findings suggest that the damage caused by CsA is preventable and could be reduced by erdosteine treatment through its antioxidant and radical scavenging effects. Further studies should be carried out in order to document the effects of erdosteine during long-term use of CsA.

## References

1. Grub S, Pershon E, Trommer WE, Wolf A. Mechanism of cyclosporine A-induced apoptosis in rat hepatocyte primary cultures. *Toxicol Appl Pharm* 2000; 163: 209–220.
2. Ponticelli C. Cyclosporine: from renal transplantation to autoimmune diseases. *Ann NY Acad Sci* 2005; 1051: 551–558.
3. Borel JF, Feurer C, Magnée C, Stähelin H. Effect of the new-anti-lymphocytic peptide cyclosporin A in animals. *Immunology* 1977; 32: 1017–1025.
4. Wartburg A, Traber R. Chemistry of the natural cyclosporin metabolites. *Prog Allergy* 1986; 38: 28–45.
5. Van Buren CT. Cyclosporine: progress, problems and perspectives. *Surg Clin N Am* 1986; 66: 435–449.
6. Calne RY, White DJ, Thiru S, Evans DB, McMaster P, Dunn DC, Graddock GN, Pentlow BD, Rolles K. Cyclosporin A in patients receiving renal allografts from cadaver donors. *Lancet* 1978; 2: 1323–1327.
7. Bennett WM, Porter GA. Cyclosporine-associated hypertension. *Am J Med* 1988; 85: 131–133.
8. Diepering H, Frandsen NE, Kemp E. Cyclosporin A: bright prospects for organ transplantation? *Ugeskr Laeger* 1983; 145: 2749–2752.
9. Rezzani R, Rodella L, Bianchi R. Melatonin antagonises the cyclosporine A immunosuppressive effects in rat thymuses. *Int Immunopharmacol* 2001; 1: 1615–1619.

10. Rezzani R. Exploring cyclosporine A-side effects and the protective role-played by antioxidants: the morphological and immunohistochemical studies. *Histol Histopathol* 2006; 21: 301–316.
11. Kurus M, Esrefoglu M, Karabulut AB, Sogutlu B, Kaya M, Otlu A. Oral L-arginine protects against cyclosporine-induced hepatotoxicity in rats. *Exp Toxicol Pathol* 2008; 60: 411–419.
12. Dechant K, Noble S. *Erdosteine*. *Drugs* 1996; 52: 875–881.
13. Braga P, Dal Sasso M, Zuccotti T. Assessment of the antioxidant activity of the SH metabolite I of erdosteine on human neutrophil oxidative bursts. *Arzneimittelforschung* 2000; 50: 739–746.
14. Koc A, Duru M, Ciralik H, Akcan R, Sogut S. Protective agent, erdosteine, against cisplatin-induced hepatic oxidant injury in rats. *Mol Cell Biochem* 2005; 278: 79–84.
15. Yagmurca M, Bas O, Mollaoglu H, Sahin O, Nacar A, Karaman O, Songur A. Protective effects of erdosteine on doxorubicin-induced hepatotoxicity in rats. *Arch Med Res* 2007; 38: 380–385.
16. Kurus M, Esrefoglu M, Sogutlu G, Atasever A. Melatonin prevents cyclosporine-induced hepatotoxicity in rats. *Med Princ Pract* 2009; 18: 407–410.
17. Sun Y, Oberley LW, Li Y. A simple method for clinical assay of superoxide dismutase. *Clin Chem* 1988; 34: 497–500.
18. Esterbauer H, Cheeseman KH. Determination of aldehydic lipid peroxidation products: malonaldehyde and 4-hydroxynonenal. *Method Enzymol* 1990; 186: 407–421.
19. Paglia DE, Valentine WN. Studies on the quantitative and qualitative characterization of erythrocyte glutathione peroxidase. *J Lab Clin Med* 1967; 70: 158–169.
20. Lowry OH, Rosebrough NJ, Farr AL, Randall RJ. Protein measurement with the Folin phenol reagent. *J Biol Chem* 1951; 193: 265–275.
21. Bianchi R, Rodella L, Rezzani R. Cyclosporine A upregulates expression of matrix metalloproteinase 2 and vascular endothelial growth factor in rat heart. *Int Immunopharmacol* 2003; 3: 427–433.
22. De Mattos AM, Olyaei AJ, Bennett WM. Nephrotoxicity of immunosuppressive drugs: long-term consequences and challenges for the future. *Am J Kidney Dis* 2000; 35: 333–346.
23. Rezzani R, Rodella R, Dessy C, Daneau G, Bianchi R, Feron O. Changes in Hsp90 expression determine the effects of cyclosporine A on the NO pathway in rat myocardium. *FEBS Lett* 2003; 552: 125–129.
24. Zhong Z, Li X, Yamashina S, Frankenberg M, Enomoto N, Ikejima K, Kolinsky M, Raleigh JA, Thurman RG. Cyclosporin A causes a hypermetabolic state and hypoxia in the liver: prevention by dietary glycine. *J Pharmacol Exp Ther* 2001; 299: 858–865.
25. Rezzani R. Cyclosporine A and adverse effects on organs: histochemical studies. *Prog Histochem Cytochem* 2004; 39: 85–128.
26. Wolf A, Trendelenburg CF, Diez-Fernandez C, Prieto P, Houy S, Trommer WE, Cordier A. Cyclosporin A-induced oxidative stress in rat hepatocytes. *J Pharmacol Exp Ther* 1997; 280: 1328–1334.
27. Durak I, Ozbek H, Elgün S. Cyclosporine reduces hepatic antioxidant capacity: protective roles of antioxidants. *Int Immunopharmacol* 2004; 4: 469–473.
28. Yagi K. *Lipid Peroxides in Biology and Medicine*. New York, NY, USA: Academic Press; 1980.
29. Lee JY, Kim HS, Park CS, Kim MC. Erdosteine in renal ischemia-reperfusion injury: an experimental study in pigs. *J Vet Med Sci* 2010; 72: 127–130.
30. Hagar HH. The protective effect of taurine against cyclosporine A-induced oxidative stress and hepatotoxicity in rats. *Toxicol Lett* 2004; 15: 335–343.
31. Canoruç N, Çicek R, Atamer A, Dursun M, Turgut C, Güneli E, Canoruç F. Protective effects of vitamin E selenium and allopurinol against stress-induced ulcer formation in rats. *Turk J Med Sci* 2001; 31: 199–203.
32. Rezzani R, Buffoli B, Rodella L, Stacchiotti A, Bianchi R. Protective role of melatonin in cyclosporine A-induced oxidative stress in rat liver. *Int Immunopharmacology* 2005; 5: 1397–1405.
33. Kaya H, Koc A, Sogut S, Duru M, Yilmaz HR, Uz E, Durgut R. The protective effect of N-acetylcysteine against cyclosporine A-induced hepatotoxicity in rats. *J Appl Toxicol* 2008; 28: 15–20.
34. Josephine A, Nithya K, Amudha G, Veena CK, Preetha SP, Varalakshmi P. Role of sulphated polysaccharides from *Sargassum wightii* in cyclosporine A-induced oxidative liver injury in rats. *BMC Pharmacol* 2008; 8: 1–9.
35. Sahin M, Cam H, Olgar S, Tunc SE, Arslan C, Uz E, Yilmaz HR. Protective role of erdosteine on vancomycin-induced oxidative stress in rat liver. *Mol Cell Biochem* 2006; 291: 155–160.
36. Kuvandik G, Duru M, Nacar A, Yonden Z, Helvacı R, Koc A, Kozlu T, Kaya H, Sogüt S. Effects of erdosteine on acetaminophen-induced hepatotoxicity in rats. *Toxicol Pathol* 2008; 36: 714–719.
37. Eraslan E, Ekiz F, Uz B, Koca C, Turkcu UO. Effects of erdosteine on cyclosporine A-induced hepatotoxicity in rats. *Drug Chem Toxicol* 2010; 34: 32–37.
38. Andrés D, Sanz N, Zaragoza A, Alvarez A, Cascales M. Changes in antioxidant defense systems induced by cyclosporine A in cultures of hepatocytes from 2- and 12-month-old rats. *Biochem Pharmacol* 2000; 59: 1091–1100.
39. Durak I, Kaçmaz M, Cimen MY, Buyukkoçak S, Elgün S, Oztürk HS. The effects of cyclosporine on antioxidant enzyme activities and malondialdehyde levels in rabbit hepatic tissues. *Transpl Immunol* 2002; 10: 255–258.