

**T.C.  
REPUBLIC OF TURKEY  
HACETTEPE UNIVERSITY  
FACULTY OF DENTISTRY**

**EVALUATION OF THE EFFECT OF MAXILLARY SINUS  
AUGMENTATION ON THE MAXILLARY SINUS VOLUME  
AND SINUS PHYSIOLOGY: A CONE-BEAM COMPUTED  
TOMOGRAPHY FOLLOW-UP**

**Dt. Samir GOYUSHOV**

**Periodontology Residency Program  
SPECIALTY THESIS**

**ANKARA  
2018**



**T.C.  
REPUBLIC OF TURKEY  
HACETTEPE UNIVERSITY  
FACULTY OF DENTISTRY**

**EVALUATION OF THE EFFECT OF MAXILLARY SINUS  
AUGMENTATION ON THE MAXILLARY SINUS VOLUME  
AND SINUS PHYSIOLOGY: A CONE-BEAM COMPUTED  
TOMOGRAPHY FOLLOW-UP.**

**Dt. Samir GOYUSHOV**

**Periodontology Residency Program  
SPECIALTY THESIS**

**SCIENTIFIC SUPERVISOR  
Associate Prof. Erhan DURSUN**

**ANKARA**

**2018**

03/04/2018

Hacettepe Üniversitesi Diş Hekimliği Fakültesi Dekanlığına

Dr. Samir Göylüçov'nin 03-04-2018 tarihinde jürimiz önünde yaptığı savunmasında "Maksiller sinüs augmentasyonunun total sinüs hacmi ve sinüs fizyolojisine etkisinin konik ışınli bilgisayarlı tomografi ile değerlendirilmesi" başlıklı çalışması jürimiz tarafından Diş Hekimliğinde Uzmanlık Tezi olarak kabul edilmiştir.

Jüri Başkanı : Prof. Dr. Güliz N. Güncü



Tez Danışmanı : Doç. Dr. Erhan Durmuş



Üye : Prof. Dr. Kaan Orhan



ONAY : Tıpta ve Diş Hekimliğinde Uzmanlık Eğitimi Yönetmeliğinin ilgili maddeleri uyanınca yukarıda jüri üyeleri tarafından uygun görülmüş ve Hacettepe Üniversitesi Diş Hekimliği Fakültesi tarafından kabul edilmiştir.



Prof. Dr. A. Rüya YAZICI  
Dekan

**YAYIMLAMA VE FİKRİ MÜLKİYET HAKLARI BEYANI**

Fakültemiz tarafından onaylanan uzmanlık tezimin tamamını veya herhangi bir kısmını, basılı (kağıt) ve elektronik formatta arşivleme ve aşağıda verilen koşullarla kullanıma açma iznini Hacettepe Üniversitesine verdiğimi bildiririm. Bu izinle Üniversiteye verilen kullanım hakları dışındaki tüm fikri mülkiyet haklarım bende kalacak, tezimin tamamının ya da bir bölümünün gelecekteki çalışmalarda (makale, kitap, lisans ve patent vb.) kullanım hakları bana ait olacaktır.

Tezin kendi orijinal çalışmam olduğunu, başkalarının haklarını ihlal etmediğimi ve tezimin tek yetkili sahibi olduğumu beyan ve taahhüt ederim. Tezimde yer alan telif hakkı bulunan ve sahiplerinden yazılı izin alınarak kullanılması zorunlu metinlerin yazılı izin alınarak kullandığımı ve istenildiğinde suretlerini Üniversiteye teslim etmeyi taahhüt ederim.

Tezimin tamamı dünya çapında erişime açılabilir ve bir kısmı veya tamamının fotokopisi alınabilir.  
(Bu seçenikle teziniz arama motorlarında indekslenebilecek, daha sonra tezinizin erişim statüsünün değiştirilmesini talep etmeniz ve kütüphane bu talebinizi yerine getirirse bile, teziniz arama motorlarının önbelleklerinde kalmaya devam edebilecektir)

Tezimin 13.04.2020 tarihine kadar erişime açılmasını ve fotokopi alınmasını (İç kapak, Özet, İçindekiler ve Kaynakça hariç) istemiyorum.  
(Bu sürenin sonunda uzatma için başvuruda bulunmadığım takdirde, tezimin tamamı her yerden erişime açılabilir, kaynak gösterilmek şartıyla bir kısmı veya tamamının fotokopisi alınabilir)

Tezimin ..... tarihine kadar erişime açılmasını istemiyorum ancak kaynak gösterilmek şartıyla bir kısmı veya tamamının fotokopisinin alınmasını onaylıyorum.

Serbest Seçenek/Yazarın Seçimi

12/04/2018

(İmza)



Öğrencinin Adı SOYADI

Samir Göğüşoğlu

## ETİK BEYAN SAYFASI



T.C.  
**HACETTEPE ÜNİVERSİTESİ**  
 Girişimsel Olmayan Klinik Araştırmalar Etik Kurulu

Sayı : 16969557 -1511

Konu : ARAŞTIRMA PROJESİ DEĞERLENDİRME RAPORU

**Toplantı Tarihi** : 07 KASIM 2017 SALI  
**Toplantı No** : 2017/24  
**Proje No** : GO 17/778 (Değerlendirme Tarihi: 27.09.2017)  
**Karar No** : GO 17/778-13

Üniversitemiz Diş Hekimliği Fakültesi Periodontoloji Anabilim Dalı öğretim üyelerinden Doç. Dr. Erhan DURSUN' un sorumlu araştırmacı olduğu, Prof. Dr. Kaan ORHAN ile birlikte çalışacakları ve Dt. Samir GÖYÜŞOV' un uzmanlık tezi olan, GO 17/778 kayıt numaralı, "**Dental İmplant Öncesi Sinüs Yükseltme Operasyonunun Maksiller Sinüs Hacmi Ve Fizyolojisine Etkisinin Konik Işınlı Bilgisayarlı Tomografi (KİBT) ile İncelenmesi**" başlıklı proje önerisi araştırmannın gerekçe, amaç, yaklaşım ve yöntemleri dikkate alınarak incelenmiş olup, etik açıdan uygun bulunmuştur.

- |  |   |
|--|---|
| 1. Prof. Dr. Nurten AKARSU (Başkan)          | 10 Prof. Dr. Oya Nuran EMİROĞLU (Üye)       |
| 2. Prof. Dr. Sevda F. MÜFTÜOĞLU (Üye)        | 11 Yrd. Doç. Dr. Özay GÖKÖZ (Üye)           |
| 3. Prof. Dr. M. Yıldırım SABA (Üye)          | İZİNLİ<br>12. Doç. Dr. Gözde GİRGİN (Üye)   |
| 4. Prof. Dr. Nedret SAĞLAM (Üye)             | 13. Doç. Dr. Fatma Visal OKUR (Üye)         |
| 5. Prof. Dr. Hatice Doğan BUZOĞLU (Üye)      | 14. Doç. Dr. Can Ebru KURT (Üye)            |
| İZİNLİ<br>6. Prof. Dr. R. Köksal ÖZGÜL (Üye) | 15. Yrd. Doç. Dr. H. Hüseyin TURNAGÖL (Üye) |
| 7. Prof. Dr. Ayşe Lale DOĞAN (Üye)           | 16. Öğr. Gör. Dr. Müge DEMİR (Üye)          |
| 8. Prof. Dr. Elmas Ebru YALÇIN (Üye)         | 17. Öğr. Gör. Dr. Meltem ŞENGELEN (Üye)     |
| 9. Prof. Dr. Mintaze Kerem GÜNEL (Üye)       | 18. Av. Meltem ONURLU (Üye)                 |

## TEŞEKKÜR

Uzmanlık eğitimim boyunca ve bu tezin oluşturulmasında büyük emekleri olan danışman hocam Doç.Dr. Erhan DURSUN'a,

Tez çalışmamın her aşamasında sonsuz yardımını hissettiğim hocam Prof.Dr. Kaan ORHAN'a, ölçümleri beraber yaptığımız Dt. Umut SEKİ'ye,

Eğitimim sürecinde bilgi ve tecrübelerinden yararlandığım, daha da önemlisi kendisinden hayata dair çok şey öğrendiğim, hayatta ve kariyerimde başarıyı bulmamda bana her zaman yol gösteren, hoşgörüsü ve sevgisi ile desteğini her zaman yanımda hissettiğim, bendeki yeri çok özel olan ve hep de öyle kalacak olan, canım hocam sayın Prof. Dr. Tolga F. TÖZÜM'e,

Uzmanlık eğitimim boyunca bilgi ve deneyimlerini paylaşarak eğitimime önemli katkılar sağlayan Prof. Dr. Ezel BERKER ve H.Ü Periodontoloji A.D.'nin tüm değerli öğretim üyelerine,

Uzmanlık süresince tecrübe ve becerilerimin gelişmesinde büyük katkıları olan Doç.Dr.Abdullah AKMAN, Yrd.Doç.Dr. Gencay KEÇELİ, Yrd.Doç.Dr. Burak KUTLU'ya,

Uzmanlık hayatımı güzelleştiren, değerli dostluklarını benimle paylaşan Dt.Tolga GENÇ, Dt.Sahand TAHERİ, Dt. Hazel KOCABAŞ, Dt. Bünyamin ÇALIŞAN, Dt. Yeşim ÖZDEMİR, Dt. Mehmet ÖZGÜR, Dt. Buğra ÇAKIN'a,

Karşılıksız sevgi ve fedakarlıklarıyla beni hayata hazırlayıp bu noktaya getiren, desteklerini ve güvenlerini her zaman arkamda hissettiğim, her şeyimi borçlu olduğum sevgili annem, babam ve abime,

Sevgisi ve hoşgörüsü ile bana sonsuz güç veren, desteğini her zaman yanımda hissettiğim, sevgili hayat arkadaşım, eşim Mercan'a,

Sonsuz teşekkürlerimi sunarım...

## ÖZET

**Samir, G. Maksiller sinüs augmentasyonunun total sinüs hacmi ve sinüs fizyolojisine etkisinin konik ışınli bilgisayarlı tomografi ile değerlendirilmesi. Hacettepe Üniversitesi Diş Hekimliği Fakültesi. ANKARA 2018.** Sinüs lift ameliyatı posterior maksilladaki rezidüel kemik miktarının artırılması için yapılan işlemdir. Sinüs elevasyon ameliyatından sonra hastaların çoğunda ameliyata bağlı patoloji gelişmese de bu ameliyat sinüs fizyolojisi için risk taşımaktadır. İlgili bölgenin kemik kalınlığının ölçülmesinde KIBT daha net sonuçlar vermektedir. Bu çalışmanın amacı sinüs cerrahisi sonrasında augmente edilmiş kemik hacmi ve total sinüs hacmini, krestal dişeti kalınlığı ve Schneiderian membran kalınlığı arasındaki ilişkini üçboyutlu olarak değerlendirmektir. Çalışmaya dahil edilmiş 22 hastaya iki aşamalı sinüs yükseltme ameliyatı uygulanmış, ameliyat sonrasında da herhangi bir komplikasyon gelişmemiştir. Tüm hastaların ameliyattan önceki ve sonraki KIBT görüntüleri detaylı incelenmiştir. Sinüs kvitesinin ortalama greftlenmiş kısmı %14,87 olarak tespit edilmiştir. Sinüs kavitesinin osteomeatal üniteye ve dolayısıyla sinüs fizyolojisine zarar vermeden greftlenmesi, sinüsün greftlenebilir güvenli hacminin aşılmadığı anlamına gelmektedir. Schneiderian membran kalınlığı ve krestal dişeti kalınlığı arasında korrelasyon tespit edilmemiştir.

**Anahtar Kelimeler:** sinüs lift, greft hacmi, konik ışınli bilgisayarlı tomografi, sinüs fizyolojisi



## ABSTRACT

**Samir, G. Evaluation of the Effect of Maxillary Sinus Augmentation on the Maxillary Sinus Volume and Sinus Physiology: A Cone-Beam Computed Tomography Follow-Up. Hacettepe University Faculty of Dentistry, Specialty Thesis in Periodontology, ANKARA 2018.**

Sinus lifting procedure is a form of preprosthetic surgery for increasing the quantity of bone in the posterior maxilla. Although not many patients develop maxillary sinus pathology-related complaints after sinus floor elevation surgery, this procedure carries the inherent risk of compromising sinus physiology. There is the risk of miscalculating the amount of available bone in the posterior maxilla for implant placement by using two-dimensional panoramic views. CBCT provides much more accurate measurements of the available bone volume. The overall aim of the present thesis were to evaluate three-dimensionally the augmented bone volume and total volume of the maxillary sinus, correlation between the thickness of the Schneiderian membrane and crestal gingival thickness, following sinus lift procedures. In this study all included 22 patients were successful two stage sinus elevation surgeries and without complications. All patients were preoperatively and postoperatively analyzed by CBCT. The average percentage of the grafted part was 14.87 % through manual measurements and 14.66 % through automatically measurements. Safe volume after sinus grafting means not to interfere with the osteomeatal unit that hazardous to sinus physiology. No correlation weref found between the thickness of the Schneiderian membrane and crestal gingival thickness.

**Keywords:** Sinus lifting, graft volume, cone-beam computed tomography, sinus physiology

**CONTENTS**

ONAY SAYFASI	iii
YAYIMLAMA VE FİKRİ MÜLKİYET HAKLARI BEYANI	iv
ETİK BEYAN SAYFASI	v
TEŞEKKÜR	vi
ÖZET	vii
ABSTRACT	viii
CONTENTS	ix
ABBREVIATIONS	xi
FİGURES	xii
TABLES	xiii
INTRODUCTION	1
<b>1. LITERATURE REVIEW</b>	<b>4</b>
1.1. Implants	4
1.2. Bone	5
1.2.1. Bone Regeneration After Sinus Lift Surgery	7
1.3. Anatomy of Maxillary Sinus	8
1.3.1. Septa	12
1.3.2. Ostium	14
1.3.3. Schneiderian Membrane	15
1.3.4. Vascularization	17
1.3.5. Innervation	20
1.4. Sinus Lifting	21
1.4.1. Pre-surgical Evaluation	22
1.4.2. Grafts	25
1.4.3. Sinus Lift Techniques	26
1.4.4. Surgical Technique	28
1.4.5. Complications	32
1.4.6. Implant Survival in the Augmented Sinus	35
<b>2. MATERIALS AND METHODS</b>	<b>38</b>
2.1. Objectives	38
2.2. Study Design and Study Groups	38

<b>3. RESULTS</b>	<b>43</b>
<b>4. DISCUSSION</b>	<b>46</b>
<b>5. CONCLUSION</b>	<b>51</b>
<b>6. REFERENCES</b>	<b>52</b>

## ABBREVIATIONS

<b>3D</b>	: three dimensional
<b>ALADA</b>	: As Low As Diagnostically Acceptable
<b>ALARA</b>	: As Low As Reasonably Achievable
<b>CBCT</b>	: cone-beam computed tomography
<b>CT</b>	: computed tomography,
<b>EA</b>	: Extraosseous Anastomosis
<b>ENT</b>	: Ear Nose and Throat
<b>IA</b>	: Intraosseous anastomosis
<b>IOA</b>	: Infraorbital artery
<b>LSFE</b>	: Lateral sinus floor evaluation
<b>M</b>	: mean
<b>MRI</b>	: magnetic resonance imaging
<b>PSAA</b>	: the posterior alveolar artery
<b>SD</b>	: standard deviation
<b>SMP</b>	: sinus membrane perforations
<b>Ti</b>	: titanium

## FIGURES

<b>Figure</b>	<b>Page</b>
1.1. Inadequate residual bone height	9
1.2. Lateral wall of the nasal cavity	10
1.3. Medial wall of the sinus cavity	10
1.4. Posterior wall of the sinus cavity	11
1.5. Sinus septa	13
1.6. Double window technique	13
1.7. Sagittal slice of the sinus cavities	13
1.8. Antranasal foramen	14
1.9. Histological slice of the Schneiderian membrane	15
1.10. Blood supply of the sinus cavity	19
1.11. Lateral sinus floor elevation	22
1.12. Coronal CT slice of the paranasal sinuses	23
1.13. Mucoperiosteal flap elevation	29
1.14. Lateral bone window	30
1.15. The appearance of the elevated sinus membrane	30
1.16. Grafted sinus cavity	31
1.17. Covering lateral window with resorbable collagen membrane	32
1.18. Inserted implants	32
1.19. Sinus membrane perforation	33
2.1. Thickness measurement of the Schneiderian membrane	40
2.2. Total sinus volume measurement	41
2.3. Visual construction of the evaluated sinus cavity	41

**TABLES**

<b>Table</b>	<b>Page</b>
<b>3.1.</b> Schneiderian membrane thickness.	44
<b>3.2.</b> Measurements before and after sinus lifting surgery.	44
<b>3.3.</b> Volumetric measurements of the sinus cavity.	45

## INTRODUCTION

Periodontal disease and dental caries are the major causes for tooth loss. Even if the prevalence of edentulism continues to decline, in western countries, the loss of teeth in the posterior upper jaw will still be a quite common reason for patients requiring dental care [1]. Since ancient times, there have been attempts to solve this problem as the loss of teeth leads to aesthetic, functional, as well as psychological problems.

Conventional management of partially edentulous patients formerly involved the use of variety of removable or fixed reconstructions designed to apply selected teeth [2]. However, many patients with removable prostheses experience trouble obtain acceptable aesthetic results and efficient function. Functionally, it is more challenging for a patient to digest food; he/she may experience malfunctioning of temporomandibular joint and overloading of masticator muscles. Fortunately, maladjusted complete denture patients react very well to implant prostheses [3]. The implant treatment to prosthetically restore function and esthetics subsequent the loss of teeth has become a routine treatment alternative to conventional tooth-supported fixed or removable prostheses, principally due to the benefit of bypass the sacrifice of intact structure of adjacent teeth. However, common obstacle of detected in implant dentistry is inadequate bone quality and quantity to allow implant placement just as standard protocol. Alveolar bone atrophy following tooth loss tends to be irreversible and rapid. In some cases posterior maxillary alveolar bone atrophy is very distinct, leaving only about 1-2 mm thin cortical bone between the oral cavity and the maxillary sinus. Analogous thin bone's not sufficient to provide primary stability and/or osseointegration for a dental implant.

Accordingly, osseointegration, which was discovered in the middle of the twentieth century, established the era of dental implantology [4]. However, where necessary augmentation of the posterior maxilla is critical, placement of dental implants in the atrophic maxilla is compelling procedure. Numerous clinical techniques have been developed to address these bone deficiency problems [5]. The first maxillary sinus floor augmentation surgery was performed in 1980s [6].

Moreover, the progress of sinus lifting techniques and developments in biomaterial research have resulted magnificent outcomes. These advances have been reported in recent years for implant-supported rehabilitations, even in cases involving serious maxillary posterior alveolar bone atrophy [7]. Sinus lifting procedure is a form of preprosthetic surgery for increasing the quantity of bone in the posterior maxilla.

Pre-operative evaluation of the alveolar bone and the maxillary sinus is crucial for the success of this surgery. Maxillary sinus can be visualized on the panoramic radiograph, computed tomography (CT), magnetic resonance imaging (MRI) and cone-beam computed tomography (CBCT) [8]. In the recent years, three-dimensional evaluation methods have been the most recommended technique for investigations before maxillary sinus lift surgeries with bone substitute biomaterials. CT is recognized as the “gold standard” for examination of the maxillary sinuses, which has limitations because of high cost and high radiation exposure [9-12]. Much more information can be collected from CBCT other than the width and length of the residual alveolar bone [13]. CBCT can easily establish sinus opacification (OPA) and can provide worthwhile information on changes of the paranasal sinuses without additional exposure [14].

In post-surgical evaluation of the results, cone beam computed tomography provides broader overview to the surgically treated field, an opportunity to assess dimensions of the augmented area and changes over the time, as well as an interaction with a maxillary sinus.

CBCT analyses have been described as a fast, simple, relatively correct and encouraging way to quantify long-term changes in the grafted area. Some authors have also pointed out that CBCT is accurate when examining soft tissue thickness [15]. Moreover, many studies/clinicians are still using CBCT for soft tissue thickness assessment. The most common intraoperative complication during sinus graft procedures is perforation of the sinus membrane. It is therefore important to predict possible sinus membrane perforations (SMPs) before the operation, may suggest a way such as a correlation between crestal soft tissue thickness and sinus membrane



thickness [16, 17]. There is only limited knowledge about the association between crestal gingival mucosa thickness and Schneiderian membrane thickness [18].

Linear measurements and the total maxillary sinus volume have conventionally been analyzed using cadavers [19-21]. Recent improvements in medical image processing technology have made possible the use of 3- dimensional evaluation of the grafted area within the maxillary sinus after surgery. These can aid the surgeon in identification the overall anatomical structure and assessment of maxillary sinus volume [22]. Presurgical knowledge of the required bone volume reduces the extent of the surgical procedure as well as the possible complications encountered and minimizes hospital costs and expenses for the patient [23-25].

The objectives of the present study were; to analyze the correlation between crestal gingival thickness and the thickness of the Schneiderian membrane, to calculate the required graft volume for several augmentation heights and implant lengths, to measure the augmented bone volume and total volume of the maxillary sinus using preoperative and postoperative CBCT scans in patients referred for dental implant placement in the posterior maxilla.

## 1. LITERATURE REVIEW

### 1.1. Implants

Nowadays, the use of dental implants is a well-documented favorite treatment method for replacing missing teeth. There have been used many types of implants for teeth replacement, including subperiosteal and endosteal implants with fibrous encapsulation, and endosseous implants with direct bone contact (osseointegration). The osseointegration of titanium dental implants was developed and scientifically documented by Brånemark and co-workers [26, 27] and by Schroeder and co-workers [28]. Osseointegration is defined as a time dependent healing process whereby clinically asymptomatic rigid fixation of alloplastic materials is achieved, and maintained, in bone during functional loading [28]. The implant should establish appropriate primary fixation (stability) after the installation at the receiving site to achieve osseointegration.

The material choice for dental implants is titanium since it has proper mechanical properties and a comprehensively documented biocompatibility [29]. Titanium has the surprising property that it can bind to living tissue and to bone.

Systematic reviews of long-term follow-up studies have shown that about 95% of the implant cases are still functioning after 5 years when placed in sufficient bones. The implants which are used in conjunction with major bone grafting have in general less good survival rates [30-33].

The preconditions for successful long-term outcomes are the attainment and maintenance of implant stability. Implant stability is achieved via association of mechanical stability and bone formation at and around the implants' surface. Implant stability can be divided into primary and secondary stability. The former is obtained during implant placement and is determined by the bone density, the surgical technique and the implant design.

Bone-healing response is induced by the surgical trauma and gradually results in secondary stability. Several studies have reported that, a certain grade of surface roughness enhances the implant's performance from several points of view [34-36]. Application of Ti dental implants with moderately rough surface topography lead to substantially advanced tissue integration of the implants, which is apparently related with their positive effect on the proliferation and differentiation of osteoblasts [37, 38]. Recently, with few exceptions, most endosseous dental implants have rough surface structures.

## **1.2. Bone**

According to Wolff, 1892 the bone in a systemically healthy patient will adapt to the loads under which it is placed (Wolff's law). Following teeth loss, the alveolar processes are no longer exposed to chewing forces and this may lead to resorption of dentoalveolar bone. Surgical procedure, infection and other traumatic injury of alveolar bone can change the original contour and therefore the volume of the alveolar process. Huge, critical sized bony defects will not regenerate fully spontaneously. Dental implant therapy is a common and well-documented method of supporting dental prosthesis and has a good long-term prognosis. The jawbone with sufficient quality and volume is prerequisite to successful implantation. Intervention of local anatomical structures such as the mental foramen or the maxillary sinuses reduces the possibility to install dental implants. Different surgical methods and techniques are applied to increase bone volume and restore to the original shape of the bone. Besides its excellent mechanical behavior, bone is a dynamic tissue with a remarkable healing potential [39, 40]. The gold standard of bone substitutes is still considered autogenous cortical bone as blocks or as particulate form of it.

Bone tissue is a highly developed supporting tissue and the definition of it is "a hard form of connective tissue composed of osteocytes and calcified collagenous intracellular substance arranged in thin plates" [41]. The role of bone is to protect and support vital organs of the body, to be storage for minerals and be involved in mineral homeostasis. Bone marrow is the soft spongy tissue that lies within the hollow interior of long bones and hosts the production of blood cells. The skeleton of

adult consists of two macroscopic types of bone: cortical or compact bone and cancellous or trabecular bone. Compact bone can be seen in the long bones and the surface of the flat bones and represents nearly 80% of the mass of the skeleton. It consists of several passages for diffusion of blood vessels and molecules. Inside the circumferential lamellae are primary osteons, which form when the blood vessels on the surface of the bone become part of the periosteal bone. Trabecular bone is lacework surrounding the bone marrow of most flat bones, within vertebral bodies and the metaphyseal region of long bones. It is built of a three-dimensional structure of interconnected plates and rods known as trabeculae, each of which is approximately 200 $\mu$ m thick [42]. The trabeculae seem to be organized randomly but are still able to arrange maximum strength as they pursue the lines of stress. The bone homeostasis is contributed by two types of cells: osteoblasts and osteoclasts which have crucial role in the remodeling and repair of bone tissue.

Osteoblasts are derived from local osteoprogenitor mesenchymal cells and are bone-forming cells that form osteoid by embedding in bone extracellular matrix as it is deposited. The osteoid becomes mineralized by minerals withdrawn from blood. However, the particular mechanisms by which osteoblasts become buried in bone matrix to take on a life as an osteocyte remained elusive [43]. Osteoblasts are settled on the outer surface of bone and bone cavities. Osteoclasts are the largest of the bone cells and are devoted to bone resorption as bone are involved in a continuous cycle of resorption and apposition. This process is termed as “bone turnover”.

The outmost layer surrounding all compact bone is termed periosteum and the inner surface is called endosteum. In bone formation, periosteum is more active than endosteum. Periosteum is much more active in bone formation and composed of two layers. The outer “fibrous” layer consists of fibroblasts, collagen and elastin along with a nerve and micro-vascular network. These components establish mechanical stability to the periosteum. The inner “cambium layer” is densely consisted with cells that influence bone formation and bone repair [44]. These features provide the periosteum with regenerative capacity.

Bone healing after fracture is identified by an acute inflammatory response which comprehends initially blood clot formation in the injured area, further on migration of inflammatory cells e.g. lymphocytes, granulocytes and monocytes and the formation of granular tissue. The inflammatory phase is believed to stimulate cell migration and proliferation of mesenchymal cells. Cell migration and proliferation are stimulated in inflammatory phase. Following the inflammation phase, chondroblasts and osteoblasts are differentiated from mesenchymal cells which aggregate at the repair site. The mineralization and formation of collagen matrix are completed. These processes end up soft callus formation that fuses the two parts of fracture margins together. In time, the soft callus will maintain to ossify and woven bone will form. In the end, the healing part of bone will restore its original shape and structure [45, 46].

### **1.2.1. Bone Regeneration After Sinus Lift Surgery**

Even with the well-established clinical effectiveness of sinus lift procedure there are still questions regarding the origin of newly formed bone, the influence of the surrounding tissues, the contribution and fate of the graft material, and the volume of new bone necessary for a successful treatment [47]. Earlier histologic observations of biopsy specimens implicated the contiguous endosteum of the sinus floor (the residual bone) and the elevated periosteum as possible sources for the newly generated bone [48]. There are different opinions as to whether residual bone height affects implant survival or the graft result itself. In retrospective studies, Wheeler et al. noted that alloplasts had a high implant-retention rate except when the preoperative bone height was  $<3$  mm [49, 50]. In contrast, a 2003 review by Wallace and Froum noted that the influence of the residual bone height in the lateral- window technique was unknown [7]. In a study by Price et al. the influence of the residual bone height was evaluated as a potential variable by comparing samples with  $<4$  mm to samples with  $\geq 4$  mm [47]. The range of vertical height dimension was considerable (0.5 to 7.0 mm), but there was no associated difference in new bone formation found in any zone of the graft compartment. They concluded that new bone was derived from a combination of de novo appositional and intramembranous formation in which cells evolved from the regeneration of vascular and perivascular

tissues that grew inward at a uniform rate from the entire periphery, but this proposal requires further investigation.

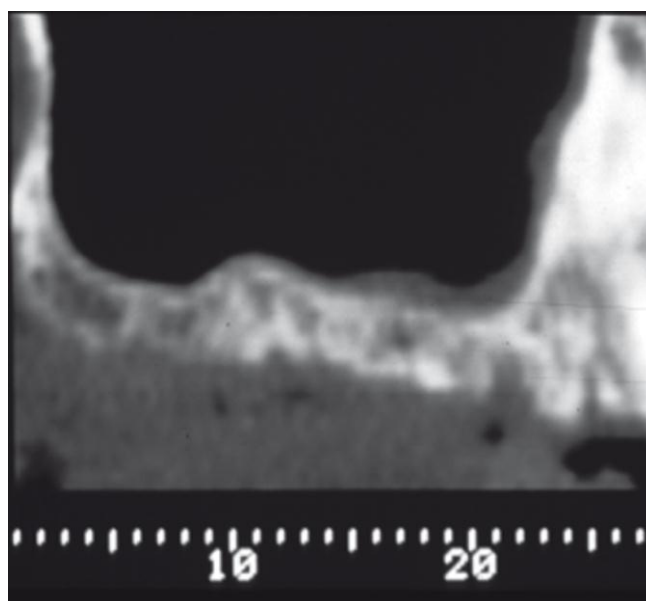
Jensen and coworkers using minipigs found that the volume of autogenous bone grafts from the iliac crest and the mandible was reduced significantly after maxillary sinus floor augmentation [51]. The graft volume was better preserved after the addition of Bio-Oss and the volumetric reduction was significantly influenced by the ratio of Bio-Oss and autogenous bone [52]. The authors also found that early bone-to-implant contact formation was more advanced with autogenous bone. No differences between the using of mandibular or iliac bone grafts were observed since the bone-to-implant contact was not significantly influenced by the origin of the bone graft.

There has been considerable clinical controversy about the role of the graft material in the sinus lift procedure. The discussion has usually been limited to osteogenic capacity, osteoinductivity, or osteoconduction. In addition, an alternative function of graft materials as space holders has been gaining interest in the literature. Experiments, in which the sinus membrane was elevated and allowed to rest on simultaneously placed implants, indicated that creating a space with a blood clot alone could lead to bone deposition on an implant [52-56]. Sohn et al. found a faster and greater new bone formation was observed in sites that received no grafting material [57, 58]. The repositioned bony window may accelerate new bone formation earlier versus placement of a collagen membrane. Srouji et al. found that the Schneiderian membrane has an osteogenic potential [59]. On the other hand, Scala et al. found that bone formation started from the parent bone of the sinus floor and extended toward the apex of the implants [60]. However, this coronal proliferation of bone did not ever exceed 4.5mm, indicating the limitation dictated by the Schneiderian membrane collapsing over the implant apex.

### **1.3. Anatomy of Maxillary Sinus**

The maxilla consists of various structures including the maxillary sinus, the pterygoid plates, the lateral nasal walls, associated nerves, arteries and veins and

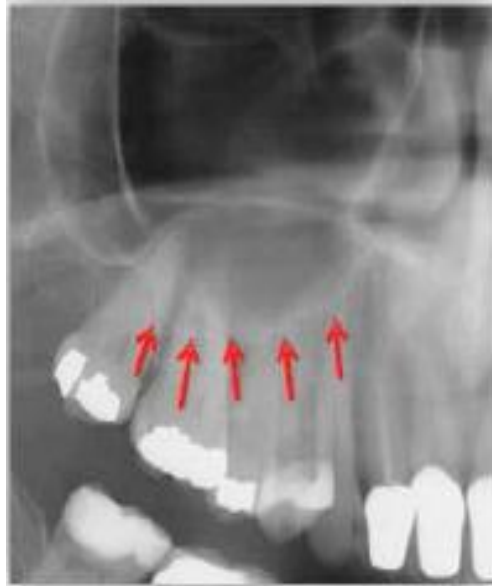
teeth. The two asymmetrical shaped maxillary sinuses are located laterally to the nose cavity. The maxillary sinus starts to develop at the about 12<sup>th</sup> week of intra-uterine life, with an invagination of the mucosa of nasal passage's lateral wall. The size of the sinus is about 0.1 to 0.2 cm<sup>3</sup> at birth and maintains its size until the eruption of the permanent teeth [17]. At the end of the growth, maxillary sinus cavities have expanded in the maxillary bone three dimensionally, apparently caused by the mild positive intra-sinus pressure due to the minor nasal openings. Another potential cause for expansion can be the physiology of the mucosal sinus membrane with presence of osteoclasts [61]. The development, concerning pneumatization (increasing volume of air contained in it), is attained by adolescence, while its volume may increase more after tooth loss. The sinus volume increases up to the age of 20 years. The resorption of the maxillary alveolar bone and pneumatization of the maxillary sinus may lead to troubles to the implant therapy and requisite to perform sinus lift surgery to increase bone height (Figure 1.1.).



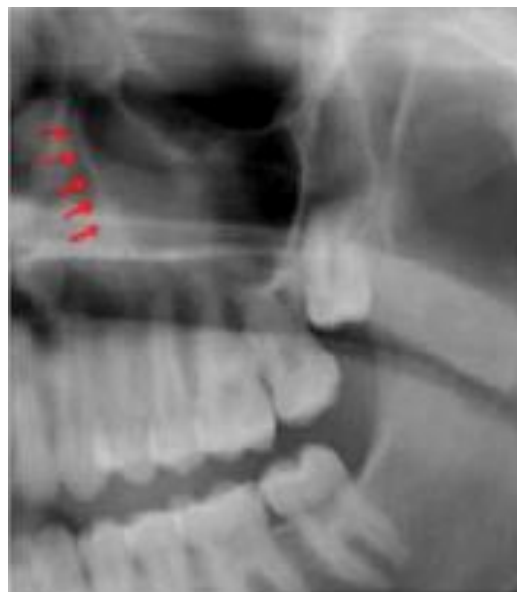**Figure 1.1.** Inadequate residual bone height

The maxillary sinus is the largest of the paranasal sinuses including the sphenoid, ethmoid, and frontal sinus, and occupies majority of the maxilla. It is typically a single chamber with a quadrangular pyramidal shape with numerous walls, limited by the floor of the orbit superiorly; the hard palate, alveolus and dental portion of the maxilla inferiorly; the zygomatic process laterally; the pterygopalatine

fossa posteriorly (Figure 1.4.); and the lateral wall of the nasal cavity (Figure 1.3.), containing the maxillary ostium and the accessory ostia, medially (Figure 1.2.) [62, 63].

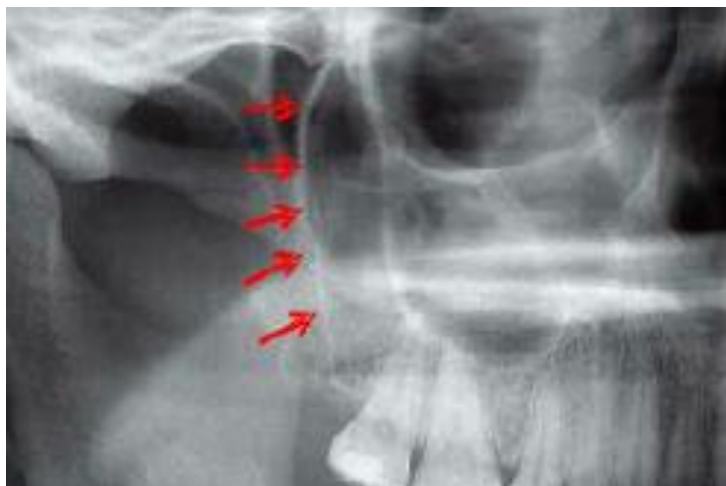


**Figure 1.2.** Lateral wall of the nasal cavity



**Figure 1.3.** Medial wall of the sinus cavity





**Figure 1.4.** Posterior wall of the sinus cavity

The most often involved bony walls in sinus surgeries are the mesiobuccal and medial walls (Figure 1.3.). The mesiobuccal wall is contained a thin cortical bone comprising a complex neurovascular system: the arterial anastomosis the infraorbital region, anterior teeth, and periodontal component. In some instances, the thickness of the wall can reach 2mm, particularly in brachyfacial patients. This thickness cannot be specified through panoramic radiographs, but only using CT-Scan analysis. The posterior maxillary teeth are innervated by complex neurovasculature from the maxillary tuberosity [64]. Sinus lift surgery performed in the apical region of posterior vital teeth may enhance the risk of devitalization of the related teeth [17]. The medial wall is rectangular and separates the maxillary sinus from nasal cavity. On the other hand, lower part of this wall corresponds to the inferior meatus of the nasal cavity [61].

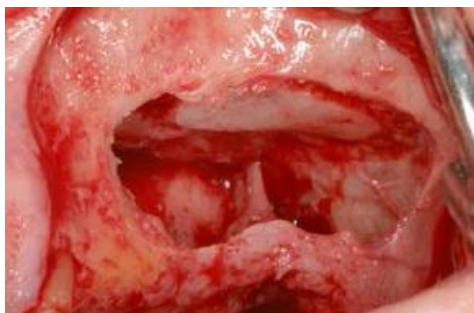All sinus walls reach their thickest form in adults with complete dentition. Usually it has some depressions near the premolars and molars. The sinus floor tends to the resorption and in some cases to the bone perforations around the roots with age, so that only the Schneiderian membrane separates the roots from the sinus cavity.

The average volume of a maxillary sinus in adult is approximately 12 to 15 cm<sup>3</sup> (with a large range from 3.5 to 35.2cm<sup>3</sup>) with a height of 36 to 45mm, length of 38 to 45mm, and width between 15 to 35 mm [17, 65-67]. The convex floor of the

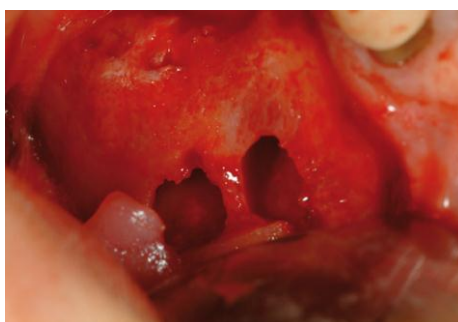cavity is approximately 1cm below the nasal floor, with its deepest point usually being in the region of first molar teeth. There is a convolution in the floor of the sinus frequently because of the maxillary teeth roots. Anteriorly the sinus cavity extends to the canine or premolar region. The maxillary sinus cavity maintains its total volume while the posterior teeth stay in function, however tends to enlarge with age and especially when the posterior maxillary teeth are lost. The path of this expansion is both laterally and inferiorly. At the edentate phase, expansion often continues such, that only a paper-thin bone on the lateral and occlusal walls are left. There are some different theories for this expansion and one of them is that the maxillary alveolar bone displays atrophy as the strain from occlusal function is reduced. The volume of the sinus may further increase with aging and tooth loss due to continuous resorption of all cavity walls. This pneumatization is not identical, can vary from patient to patient, and even can be asymmetrical between the two sinuses in the same patient [65].

### **1.3.1. Septa**

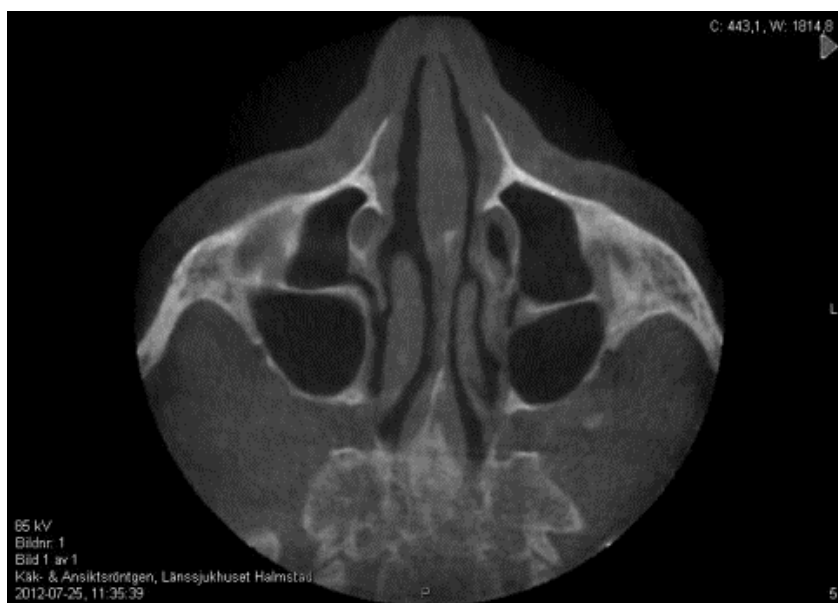The maxillary sinus cavity can be separated into smaller cavities by bone septa (Figure 1.5.). This bony septum is a barrier of cortical bone that bulge into the sinus cavity from the floor or the lateral wall of the maxillary sinus [68-71]. The sinus septa dividing the maxillary sinus cavity into separate compartments, is a phenomenon first described by A.S. Underwood in 1910 [72]. There is abundant anatomical variation of the septa in their prevalence, size, location, and morphology, regardless of the degree of atrophy. The average height of the septa measured as 7.5mm. The septa, dividing the sinus cavity into two separate cavities is called “complete septa” and was found in only 0.3%. The overall prevalence of septa reported in the literature at the sinus level is between 16% and 48% [68-70, 73, 74]. The presence of maxillary sinus septa may complicate sinus membrane lifting procedures, particularly when they are not identified before the surgery (Figure 1.6.). Two-dimensional radiographic measurements can lead to false positive and false-negative judgements in the visualization of septa. Hence, before the sinus lift surgery, a detailed evaluation of the related sinus using CBCT could be recommended (Figure 1.7.) [75-80].



**Figure 1.5.** Sinus septa



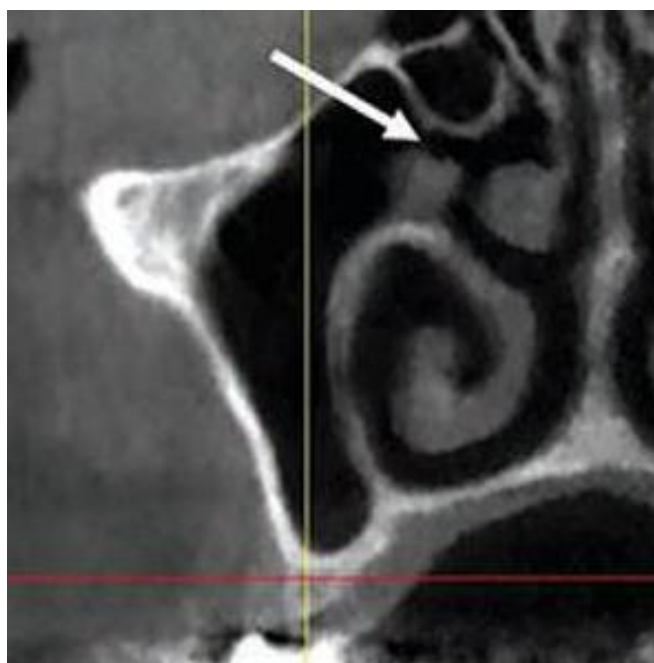
**Figure 1.6.** Double window technique



**Figure 1.7.** Sagittal slice of the sinus cavities

### 1.3.2. Ostium

The antronasal foramen, a drainage port for the sinus, lies high on the medial wall of the sinus (Figure 1.8.). This port opens into the nasal cavity between the middle and lower nasal conchae [81]. Functions of the maxillary sinus contain air humidification and heating; promote to weight lowering in the cranial bones of the skeleton, protection of the skull base against mechanical trauma, thermal isolation of some of the superior nerves, and influence in phonation [82, 83]. The fact that the ostium lies high on the medial wall is an advantage to sinus lift procedure as it is possible not to obstruct with graft placement. It has been suggested that a maxillary sinus membrane elevation may even in fact progress symptoms of sinusitis by bringing the sinus floor closer to the drainage port. The discovery of the ostium in the medial wall may happen in surgery hence, the sinus membrane should not be elevated to a height of obstruction of the ostium.

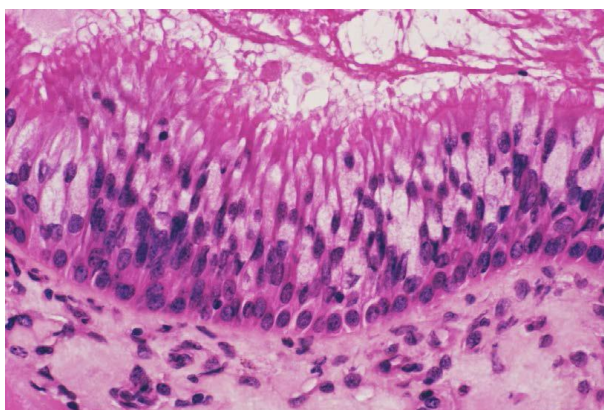


**Figure 1.8.** Antronasal foramen

### 1.3.3. Schneiderian Membrane

The maxillary sinus cavity is lined with respiratory epithelium, or pseudostratified ciliated columnar epithelium, that covers a moveable and extremely vascular connective tissue. Three types of cells are recognized in sinus membrane: ciliated cells, goblet cells and basal cells [84]. This membrane is an extension of the nasal respiratory epithelium (Figure 1.9.), known as the Schneiderian membrane consists of the following [85]:

- a) Pseudostratified cylindrical epithelium with goblet cells and,
- b) Corium, or lamina, with a junction of blood vessels and glands.



**Figure 1.9.** Histological slice of the Schneiderian membrane

In the literature, little data are available on the thickness of healthy sinus membranes. The mean histological Schneiderian membrane thickness was  $0.3 \pm 0.17$  mm which was statistically different from mean CBCT membrane thickness ( $0.79 \pm 0.52$  mm) [86, 87]. There seems to be an association between thickness of the antral mucosa and periodontal phenotype [86]. Mucosal thickening of 2 mm is considered a reliable threshold for pathological mucosal swelling of the Schneiderian membrane [88]. Mucosal thickening of more than 2 mm can be grouped according to criteria from Soikkonen and coworkers 91: 1) Flat: shallow thickening without well-defined outlines, 2) Semi-aspherical: thickening with well-defined outlines rising in an angle of more than  $30^\circ$  from the floor or the walls of the sinus, 3) Mucocele-like: complete opacification of the sinus, 4) Mixed flat and semi-aspherical thickenings, 5)

Other mucosal thickenings types or pathological findings. A high prevalence of mucosal thickening in paranasal sinuses in asymptomatic patients has been reported [89-92]. Because of the complex anatomy in the posterior maxilla, cross-sectional imaging has been proposed as the standard diagnostic imaging method for preoperative planning of dental implant placement [93-96]. CBCT can be regarded as a first choice for three-dimensional imaging of the posterior maxilla due to less radiation administered to the patient compared to CT [96, 97].

However, the sinus membrane can suffer from damage causing increase in its thickness due to inflammatory reaction, known as sinusitis. In cases, in which the thickness is greater than 3-4 mm, it is reasonable for the patient see an Ear-Nose-Throat specialist. The sinus membrane includes a highly vascularized lamina propria [59] containing of two layers, a surface layer of connective tissue beneath the epithelium, and the deep compact layer below the vascular layer merging with the periosteum to form the mucoperiosteum [98]. The inmost layer is similar to a periosteum-analog construction [59]. Under normal circumstances, the epithelium remains constantly humidified by fluid secretion from glands contained in Schneiderian membrane. This mucosal epithelium leads fluid to the ostium that terminates in the nasal cavity [99]. This process is realized by the 100-150 cilia existing in every cuboidal cell epithelium, which vibrate at a frequency of 1000 strokes per minute. Because of its direct contact with air, this membrane has an immune defense ability, although less significant than the nasal mucosa. The cells of the sinus membrane are capable of differentiating into osteoblasts, consequently making osteogenesis in this region possible. The ciliated epithelium transports pus and mucous fluids towards the antro-nasal foramen, or the ostium [17].

#### *Function:*

There have been many theories about the function of the paranasal sinuses. Some of the functions of maxillary sinus are: air humidification and heating; promote to weight lowering in the cranial bones of the skeleton, protection of the skull base against mechanical trauma, regulation of intranasal pressure, increasing surface area of olfaction, contribute to facial growth, shock absorbing in trauma and immunologic

defense, thermal isolation of some of the superior nerves, and influence in phonation [82, 83].

#### **1.3.4. Vascularization**

The maxillary blood supplies crucial for conserving the vitality of the region affected by any sinus lift surgery. It is also critical for the integration of any grafting material being used as well as for wound healing. In the atrophied edentulous maxilla, the overall vascularity diminishes as bone resorption increases [100].

The maxillary vascular complex is principally enormous, hence suitable blood is assured. This maxillary sinus blood flow is mediated through three branches of the maxillary artery: the infraorbital artery; the posterior lateral nasal artery (irrigates the medial wall); and the posterior superior alveolar artery (internal maxillary artery branch) [61, 64, 101, 102].

The blood supply of the maxillary sinus cavity reaches from the external carotid artery. It is provided predominantly by the posterior alveolar artery (PSAA) and infraorbital (IOA), originating from very close to the maxillary artery. These two arteries form an anastomosis inside the maxillary sinus that build up a double arterial arcade, supplying the lateral wall of the antrum and related parts of the alveolar process. The PSAA has been found to be in contact with the maxilla and its periosteum [103]. It divides into two arteries: (i) the gingival branch, supplying the oral mucous membrane in the premolar/molar area and (ii) the dental branch. The gingival branch and the dental branch of the PSAA are supplying the oral mucosa in the premolar/molar region.

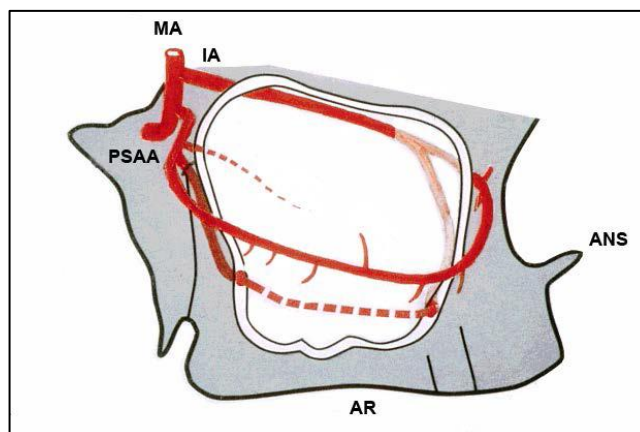
During sinus surgeries, the blood supply of graft material occurs by three following branches [100]:

The sphenopalatine and greater/lesser palatine arteries vascularize the sinus floor via penetration through the bony palate. The PSAA has tributaries that perfuse the posterior and lateral walls of the sinus. The PSAA and infraorbital artery

anastomose in the bony lateral wall, a mean of 16-19mm superior to the alveolar crest [100, 104]. The Schneiderian membrane also supplied by these arteries. The two anastomoses between these arteries form a double arterial arcade, supplying the lateral wall of the maxillary sinus cavity and related parts of the maxillary alveolar bone. The PSAA can be found wall of the sinus and parts of the alveolar process[103]. The PSAA found either within the bony wall (intraosseous) or medial or lateral to the wall (extraosseous). The average diameter of the PSAA has been found to 1.2-1.3mm with a range of 0.5-2.5mm [105, 106]. During sinus floor elevation procedure, the vascularization of bone graft material occurs through the three following branches [100](Figure 1.10.):

- Extraosseous Anastomosis (EA): gingival branch of the posterior superior alveolar artery (PSAA) with an extraosseous terminal branch of the infraorbital artery (IOA). It has a mean height of 23 to 26 mm from the alveolar margin. An extraosseous vestibular vascular anastomosis was detected in 44% of cases. These vessels may cause to hemorrhage during flap preparation and periosteum releasing incisions.
- Intraosseous anastomosis (IA) between the dental branch of the PSAA, also known as alveolar antral artery, and the infraorbital artery was found in 100% of cases. It is located at a distance of 18.9 to 19.6 mm from the alveolar crest of the maxilla. Such an anastomosis seemed to guarantee the blood supply to the sinus membrane, to the periosteal tissues, and especially to the lateral wall of the sinus.
- Branches of these vessels (PSAA, IOA, and IA) in the Schneiderian membrane.





**Figure 1.10.** Blood supply of the sinus cavity

It is clinically important for all oral surgeons to distinguish the exact localization of such anastomosis because its laceration during membrane elevation is rather frequent and can cause hemorrhage.

Severe hemorrhages during sinus lifting surgeries are rather unusual, as main arteries do not get involved inside the surgical area. Small vessels may be perforated during surgery. If these perforations are located in the exposed area of the Schneiderian membrane, hemostasis may occur naturally, probably through applying minor pressure with gauze [107]. These vessels supply both sinus membrane and periosteal tissues as the PSAA often has an extraosseous course. The majority of blood vessels in the maxillary sinus (70-100%) come from the periosteum [61, 107]. Healing and remodeling of the graft depends mainly on the blood supply from the maxillary sinus walls where new blood vessels are formed around the graft particles. It is also important to protect blood flow to other anatomical landmarks involved surgical procedure, such as the Schneiderian membrane and the mucoperiosteal buccal flap.

The maxillary sinus venous return occurs toward the pterygomaxillary plexus, along two paths: the facial and the maxillary vein to the internal jugular vein, or through the ophthalmic vein into the cavernous sinus [100, 107].

The reasons of marked reduction in vascularization of the bone are loss of maxillary teeth and aging. The correlation between the development of micro-vascular defects, bone atrophy and advancing age is detected [107].

Lymphatic drainage of the sinus is realized from the posterior region of the nasal cavity and nasopharynx to the retropharyngeal nodes and submaxillary glands. The healthy maxillary sinus needs postural drainage and action of the ciliated epithelial mucosa, which moves bacteria toward the ostium. It also produces mucus-containing lysozyme and immunoglobulins. Blood supply of the Schneiderian membrane maintains the body's defenses by providing access to lymphocytes and immunoglobulin from both the membrane and the sinus cavity [108].

The communication point from the nasal cavity to the maxillary sinus is not located in the inferior part of the sinus (where graft is placed) which is important in providing an anatomical foundation for sinus floor elevation. A sinus lift may even enhance symptoms of sinusitis and congestion since the lifted floor is relocated closer to the drain port [108].

The maxillary blood supply is crucial for the vitality of the region affected by any sinus lift surgery. It is also critical for the integration of any bone grafting material being used as well as for wound healing. In the atrophied edentulous maxilla, the overall vascularity decreases as bone resorption progresses [100].

### **1.3.5. Innervation**

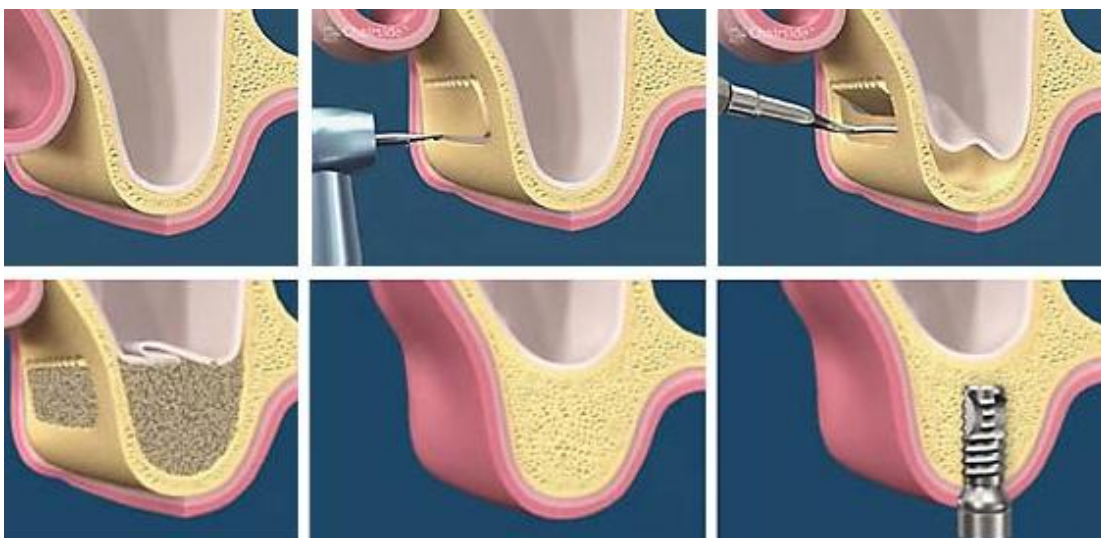
Innervation of the maxillary sinus occurs through the maxillary nerve, the second branch of the nervus trigeminal (5<sup>th</sup> cranial nerve). The maxillary nerve innervates posterior area of the sinus floor with its posterior middle and superior alveolar branches, as well the molar and premolar teeth. The anterior wall of sinus plexus is innervated by the anterior superior alveolar branch, a branch of the infraorbital nerve.

Some branches of the infraorbital nerve trunk innervate the medial wall of the maxillary sinus before leaving the infraorbital foramen. Other branches involving the sinus mucosa are branches of the pterygopalatine ganglion and the sphenopalatine ganglion, with the long and short sphenopalatine nerve [107].

#### **1.4. Sinus Lifting**

The maxillary atrophic posterior bone serves as an extra challenge for implant surgery not only by nature of the bone quality but also because of sinus pneumatization. Several treatment options have been utilized in the posterior maxilla due to treat insufficient bone quantity problems [109]. The most conservative option of these is the use of short implants to avoid implant placement into the sinus cavity. The required residual bone height for the short implants is at least 6mm [110]. Another way to avoid sinus augmentation procedure is to use tilted implants in a medial or distal position to the sinus cavity when adequate bone height exist [111].

Lateral sinus floor evaluation (LSFE) (Figure 1.11.), is one of the most common procedure for sinus augmentation whereby an osteotomy “window” technique in the lateral wall for access into the sinus cavity [112]. If residual bone height is less 4-5mm, one or two stage sinus lift procedure is recommended through lateral approach. The lateral window technique allows directing sinus cavity view, direct access for lifting the Schneiderian membrane and thoroughly augmentation of the cavity. However, disadvantages of this technique also have been documented, such as additional cost, and increased morbidity [113].



**Figure 1.11.** Lateral sinus floor elevation

The sinus floor graft procedure was introduced by Tatum in 1976 [114], modified by Boyne and James in 1980 [115], and further modified by Tatum in 1986[116]. The surgical technique as reported by Tatum in 1986 is generally used as present. According to this technique, access to the maxillary sinus is provided by a window osteotomy in the lateral maxillary sinus wall.

#### **1.4.1. Pre-surgical Evaluation**

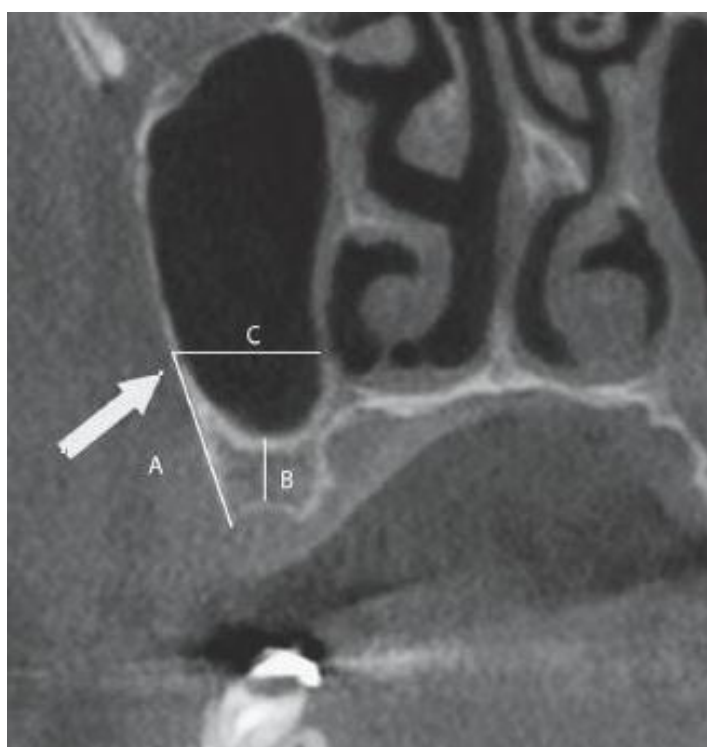A detailed examination of the patient, which includes a medical and dental history, should be attained prior to scheduling complicated surgical procedures such as the sinus floor elevation. The dental and periodontal status of the patient is assessed through the clinical and radiological examination methods. Upper facial, infraorbital, lateral nasal and labial regions must be examined for pain, swelling, or asymmetry. The findings of the clinical examination are reviewed with the medical and dental history of the patient due to obtain appropriate information for diagnosing acute, allergic and chronic sinusitis [108].

The investigation of choice for paranasal sinuses is CT scan. Contemporary multi slice CT scanner allow very thin axial plane slices to be obtained, from which reconstruction to sagittal and coronal planes can be made. The ostiomeatal complex, which contains maxillary sinus cavity too, is displayed by the coronal plane. The

axial plane helps identify the basal lamella of middle turbinate, which is the dividing point of anterior and posterior ethmoid sinuses.

Computed tomography not just provides objective information about the anatomy of the sinus cavity, it is also useful in planning effective strategies and is a reliable prognosticator of the sinus diseases (Figure 1.12.).

The EAO (European Academy of Osseointegration) held a consensus workshop on radiological guidelines in implant dentistry in 2011. Previous EAO guidelines from 2002 were updated and expanded to embrace cone beam computed tomography (CBCT) [93, 94]. CBCT can offer cross-sectional imaging and 3D reconstructions at potentially lower radiation doses compared to medical multi-slice CT. There is the risk of miscalculating the amount of available bone in the posterior maxilla for implant placement by using two-dimensional panoramic views. CBCT provides much more accurate measurements of the available bone volume [117, 118]. CBCT can also provide information about arterial channels in the lateral sinus wall, the presence of septa and other pathologies of the maxillary sinus [119].



**Figure 1.12.** Coronal CT slice of the paranasal sinuses

To avoid complications during a sinus lift procedure, rigorous pre-surgical examination of the maxillary sinus by means of cone beam computed tomography (CBCT) is recommended, as it has been shown to have higher sensitivity and specificity in the determining of septa than panoramic radiography [120]. Cone beam computed tomography (CBCT) imaging is often used to interpret sinus anatomy before the implant surgery. It can produce high resolution isotropic volumetric records with high geometric accuracy and at a low effective radiation dose [121, 122].

Panoramic radiography has been found to lead to wrong diagnosis about the presence or absence of sinus septa in 21% to 46.5% of cases [76, 79]. The use of CBCT imaging with high spatial resolution permits for the finding of septa with a frequency nearly as high as that found with clinical inspection [121].

Faintly radiopaque lesions arising at the floor of the maxillary sinus may present as obstacles during sinus lift procedure, and should be recognized to prevent further complications. According to Ziccardi and Betts, The presence of maxillary cysts is an absolute contraindication for sinus grafting [123, 124]. Three types of cystic lesions may be determined during a routine preoperative CBCT scan: pseudocysts, retention and mucoceles. Mucoceles, accumulations of mucous, are formed when the sinus ostium are obstructed [125]. As fluid pressure increases against the internal walls of the sinus cavity, excessive bone resorption may be obvious. This radiographic characteristic will differentiate a mucocele from a pseudocyst and retention cyst [126]. Pathological membrane thickening can also be detected through pretreatment cone-beam computed tomographic (CBCT) scanning. Mucosal thickening greater than 2 mm is considered a pathologic sinus membrane [119, 127, 128]. In a recent retrospective study of CBCT scans of 500 patients, Yildirim et al. found that the mucosal thickening could be visualized in 42.8% of sinuses [129].

Following a sinus lift procedure, CBCT is a best method of determining how the bone substitute is positioned in relation to the adjacent bone of the maxillary sinus<sup>48</sup>. In conclusion, CBCT images can be valuable to the clinician in both

diagnosing and treatment planning in that they improve the accuracy of diagnostic consequences and help in the design of an adequate treatment plan [70, 130]. According to the fact that the prevalence of sinus septa is fairly high, and both the success of the sinus lift procedure as well as the accruing of complications are correlated to their presence, CBCT imaging is highly recommended as part of the principle, however, that radiation doses are As Low As Reasonably Achievable (ALARA) [131]. The ALARA concept further modified by Prashant et al in 2015 as a ALADA (As Low As Diagnostically Acceptable) [132]. This new concept further highlights the critical balance between clinical value and safety, which is an effort that was less explicit and more vaguely portrayed by the former ALARA acronym. Implementing this concept of ALADA would require the strict regulation of guidelines on CBCT referrals followed by an evidence-based assessment of image quality for specific diagnostic tasks with exposure and doses associated with a given level of image quality.

The residual bone height directly affects the possibility of achieving primary implant stability and will dictate whether a one- or two- stage technique can be used [32, 133]. In indirect approach, which is considered a one-staged technique, a minimum cut off of 5 to 6mm residual ridge height has been proposed as requirement [32, 134-137]. Evidence however does also support cut offs of 1.4 to 4mm [20, 53, 133, 138-141]. Thus, overall, the decision to proceed with a one-stage technique ultimately rests with the surgeon, their experience, and the minimum residual ridge height they are comfortable with [138].

#### **1.4.2. Grafts**

There are different concepts on the obligation of grafting material when performing a sinus lifting surgery, either by a direct or indirect approach. These differences are supported by the large body of studies, which comprise success and survival rate of implants placed with and without grafting material. Generally, the changeover from autogenous bone graft to bone replacement grafts as a donor substitute has been one of the major tendencies in direct sinus lift surgery. The use of biomimetic improvement factors, used in combination with bone replacement grafts,

is also gaining momentum in sinus surgeries. Success of the graft procedure is measured as it relates to implant placement, and thus secondary outcome measures including the percentage of histologic new vital bone formation as well as clinical implant survival rates are used [141-143]. Not just the type of bone graft, but also its particle size, if a particulate graft is preferred, will affect the quality of new organized bone, the speed of osseous turnover, and the final bone density. The clinician's timeline of implant placement is defined because of these factors. Xenografts establish a large fraction of bone substitutes in the comparison with autogenous graft. The success of the xenografts based on its osteoconductive feature with the formation of approximately 25% vital bone by volume at 6 to 8 months. Additionally, xenograft does not appear to resorb with time, which results in the addition of approximately 25% of mineral content, although this residual graft material is non-vital. Finally, histologic evaluation has discovered that the residual graft substitute is never seen in direct contact with the implant surface, and therefore it does not appear to interfere with osseointegration. Instead, the residual graft particles are interconnected by sections of new vital bone, a process that has been termed "bone bridging" [141]. Thus, xenograft may be considered the gold standard non-autogenous sinus grafting material.

### **1.4.3. Sinus Lift Techniques**

The lateral window technique was modified Caldwell-Luc procedure involves exposure of the lateral sinus wall. Surgical access to the sinus cavity may be achieved in two different methods. The most popular method is "trap-door technique", involves an in fracturing of the lateral sinus wall like a trap-door and using this bone as the superior border of the sinus compartment while leaving it attached to the underlying Schneiderian membrane. The less-popular technique involves preparing an access hole by removing the entire lateral plate prior the membrane elevation [32].

The maxillary sinus surgery by the lateral approach is mainly indicated in case of reduced residual bone height, when implant placement using the osteotomy technique is not promising.



The following are some of the indications for the use bone grafting in the sinus cavity:

1. Insufficient vertical bone height (<5mm) due to implant placement.
  - Sinus pneumatization
  - Alveolar ridge resorption
  - Combination of the above
2. Oroantral fistula repair
3. Alveolar cleft reconstruction
4. Le-fort 1 with graft reconstruction
5. Cancer with reconstruction of craniofacial prostheses

Guidelines to sinus grafting may also include the following:

1. Residual alveolar bone height (<10mm)
2. At least 4mm width of residual bone
3. No history of sinus pathology
4. No significant history of sinus disease
5. No anatomical limitations due to anatomical structures or scars after previous surgery

Contraindications:

Contraindications for maxillary sinus augmentation include:

- General Medical contraindications:

1. Radiation treatment to the jaw region
  2. Septicemia
  3. Serious medical fragility
  4. Uncontrolled systemic disease
  5. Excessive smoking
  6. Excessive alveolar or substance abuse
  7. Psychophobias
- Local factors that may contraindicate subantral augmentation include:
    1. Sinus infections
    2. Chronic sinusitis
    3. Alveolar ablation due to scar
    4. Odontogenic infections
    5. Inflammatory lesions or pathological
    6. Severe allergic rhinitis

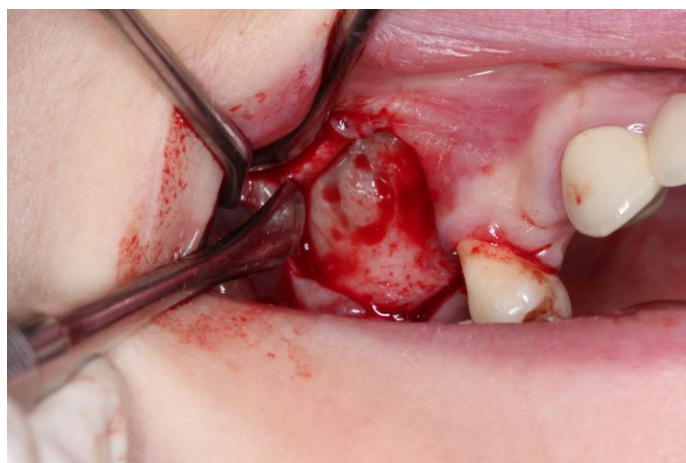#### **1.4.4. Surgical Technique**

Tatum, Boyne & James et al., and Wood & Moore were the first authors to describe an augmentation technique for the floor of the maxillary sinus [114-116, 144]. This technique comprised the creation of an access to the maxillary sinus via a window through the lateral bone wall. A mucoperiosteal trapezoidal flap is raised after a midcrestal horizontal incision along the horizontal portion of the palatal vault, and an anterior and a posterior vertical releasing incision. The anterior incision is made next to the last tooth in the area, while the posterior incision is made in the posterior part of the infrazygomatic crest. The exact location depends on the extent

of implant insertion surgery and related bone augmentation. The mucoperiosteal flap is elevated so as to expose the lateral bone aspect of the maxillary sinus.

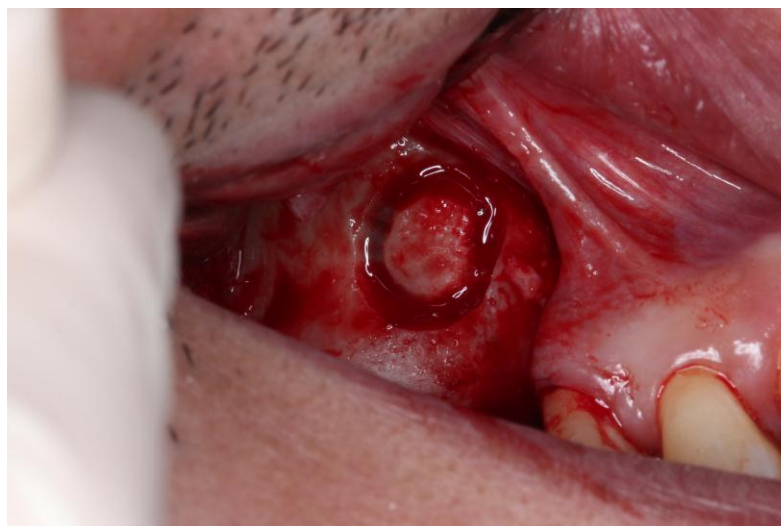The surgical technique is performed as following details:

- Local anesthesia of the buccal and palatal surgical sites
- The initial incision (midcrestal) is extended well beyond the planned expansion of the osteotomy. The incision is performed to a position beyond the leading edge of the maxillary sinus and is made above and extended into the vestibule to facilitate mucoperiosteal flap elevation (Figure 1.13.).



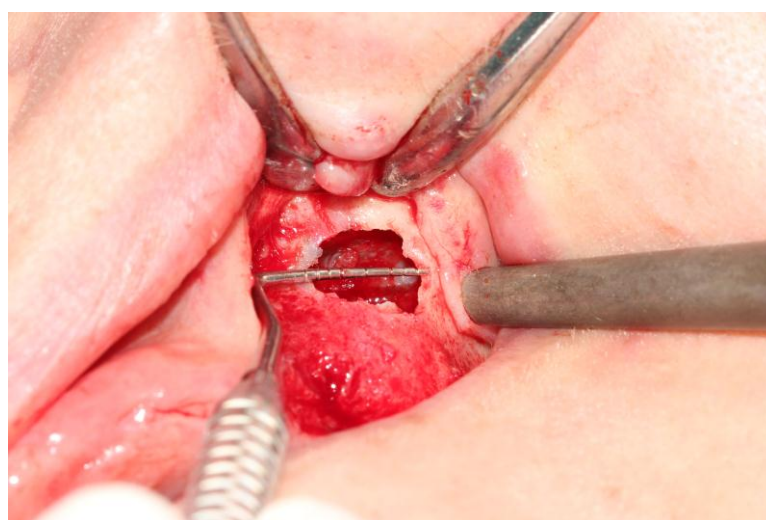
**Figure 1.13.** Mucoperiosteal flap elevation

- The mucoperiosteal trapezoidal flap is elevated slightly to the expected height of the window
- After exposing the sinus side wall bone, a medium sized round diamond bur is used with abundant irrigation to mark outline of the osteotomy. The holes are then connected to complete the outlining of the bone window (Figure 1.14.). The preparation is continued with piezotome after the bone has been reduced to a thin bone plate, until a bluish hue of the sinus membrane is observed.



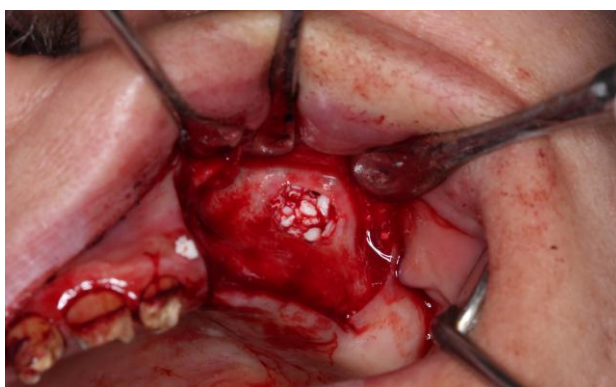**Figure 1.14.** Lateral bone window

- The next step is the sinus membrane dissection. If the buccal wall is removed, the sinus membrane is elevated directly with blunt instruments (Figure 1.16.). The membrane elevation provides adequate space for the graft material placement. The sinus membrane should be carefully and completely elevated to avoid perforations. Depending on the clinical condition and the surgeon's preference, the clinician can use a delayed technique (in second subsequent stage with the implants are placed), or simultaneous placement of the implant.

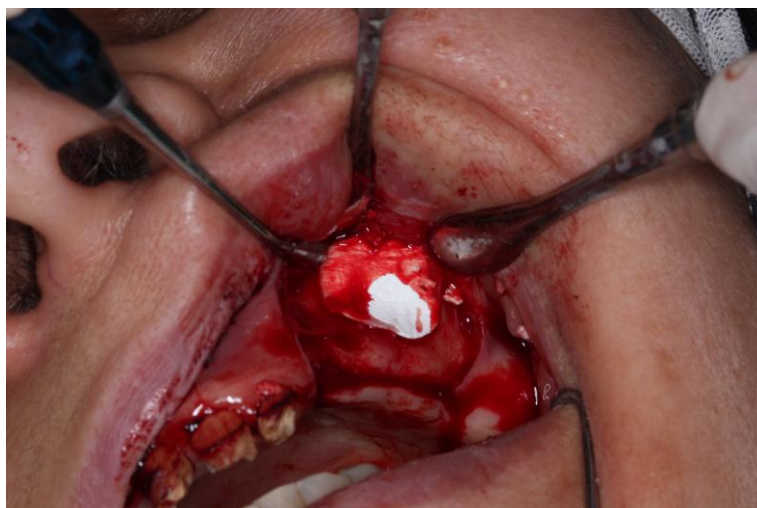

**Figure 1.15.** The appearance of the elevated sinus membrane

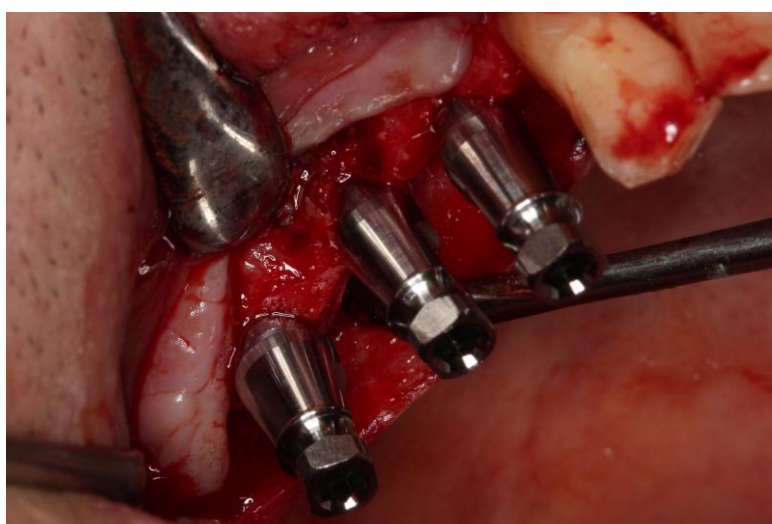
When indicated, the creation of a large bone window permits the exposure and elevation of the sinus membrane from all sinus bony walls including the posterior wall. When implant placement is planned in the canine and premolar regions, minimal buccal-palatal dimension can sometimes shrink access such that the implant is inclined far too palatal. A large window improves access and allows just enough fracture of the lateral wall of the nasal cavity such that it can be pushed inward in order to create space for appropriate implant angulation [140]. Bony plate is either removed before the membrane elevation, or in-fractured to be used as the superior border of the sinus compartment. If removed, the schneiderian membrane is elevated directly with blunt instruments. The shapes of the instruments available during the procedure play a role in the need to remove parts of the septa to facilitate membrane elevation. Membrane integrity is critical in the containment of the bone graft and it can be diagnosed either using the Valsalva maneuver, or by cautious checkup that the bony window or membrane moves along with respiratory rhythm. If a two-stage sinus elevation is preferred, bone substitute is placed into the newly made compartment of the cavity (Figure 1.17.). The lateral window is then covered with a resorbable or non-resorbable barrier membrane and the flap is closed (Figure 1.18.). If a one-stage sinus elevation is chosen, the implant sockets are drilled after sinus membrane elevation. Grafting material is placed into the medial aspect of the sinus compartment before the implant placement (Figure 1.19.). After the placement of the implants, the lateral part of the compartment is also filled with grafting material.



**Figure 1.16.** Grafted sinus cavity



**Figure 1.17.** Covering lateral window with resorbable collagen membrane



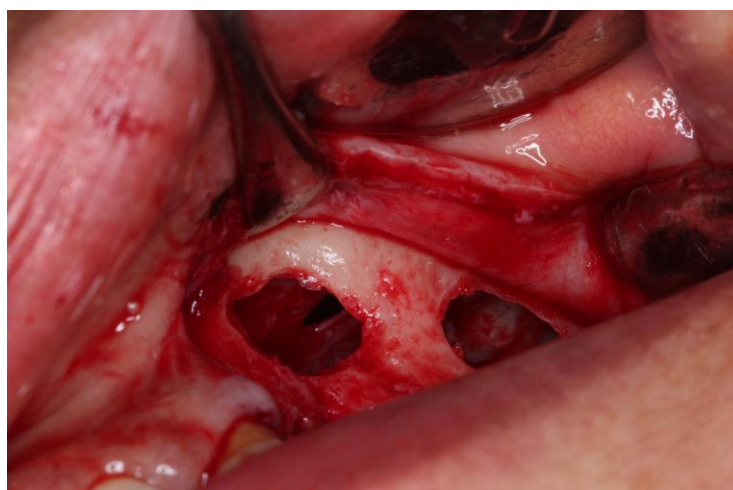
**Figure 1.18.** Inserted implants

After surgery, condition of maxillary sinus was radiologically scanned for any radiologically noticeable abnormalities: mucosal thickening (mm), type of mucosal thickening (no thickening, basal, circular, cystic, total shadowing), obstruction of physiological opening (yes/no), additional opening (yes/no), pneumatized middle turbinate of the nasal cavity – *concha bullosa* – yes/no. Volume of maxillary sinus (mm<sup>3</sup>) was also measured after surgery.

#### **1.4.5. Complications**

Complications encountered during and after sinus lift procedure include membrane perforation, bleeding, sinusitis, cyst discovery, sinus cavity obliteration,

implant dislodgement, and sequestration and infection of bone graft material [126]. The most common complication that is encountered during sinus lift surgery is schneiderian membrane perforation (Fig. 21). Although advanced 3-dimensional imaging methods are available in recognizing sinus septa, and despite the fact that considerable research has been undertaken in improving the surgical technique, membrane perforations still occur, even in the hands of the experienced surgeon. The main reasons of perforations are improper rotary instrumentation and sinus membrane elevators practice. Literature reviews show that the percentages of described perforations range from 11% to 44% and higher percentages with sinuses, with thin membranes, and with the existence of septa. Any tear in the sinus membrane will result in a direct communication between the bone graft material and the contaminated sinus cavity [126]. Particularly in the case when bone graft material is placed during the perforation without any membrane reduces the guarantee of initial graft stability. This initial stability is essential in encouraging vascularization such that the graft can mature and mineralize [145]. Additional results of the exposed graft to the sinus cavity are infection, chronic sinusitis, and the eventual loss of graft volume [126].



**Figure 1.19.** Sinus membrane perforation

The possibility of membrane perforation can be diminished by planning a direct approach by means of lateral access. The risk is not so much in cases with an increased residual ridge height. Nevertheless, even with careful preparation and reflection, mobilization of the membrane along anatomical anomalies cannot always

avoid a membrane tearing [121]. Aimetti et al [18] attained Schneiderian membrane biopsy specimens and compared their thickness to the maxillary gingival thickness. According to that study, increased gingival thickness could be used as a reliable prediction for increased sinus membrane thickness. The frequency of reported membrane perforations during direct sinus lift surgery has ranged from zero to 57.5% [146]. However, the incidence of reported perforations during indirect sinus lift surgery has ranged from zero to 21.4%.

A diversity of methods have been described in the literature to manage sinus membrane perforations, including suturing, covering with the collagen membranes, fibrin sealants, freeze-dried human lamellar bone sheets, and oxidized regenerated cellulose. Repair has been applied to the cases with perforations ranging in size from two to 15mm.

The ostium, situated 25 to 35mm superior to the maxillary sinus floor, can potentially be obliterated, or blocked, if the sinus cavity is overfilled with bone graft material during sinus surgeries. In this situations, patency is lost such that drainage into the nasal cavity ceases [126]. Therefore, in order to evade a reentry surgery to eliminate the excess bone graft, before the first sinus surgery measurements should be taken such that the final graft height does not exceed the height of the ostium. Paresthesia and vertigo are also rare complications of the sinus surgeries.

Maxillary sinusitis after this procedure was considered to be the major drawback, although many results were based on unclear criteria for examination and diagnosis of maxillary sinusitis [147]. When using general accepted Ear Nose and Throat (ENT) criteria for diagnosing sinusitis, however, development of post-elevation chronic maxillary sinusitis has been reported to occur in 1.3% of the patients that underwent such a procedure [148].

Although not many patients develop maxillary sinus pathology-related complaints after sinus floor elevation surgery, this procedure carries the inherent risk of compromising sinus physiology. It is generally assumed that the maxillary sinus physiology is affected by the altered anatomy (i.e. the lifted sinus floor in



combination with a bulging or injured subsurface of the lifted sinus mucosa). Mucosal swelling may also lead to reduction of the patency of the ostio-meatal unit. This unit plays a key role in the development of sinusitis, through impairment of the mucociliar cleansing system [149]. If the maxillary sinus is (partly) filled up by hematoma or seroma and/or the patency of the maxillary ostium is reduced, maxillary sinusitis might develop, compromising the success of the grafting procedure.

#### **1.4.6. Implant Survival in the Augmented Sinus**

The criteria for the evaluation of dental implant success as part of an assessment of the long-term efficacy of dental implants is suggested by Albrektsson (1986) which is in popular use at that time [150]. By this time, the Branemark titanium implant had already been the subject of more than 100 published papers, and more than 15,000 of these implants had been applied globally. Criteria for implant success comprise:

- 1) That an individual unattached implant be immobile when tested clinically,
- 2) There is no evidence of peri- implant radiolucency in radiography,
- 3) Vertical bone loss is not more than 0.2mm annually after the implant's first year of service,
- 4) That an individual implant's performance be characterized by the absence of persistent or irreversible signs and symptoms of pain, infection, neuropathy, paresthesia, or damage of the mandibular canal, and
- 5) The criteria for minimum success rate is 85% at the end of a 5-year observation period, and and 80% at the end of a 10-year period.

Albrektsson Et al (2012) published a report on a consensus meeting targeted to evaluate whether the high rates of peri- implantitis related with machined surface

implants reported in the literature to date are also valid for modern rough- surface implants [151].

The conclusion was that poor, undocumented new implant systems, poorly trained surgeons, and patients with drug abuse or exposed to irradiation or grafting were accountable for the most of marginal bone resorption and implant failure. If authenticated implant systems are used by correctly trained clinicians who work with ordinary patients, then the overall failure rate and frequency of peri- implantitis are within 5% of all implants that have 10 Years of documented follow up. When interpreting studies reporting marginal bone loss a cluster influence can be detected such that one and the same patient with marginal bone loss around one implant is likely to have problems around their other implants as well.

Supportive arguments to both an one- stage and two- stage surgery exist in the literature. From a biological standpoint, the two-stage procedure permits for graft maturation and integration prior to implant placement. Thus, the insertion torque during the one-stage implant placement is likely to be higher than with a two-stage procedure. In addition, the risk of implant relocation or dislodgement is reduced. One- stage surgery, however, is less invasive, requiring only single surgery. It is not just more cost-effective also shortens the total treatment time [152]. The more experienced clinicians are now using one- stage technique commonly than before [138]. As Stated previously, the amount of residual bone is a deciding factor in choosing the appropriate technique. Implant survival rates in the grafted sinus was evaluated by Del Fabbro Et al (2008) from different point of views; implant surface, graft material, and implant placement timing [112]. It was found that the implant survival rate was not dependent on the use of either an one- or a two- stage procedure. The conclusion of Wallace Et al (2012) was that both techniques have similar survival rates assuming primary stability is attained at placement and maintained during the early graft maturation period [141].

Overall, Implant placement to the posterior region of the maxilla can be considered a safe and predictable therapy, provided that fair consideration is given to the perfect prosthetic location of the implants as well as the need for vertical ridge

augmentation, implant failure possibilities are taken into account, rough surface implants are applied, and more experienced surgeon and restorative dentist are in charge. Implant Survival rates in the augmented sinus compare favorably to reported survival rates for implants placed in the non-grafted posterior maxilla<sup>61</sup>. The approximate yearly implant failure rate for implants inserted with one-stage technique is 3.5%, leading to a 3-year implant survival of 90.1%. The failure rate of the implants is usually highest during the first year after the placement [32]. The prosthetic stage of implant therapy in the posterior maxilla should also be taken into account. After a minimum 12 months follow up period, the survival rates of different type of prosthetic treatment options (single crowns, splinted crowns, and fixed partial dentures) have ranged between 96.4% and 100%. Therefore, the prognosis of implant therapy does not seem to be affected by the type of the applied restoration. To date there is a deficiency of controlled trials using split mouth designs, which compare the outcomes of implant therapy with single versus splinted crowns.

## **2. MATERIALS AND METHODS**

### **2.1. Objectives**

The overall aim of the present thesis were to evaluate the augmented bone volume and total volume of the maxillary sinus, correlation between the thickness of the Schneiderian membrane and crestal gingival thickness, following sinus lift procedures.

Specific aims:

- To prospectively evaluate the correlation between the thickness of the Schneiderian membrane and crestal gingival thickness, using pre-op and post-op CBCT in patients referred for dental implant placement in the posterior maxilla.
- To prospectively measure, the augmented bone volume and total volume of the maxillary sinus using pre-op and post-op CBCT scans and to calculate the required safe graft volume.
- Evaluation of healing of the lateral bone in the window region
- Effect of maxillary sinus augmentation on sinus membrane thickness
- Three-dimensional evaluation of the sinus anatomy and physiology after sinus surgery
- To evaluate the difference between manually and automatically measurements of the sinus cavity volume.

### **2.2. Study Design and Study Groups**

The study included 21 patients/ 36 maxillary sinuses. During the period from 2010 to 2016 the above patients had undergone CBCT investigations before maxillary sinus lift (MSL) using biomaterials at the Department of Periodontology of the Hacettepe University. Fourteen patients (63.6%) had undergone bilateral maxillary sinus lift surgery. Maxillary sinus lift surgeries were carried out at the

Clinic of Periodontology of the Hacettepe University. In all sites, preoperative bone height was lower than 5mm and a staged surgical approach was necessary. Thirty six (36) maxillary sinuses which had undergone maxillary sinus lifting surgeries with the application of bone substitute biomaterials were defined as research subjects. Bovine derived xenograft was used to fill the antrum. The study did not address patient's general health condition at the time of examination and surgery, as well as the elapsed time between tooth loss and MSL and the smoking factor. Radiological investigation for pre-surgical planning and post-surgical evaluation purposes was performed using CBCT device I-CAT Next Generation, Imaging Science, USA.

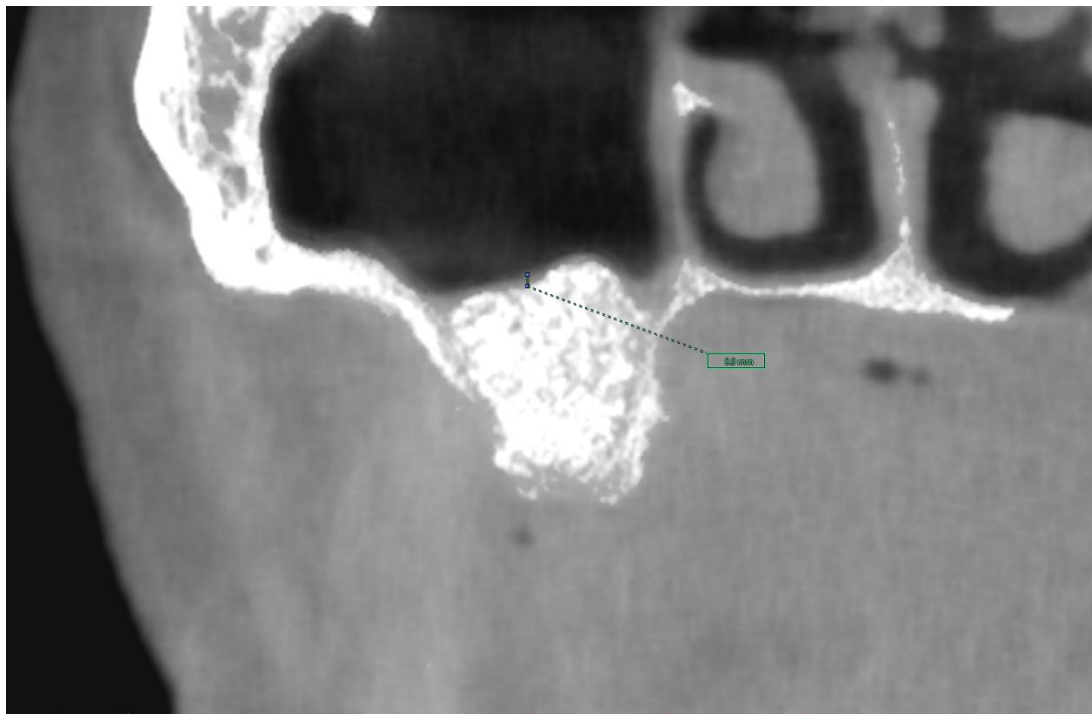
All patients were investigated following a unified protocol. Patient's jaws were scanned with the following parameters: diameter – 16 cm, height – 13 cm, scanning time – 8 to 9 seconds, power – 120 kV, 5 mA. Images were obtained using 0.3 voxel (three-dimensional image volume unit) size. Images were processed and reconstructed by 3D Synapse Software (Fujifilm, Tokyo, Japan), software.

Before taking measurements, an image was positioned so that the plane of the hard palate is parallel to the floor, while the sagittal plane is perpendicular to the floor. In pre-surgical examinations, the measurements were taken in coronal section, where physiological opening of the maxillary sinus is visible. The following linear measurements were taken: pre-surgical measurements of height and width of the alveolar bone. Measurements were recorded in millimeters (mm).

Condition of maxillary sinus was radiologically investigated, determining whether any of the following pathologies are radiologically detectable: sinus membrane thickening (mm), functionality of physiological opening (functional/obstruction). The ostium patency could be evaluated in the coronal section of each sinus and was classified as “patent” or “obstructed” (Shanbhag et al. 2014).

Anatomical landmarks and the position of the lateral window were used to properly position the CBCT slice. Membrane thickness measurements were conducted in the sagittal and in the cross-sectional images (Figure 2.1.) and were

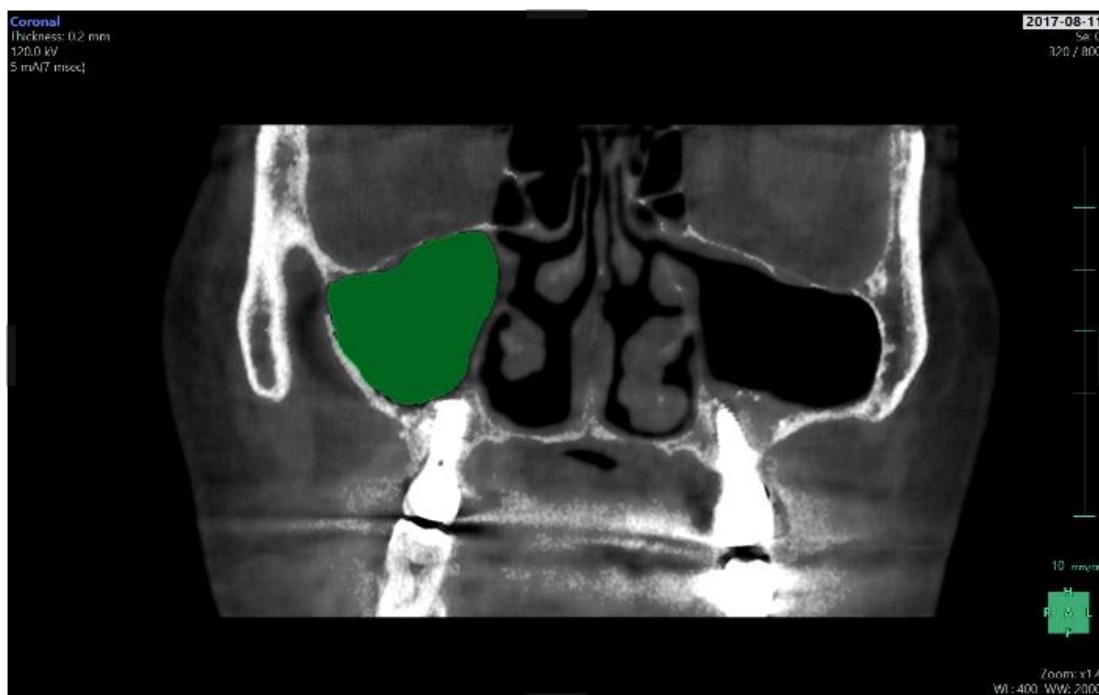
conducted by a built-in digital caliper in millimeters perpendicularly from the underlying bone plate of the sinus to the mucosal surface.



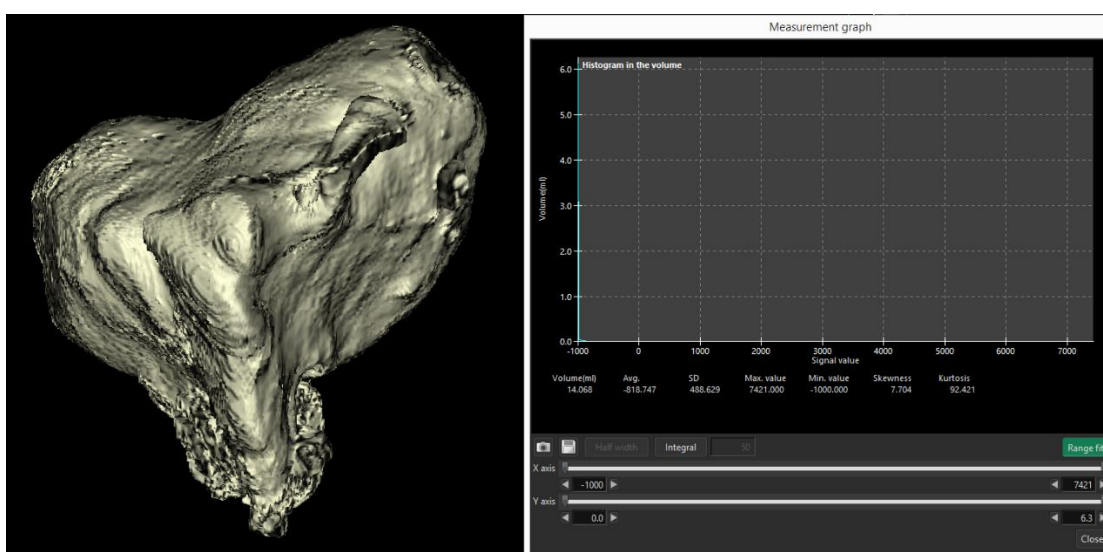
**Figure 2.1.** Thickness measurement of the Schneiderian membrane

Total volume of maxillary sinus (mm<sup>3</sup>) (Figure 2.2., and 2.3.), and grafted part volume of sinus were also measured before surgery. Sinus volume was measured using 3D Synapse Software (Fujifilm, Tokyo, Japan) software.

Post-surgical radiological investigations were positioned analogous to those performed before surgery. The selection criteria were met only by those patients who underwent the second, repeated radiological investigation at least a week after the surgery. All second radiographs were taken because of different diagnostic purposes other than the sinus regions. Statistical processing of the data was performed using Graphpad Prism v 7.0 and Microsoft Office Excel v.11 software.



**Figure 2.2.** Total sinus volume measurement



**Figure 2.3.** Visual construction of the evaluated sinus cavity

Patient parameters were described by conventional methods of descriptive statistics – summary tables with columns, bar graphs or histograms.

Significance of the test results was evaluated with a 5% statistical probability of errors, therefore, if a p-value was found to be less than 0.05, then test results were found statistically significant.

Difference was assessed by applying several statistical tests – when the proportional data were subjected to normal distribution, then analysis of variance (ANOVA) was used for analysis of quantitative differences between two or more groups, while Student's t-test was used for analysis of differences between two groups.



### 3. RESULTS

Summarization of demographic data led to the conclusion that out of 36 maxillary sinuses included in the study 22 (61.1%) was female sinus and 14 (38.9%) were male sinuses.

At the time of maxillary sinus lift surgery, the mean age of patients was 50.88 SD  $\pm$  9.82 years. The lowest age was 31, but the oldest patient who was included in the study, was 66 years of age at the time of surgery. Mean age of females who were included in the study was 49.39 SD  $\pm$  10.16, while the mean age of males was 53.70 SD  $\pm$  8.63.

Selection criterion for inclusion of patients in the study was repeated control CBCT imaging at least one week after MSL with application of bone substitute biomaterials. The longest time recorded from post-surgery until CBCT re-examination was 5 years. The average time from post-surgery until CBCT re-examination was 2.06  $\pm$  SD 0.749 years.

In pre-surgical CBCT imaging, the mean gingival thickness was determined in mm and it was 1.09 SD  $\pm$  0.94 mm. Gingival thickness in the area of the maxillary posterior teeth increased slightly after surgery but this change was statistically insignificant (P=0.95).

A total of 36 measurements (Table 2) were performed in total, and the overall residual bone thickness was 3.14 mm ( $\pm$ 2.38mm).

Schneiderian membrane thickness ranged from 0.7 mm to 3.2 mm in pre-op CBCT scans (Table 1). The mean thickness was 1.62 $\pm$ 1.04 mm. Post-op CBCT scan measurements of the sinus membrane thickness showed no statistically different values from pre-op values (P=0.64).

**Table 3.1.** Schneiderian membrane thickness.

	Right (M, SD) mm	Left (M, SD) mm	Total (M, SD) mm
Pre-op	1.39 (0.87)	1.77 (1.94)	1.62 (1.04)
Post-op	1.79 (0.47)	1.76 (0.88)	1.77 (0.72)
---	---	---	P value = 0.64

The buccal bony wall thickness of the maxillary sinus cavity was 1.76 ( $\pm 0.55$ ) in pre-op CBCT scans. Although the difference between preop and postop values were statistically insignificant, there was slightly increase after surgery (P=0.28).

All ostiums were detected and almost all of them maintained their openness after sinus lifting surgery. Obstruction of the sinus ostium was observed just in one sinus (2.7%).

**Table 3.2.** Measurements before and after sinus lifting surgery.

Parameters	Pre-op (M, SD) mm	Post-op (M,SD) mm	P value
Gingival thickness	1.09 ( $\pm 0.94$ )	1.29 ( $\pm 0.47$ )	0.95 (NS)
Residual bone height	3.14 ( $\pm 2.38$ )	---	---
Graft height	---	11.36 ( $\pm 2.78$ )	---
Buccal bone thickness	1.76 ( $\pm 0.55$ )	2.62 ( $\pm 3.21$ )	0.28 (NS)

Mean values and standard deviations of the volumes for the maxillary sinus and for grafts are shown in Table 2. All volumetric assessments were performed not just automatically, but also manually using 3D Synapse Software (Fujifilm, Tokyo, Japan). There were small differences between manually and automatically measurements which were also statistically insignificant. The total maxillary sinus volume (mean  $\pm$  SD) measured manually on CT images was  $14.87 \pm 7.71$  cm<sup>3</sup>. The minimum maxillary sinus volume was 10.91 cm<sup>3</sup> and the maximum was 22.03 cm<sup>3</sup>. Grafted part volume of the sinus cavity was assessed in each CBCT scan ( $2.25 \pm 1.24$  mm<sup>3</sup>)

Statistical comparisons between groups showed no statistical differences for any of the variables considered (Volume, Density, and percentage of residual bone) different follow-up times.

The overall average graft volume obtained after the surgery was 2.25 cm<sup>3</sup> ( $\pm 1.24$  cm<sup>3</sup>). The occupied space of the sinus cavity by graft biomaterials was calculated (%), as shown in Table 3.

The average percentage of the grafted part was 14.87 % through manual measurements and 14.66 % through automatically measurements.

**Table 3.3.** Volumetric measurements of the sinus cavity.

	Total volume (M, SD) mm	Graft volume (M, SD) mm	Percentage (%)
Right side manually	15.37 ( $\pm 3.05$ )	2.21 ( $\pm 1.18$ )	14.97 ( $\pm 8.23$ )
Left side manually	15.9 ( $\pm 3.08$ )	2.3 ( $\pm 1.03$ )	15.72 ( $\pm 7.25$ )
Manually both	15.35 ( $\pm 2.9$ )	2.25 ( $\pm 1.24$ )	14.87 ( $\pm 7.71$ )
Right side automatically	15.19 ( $\pm 3.08$ )	2.3 ( $\pm 1.03$ )	15.71 ( $\pm 7.25$ )
Left side automatically	14.98 ( $\pm 2.87$ )	2.2 ( $\pm 1.32$ )	13.97 ( $\pm 8.13$ )
Automatically both	15.1 ( $\pm 2.9$ )	2.24 ( $\pm 1.2$ )	14.66 ( $\pm 7.73$ )

#### 4. DISCUSSION

The total volume of the maxillary sinus has previously been measured in human cadavers, with measurements obtained by injecting dental impression material into the maxillary sinus of the specimens [153, 154].

Ariji et al evaluated maxillary sinus volume in living subjects using a computed tomography (CT) scan. In their study, no significant differences were observed in maxillary sinus volume depending on the side or sex [155]. According to these researchers, the only important parameter was age; maxillary sinus volume tends to decrease after the age of 20 years [155]. However, no strong negative correlation was found between maxillary sinus volume and age, with a correlation coefficient of  $y = -0.43$  from their data [155]. As reported by Schaeffer, adult maxillary sinus size was related to the side, sex, and age, but the differences were not statistically significant [153].

The CBCT images used for measurements in the present study included the maxillary sinus and were obtained for the evaluation of patients with other medical conditions in whom no abnormalities of the maxillary sinus were detected. 3D Synapse Software (Fujifilm, Tokyo, Japan), was developed as preoperative planning software that combined the accuracy of CBCT imaging with the power of computer aided design. Maxillary sinus volume measurement is possible using this software. The existing system does not depend on the CBCT data format; therefore, 3-dimensional reconstruction and measurement of CT data in various formats are possible.

To the best our knowledge, this is the first study to evaluate the total sinus volume using CBCT images. Total sinus volume after was around 11.3 cm<sup>3</sup> when assessed volumetrically in cadaver studies [153, 154]. However, the present study shows different volume numbers of total sinus cavity.

The differences in volumetric reduction rates may be explained by some patient depended factors: number of missing teeth, anatomy of the maxillary sinus, repneumatisation capacity of the patient [156, 157].

CT is an excellent technique to delineate the osseous structures and offers a reliable technique for 3D visualization of the grafted part of the sinus cavity [157]. Difficulties in assessing the resorption rate of the grafted material by conventional X-ray techniques as well as magnification errors are reported by Diserens et al., Bolin et al. and Gray et al [158-160]. Panoramic radiographs display only 2D changes and hence do not suffice to evaluate volumetric changes in bone grafts [161-163]. The segmenting method was demonstrated to be accurate in phantom tests using CT images of either water-filled syringes or plaster of Paris simulating bone grafts in the edentulous maxilla [164, 165]. The reported accuracy ranges from 84% to more than 95%. Several studies evaluated the 3D volume of bone grafts in the maxillary sinus using CT scans [160, 164-169]. To our best knowledge, no information can be found in literature on the grafted percentage of the grafted area of sinus cavity.

Graft volumes after LSE seems to be around 2,25 cm<sup>3</sup> when assessed volumetrically. However, a study by Mazzocco and co-workers was only able to obtain an mean graft volume of 1,43cm<sup>3</sup> when performing a ISFE [170]. In living subjects, Dellavia et al have reported grafted sinus volume measured on CBCT images which was 2.6 mc<sup>3</sup> after surgery [170]. Their method was similar to that used in the present study.

Several investigators have previously reported on the donor site, graft bone volume, and implant length in conjunction with bone grafting in the maxillary sinus floor [166, 171]. The graft bone volume in these studies ranged from two cm<sup>3</sup> to 15 cm<sup>3</sup>.

This study is the first study reported in the literature investigating the safe volume of the sinus cavity for grafting. The results this retrospective study show that approximately 14.87% of the sinus cavity is occupying by graft materials after LSE procedure.

Furthermore, for the success of the sinus augmentation procedure, it is important not only to consider the volume and the behavior of the graft, but also to include the residual crestal bone as part of the entire tissue that will be remodeled and will host the implants. The method proposed here includes in the computation not only the grafted material but also the native bone of the alveolar crest, thus considering the actual tissue where the implant is usually inserted.

Schneiderian membrane thickness (SMT) is not a frequent data reported in the literature. In addition, there is a big variation in terms of membrane thickness due to various techniques that have been used to record the amount [172-175].

Although there is no precise threshold to define normal radiographic mucosal thickness, 2 mm has been selected in many studies [176, 177]. According to Janner et al., the thickness of the Schneiderian membrane exhibited a wide range (0.16–34.14 mm) with interindividual variability [177]. In the present study, the mean thickness of preoperative membrane region was higher than that in research of Pommer et al., the authors reported an average thickness of 0.8 mm for the membrane of the maxillary sinus, which may be due to the large proportion of patients in our study had a history of periodontitis before SFE [175]. It has also been shown that a thicker Schneiderian membrane is more likely to be present in patients with periodontitis or extractions due to periodontal causes [173, 178].

To the best of our knowledge, only four histological studies have been published so far. For example, Tos & Mogensen reported 0.3 and 0.8 mm mean membrane thickness from 10 unfixed cadavers [179]. Pommer et al. recorded 0.09 mm (range 0.024–0.35 mm) mean membrane thickness and also discussed the mechanical properties of the Schneiderian membrane [175].

The transient swelling of the Schneiderian membrane has already been described by Quirynen and coworkers [180]. In this study, 2D measurements were made on CBCT images and the authors concluded that a tSFA technique results in transient swelling of the membrane, 5-10 times its original thickness. After a healing

period of 6 months, the thickness of the membrane normalized to its original thickness, leaving no post-operative complication for the patients.

Recently, CBCT was used in the determination of the SMT: Janner et al. found out values of 0.9 and 1.84 mm in the lateral and medial aspects of the wall, respectively, and 2.16–3.11 mm in the mid-sagittal areas [177]. This is similar to our data where we observed a thinner SMT in mid-sagittal position (1.62 mm).

The difference probably is due to CBCT inability to differentiate between liquid and soft tissue. This inability makes clinician unable to properly differentiate between real membrane thickness and mucous accumulation [181].

Zheng-Ze Guo et al. showed that no difference in MT between the preoperative scans and the ones performed after a healing of 7.5 months although it experiences a transient swelling [182]. The same result was observed by Anduze-Acher et al., the author indicated no significant changes in MT after 8.9 months of healing [183]. This observation confirms mucociliary function could recover from SFE and corresponds to that reported by Timmenga et al. who suggested that SFE via a lateral approach had no impact on the natural sinus physiology based on a clinical, morphological, and microbiological evaluation [184].

The transient swelling is also found in transalveolar approach. This swelling may result from the surgical trauma exerting on the sinus membrane, and subsequently, this swelling might disturbs mucociliary clearance. Carmeli et al. analyzed 280 computed tomography scans and observed that sinus outflow patency was associated with mucosal thickening and appearance [185]

In particular, mucosal thickening >10 mm with a circumferential or complete opacification was shown to most commonly accompany ostium obstruction. Another study reported consistent findings. Postoperative CBCT scan found four cases presenting complete or partial sinus opacification even though no membrane perforation took place during the surgery. When checking the postoperative CBCT scan, ostium obstruction was detected in one case. This might seemingly account for

the opacity of sinus as the sinus ostium patency plays an important role in maintaining the health of sinus and determine the sinus drainage.



## 5. CONCLUSION

In this study all included patients were successful two stage sinus elevation surgeries and without complications. All patients were preoperatively and postoperatively analyzed by CBCT. The results of this retrospective study showed that approximately 14.87% of the sinus cavity is occupying by graft materials after sinus elevation procedure. This study is the first study reported in the literature investigating the safe volume of the sinus cavity for grafting. Safe volume after sinus grafting means not to interfere with the osteomeatal unit that hazardous to sinus physiology. No correlation were found between the thickness of the Schneiderian membrane and crestal gingival thickness. Crestal gingival thickness has been reported a predictor of sinus membrane thickness however our results did not support this prediction. Sinus anatomy and physiology did not change after sinus lifting procedure in this study depends on successful sinus surgeries. Another important factor that effects the sinus physiology is the thickening of sinus membrane after surgery. In this study there were no differences between pre-op and post-op CBCT scans according to sinus membrane thickness suggested no altered physiology after sinus lifting procedure. For appropriate sinus augmentation, it is important to take the characteristics and physiology of the sinus into consideration. Sinus physiology may affected by altered anatomic relationships of the antral floor, in combination with a bulging or injured surface of the elevated sinus mucosa. In addition, postoperative swelling, haematoma, or seroma that fills the maxillary sinus may also lead to reduction of the patency of the osteo-meatal unit, playing a key role in the development of post-operative sinusitis. Accordingly it is important to analyze and characterize the sinus physiology and anatomy before any sinus augmentation procedure with 3-D approach. This retrospective radiographic study confirmed that sinus augmentation surgery is a safe procedure when carefully planned and executed and do not change the sinus physiology.

## 6. REFERENCES

1. Muller, F., M. Naharro, and G.E. Carlsson, *What are the prevalence and incidence of tooth loss in the adult and elderly population in Europe?* Clin Oral Implants Res, 2007. **18 Suppl 3**: p. 2-14.
2. Bryant, S.R. and G.A. Zarb, *Osseointegration of oral implants in older and younger adults.* Int J Oral Maxillofac Implants, 1998. **13**(4): p. 492-9.
3. Zarb, G.A. and A. Schmitt, *The longitudinal clinical effectiveness of osseointegrated dental implants: the Toronto study. Part III: Problems and complications encountered.* J Prosthet Dent, 1990. **64**(2): p. 185-94.
4. Block, M.S., et al., *Hemimaxillectomy prosthesis stabilization with hydroxylapatite coated implants: a case report.* Int J Oral Maxillofac Implants, 1987. **2**(2): p. 111-3.
5. Tonetti, M.S. and C.H. Hammerle, *Advances in bone augmentation to enable dental implant placement: Consensus Report of the Sixth European Workshop on Periodontology.* J Clin Periodontol, 2008. **35**(8 Suppl): p. 168-72.
6. Tatum, J.H., *Maxillary and sinus implant reconstructions.* Dental Clinics of North America, 1986. **30**(2): p. 207-229.
7. Wallace, S.S. and S.J. Froum, *Effect of maxillary sinus augmentation on the survival of endosseous dental implants. A systematic review.* Ann Periodontol, 2003. **8**(1): p. 328-43.
8. Raghav, M., et al., *Prevalence of incidental maxillary sinus pathologies in dental patients on cone-beam computed tomographic images.* Contemp Clin Dent, 2014. **5**(3): p. 361-5.
9. Anzai, Y. and B. Yueh, *Imaging evaluation of sinusitis: diagnostic performance and impact on health outcome.* Neuroimaging Clin N Am, 2003. **13**(2): p. 251-63, xi.
10. Mafee, M.F., B.H. Tran, and A.R. Chapa, *Imaging of rhinosinusitis and its complications: plain film, CT, and MRI.* Clin Rev Allergy Immunol, 2006. **30**(3): p. 165-86.
11. Dobele, I., et al., *Radiographic assessment of findings in the maxillary sinus using cone-beam computed tomography.* Stomatologija, 2013. **15**(4): p. 119-22.
12. Nunes, L.S., et al., *Anatomical characteristics and dimensions of edentulous sites in the posterior maxillae of patients referred for implant therapy.* Int J Periodontics Restorative Dent, 2013. **33**(3): p. 337-45.
13. Rahpeyma, A. and S. Khajehahmadi, *Open Sinus Lift Surgery and the Importance of Preoperative Cone-Beam Computed Tomography Scan: A Review.* J Int Oral Health, 2015. **7**(9): p. 127-33.
14. White, S.C., *Cone-beam imaging in dentistry.* Health Phys, 2008. **95**(5): p. 628-37.

15. Barriviera, M., et al., *A new method to assess and measure palatal masticatory mucosa by cone-beam computerized tomography*. J Clin Periodontol, 2009. **36**(7): p. 564-8.
16. Berengo, M., et al., *Endoscopic evaluation of the bone-added osteotome sinus floor elevation procedure*. Int J Oral Maxillofac Surg, 2004. **33**(2): p. 189-94.
17. van den Bergh, J.P., et al., *Anatomical aspects of sinus floor elevations*. Clin Oral Implants Res, 2000. **11**(3): p. 256-65.
18. Aimetti, M., et al., *Correlation between gingival phenotype and Schneiderian membrane thickness*. Int J Oral Maxillofac Implants, 2008. **23**(6): p. 1128-32.
19. Smiler, D.G., et al., *Sinus lift grafts and endosseous implants. Treatment of the atrophic posterior maxilla*. Dent Clin North Am, 1992. **36**(1): p. 151-86; discussion 187-8.
20. Hurzeler, M.B., et al., *Reconstruction of the severely resorbed maxilla with dental implants in the augmented maxillary sinus: a 5-year clinical investigation*. Int J Oral Maxillofac Implants, 1996. **11**(4): p. 466-75.
21. Fugazzotto, P.A. and J. Vlassis, *Long-term success of sinus augmentation using various surgical approaches and grafting materials*. Int J Oral Maxillofac Implants, 1998. **13**(1): p. 52-8.
22. Ariji, Y., et al., *Age changes in the volume of the human maxillary sinus: a study using computed tomography*. Dentomaxillofac Radiol, 1994. **23**(3): p. 163-8.
23. Cricchio, G. and S. Lundgren, *Donor site morbidity in two different approaches to anterior iliac crest bone harvesting*. Clin Implant Dent Relat Res, 2003. **5**(3): p. 161-9.
24. Raghoobar, G.M., et al., *Morbidity of chin bone harvesting*. Clin Oral Implants Res, 2001. **12**(5): p. 503-7.
25. Kalk, W.W., et al., *Morbidity from iliac crest bone harvesting*. J Oral Maxillofac Surg, 1996. **54**(12): p. 1424-9; discussion 1430.
26. Branemark, P.I., et al., *Intra-osseous anchorage of dental prostheses. I. Experimental studies*. Scand J Plast Reconstr Surg, 1969. **3**(2): p. 81-100.
27. Branemark, P.I., et al., *Osseointegrated implants in the treatment of the edentulous jaw. Experience from a 10-year period*. Scand J Plast Reconstr Surg Suppl, 1977. **16**: p. 1-132.
28. Schroeder, A., O. Pohler, and F. Sutter, *[Tissue reaction to an implant of a titanium hollow cylinder with a titanium surface spray layer]*. SSO Schweiz Monatsschr Zahnheilkd, 1976. **86**(7): p. 713-27.
29. Albrektsson, T., L. Sennerby, and A. Wennerberg, *State of the art of oral implants*. Periodontol 2000, 2008. **47**: p. 15-26.
30. Becktor, J.P., S. Isaksson, and L. Sennerby, *Survival analysis of endosseous implants in grafted and nongrafted edentulous maxillae*. Int J Oral Maxillofac Implants, 2004. **19**(1): p. 107-15.

31. Nystrom, E., et al., *A 9-14 year follow-up of onlay bone grafting in the atrophic maxilla*. Int J Oral Maxillofac Surg, 2009. **38**(2): p. 111-6.
32. Pjetursson, B.E., et al., *A systematic review of the success of sinus floor elevation and survival of implants inserted in combination with sinus floor elevation*. J Clin Periodontol, 2008. **35**(8 Suppl): p. 216-40.
33. Lambert, F.E., et al., *Descriptive analysis of implant and prosthodontic survival rates with fixed implant-supported rehabilitations in the edentulous maxilla*. J Periodontol, 2009. **80**(8): p. 1220-30.
34. Giordano, C., et al., *A new chemical etching process to improve endosseous implant osseointegration: in vitro evaluation on human osteoblast-like cells*. Int J Artif Organs, 2006. **29**(8): p. 772-80.
35. P., M.-B., *On the influence of micro- and macroscopic surface modifications on bone integration of titanium implants*. 2006, Göteborg: Göteborg University.
36. Sul, Y.T., C. Johansson, and T. Albrektsson, *Which surface properties enhance bone response to implants? Comparison of oxidized magnesium, TiUnite, and Osseotite implant surfaces*. Int J Prosthodont, 2006. **19**(4): p. 319-28.
37. Cochran, D.L., et al., *The use of reduced healing times on ITI implants with a sandblasted and acid-etched (SLA) surface: early results from clinical trials on ITI SLA implants*. Clin Oral Implants Res, 2002. **13**(2): p. 144-53.
38. Boyan, B.D., et al., *Osteoblast-mediated mineral deposition in culture is dependent on surface microtopography*. Calcif Tissue Int, 2002. **71**(6): p. 519-29.
39. Lemperle, S.M., et al., *Bony healing of large cranial and mandibular defects protected from soft-tissue interposition: A comparative study of spontaneous bone regeneration, osteoconduction, and cancellous autografting in dogs*. Plast Reconstr Surg, 1998. **101**(3): p. 660-72.
40. Marsell, R. and T.A. Einhorn, *The biology of fracture healing*. Injury, 2011. **42**(6): p. 551-5.
41. O'Toole, M.T., *Mosby's Medical Dictionary*. 2012: Elsevier.
42. Martin RB, B.D., Sharkey NA, *Skeletal tissue mechanics*. 1998: Springer.
43. Franz-Odenaal, T.A., B.K. Hall, and P.E. Witten, *Buried alive: how osteoblasts become osteocytes*. Dev Dyn, 2006. **235**(1): p. 176-90.
44. Allen, M.R., J.M. Hock, and D.B. Burr, *Periosteum: biology, regulation, and response to osteoporosis therapies*. Bone, 2004. **35**(5): p. 1003-12.
45. Colnot, C., X. Zhang, and M.L. Knothe Tate, *Current insights on the regenerative potential of the periosteum: molecular, cellular, and endogenous engineering approaches*. J Orthop Res, 2012. **30**(12): p. 1869-78.
46. Dimitriou, R., et al., *Bone regeneration: current concepts and future directions*. BMC Med, 2011. **9**: p. 66.

47. Price, A.M., et al., *De novo bone formation after the sinus lift procedure*. J Periodontol, 2011. **82**(9): p. 1245-55.
48. Jensen, O.T., et al., *Report of the Sinus Consensus Conference of 1996*. Int J Oral Maxillofac Implants, 1998. **13 Suppl**: p. 11-45.
49. Wheeler, S.L., R.E. Holmes, and C.J. Calhoun, *Six-year clinical and histologic study of sinus-lift grafts*. Int J Oral Maxillofac Implants, 1996. **11**(1): p. 26-34.
50. Wheeler, S.L., *Sinus augmentation for dental implants: the use of alloplastic materials*. J Oral Maxillofac Surg, 1997. **55**(11): p. 1287-93.
51. Jensen, T., et al., *Bone-to-implant contact after maxillary sinus floor augmentation with Bio-Oss and autogenous bone in different ratios in mini pigs*. Clin Oral Implants Res, 2013. **24**(6): p. 635-44.
52. Jensen, T., et al., *Volumetric changes of the graft after maxillary sinus floor augmentation with Bio-Oss and autogenous bone in different ratios: a radiographic study in minipigs*. Clin Oral Implants Res, 2012. **23**(8): p. 902-10.
53. Ellegaard, B., J. Kolsen-Petersen, and V. Baelum, *Implant therapy involving maxillary sinus lift in periodontally compromised patients*. Clin Oral Implants Res, 1997. **8**(4): p. 305-15.
54. Li, T.F., *Sinus floor elevation: a revised osteotome technique and its biological concept*. Compend Contin Educ Dent, 2005. **26**(9): p. 619-20, 622, 624-6 passim; quiz 630, 669.
55. Lundgren, S., et al., *Sinus membrane elevation and simultaneous insertion of dental implants: a new surgical technique in maxillary sinus floor augmentation*. Periodontol 2000, 2008. **47**: p. 193-205.
56. Boyne, P.J., *Analysis of performance of root-form endosseous implants placed in the maxillary sinus*. J Long Term Eff Med Implants, 1993. **3**(2): p. 143-59.
57. Sohn, D.S., et al., *Bone regeneration in the maxillary sinus using an autologous fibrin-rich block with concentrated growth factors alone*. Implant Dent, 2011. **20**(5): p. 389-95.
58. Sohn, D.S., et al., *Comparison of new bone formation in the maxillary sinus with and without bone grafts: immunochemical rabbit study*. Int J Oral Maxillofac Implants, 2011. **26**(5): p. 1033-42.
59. Srouji, S., et al., *The innate osteogenic potential of the maxillary sinus (Schneiderian) membrane: an ectopic tissue transplant model simulating sinus lifting*. Int J Oral Maxillofac Surg, 2010. **39**(8): p. 793-801.
60. Scala, A., et al., *Early healing after elevation of the maxillary sinus floor applying a lateral access: a histological study in monkeys*. Clin Oral Implants Res, 2010. **21**(12): p. 1320-6.
61. Chanavaz, M., *Maxillary sinus: anatomy, physiology, surgery, and bone grafting related to implantology--eleven years of surgical experience (1979-1990)*. J Oral Implantol, 1990. **16**(3): p. 199-209.
62. Naumann, H.H. and C.R. Pfaltz, *Ear, nose, and throat diseases: a pocket reference*. 1994: G. Thieme Verlag.

63. Kennedy, D.W., W.E. Bolger, and S.J. Zinreich, *Diseases of the sinuses: diagnosis and management*. 2001: PMPH-USA.
64. Mol van Otterloo, J.d., *The influence of the Le Fort I osteotomy on the surrounding midfacial structures*. Amsterdam: Vrije Universiteit, 1994.
65. Chan, H.L., et al., *Evaluation of maxillary sinus width on cone-beam computed tomography for sinus augmentation and new sinus classification based on sinus width*. Clin Oral Implants Res, 2014. **25**(6): p. 647-52.
66. Uchida, Y., et al., *A cadaveric study of maxillary sinus size as an aid in bone grafting of the maxillary sinus floor*. J Oral Maxillofac Surg, 1998. **56**(10): p. 1158-63.
67. Uchida, Y., et al., *Measurement of maxillary sinus volume using computerized tomographic images*. Int J Oral Maxillofac Implants, 1998. **13**(6): p. 811-8.
68. Krennmair, G., C. Ulm, and H. Lugmayr, *Maxillary sinus septa: incidence, morphology and clinical implications*. J Craniomaxillofac Surg, 1997. **25**(5): p. 261-5.
69. Velasquez-Plata, D., et al., *Maxillary sinus septa: a 3-dimensional computerized tomographic scan analysis*. Int J Oral Maxillofac Implants, 2002. **17**(6): p. 854-60.
70. Kim, M.J., et al., *Maxillary sinus septa: prevalence, height, location, and morphology. A reformatted computed tomography scan analysis*. J Periodontol, 2006. **77**(5): p. 903-8.
71. Gonzalez-Santana, H., et al., *A study of the septa in the maxillary sinuses and the subantral alveolar processes in 30 patients*. J Oral Implantol, 2007. **33**(6): p. 340-3.
72. Underwood, A.S., *An Inquiry into the Anatomy and Pathology of the Maxillary Sinus*. J Anat Physiol, 1910. **44**(Pt 4): p. 354-69.
73. Betts, N.J. and M. Miloro, *Modification of the sinus lift procedure for septa in the maxillary antrum*. J Oral Maxillofac Surg, 1994. **52**(3): p. 332-3.
74. Zijdeveld, S.A., et al., *Anatomical and surgical findings and complications in 100 consecutive maxillary sinus floor elevation procedures*. J Oral Maxillofac Surg, 2008. **66**(7): p. 1426-38.
75. Pommer, B., et al., *Prevalence, location and morphology of maxillary sinus septa: systematic review and meta-analysis*. J Clin Periodontol, 2012. **39**(8): p. 769-73.
76. Maestre-Ferrin, L., et al., *Prevalence, location, and size of maxillary sinus septa: panoramic radiograph versus computed tomography scan*. J Oral Maxillofac Surg, 2011. **69**(2): p. 507-11.
77. Kasabah, S., et al., *Evaluation of the accuracy of panoramic radiograph in the definition of maxillary sinus septa*. Acta Medica (Hradec Kralove), 2002. **45**(4): p. 173-5.

78. Ulm, C.W., et al., *The edentulous maxillary alveolar process in the region of the maxillary sinus--a study of physical dimension*. Int J Oral Maxillofac Surg, 1995. **24**(4): p. 279-82.
79. Krennmair, G., et al., *The incidence, location, and height of maxillary sinus septa in the edentulous and dentate maxilla*. J Oral Maxillofac Surg, 1999. **57**(6): p. 667-71; discussion 671-2.
80. Baciut, M., et al., *Pre- and postoperative assessment of sinus grafting procedures using cone-beam computed tomography compared with panoramic radiographs*. Clin Oral Implants Res, 2013. **24**(5): p. 512-6.
81. May, M., S.M. Sobol, and K. Korzec, *The location of the maxillary os and its importance to the endoscopic sinus surgeon*. Laryngoscope, 1990. **100**(10 Pt 1): p. 1037-42.
82. Ritter, F.N., *The paranasal sinuses: anatomy and surgical technique*. Vol. 340. 1973: Mosby.
83. Blanton, P.L. and N.L. Biggs, *Eighteen hundred years of controversy: the paranasal sinuses*. Am J Anat, 1969. **124**(2): p. 135-47.
84. Topozada, H.H. and M.A. Talaat, *The normal human maxillary sinus mucosa. An electron microscopic study*. Acta Otolaryngol, 1980. **89**(3-4): p. 204-13.
85. Testori, T., et al., *Ligation of an unusually large vessel during maxillary sinus floor augmentation. A case report*. Eur J Oral Implantol, 2010. **3**(3): p. 255-8.
86. Insua, A., et al., *Accuracy of Schneiderian membrane thickness: a cone-beam computed tomography analysis with histological validation*. Clin Oral Implants Res, 2017. **28**(6): p. 654-661.
87. Keceli, H.G., et al., *Evaluation of Single Tooth Loss to Maxillary Sinus and Surrounding Bone Anatomy With Cone-Beam Computed Tomography: A Multicenter Study*. Implant Dent, 2017. **26**(5): p. 690-699.
88. Cagici, C.A., et al., *Appropriate interslice gap for screening coronal paranasal sinus tomography for mucosal thickening*. Eur Arch Otorhinolaryngol, 2009. **266**(4): p. 519-25.
89. Havas, T.E., J.A. Motbey, and P.J. Gullane, *Prevalence of incidental abnormalities on computed tomographic scans of the paranasal sinuses*. Arch Otolaryngol Head Neck Surg, 1988. **114**(8): p. 856-9.
90. Cooke, L.D. and D.M. Hadley, *MRI of the paranasal sinuses: incidental abnormalities and their relationship to symptoms*. J Laryngol Otol, 1991. **105**(4): p. 278-81.
91. Patel, S., *New dimensions in endodontic imaging: Part 2. Cone beam computed tomography*. Int Endod J, 2009. **42**(6): p. 463-75.
92. Vallo, J., et al., *Prevalence of mucosal abnormalities of the maxillary sinus and their relationship to dental disease in panoramic radiography: results from the Health 2000 Health Examination Survey*. Oral Surg Oral Med Oral Pathol Oral Radiol Endod, 2010. **109**(3): p. e80-7.

93. Harris, D., et al., *E.A.O. guidelines for the use of diagnostic imaging in implant dentistry 2011. A consensus workshop organized by the European Association for Osseointegration at the Medical University of Warsaw*. Clin Oral Implants Res, 2012. **23**(11): p. 1243-53.
94. Harris, D., et al., *E.A.O. guidelines for the use of diagnostic imaging in implant dentistry. A consensus workshop organized by the European Association for Osseointegration in Trinity College Dublin*. Clin Oral Implants Res, 2002. **13**(5): p. 566-70.
95. Dula, K., et al., *The radiographic assessment of implant patients: decision-making criteria*. Int J Oral Maxillofac Implants, 2001. **16**(1): p. 80-9.
96. Cohenca, N., et al., *Clinical indications for digital imaging in dento-alveolar trauma. Part I: traumatic injuries*. Dent Traumatol, 2007. **23**(2): p. 95-104.
97. Hirsch, E., et al., *Dosimetry of the cone beam computed tomography Veraviewepocs 3D compared with the 3D Accuitomo in different fields of view*. Dentomaxillofac Radiol, 2008. **37**(5): p. 268-73.
98. Watelet, J.B., et al., *Wound healing of the nasal and paranasal mucosa: a review*. Am J Rhinol, 2002. **16**(2): p. 77-84.
99. Stammberger, H., *Nasal and paranasal sinus endoscopy. A diagnostic and surgical approach to recurrent sinusitis*. Endoscopy, 1986. **18**(6): p. 213-8.
100. Solar, P., et al., *Blood supply to the maxillary sinus relevant to sinus floor elevation procedures*. Clin Oral Implants Res, 1999. **10**(1): p. 34-44.
101. Flanagan, D., *Arterial supply of maxillary sinus and potential for bleeding complication during lateral approach sinus elevation*. Implant Dent, 2005. **14**(4): p. 336-8.
102. McGowan, D.A., Baxter, P.W. & James, J., *The Maxillary Sinus and its Dental Implications*. 1993: Oxford: Wright, Butterworth-Heinemann Ltd.
103. Traxler, H., et al., *Arterial blood supply of the maxillary sinus*. Clin Anat, 1999. **12**(6): p. 417-21.
104. Elian, N., et al., *Distribution of the maxillary artery as it relates to sinus floor augmentation*. Int J Oral Maxillofac Implants, 2005. **20**(5): p. 784-7.
105. Guncu, G.N., et al., *Location of posterior superior alveolar artery and evaluation of maxillary sinus anatomy with computerized tomography: a clinical study*. Clin Oral Implants Res, 2011. **22**(10): p. 1164-7.
106. Ella, B., et al., *Vascular connections of the lateral wall of the sinus: surgical effect in sinus augmentation*. Int J Oral Maxillofac Implants, 2008. **23**(6): p. 1047-52.
107. Testori, T., et al., *A multicenter prospective evaluation of 2-months loaded Osseotite implants placed in the posterior jaws: 3-year follow-up results*. Clin Oral Implants Res, 2002. **13**(2): p. 154-61.
108. Lindhe J, L.N., Karring T. , *Clinical Periodontology and Implant Dentistry* 5th Edition ed. 2008: Wiley-Blackwell.



109. Aghaloo, T.L. and P.K. Moy, *Which hard tissue augmentation techniques are the most successful in furnishing bony support for implant placement?* Int J Oral Maxillofac Implants, 2007. **22 Suppl**: p. 49-70.
110. Taschieri, S., S. Corbella, and M. Del Fabbro, *Mini-invasive osteotome sinus floor elevation in partially edentulous atrophic maxilla using reduced length dental implants: interim results of a prospective study.* Clin Implant Dent Relat Res, 2014. **16**(2): p. 185-93.
111. Malo, P., M. Nobre, and A. Lopes, *Immediate loading of 'All-on-4' maxillary prostheses using trans-sinus tilted implants without sinus bone grafting: a retrospective study reporting the 3-year outcome.* Eur J Oral Implantol, 2013. **6**(3): p. 273-83.
112. Del Fabbro, M., G. Rosano, and S. Taschieri, *Implant survival rates after maxillary sinus augmentation.* Eur J Oral Sci, 2008. **116**(6): p. 497-506.
113. Barone, A., et al., *A clinical study of the outcomes and complications associated with maxillary sinus augmentation.* Int J Oral Maxillofac Implants, 2006. **21**(1): p. 81-5.
114. Tatum, H., *Lectures presented at the Alabama implant study group.* Birmingham, AL, 1977.
115. Boyne, P.J. and R.A. James, *Grafting of the maxillary sinus floor with autogenous marrow and bone.* J Oral Surg, 1980. **38**(8): p. 613-6.
116. Tatum, H., Jr., *Maxillary and sinus implant reconstructions.* Dent Clin North Am, 1986. **30**(2): p. 207-29.
117. Temmerman, A., et al., *Are panoramic images reliable in planning sinus augmentation procedures?* Clin Oral Implants Res, 2011. **22**(2): p. 189-94.
118. Fortin, T., et al., *Panoramic images versus three-dimensional planning software for oral implant planning in atrophied posterior maxillary: a clinical radiological study.* Clin Implant Dent Relat Res, 2013. **15**(2): p. 198-204.
119. Janner, S.F., et al., *Characteristics and dimensions of the Schneiderian membrane: a radiographic analysis using cone beam computed tomography in patients referred for dental implant surgery in the posterior maxilla.* Clin Oral Implants Res, 2011. **22**(12): p. 1446-53.
120. Maestre-Ferrin, L., et al., *Maxillary sinus septa: a systematic review.* Med Oral Patol Oral Cir Bucal, 2010. **15**(2): p. e383-6.
121. Neugebauer, J., et al., *Evaluation of maxillary sinus anatomy by cone-beam CT prior to sinus floor elevation.* Int J Oral Maxillofac Implants, 2010. **25**(2): p. 258-65.
122. Ludlow, J.B. and M. Ivanovic, *Comparative dosimetry of dental CBCT devices and 64-slice CT for oral and maxillofacial radiology.* Oral Surg Oral Med Oral Pathol Oral Radiol Endod, 2008. **106**(1): p. 106-14.
123. Anavi, Y., et al., *Complications of maxillary sinus augmentations in a selective series of patients.* Oral Surg Oral Med Oral Pathol Oral Radiol Endod, 2008. **106**(1): p. 34-8.

124. Ziccardi, V. and N. Betts, *Complications of maxillary sinus augmentation. The sinus bone graft*, 1999: p. 201-208.
125. Busaba, N.Y. and S.D. Salman, *Maxillary sinus mucocèles: clinical presentation and long-term results of endoscopic surgical treatment*. Laryngoscope, 1999. **109**(9): p. 1446-9.
126. Katranji, A., P. Fotek, and H.L. Wang, *Sinus augmentation complications: etiology and treatment*. Implant Dent, 2008. **17**(3): p. 339-49.
127. Bornstein, M.M., et al., *Characteristics and dimensions of the Schneiderian membrane and apical bone in maxillary molars referred for apical surgery: a comparative radiographic analysis using limited cone beam computed tomography*. J Endod, 2012. **38**(1): p. 51-7.
128. Maillet, M., et al., *Cone-beam computed tomography evaluation of maxillary sinusitis*. J Endod, 2011. **37**(6): p. 753-7.
129. Yildirim, T.T., et al., *The effect of demographic and disease variables on Schneiderian membrane thickness and appearance*. Oral Surg Oral Med Oral Pathol Oral Radiol, 2017.
130. Orhan, K., et al., *Cone beam CT evaluation of maxillary sinus septa prevalence, height, location and morphology in children and an adult population*. Med Princ Pract, 2013. **22**(1): p. 47-53.
131. Gröndahl, H. and K. Gröndahl, *Radiographic examination of the implant patient*. Clinical Periodontology and Implant Dentistry. Oxford: Wiley-Blackwell, 2008: p. 600-22.
132. Jaju, P.P. and S.P. Jaju, *Cone-beam computed tomography: Time to move from ALARA to ALADA*. Imaging Sci Dent, 2015. **45**(4): p. 263-5.
133. ten Bruggenkate, C.M. and J.P. van den Bergh, *Maxillary sinus floor elevation: a valuable pre-prosthetic procedure*. Periodontol 2000, 1998. **17**: p. 176-82.
134. Ferrigno, N., M. Laureti, and S. Fanali, *Dental implants placement in conjunction with osteotome sinus floor elevation: a 12-year life-table analysis from a prospective study on 588 ITI implants*. Clin Oral Implants Res, 2006. **17**(2): p. 194-205.
135. Rosen, P.S., et al., *The bone-added osteotome sinus floor elevation technique: multicenter retrospective report of consecutively treated patients*. Int J Oral Maxillofac Implants, 1999. **14**(6): p. 853-8.
136. Mazor, Z., et al., *The use of hydroxyapatite bone cement for sinus floor augmentation with simultaneous implant placement in the atrophic maxilla. A report of 10 cases*. J Periodontol, 2000. **71**(7): p. 1187-94.
137. Chen, T.W., et al., *Implant placement immediately after the lateral approach of the trap door window procedure to create a maxillary sinus lift without bone grafting: a 2-year retrospective evaluation of 47 implants in 33 patients*. J Oral Maxillofac Surg, 2007. **65**(11): p. 2324-8.
138. Irinakakis, T., *Efficacy of injectable demineralized bone matrix as graft material during sinus elevation surgery with simultaneous implant placement in the*

- posterior maxilla: clinical evaluation of 49 sinuses.* J Oral Maxillofac Surg, 2011. **69**(1): p. 134-41.
139. Hatano, N., Y. Shimizu, and K. Ooya, *A clinical long-term radiographic evaluation of graft height changes after maxillary sinus floor augmentation with a 2:1 autogenous bone/xenograft mixture and simultaneous placement of dental implants.* Clin Oral Implants Res, 2004. **15**(3): p. 339-45.
  140. Peleg, M., A.K. Garg, and Z. Mazor, *Healing in smokers versus nonsmokers: survival rates for sinus floor augmentation with simultaneous implant placement.* Int J Oral Maxillofac Implants, 2006. **21**(4): p. 551-9.
  141. Wallace, S.S., et al., *Maxillary sinus elevation by lateral window approach: evolution of technology and technique.* J Evid Based Dent Pract, 2012. **12**(3 Suppl): p. 161-71.
  142. Dursun, E., et al., *Do porous titanium granule grafts affect bone microarchitecture at augmented maxillary sinus sites? a pilot split-mouth human study.* Implant dentistry, 2015. **24**(4): p. 427-433.
  143. Dursun, C.K., et al., *Effect of porous titanium granules on bone regeneration and primary stability in maxillary sinus: a human clinical, histomorphometric, and microcomputed tomography analyses.* Journal of Craniofacial Surgery, 2016. **27**(2): p. 391-397.
  144. Wood, R.M. and D.L. Moore, *Grafting of the maxillary sinus with intraorally harvested autogenous bone prior to implant placement.* Int J Oral Maxillofac Implants, 1988. **3**(3): p. 209-14.
  145. Vercellotti, T., S. De Paoli, and M. Nevins, *The piezoelectric bony window osteotomy and sinus membrane elevation: introduction of a new technique for simplification of the sinus augmentation procedure.* Int J Periodontics Restorative Dent, 2001. **21**(6): p. 561-7.
  146. Mazor, Z., et al., *Sinus floor augmentation with simultaneous implant placement using Choukroun's platelet-rich fibrin as the sole grafting material: a radiologic and histologic study at 6 months.* J Periodontol, 2009. **80**(12): p. 2056-64.
  147. Doud Galli, S.K., et al., *Chronic sinusitis complicating sinus lift surgery.* American journal of rhinology, 2001. **15**(3): p. 181-186.
  148. Timmenga, N.M., et al., *Maxillary sinusitis after augmentation of the maxillary sinus floor: a report of 2 cases.* Journal of Oral and Maxillofacial Surgery, 2001. **59**(2): p. 200-204.
  149. Bertrand, B. and P. Eloy, *Relationship of chronic ethmoidal sinusitis, maxillary sinusitis, and ostial permeability controlled by sinusomanometry: statistical study.* The Laryngoscope, 1992. **102**(11): p. 1281-1284.
  150. Albrektsson, T., et al., *The long-term efficacy of currently used dental implants: a review and proposed criteria of success.* Int J Oral Maxillofac Implants, 1986. **1**(1): p. 11-25.
  151. Albrektsson, T., D. Buser, and L. Sennerby, *Crestal bone loss and oral implants.* Clin Implant Dent Relat Res, 2012. **14**(6): p. 783-91.

152. Tuna, T., M. Yorgidis, and J.R. Strub, *Prognosis of implants and fixed restorations after lateral sinus elevation: a literature review*. J Oral Rehabil, 2012. **39**(3): p. 226-38.
153. Schaeffer, J.P., *The sinus maxillaris and its relations in the embryo, child, and adult man*. Developmental Dynamics, 1910. **10**(1): p. 313-368.
154. Anagnostopoulou, S., D. Venieratos, and N. Spyropoulos, *Classification of human maxillar sinuses according to their geometric features*. Anatomischer Anzeiger, 1991. **173**(3): p. 121-130.
155. Ariji, Y., et al., *Age changes in the volume of the human maxillary sinus: a study using computed tomography*. Dentomaxillofacial radiology, 1994. **23**(3): p. 163-168.
156. Shanbhag, S., V. Shanbhag, and A. Stavropoulos, *Volume changes of maxillary sinus augmentations over time: a systematic review*. International Journal of Oral & Maxillofacial Implants, 2014. **29**(4).
157. Kirmeier, R., et al., *Evaluation of three-dimensional changes after sinus floor augmentation with different grafting materials*. Clinical oral implants research, 2008. **19**(4): p. 366-372.
158. Diserens, V., E. Mericske, and R. Mericske-Stern, *Radiographic Analysis of the Transcrestal Sinus Floor Elevation: Short-Term Observations*. Clinical implant dentistry and related research, 2005. **7**(2): p. 70-78.
159. Bolin, A., et al., *Radiographic evaluation of maddibular posterior implant sites; correlation between panoramic and tomographic determinations*. Clinical oral implants research, 1996. **7**(4): p. 354-359.
160. Gray, C.F., et al., *Magnetic resonance imaging assessment of a sinus lift operation using reoxidised cellulose (SurgicelR) as graft material*. Clinical oral implants research, 2001. **12**(5): p. 526-530.
161. Bianchi, J., et al., *Measuring the efficacy of rhBMP-2 to regenerate bone: a radiographic study using a commercially available software program*. International Journal of Periodontics & Restorative Dentistry, 2004. **24**(6).
162. Bouquet, A., et al., *Contributions of reformatted computed tomography and panoramic radiography in the localization of third molars relative to the maxillary sinus*. Oral Surgery, Oral Medicine, Oral Pathology, Oral Radiology and Endodontics, 2004. **98**(3): p. 342-347.
163. Reddy, M., et al., *A comparison of the diagnostic advantages of panoramic radiography and computed tomography scanning for placement of root form dental implants*. Clinical oral implants research, 1994. **5**(4): p. 229-238.
164. Johansson, B., et al., *A clinical study of changes in the volume of bone grafts in the atrophic maxilla*. Dentomaxillofacial Radiology, 2001. **30**(3): p. 157-161.
165. Dastidar, P., et al., *Semi-automatic segmentation of computed tomographic images in volumetric estimation of nasal airway*. European archives of oto-rhino-laryngology, 1999. **256**(4): p. 192-198.

166. Uchida, Y., et al., *Measurement of maxillary sinus volume using computerized tomographic images*. International Journal of Oral and Maxillofacial Implants, 1998. **13**(6): p. 811-818.
167. Szabó, G., et al., *A Prospective Multicenter Randomized Clinical Trial of Autogenous Bone Versus  $\beta$ -Tricalcium Phosphate Graft Alone for Bilateral Sinus Elevation: Histologic and Histomorphometric Evaluation*. International Journal of Oral & Maxillofacial Implants, 2005. **20**(3).
168. Smolka, W., et al., *Changes in the volume and density of calvarial split bone grafts after alveolar ridge augmentation*. Clinical oral implants research, 2006. **17**(2): p. 149-155.
169. Wanschitz, F., et al., *Measurement of volume changes after sinus floor augmentation with a phycogenic hydroxyapatite*. International Journal of Oral & Maxillofacial Implants, 2006. **21**(3).
170. Mazzocco, F., et al., *Three-dimensional volume change of grafted bone in the maxillary sinus*. International Journal of Oral & Maxillofacial Implants, 2014. **29**(1).
171. Uchida, Y., et al., *A cadaveric study of maxillary sinus size as an aid in bone grafting of the maxillary sinus floor*. Journal of oral and maxillofacial surgery, 1998. **56**(10): p. 1158-1163.
172. Lin, Y.H., et al., *The influence of sinus membrane thickness upon membrane perforation during lateral window sinus augmentation*. Clinical oral implants research, 2016. **27**(5): p. 612-617.
173. Yoo, J.-Y., et al., *Healing pattern of the mucous membrane after tooth extraction in the maxillary sinus*. Journal of periodontal & implant science, 2011. **41**(1): p. 23-29.
174. Yilmaz, H.G. and T.F. Tözüm, *Are gingival phenotype, residual ridge height, and membrane thickness critical for the perforation of maxillary sinus?* Journal of periodontology, 2012. **83**(4): p. 420-425.
175. Pommer, B., et al., *Effect of maxillary sinus floor augmentation on sinus membrane thickness in computed tomography*. Journal of periodontology, 2012. **83**(5): p. 551-556.
176. Cagici, C.A., et al., *Appropriate interslice gap for screening coronal paranasal sinus tomography for mucosal thickening*. European Archives of Oto-Rhino-Laryngology, 2009. **266**(4): p. 519-525.
177. Janner, S.F., et al., *Characteristics and dimensions of the Schneiderian membrane: a radiographic analysis using cone beam computed tomography in patients referred for dental implant surgery in the posterior maxilla*. Clinical oral implants research, 2011. **22**(12): p. 1446-1453.
178. Vallo, J., et al., *Prevalence of mucosal abnormalities of the maxillary sinus and their relationship to dental disease in panoramic radiography: results from the Health 2000 Health Examination Survey*. Oral Surgery, Oral Medicine, Oral Pathology, Oral Radiology and Endodontics, 2010. **109**(3): p. e80-e87.

179. Tos, M. and C. Mogensen, *Mucus production in the nasal sinuses*. Acta Otolaryngol Suppl, 1979. **360**: p. 131-4.
180. Quirynen, M., et al., *Transient swelling of the Schneiderian membrane after transversal sinus augmentation: a pilot study*. Clinical oral implants research, 2014. **25**(1): p. 36-41.
181. Insua, A., et al., *Accuracy of Schneiderian membrane thickness: a cone-beam computed tomography analysis with histological validation*. Clinical oral implants research, 2017. **28**(6): p. 654-661.
182. Guo, Z.Z., et al., *Longitudinal response of membrane thickness and ostium patency following sinus floor elevation: a prospective cohort study*. Clinical oral implants research, 2016. **27**(6): p. 724-729.
183. Anduze-Acher, G., et al., *Change in sinus membrane dimension following sinus floor elevation: a retrospective cohort study*. Clinical oral implants research, 2013. **24**(10): p. 1123-1129.
184. Timmenga, N.M., et al., *Effects of maxillary sinus floor elevation surgery on maxillary sinus physiology*. European journal of oral sciences, 2003. **111**(3): p. 189-197.
185. Carmeli, G., et al., *Antral computerized tomography pre-operative evaluation: relationship between mucosal thickening and maxillary sinus function*. Clinical oral implants research, 2011. **22**(1): p. 78-82.