

Investigation of the determinants of the mandibular cortical morphology

Badanie determinant morfologii warstwy korowej żuchwy

Nagihan Koç^{A–D,F}, Leyla Berna Çağırankaya^{A,C,E}

Department of Dento-Maxillofacial Radiology, Faculty of Dentistry, Hacettepe University, Ankara, Turkey

A – research concept and design; B – collection and/or assembly of data; C – data analysis and interpretation; D – writing the article; E – critical revision of the article; F – final approval of the article

Dental and Medical Problems, ISSN 1644-387X (print), ISSN 2300-9020 (online)

Dent Med Probl. 2019;56(1):21–25

Address for correspondence

Nagihan Koç
E-mail: nagihan.koc@hacettepe.edu.tr

Funding sources

None declared

Conflict of interest

None declared

Received on October 21, 2018
Reviewed on November 17, 2018
Accepted on December 20, 2018

Published online on March 5, 2019

Abstract

Background. The mandibular cortical index (MCI) is a measurement based on the visual assessment of changes in the morphology of the mandibular cortex on panoramic radiographs.

Objectives. The present study aimed to investigate age, gender, dental status (DS), occlusal function, and presence of torus mandibularis (TM) as variables that might have a possible effect on MCI.

Material and methods. A total of 381 patients (155 men and 226 women) aged 21–84 years (mean age: 43.8 ± 14.5 years) were included in this study. Age, gender and DS were recorded for each patient. The occlusal function was evaluated using the Eichner index (EI). The presence of tori was assessed by visual inspection and digital palpation. The MCI assessments were done based on Klemetti's classification (C1–C3). Statistical comparisons were performed using the χ^2 test, independent samples *t*-test and multiple logistic regression analysis ($p < 0.05$).

Results. Significant differences were observed between the MCI categories regarding age, gender, DS, EI, and TM. The likelihood of the MCI categories C2 and C3 was increased in males (odds ratio (OR) 9.33; $p < 0.001$), when TM was absent (OR 2.73; $p < 0.001$), in EI Class B (OR 2.68; $p = 0.027$), and in the age group 50–70 years (OR 2.5; $p = 0.018$).

Conclusions. Morphological changes of the mandibular cortical bone are related to gender, presence of TM, occlusal function expressed as EI, and age.

Key words: panoramic radiography, mandibular cortical morphology, bone hyperplasia

Słowa kluczowe: radiografia panoramiczna, morfologia warstwy korowej żuchwy, hiperplazja kości

Cite as

Koç N, Çağırankaya LB. Investigation of the determinants of the mandibular cortical morphology. *Dent Med Probl.* 2019;56(1):21–25. doi:10.17219/dmp/102262

DOI

10.17219/dmp/102262

Copyright

© 2019 by Wrocław Medical University
This is an article distributed under the terms of the Creative Commons Attribution Non-Commercial License (<http://creativecommons.org/licenses/by-nc-nd/4.0/>)

Introduction

The skeletal system is a dynamic organ that undergoes remodeling throughout life. With increasing age, bone resorption exceeds bone formation, leading to remodeling imbalance, which results in a physiological decrease in bone mass.¹ Due to postmenopausal hormonal changes, in association with osteoporosis, women are more prone to lose mineralized bone compared to men. The condition known as osteoporosis is a systemic skeletal disease characterized by low bone mass and micro-architectural deterioration of bone tissue, leading to enhanced bone fragility and a consequent increase in fracture risk.²

The evidence suggests that the jawbones of subjects with osteoporosis show reduced bone mass and altered morphology.³ Since morphological changes involving the cortical layers of the mandible are shown to be dependent on age and mineral loss within the skeleton,^{4,5} investigations of the morphology of the jawbones in relation to osteoporosis, based on panoramic radiographs, are often done by evaluating the thickness and integrity of the inferior mandibular cortex.⁶ The thickness of the inferior mandibular cortex at the mental foramen region has often been measured directly (mental index) or as a ratio of the thickness divided by the distance from the mental foramen to the inferior border (panoramic mandibular index). Erosions of the inferior mandibular cortex are evaluated using the mandibular cortical index (MCI).

The mandibular cortical index, devised by Klemetti et al., is a simple ordinal scale, based on the visual evaluation of the mandibular cortex, and requires no measurements or calculations.⁵ Studies have shown that MCI is significantly correlated with bone mineral density (BMD) in the hip, lumbar spine, femoral neck, and mandible.^{7,8}

Tori and exostosis are common bony growths of the mandibular and maxillary bones, which are visualized predominantly in the 3rd decade of life.⁹ Mandibular tori are usually bilateral, located at the canine-premolar region, on the lingual aspect of the mandible, above the mylohyoid ridge. Previous studies suggest that bone metabolism might be involved in the development of torus mandibularis (TM) based on the correlations between the presence of tori and high BMD.^{10,11}

Studies have reported associations between MCI and age, gender and the number of teeth.^{12–14} A significant correlation between MCI and skeletal BMD has also been demonstrated.^{5,7} Based on the proposition that bone metabolism could play a role in the TM formation, a possible association between MCI and TM was suggested in this study. The aim of this study was, therefore, to evaluate age, gender, dental status (DS), occlusal function, and presence of TM as variables that might have a possible effect on MCI.

Material and methods

Selection of patients

The study was approved by the Non-Interventional Clinical Research Ethics Board of Hacettepe University, Ankara, Turkey (No. 16969557-91). Written informed consent was obtained from all participants.

A total of 381 patients (155 men and 226 women) who visited the Department of Dento-Maxillofacial Radiology, Faculty of Dentistry, Hacettepe University between January and June 2015 for a complete oral examination were randomly selected for the study. The mean age of the patients was 43.8 ± 14.5 years, ranging from 21 to 84 years.

All patients were over 20 years of age and had been indicated for panoramic radiography. The exclusion criteria comprised systemic diseases or the use of medications that affect bone metabolism, the presence of cancer with bone metastasis, and local pathologies that affect the evaluation of MCI or TM.

Procedures

After informed consent was obtained, patients underwent a clinical examination. The following data was recorded for each patient: age, gender, DS, the Eichner index (EI), and the presence or absence of TM. Radiographic analysis was performed in separate sessions after completing all clinical examinations.

Clinical examination

The existence of TM was evaluated on visual inspection and by means of a digital examination. Small thickenings or a questionable TM were considered as a normal lingual outline.

The dental status was recorded using a simple classification system (third molars excluded): full dentition, partial dentition (missing any teeth) and edentulous.^{12,13}

The Eichner index was used to evaluate the occlusal function, which was determined by the number of functioning posterior teeth. According to EI, there are 4 occlusal supporting zones in the jaws, 2 in the molar region and 2 in the premolar region. An occlusal supporting zone must have at least 1 contact between a tooth and its antagonist in order to be counted. In this study, patients were grouped based on a modified version of EI¹⁵: Class A had contacts in 4 support areas; Class B in 1–3 areas or in the anterior area only; Class C, with few if any remaining teeth, had no contact in any area.

Radiographic analysis

The images were obtained from 2 panoramic X-ray units (Orthophos XG 5; Sirona Dental Systems GmbH, Bensheim, Germany, and Veraview IC5 HD; J. Morita

Manufacturing Corp., Kyoto, Japan). The images were transferred to a digital archiving system (Turcasoft Software, Ltd., Samsun, Turkey).

The panoramic radiographs were assessed by 2 oral radiologists. The morphology of the inferior mandibular cortex was determined by observing both sides of the mandible distally from the mental foramen according to the criteria defined by Klemetti et al. (Fig. 1)⁵:

- C1: endosteal cortical margin even and sharp on both sides;
- C2: endosteal margin with semilunar defects (lacunar resorption) or endosteal cortical residues on one or both sides;
- C3: the cortical layer consists of heavy endosteal cortical residues and is clearly porous.

For the intra- and inter-observer reliability, 40 samples were randomly selected and the MCI measurements were reassessed over a distance of 2 weeks.

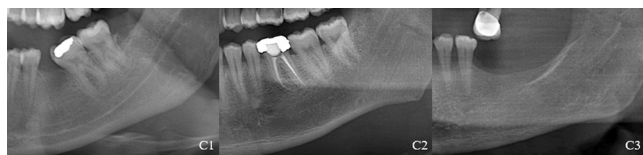

Fig. 1. Examples of the mandibular cortical index (MCI) classification (C1, C2 and C3)

Statistical analysis

The data was analyzed using the IBM SPSS Statistics v. 17.0 (IBM Corp, Armonk, USA) package. Categorical variables were compared using the χ^2 test. The independent samples *t*-test was used to compare mean values between the groups. The kappa statistic was used to evaluate the intra- and inter-observer agreements.

Multiple logistic regression analysis was used to determine whether an independent variable remained statistically significant after controlling for other confounding variables. Risk estimates were presented as odds ratios (ORs) with 95% confidence intervals (CIs). The results were considered significant if $p < 0.05$.

Results

Regarding the MCI assessments, the kappa values for the intra-observer agreements were 0.93 and 0.94, and for the inter-observer agreements – 0.82 and 0.93 in the 1st and 2nd session, respectively.

The characteristics of the sample according to the MCI classification are presented in Table 1. All 3 categories of MCI were observed; the majority (74%) demonstrated category C2, whereas the remainder was divided between categories C1 (20.7%) and C3 (5.3%). Cross-tabulation of MCI by age demonstrated an age-related pattern (χ^2 test; $p < 0.001$); the extremes of cortical appearance (categories C1 and C3) were mostly found in the extreme age groups. Significant differences were observed between the MCI categories regarding gender (χ^2 test; $p < 0.001$); categories C1 and C3 were more frequently seen in females, whereas category C2 showed an equal distribution among females and males. The MCI categories were significantly correlated with DS and EI (χ^2 test; $p < 0.001$); as the number of teeth or occlusal supporting zones decreased, categories C2 and C3 increased, whereas category C1 decreased. A statistically significant relationship was found between TM and MCI (χ^2 test; $p < 0.001$); the percentage of patients with TM in category C1 was significantly higher compared to those in categories C2 and C3.

Age, gender, DS, EI, and TM were the parameters having a significant impact on MCI. These parameters were included in multiple logistic regression analysis to assess their

Table 1. Characteristics of the sample according to the mandibular cortical index (MCI) classification

Variables	Total n	MCI			p-value
		C1 n (%)	C2 n (%)	C3 n (%)	
Age [years]	21–49	235	65 (82.3)	169 (59.9)	<0.001
	50–70	134	12 (15.2)	106 (37.6)	
	>70	12	2 (2.5)	7 (2.5)	
Gender	female	226	70 (88.6)	142 (50.4)	<0.001
	male	155	9 (11.4)	140 (49.6)	
DS	fully dentate	102	37 (46.8)	65 (23.1)	<0.001
	partially dentate	265	41 (51.9)	207 (73.4)	
	edentulous	14	1 (1.3)	10 (3.5)	
EI	Class A	245	68 (86.1)	177 (62.8)	<0.001
	Class B	102	9 (11.4)	78 (27.6)	
	Class C	34	2 (2.5)	27 (9.6)	
TM	present	109	35 (44.3)	73 (25.9)	<0.001
	absent	272	44 (55.7)	209 (74.1)	

MCI – mandibular cortical index; C1–C3 – MCI categories; DS – dental status; EI – Eichner index; TM – torus mandibularis; n – number of patients.

significance in determining an eroded mandibular cortex (MCI C2–C3). Regression analysis revealed that males (OR 9.33; 95% CI 4.29–20.30; $p < 0.001$), patients without TM (OR 2.73; 95% CI 1.49–4.99; $p < 0.001$), EI Class B (OR 2.68; 95% CI 1.11–6.42; $p = 0.027$), and patients aged 50–70 years (OR 2.50; 95% CI 1.17–5.35; $p = 0.018$) showed an increased risk of having eroded cortices (Table 2).

Table 2. Contributions of significant variables to the mandibular cortical index (MCI) categories (C2–C3)

Variables	Contributions			
	<i>p</i> -value	OR	95% CI	
Age [years]	21–49	–	1.00	–
	50–70	0.018	2.50	1.17–5.35
	>70	0.381	0.41	0.05–2.98
Gender	female	–	1.00	–
	male	<0.001	9.33	4.29–20.30
DS	fully dentate	–	1.00	–
	partially dentate	0.157	1.52	0.83–2.99
	edentulous	0.727	1.72	0.08–36.84
EI	Class A	–	1.00	–
	Class B	0.027	2.68	1.11–6.42
	Class C	0.246	4.11	0.37–44.86
TM	present	–	1.00	–
	absent	<0.001	2.73	1.49–4.99

OR – odds ratio; CI – confidence interval.

Discussion

It has been reported that the systemic environment and local factors could have an influence on the mandibular bone morphology: subjects with low BMD, older age and a reduced number of teeth may present altered mandibular cortical morphology.^{16–18} The mandibular cortical index is a simple method to assess the mandibular bone quality and possible signs of osteoporosis based on the evaluation of the cortical shape of the mandible.^{19,20} Although the MCI assessments are subjective by nature, the results of previous studies suggest that MCI has satisfactory reliability in terms of repeatability and reproducibility.^{5,12–14} In line with previous findings, this study demonstrated excellent intra- and inter-observer agreements regarding the MCI assessments.

In the present study, age, gender, dentition, and TM were the parameters significantly related to the cortical shape of the mandible (MCI). The age-related distribution of MCI in this study is consistent with the literature.^{12,13} However, we did not observe these differences in the age group >70 years, which might be attributed to the small sample size. It is well-known that the bone mineral status is related to physical and muscular activity. Moreover, bone undergoes substantial and morphological changes to adapt to its mechanical environment. An increase in age is often accompanied by a decrease in the number of teeth, which may cause lower masticatory forces, leading to low quality of the mandibular bone and higher MCI values.

In this study, males showed an increased risk of having eroded cortices (MCI C2–C3) compared to females. Our study group of patients represented a typical range of female and male patients who had undergone a panoramic radiographic examination as part of diagnostic procedures or treatment planning. Although there are conflicting results in previous studies regarding the relationship between MCI and gender,^{13,21} these discrepancies might be related to population differences (e.g., number of postmenopausal women, race) and individual variations in the rate of bone loss (e.g., body mass index – BMI, physical activity, diet, heredity).


It has been suggested that the absence of occlusal support in the premolar and molar regions reduces the transfer of occlusal forces on the mandible, which may affect the mandibular cortex and result in higher MCI values.²² In the present study, in accordance with the results of previous research,^{12–14} patients having fewer teeth were found to have higher MCI values. We are aware that precise evaluation of the occlusal function cannot be obtained solely from the number of teeth. Therefore, we examined the occlusal function using EI, which was previously used in epidemiological studies and found to be related to the masticatory ability and bite force.²³ Although the association between EI Class C and an eroded mandibular cortex was not at the level of significance (Table 2; $p = 0.246$) based on the results of multiple regression analysis, we suggest that the effect of the occlusal function on MCI is better reflected by EI rather than DS or the number of teeth.


The prevalence of TM has been correlated with the number of functioning teeth, parafunctional activity and age.^{24,25} However, the etiology and morphological significance of TM are still unclear. It is also uncertain if tori are the expression of systemic conditions or bone metabolism. On the other hand, recent knowledge emphasizes the importance of genetic and local factors on the formation of TM.^{26–30} The results of previous studies implicate common mechanisms involved in the elevation of skeletal BMD and the formation of TM.^{10,11} Our findings showing a correlation between the C1 category of MCI and the presence of TM suggest that subjects with TM may have higher skeletal bone mass and mandibular bone quality compared to subjects without TM. In the literature, there have been very few studies investigating the relationship between MCI and TM. The results of our study are in agreement with the results reported by Cortes et al.²⁸ However, the study of Uysal et al. failed to establish an association between MCI and TM.²²

Conclusions

This observational study demonstrated that gender, presence of TM, occlusal function expressed as EI, and age are related to morphological changes in the mandibular cortical bone, evaluated by means of MCI.

ORCID iDs

Nagihan Koç  <https://orcid.org/0000-0002-3339-7783>

Leyla Berna Çağırankaya  <https://orcid.org/0000-0003-0761-5166>

References

- Raisz LG. Physiology and pathophysiology of bone remodeling. *Clin Chem*. 1999;45(8 Pt 2):1353–1358.
- Consensus development conference: Diagnosis, prophylaxis, and treatment of osteoporosis. *Am J Med*. 1993;94(6):646–650.
- von Wöhrer N. General and oral aspects of osteoporosis: A review. *Clin Oral Investig*. 2001;5(2):71–82.
- Klemetti E, Vainio P, Lassila V, Alhava E. Cortical bone mineral density in the mandible and osteoporosis status in postmenopausal women. *Scand J Dent Res*. 1993;101(4):219–223.
- Klemetti E, Kolmakov S, Kröger H. Pantomography in assessment of the osteoporosis risk group. *Scand J Dent Res*. 1994;102(1):68–72.
- White SC. Oral radiographic predictors of osteoporosis. *Dentomaxillofac Radiol*. 2002;31(2):84–92.
- Savic Pavicin I, Dumancic J, Jukic T, Badel T, Badanjak A. Digital orthopantomograms in osteoporosis detection: Mandibular density and mandibular radiographic indices as skeletal BMD predictors. *Dentomaxillofac Radiol*. 2014;43(7):20130366.
- Leite AF, Figueiredo PT, Guia CM, Melo NS, de Paula AP. Correlations between seven panoramic radiomorphometric indices and bone mineral density in postmenopausal women. *Oral Surg Oral Med Oral Pathol Oral Radiol Endod*. 2010;109(3):449–456.
- Hrdlička A. Mandibular and maxillary hyperostoses. *Am J Phys Anthropol*. 1940;27(1):1–67.
- Hosoi T, Yoda T, Yamaguchi M, Amano H, Orimo H. Elderly women with oral exostoses had higher bone mineral density. *J Bone Miner Metab*. 2003;21(2):120–122.
- Hjertstedt J, Burns EA, Fleming R, et al. Mandibular and palatal tori, bone mineral density, and salivary cortisol in community-dwelling elderly men and women. *J Gerontol A Biol Sci Med Sci*. 2001;56(11):M731–735.
- Ledgerton D, Horner K, Devlin H, Worthington H. Radiomorphometric indices of the mandible in a British female population. *Dentomaxillofac Radiol*. 1999;28(3):173–181.
- Gulsahi A, Yüzügüllü B, Imirzalioglu P, Genç Y. Assessment of panoramic radiomorphometric indices in Turkish patients of different age groups, gender and dental status. *Dentomaxillofac Radiol*. 2008;37(5):288–292.
- Bozdag G, Sener S. The evaluation of MCI, MI, PMI and GT on both genders with different age and dental status. *Dentomaxillofac Radiol*. 2015;44(9):20140435.
- Yoshinaka M, Ikebe K, Furuya-Yoshinaka M, Maeda Y. Prevalence of torus mandibularis among a group of elderly Japanese and its relationship with occlusal force. *Gerodontology*. 2014;31(2):117–122.
- Taguchi A, Tanimoto K, Sui Y, Wada T. Tooth loss and mandibular osteopenia. *Oral Surg Oral Med Oral Pathol Oral Radiol Endod*. 1995;79(1):127–132.
- Kribbs PJ. Comparison of mandibular bone in normal and osteoporotic women. *J Prosthet Dent*. 1990;63(2):218–222.
- Roberts M, Yuan J, Graham J, Jacobs R, Devlin H. Changes in mandibular cortical width measurements with age in men and women. *Osteoporos Int*. 2011;22(6):1915–1925.
- Klemetti E, Kolmakow S. Morphology of the mandibular cortex on panoramic radiographs as an indicator of bone quality. *Dentomaxillofac Radiol*. 1997;26(1):22–25.
- Horner K, Devlin H. The relationships between two indices of mandibular bone quality and bone mineral density measured by dual energy X-ray absorptiometry. *Dentomaxillofac Radiol*. 1998;27(1):17–21.
- Knezović Zlatarić D, Celebić A, Lazić B, et al. Influence of age and gender on radiomorphometric indices of the mandible in removable denture wearers. *Coll Antropol*. 2002;26(1):259–266.
- Uysal S, Çağırankaya BL, Hatipoğlu MG. Do gender and torus mandibularis affect mandibular cortical index? A cross-sectional study. *Head Face Med*. 2007;3:37.
- Ikebe K, Hazeyama T, Iwase K, et al. Association of symptomless TMJ sounds with occlusal force and masticatory performance in older adults. *J Oral Rehabil*. 2008;35(5):317–323.
- Eggen S, Natvig B. Relationship between torus mandibularis and number of present teeth. *Scand J Dent Res*. 1986;94(3):233–240.
- Kerdpon D, Sirirungrojying S. A clinical study of oral tori in southern Thailand: Prevalence and the relation to parafunctional activity. *Eur J Oral Sci*. 1999;107(1):9–13.
- Eggen S. Torus mandibularis: An estimation of the degree of genetic determination. *Acta Odontol Scand*. 1989;47(6):409–415.
- De Luca Canto G, Torres de Freitas S, Schuldt Filho G, de Sousa Vieira R. Association between mandibular torus and parafunctional activity. *J Stomat Occ Med*. 2012;6(2):43–49.
- Cortes AR, Jin Z, Morrison MD, Arita ES, Song J, Tamimi F. Mandibular tori are associated with mechanical stress and mandibular shape. *J Oral Maxillofac Surg*. 2014;72(11):2115–2125.
- Al-Dwairi ZN, Al-Daqaq ANF, Kielbassa AM, Lynch E. Association between oral tori, occlusal force, and mandibular cortical index. *Quintessence Int*. 2017;48(10):841–849.
- Çağırankaya B, Hatipoğlu M, Kansu Ö. Is there an association between torus mandibularis and bite force? *J Hacettepe Univ Fac Dent*. 2005;29(4):15–17.