

Olympus and a consultant for Medtronic. The other author disclosed no financial relationships relevant to this publication.

**Majidah Bukhari, MD, FRCPC**

Division of Gastroenterology and Hepatology  
Johns Hopkins Medical Institutions  
Baltimore, Maryland, USA

Division of Medicine and Gastroenterology and Hepatology  
King Faisal Specialist Hospital and Research Center  
Jeddah, Saudi Arabia

**Mouen A Khashab, MD**

Division of Gastroenterology and Hepatology  
Johns Hopkins Medical Institutions  
Baltimore, Maryland, USA

**REFERENCES**

1. Yang D, Draganov PV. ERCP in patients with Roux-en-Y gastric bypass: one size does not fit all. *Gastrointest Endosc* 2019;89:646.
2. Bukhari M, Kowalski T, Nieto J, et al. An international, multicenter, comparative trial of EUS-guided gastrogastrostomy-assisted ERCP versus enteroscopy-assisted ERCP in patients with Roux-en-Y gastric bypass anatomy. *Gastrointest Endosc* 2018;88:486-94.
3. Abbas AM, Strong AT, Diehl DL, et al. Multicenter evaluation of the clinical utility of laparoscopy-assisted ERCP in patients with Roux-en-Y gastric bypass. *Gastrointest Endosc* 2018;87:1031-9.
4. Tyberg A, Nieto J, Salgado S, et al. Endoscopic ultrasound (EUS)-directed transgastric endoscopic retrograde cholangiopancreatography or EUS: mid-term analysis of an emerging procedure. *Clin Endosc* 2017;50:185-90.
5. Schreiner MA, Chang L, Gluck M, et al. Laparoscopy-assisted versus balloon enteroscopy-assisted ERCP in bariatric post-Roux-en-Y gastric bypass patients. *Gastrointest Endosc* 2012;75:748-56.
6. Frederiksen NA, Tveskov L, Helgstrand F, et al. Treatment of common bile duct stones in gastric bypass patients with laparoscopic transgastric endoscopic retrograde cholangiopancreatography. *Obes Surg* 2017;27:1409-13.
7. Aiolfi A, Asti E, Rausa E, et al. Trans-gastric ERCP after Roux-en-Y gastric bypass: systematic review and meta-analysis. *Obes Surg* 2018;28:2836-43.
8. Kedia P, Tarnasky PR, Nieto J, et al. EUS-directed transgastric ERCP (EDGE) versus laparoscopy-assisted ERCP (LA-ERCP) for Roux-en-Y gastric bypass (RYGB) anatomy: a multicenter early comparative experience of clinical outcomes. *J Clin Gastroenterol*. Epub 2018 Apr 17.
9. Kedia P, Tyberg A, Kumta NA, et al. EUS-directed transgastric ERCP for Roux-en-Y gastric bypass anatomy: a minimally invasive approach. *Gastrointest Endosc* 2015;82:560-5.
10. Irani S, Yang J, Khashab MA. Mitigating lumen-apposing metal stent dislodgment and allowing safe, single-stage EUS-directed transgastric ERCP. *VideoGIE* 2018;3:322-4.

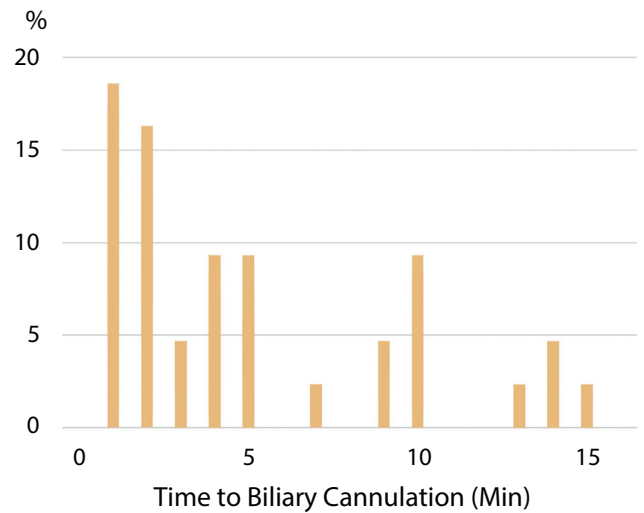
<https://doi.org/10.1016/j.gie.2018.10.033>

## Pancreatic stent during biliary cannulation: How can we catch 2 hares?

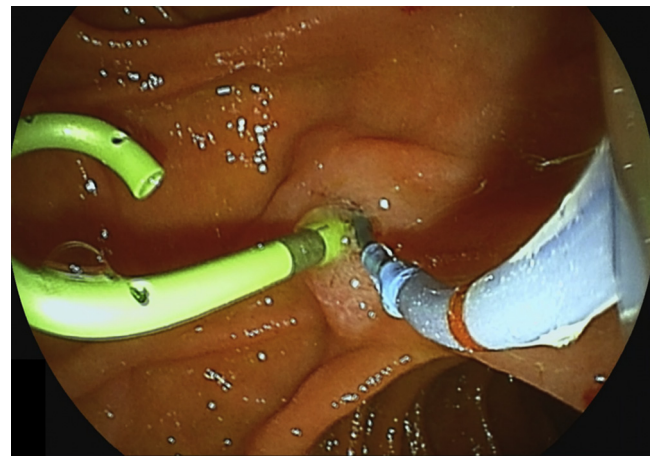


To the Editor:

Unintentional guidewire insertion to the pancreatic duct commonly occurs during biliary cannulation and provokes



**Figure 1.** Time to successful biliary cannulation during wire-guided cannulation with an indwelling pancreatic stent.



**Figure 2.** Wire-guided biliary cannulation with an indwelling pancreatic stent. We attempt to cannulate the bile duct keeping a guidewire tip outside a cannula and manipulate the guidewire when the tip is supposed to be in the biliary orifice ("the nontouch technique"). This technique is particularly helpful in patients with a small ampulla where the touch technique is difficult. In patients with an indwelling pancreatic stent, the nontouch technique helps avoid guidewire insertion into the pancreatic duct.

post-ERCP pancreatitis (PEP).<sup>1</sup> Several cannulation approaches have been reported in this setting.<sup>2,3</sup> In a recent issue of *Gastrointestinal Endoscopy*, Eminler et al<sup>4</sup> reported that the double-guidewire (DGW) method was superior to wire-guided cannulation after pancreatic stent placement (WGC-PS) in terms of the successful cannulation rate: 90% versus 54%. Notably, they proceeded to precut sphincterotomy over a pancreatic stent after 5 minutes of cannulation attempts.

We recently reported our experience with WGC-PS.<sup>5</sup> WGC-PS was associated with a lower rate of PEP compared with repeated wire-guided cannulation and had comparable final biliary cannulation rates (>95%). When we

reanalyzed our data using the endpoint of the current study,<sup>4</sup> our successful selective cannulation (<5 minutes) rate was quite similar (56%), but a substantial number of patients underwent successful cannulation thereafter (Fig. 1). Compared with the DGW method with a risk of guidewire-induced pancreatitis,<sup>6,7</sup> WGC-PS may be reasonably performed for longer than 5 minutes without a significant increase in PEP. Prior studies also suggest that an indwelling pancreatic stent may not hamper biliary cannulation,<sup>8,9</sup> and we use the so-called nontouch technique during WGC-PS, especially in patients with a small ampulla (Fig. 2).<sup>10</sup>

The rates of PEP were remarkably low in both groups in the current study, probably because of early placement of a prophylactic pancreatic stent (rather than at the end of the procedure)<sup>2,5</sup> and the expertise of the endoscopists. However, in many academic centers, trainees are involved in most ERCs, and precut sphincterotomy in 5 minutes is not always possible. Despite the established effectiveness of prophylactic pancreatic stents, stent placement at the end of the procedure may reduce its preventive effects.<sup>5</sup> Further research is warranted to identify the best cannulation strategy after early pancreatic stent placement in different settings.

## DISCLOSURE

*All authors disclosed no financial relationships relevant to this publication.*

**Ryunosuke Hakuta, MD**  
**Tsuyoshi Hamada, MD, PhD**  
**Yosuke Nakai, MD, PhD**  
 Department of Gastroenterology  
 Graduate School of Medicine  
 The University of Tokyo  
**Hiroyuki Isayama, MD, PhD**  
 Department of Gastroenterology  
 Graduate School of Medicine  
 The University of Tokyo  
 Department of Gastroenterology  
 Graduate School of Medicine  
 Juntendo University  
**Kazuhiko Koike, MD, PhD**  
 Department of Gastroenterology  
 Graduate School of Medicine  
 The University of Tokyo  
 Tokyo, Japan

## REFERENCES

1. Nakai Y, Isayama H, Sasahira N, et al. Risk factors for post-ERCP pancreatitis in wire-guided cannulation for therapeutic biliary ERCP. *Gastrointest Endosc* 2015;81:119-26.

2. Sasahira N, Kawakami H, Isayama H, et al. Early use of double-guidewire technique to facilitate selective bile duct cannulation: the multicenter randomized controlled EDUCATION trial. *Endoscopy* 2015;47:421-9.
3. Yasuda I, Isayama H, Bhatia V. Current situation of endoscopic biliary cannulation and salvage techniques for difficult cases: current strategies in Japan. *Dig Endosc* 2016;28:62-9.
4. Eminler AT, Parlak E, Koksas AS, et al. Wire-guided cannulation over a pancreatic stent method increases the need for needle-knife precutting in patients with difficult biliary cannulation. *Gastrointest Endosc* 2019;89:301-8.
5. Hakuta R, Hamada T, Nakai Y, et al. Early pancreatic stent placement in wire-guided biliary cannulation: a multicenter retrospective study. *J Gastroenterol Hepatol*. Epub 2018 Aug 27.
6. Tse F, Yuan Y, Moayyedi P, et al. Double-guidewire technique in difficult biliary cannulation for the prevention of post-ERCP pancreatitis: a systematic review and meta-analysis. *Endoscopy* 2017;49:15-26.
7. Fukasawa M, Takano S, Enomoto N. Pancreatic guidewire technique increases the risk of post-endoscopic retrograde cholangiopancreatography pancreatitis. *Dig Endosc* 2016;28:102-3.
8. Yang MJ, Hwang JC, Yoo BM, et al. Wire-guided cannulation over a pancreatic stent versus double guidewire technique in patients with difficult biliary cannulation. *BMC Gastroenterol* 2015;15:150.
9. Cote GA, Mullady DK, Jonnalagadda SS, et al. Use of a pancreatic duct stent or guidewire facilitates bile duct access with low rates of precut sphincterotomy: a randomized clinical trial. *Dig Dis Sci* 2012;57:3271-8.
10. Bassi M, Luigiano C, Ghersi S, et al. A multicenter randomized trial comparing the use of touch versus no-touch guidewire technique for deep biliary cannulation: the TNT study. *Gastrointest Endosc* 2018;87:196-201.

<https://doi.org/10.1016/j.gie.2018.09.018>

## Response:



We thank Hakuta et al<sup>1</sup> for their interest in and comments on our study.<sup>2</sup> We agree that repeated guidewire cannulation of the pancreatic duct may increase the risk of post-ERCP pancreatitis. Although there is some debate on this issue, we think that successful insertion of a prophylactic pancreatic stent, inadvertent cannulation of the side branches of the pancreatic duct, and injection of contrast material are among the determining factors. Additionally, there is some controversy about the timing of pancreatic stent insertion, which usually depends on the preference of the endoscopists. We prefer to insert a pancreatic stent immediately after biliary sphincterotomy, not at the end of the procedure.

Finally, the authors emphasized the usefulness of a nontouch technique during wire-guided cannulation over a pancreatic stent, especially in a patient with a small ampulla. The success of this technique depends on the patient's anatomy, the position of the duodenoscope, and other factors such as a papilla with a small orifice. We also prefer this technique in some cases; however, only 1 randomized trial has compared the touch and nontouch techniques with naïve papillae, and it revealed a significantly higher primary cannulation rate in favor of the touch technique, with similar adverse event rates.<sup>3</sup>