


This article was downloaded by:[ANKOS 2007 ORDER Consortium]  
On: 22 October 2007  
Access Details: [subscription number 772814176]  
Publisher: Informa Healthcare  
Informa Ltd Registered in England and Wales Registered Number: 1072954  
Registered office: Mortimer House, 37-41 Mortimer Street, London W1T 3JH, UK



## Pediatric Hematology and Oncology Incorporating the International Journal of Pediatric Hematology/Oncology

Publication details, including instructions for authors and subscription information:  
<http://www.informaworld.com/smpp/title~content=t713610311>

### AN UNUSUAL CASE OF REACTIVE LYMPHOCYTOSIS MIMICKING ACUTE LEUKEMIA

Sevgi Yetgin <sup>a</sup>, Barış Kuşkonmaz <sup>a</sup>, Selin Aytaç <sup>a</sup>, Betül Tavil <sup>a</sup>

<sup>a</sup> Department of Pediatrics, Division of Pediatric Hematology, Hacettepe University  
Faculty of Medicine, Sıhhiye, Ankara, Turkey

Online Publication Date: 01 February 2007

To cite this Article: Yetgin, Sevgi, Kuşkonmaz, Barış, Aytaç, Selin and Tavil, Betül  
(2007) 'AN UNUSUAL CASE OF REACTIVE LYMPHOCYTOSIS MIMICKING  
ACUTE LEUKEMIA', Pediatric Hematology and Oncology, 24:2, 129 - 135

To link to this article: DOI: 10.1080/08880010601069948

URL: <http://dx.doi.org/10.1080/08880010601069948>

PLEASE SCROLL DOWN FOR ARTICLE

Full terms and conditions of use: <http://www.informaworld.com/terms-and-conditions-of-access.pdf>

This article maybe used for research, teaching and private study purposes. Any substantial or systematic reproduction, re-distribution, re-selling, loan or sub-licensing, systematic supply or distribution in any form to anyone is expressly forbidden.

The publisher does not give any warranty express or implied or make any representation that the contents will be complete or accurate or up to date. The accuracy of any instructions, formulae and drug doses should be independently verified with primary sources. The publisher shall not be liable for any loss, actions, claims, proceedings, demand or costs or damages whatsoever or howsoever caused arising directly or indirectly in connection with or arising out of the use of this material.

## Case Report

### AN UNUSUAL CASE OF REACTIVE LYMPHOCYTOSIS MIMICKING ACUTE LEUKEMIA

**Sevgi Yetgin, Barış Kuşkonmaz, Selin Aytaç, and Betül Tavil** □ *Hacettepe University Faculty of Medicine, Department of Pediatrics, Division of Pediatric Hematology, Sıhhye, Ankara, Turkey*

□ *The diagnosis of acute leukemia is based on a combination of clinical, hematological, morphological, cytogenetic, and immunophenotypic data. The authors report a case of reactive lymphocytosis with extremely elevated lymphocytic and lymphoblastic leukocytosis that mimicked acute lymphoblastic leukemia, not only morphologically, but also in immunophenotypic analysis. They could not determine any underlying disease marker other than infectious symptoms that were present for 20 days prior to presentation to their clinic. Although this case presented with extremely high lymphocytic leukocytosis, the patient had normal blood cell lineage, a moderate level of blastic cells in bone marrow, and normal physical findings. These findings convinced the authors to follow up the patient before beginning treatment.*

**Keywords** acute leukemia, reactive lymphocytosis

The diagnosis of acute leukemia is largely based on morphological assessment of peripheral blood and bone marrow cells. The second requirement for diagnosis of acute leukemia, especially that of acute lymphoblastic leukemia (ALL), is that the blasts must be equal to or exceed 30% in the bone marrow. However, the final diagnosis of an acute leukemia must be based on a combination of the clinical, hematological, morphological, cytochemical, and immunophenotypic data.

Reactive lymphocytosis that presents as immature lymphocytes, i.e., hematogones, in the marrow is the hallmark of several infections especially acute viral infections such as Epstein-Barr virus (EBV), cytomegalovirus (CMV), acquired immune deficiency, and hepatitis. It can also be associated with immune neutropenias, reaction to some drugs (i.e., diphenylhydantoin), and bone marrow recovering from chemotherapy [1–13]. Hematogones are identified in most marrow specimens, especially in the

Received 1 May 2006; accepted 10 October 2006.

Address correspondence to Sevgi Yetgin, MD, Professor in Pediatric Hematology, Hacettepe University Faculty of Medicine, Department of Pediatrics, Division of Pediatric Hematology, Sıhhye, Ankara, Turkey 06100. E-mail: yetgins@superonline.com

childhood period and the numbers decrease with age [11, 12]. In such cases, lymphocyte morphology in general is dramatically different from what is seen in normal controls. This distinctive type of immature lymphocytosis in blood and bone marrow can be confused with ALL. Lymphocyte precursor cells, termed hematogones, have scant cytoplasm and dense homogeneous nuclear chromatin with absent or indefinite nucleoli. In addition, their immunophenotype (CD45<sup>+</sup>, CD19<sup>+</sup>, CD10<sup>+</sup>, TdT<sup>+/-</sup>, and surface immunoglobulin<sup>-</sup>) is similar to that of pre-B lymphoblasts [5]. However, with four-color flow cytometry using optimal antibody combinations, distinction from neoplastic lymphoblasts can nearly always be made [11, 12].

The duration of reactive lymphocytosis can range from weeks to months, depending on the etiological and host factors. Here in, we report a pediatric case of reactive lymphocytosis with extremely high white blood cell (WBC) count, which mimicked ALL with extreme features based on morphological and immunophenotyping analysis.

### CASE REPORT

A 26-month-old boy, who was admitted to the Pediatric Hematology Department of Hacettepe Medical Center, had been previously diagnosed with ALL at the referring hospital. He presented with interval fever, mucoid diarrhea, weight loss, and sweating, which had persisted for 20 days. His family history was unremarkable (2 sisters, 2 brothers, and nonconsanguineous parents).

Physical examination revealed cervical 5 microlymphadenopathies with size ranging between 0.5 and 0.8 cm; the liver was palpable 3 cm under the right costal margin; and splenomegaly caused obliteration of Traube's space. Body weight and height were 13.5 kg and 90 cm, respectively (50th–75th percentile). The results of laboratory examinations were as follows: hemoglobin (Hb) 13.2 g/dL; platelet (Plt)  $392 \times 10^9/L$ ; WBC count  $135 \times 10^9/L$  with a differential count of 20% lymphoblasts, 70% lymphocytes, 6% monocytes, and 4% neutrophils (Table 1). Bone marrow (BM) aspiration smear (Figure 1) revealed 45% lymphoblasts, 30% lymphocytes, 5% promyelocytes, 7% myelocytes, and 13% normoblasts with the presence of megakaryocytes

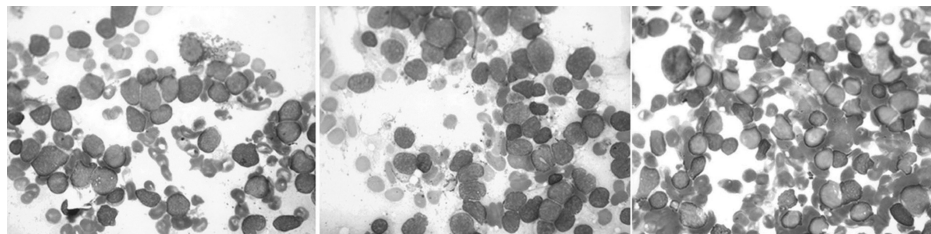


FIGURE 1 Bone marrow smear of patient.

**TABLE 1** Laboratory findings of patient

Hemoglobin	13.2 g/dl
Platelet	$392 \times 10^9/L$
White blood cells	$135 \times 10^9/L$
Peripheral blood smear	
Lymphoblast	20%
Lymphocyte	70%
Monocytes	6%
Neutrophils	4%
Bone marrow aspiration	
Lymphoblast	45%
Lymphocyte	30%
Promyelocyte	5%
Myelocyte	7%
Normoblast	13%
Serologic examinations	
EBV EBNA IgM	Negative
EBV VCA IgM	Negative
EBV VCA IgG	Positive
EBV EA	Negative
CMV IgM	Negative
CMV IgG	Positive
Parvovirus PCR	Negative
Hepatitis A virus IgM	Negative
Hepatitis A virus IgG	Positive
HBs antigen	Negative
Anti-HBs	Positive
Hepatitis C viruses	Negative
HSV type I IgM	Negative
HSV type I IgG	Positive
HSV type II IgM	Negative
HSV type II IgG	Negative
Salmonella agglutination	Negative
Brucella agglutination	Negative
IgG	614 mg/dl
IgM	72.3 mg/dl
IgA	538 mg/dl

EBV: Epstein-Barr virus, EBNA: EBV-determined nuclear antigen EA: Early antigen, VCA: viral capsid antigen. CMV: Cytomegalovirus, HSV: Herpes simplex virus, Ig: Immunoglobuline.

(Table 1). The phenotype of the BM blasts, which was based on gating by CD45 SSC analysis, revealed HLA-DR 70%, CD45 85%, CD19 66%, CD20 40%, CD22 68%, CD10 69%, CD3 11%, CD5 11%, CD7 11%, CD2 13%, CD34 8%, CD117 2%, and CD13 3% (Figure 2). Bone marrow cytogenetic examination was normal. Urinalysis and renal and liver function tests were normal, except for alanine aminotransferase (67 U/L). Serological studies were found to be negative or consistent with prior exposure to the following: EBV, CMV, parvovirus B19, hepatitis A, B, and C viruses, human herpes simplex type I and type II, human immunodeficiency virus, *Salmonella*, and *Brucella* (Table 1). Cerebrospinal fluid showed  $300/mm^3$  lymphocytes with normal protein and glucose levels.

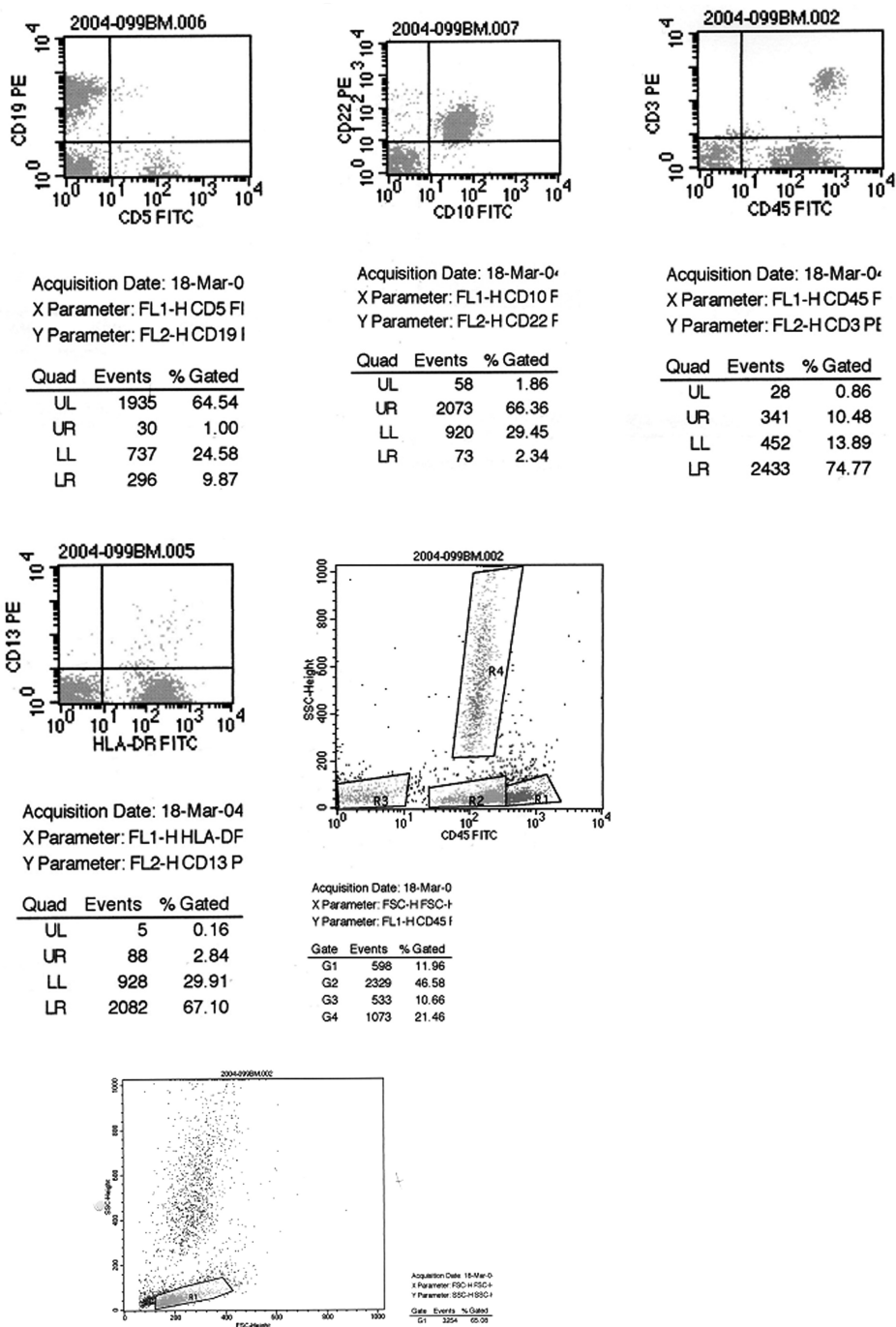


FIGURE 2 Flow cytometric analysis of patient.

The serum immunoglobulin levels of IgG, IgM, and IgA were within normal levels (Table 1). Lymphocyte subsets were determined to be in the normal ratio (CD3: 49%, CD4: 41%, CD4: 29%, CD8: 20%, CD18: 73%, and CD11b: 99%). Microscopic examinations as well as cultures of urine and feces, echocardiographic examination, and plain chest radiogram were all normal. Abdominal ultrasonography determined liver and spleen size were larger than normal by 1.8 and 1 cm, respectively.

Our findings and the patient's history, which included fever and diarrhea 4–5 times per day, suggested that he also had a concurrent infection. He received intravenous fluid treatment for gastroenteritis. After 2 days of observation, his WBC count declined to  $106 \times 10^9/L$  and his body temperature was normal. Over the following 6 days, he remained clinically stable, and WBC counts gradually dropped to  $20 \times 10^9/L$  within 2 weeks; blast cells also decreased in the peripheral blood and second BM (5%). He was then discharged from the hospital and scheduled for monthly follow-up. During 15 months of follow-up, he had continuously high WBC level (mean:  $19.7 \times 10^9/L$ ; range:  $16.9 \times 10^9/L$  to  $23.1 \times 10^9/L$ ) with a normal differential count, and both Hb and Plt levels were mildly high (Hb/Hct: range 11.7–14.1 g/dL, 35.7–40.9%; Plt: range  $373$ – $539 \times 10^9/L$ ), though they were at times normal.

## DISCUSSION

We present the case of a 26-month-old boy with a very high lymphocytic WBC count, in whom the presence of prominent lymphoblasts challenged our diagnostic abilities. The blastic character of the lymphoid cells was determined by peripheral blood smear (20%), BM morphology (45%), and with BM flow cytometric analysis showing a typical CD45/SSC and CD10 positivity. CD45/SSC analysis was used to identify CD45-positive and -negative blast populations as well as CD45 bright lymphoid cells. Morphologic blast count correlated with the percentage of CD10-positive cells.

Our first step was to exclude the existence of any infection superimposed onto leukemia, and no evidence of viral or bacterial infection was found after extensive examinations. WBC count showed a declining trend from  $132 \times 10^9/L$  to  $59 \times 10^9/L$  over the 6 days the patient was under our observation. He was in good physical condition and his gastroenteritis improved.

A variety of hematological disorders, early infancy, postchemotherapeutic stage, administration of certain drugs and bone marrow regenerative stage are all associated with the presence of cells mimicking lymphoblasts, which are also known hematogones [5–10]. A persistent elevation in hematogones may be observed in ALL patients after cessation of chemotherapy [11, 13]. These authors have also pointed out that increased marrow hematogones

may cause diagnostic confusion following treatment for ALL since they are expanded in regenerating marrow and can potentially be mistaken for residual diseases. This is also the case in post-stage of bone marrow transplantation [11]. Using four-color flow cytometry, McKenna et al. revealed that in all instances, the hematogone population exhibited a typical complex spectrum of antigens that defines the normal evaluations of B-cell precursors. Furthermore, they lacked aberrant or asynchronous antigen expression. Neoplastic lymphoblasts exhibit maturation arrest and over-, under-, and asynchronous expression of antigens observed on normal B-cell precursors and often expressed myeloid-associated antigens. Asynchronous expression of the earliest (CD34) and latest (CD20) antigens was not observed in the hematogone population in the two studies [11, 12]. Immunophenotypic analysis (CD10, CD22, HLA-DR, cytoplasmic  $\mu$  chain in pre-B) is an important adjunct to the morphological classification of blasts in ALL. Clonal gene rearrangements have also rarely been described in clear-cut non-neoplastic processes [14]. Our case was classified as CALLA (+) B-precursor ALL based on the results of immunophenotyping. He had had a 20-day history of fever, mucoid diarrhea, weight loss, and sweating before admission to our clinic and two blood lineages other than WBC within normal range at the time of admission and also during the follow-up period. In addition to the sound clinical picture of the patient, WBC count and lymphoblasts in peripheral blood and BM dropped rather than progressed during follow-up. This patient was particularly interesting because he had a mildly high WBC count during more than 1 year of follow-up with a normal differential ratio. Plt and Hb levels also mildly rose to or exceeded the normal limit. This finding suggested that the etiological factor, which was most probably viral infection, participated in the regulation of hematopoiesis in all lineage activities. Viral infections may affect the hematopoietic system resulting in various aberrations of hematopoiesis by deteriorating the immune system or the hematological maturation hierarchy [15–18]. Activated B cells are reported to produce molecules capable of stimulating hematopoietic hyperactivity [19–21].

In conclusion, this case report suggests that an ALL patient presenting with two normal blood cell lineages and a moderate level of blastic cells in the BM should undergo an extensive examination of historical and clinical factors associated with increased hematogones and be allowed an adequate follow-up period prior to beginning chemotherapy. The following question should be asked: Why are lymphoid hematopoietic hyperactivity and a leukemia-mimicking state not seen in all patients presenting with the same condition as mentioned above?

Factors responsible for reactive lymphocytosis might be related to an unknown patient characteristic or etiological factors, which may result in

some patients having limited proliferative capacity to regress and others to progress to ALL [15].

## REFERENCES

- [1] Blumberg RS, Schooley RT. Lymphocyte markers and infectious diseases. *Semin Hematol*. 1985;22:81-114.
- [2] Chow KC, Nacilla JQ, Witzig TE, et al. Is persistent polyclonal B lymphocytosis caused by Epstein-Barr virus? A study with polymerase chain reaction and in situ hybridization. *Am J Hematol*. 1992;41:270-275.
- [3] Caldwell CW, Poje E, Cooperstock M. Expansion of immature thymic precursor cells in peripheral blood after acute marrow suppression. *Am J Clin Pathol*. 1991;95:824-827.
- [4] Caldwell CW, Poje E, Helikson MA. B-cell precursors in normal pediatric bone marrow. *Am J Clin Pathol*. 1991;95:816-823.
- [5] Foucar K. Reactive lymphoid proliferations in blood and bone marrow. In: Foucar K, ed. *Bone Marrow Pathology*. Chicago: ASCP Press; 1994:255-273.
- [6] Vogel P, Erf LA, Rosenthal N. Hematological observations on bone marrow obtained by sternal picture. *Am J Clin Pathol*. 1937;7:436-447.
- [7] Brunning RD, McKenna RW. Bone marrow manifestations of malignant lymphoma and lymphoma-like conditions. *Pathol Annu*. 1979;14:1-59.
- [8] Greaves MF, Delia D, Janossy G, et al. Acute lymphoblastic leukemia associated antigen, IV: expression on non-leukemia lymphoid cells. *Leuk Res*. 1980;4:15-26.
- [9] Muehleck SD, McKenna RW, Gale PF, Brunning RD. Terminal deoxynucleotidyl transferase (TdT)-positive cells in bone marrow in the absence of hematologic malignancy. *Am J Clin Pathol*. 1983;79:277-284.
- [10] Longacre TA, Foucar K, Crago S, et al. Hematogones: a multiparameter analysis of bone marrow precursor cells. *Blood*. 1989;73:543-552.
- [11] McKenna RW, Washington LT, Aquino DB. Immunophenotypic analysis of hematogones (B-lymphocyte precursors) in 662 consecutive bone marrow specimens by 4-color flow cytometry. *Blood*. 2001;98:2498-2507.
- [12] McKenna RW, Asplund SL, Kroft SH. Immunophenotypic analysis of hematogones (B-lymphocyte precursors) and neoplastic lymphoblasts by 4-color flow cytometry. *Leuk Lymphoma*. 2004;45:277-285.
- [13] van Wering ER, van der Linden-Schrever BE, Szczepanski T, et al. Regenerating normal B-cell precursors during and after treatment of acute lymphoblastic leukaemia: implications for monitoring of minimal residual disease. *Br J Haematol*. 2000;110:139-146.
- [14] Strickler JG, Movahed LA, Gajl-Peczalska KJ, et al. Oligoclonal T cell receptor gene rearrangements in blood lymphocytes of patients with acute Epstein-Barr virus-induced infectious mononucleosis. *J Clin Invest*. 1990;86:1358-1363.
- [15] Yetgin S, Cetin M, Aslan D, et al. Parvovirus B19 infection presenting as pre-B-cell acute lymphoblastic leukemia: a transient and progressive course in two children. *J Pediatr Hematol Oncol*. 2004;26:689-692.
- [16] Yetgin S, Cetin M, Yenicesu I, et al. Acute parvovirus B19 infection mimicking juvenile myelomonocytic leukemia. *Eur J Haematol*. 2000;65:276-278.
- [17] Yetgin S, Cetin M, Ozyurek E, et al. Parvovirus B19 infection associated with severe aplastic anemia in an immunocompetent patient. *Pediatr Hematol Oncol*. 2004;21:223-226.
- [18] Yenicesu I, Yetgin S, Ozyurek E, et al. Virus-associated immune thrombocytopenic purpura in childhood. *Pediatr Hematol Oncol*. 2002;19:433-437.
- [19] Kishimoto T. B-cell stimulatory factors (BSFs): molecular structure, biological function, and regulation of expression. *J Clin Immunol*. 1987;7:343-355.
- [20] Uckun FM, Fauci AS, Heerema NA, et al. B-cell growth factor receptor expression and B-cell growth factor response of leukemic B-cell precursors and B lineage lymphoid progenitor cells. *Blood*. 1987;70:1020-1034.
- [21] Niskanen E, Gorman J, Isakson PC. Hematopoietic precursors respond to a unique B lymphocyte-derived factor in vivo. *Blood*. 1987;70:1784-1789.