

## CASE REPORT

# A complex suicide by vehicle assisted ligature strangulation and wrist-cutting



Ramazan Akçan<sup>a,\*</sup>, Ali Eren<sup>b</sup>, Mahmut Şerif Yıldırım<sup>a</sup>, Necmi Çekin<sup>c</sup>

<sup>a</sup> Hacettepe University Faculty of Medicine, Department of Forensic Medicine, Ankara, Turkey

<sup>b</sup> Adana Group Administration of The Council of Forensic Medicine, Adana, Turkey

<sup>c</sup> Cukurova University Faculty of Medicine, Department of Forensic Medicine, Adana, Turkey

Received 25 February 2016; revised 8 June 2016; accepted 27 June 2016

Available online 18 July 2016

### KEYWORDS

Complex suicide;  
Vehicle assisted strangulation;  
Wrist-cutting;  
Crime scene

**Abstract** *Background:* Complex suicide defines the type of suicide involving using more than one suicide methods to lead to death. Second method is used to escape from pain or to prevent failure of the first method. Here we present a case of unusual complex suicide case by vehicle assisted ligature strangulation and wrist-cutting.

*Case:* A 38 year-old male was found dead in his automobile at roadside out of his hometown. At crime scene investigation, driver side window was open and a ligature surrounding the victim's neck was attached to a tree 8 m behind the car. The victim's shirt and trousers were blood soaked due to bleeding from wrist cuts. There was a suicide note on the front panel of the car. At external examination there was a ligature mark, 1 cm in width, gently sloping upward toward the notch at left side of occipital region. Additionally, multiple wrist-cuts of approximately 5 cm in length were noticed on anterior side of both wrists. There was no injury of thyroid cartilage or hyoid bone, in internal examination. There was a soft tissue hemorrhage with 0.5 cm diameter around left greater horn of the thyroid cartilage. There was no injury of ulnar or radial vessels. No traces of alcohol or drugs were detected in toxicological analyses. Death was attributed to vehicle assisted ligature strangulation.

*Conclusion:* A complete forensic investigation revealed the case was an unusual complex suicide by vehicle assisted ligature strangulation and wrist-cutting. The case was interesting in terms of involving car assisted ligature strangulation.

© 2016 The International Association of Law and Forensic Sciences (IALFS). Production and hosting by Elsevier B.V. This is an open access article under the CC BY-NC-ND license (<http://creativecommons.org/licenses/by-nc-nd/4.0/>).

## 1. Introduction

The term “complex suicide” is described as the type of suicide involving more than one method to complete suicide.<sup>1–4</sup> Purpose of the use of a second method is to get a safeguard in the case of fail in “primary complex suicides”, and to get over the pain caused by the first method and accelerate death in “secondary complex suicides”.<sup>1,3,4</sup>

\* Corresponding author at: Hacettepe University Medical Faculty, Department of Forensic Medicine, 06100 Ankara, Turkey.

E-mail address: [akcanmd@hotmail.com](mailto:akcanmd@hotmail.com) (R. Akçan).

Peer review under responsibility of The International Association of Law and Forensic Sciences (IALFS).

<http://dx.doi.org/10.1016/j.ejfs.2016.06.009>

2090-536X © 2016 The International Association of Law and Forensic Sciences (IALFS). Production and hosting by Elsevier B.V. This is an open access article under the CC BY-NC-ND license (<http://creativecommons.org/licenses/by-nc-nd/4.0/>).

The combination of consumption of medications, hypnotics in particular, with hanging, drowning, and suffocation, and combination of firearms with drowning and hanging are among the most commonly reported complex suicide combinations in the literature.<sup>1,4-7</sup> On the other hand, there are less common combinations such as hanging and electric shock, wrist-cutting and firearms, medication overdose and use of sharp instrument, medication overdose and LPG inhalation, firearms and self-immolation, and hanging and burning.<sup>1,2,4,7,8</sup>

Here we present a case of unusual complex suicide case by vehicle assisted ligature strangulation and wrist-cutting.

## 2. Case

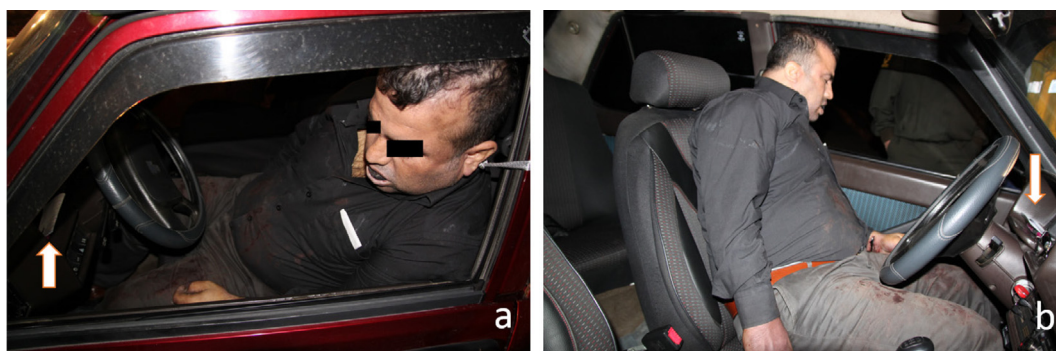A 38 year old male was found dead in his automobile at roadside out of his hometown. At death scene investigation, driver side window was open and a ligature surrounding the victim's neck was attached to a tree 8 m behind the car (Fig. 1a-d). The

car engine was stopped. There were tire marks/traces on ground, which were compatible with tires of the victim's car. The victim's shirt and trouser were blood soaked due to bleeding from wrist cuts (Fig. 2a and b). There was a suicide note and a pen on the front panel of the car (Fig. 2a and b). The suicide note was addressed to the victim's family and it expresses that he has lied to them, he has insufficient money to buy a house, and the note was ending with request of forgiveness. The identity card of the victim was in his shirt's pocket. Death scene investigation did not reveal findings related to struggling or existence of a second person at the scene. Notes indicating thoughts about meaninglessness of life were noticed in social media accounts of the victim.

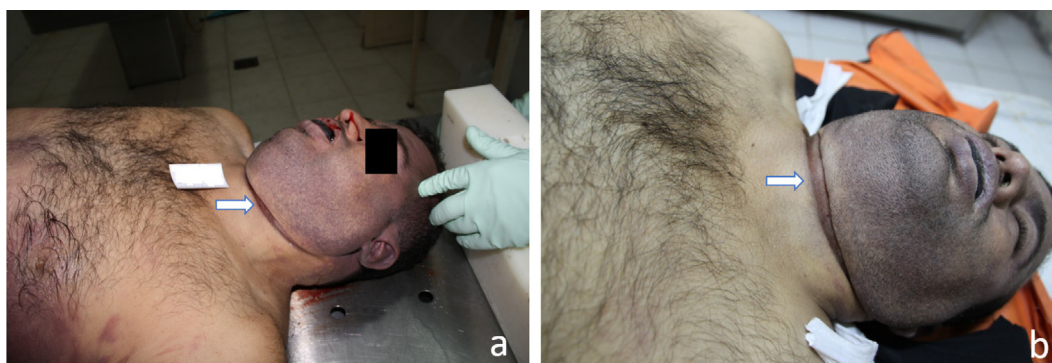At external examination there was a ligature mark, with 1 cm width, gently sloping upward toward the notch at left side of occipital region (Fig. 3a and b). Additionally, multiple wrist-cuts of approximately 5 cm in length were noticed on anterior side of both wrists (Fig. 4a and b). The wrist cuts were



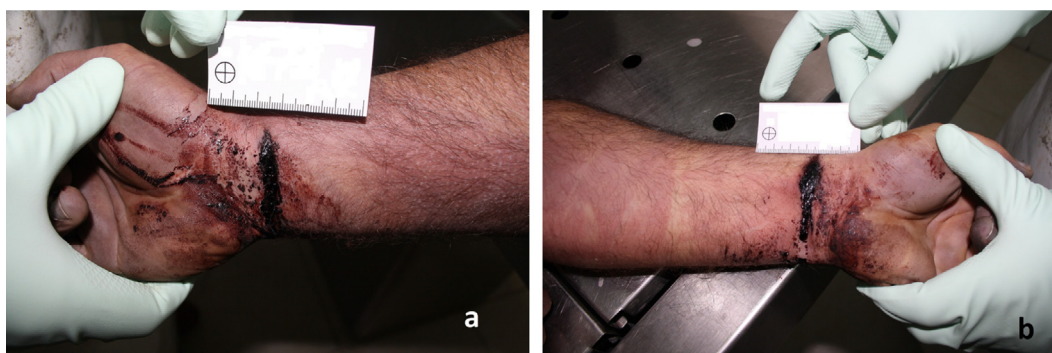
**Figure 1** (a-d) Scene of death.



**Figure 2** (a and b) Blood on shirt and trousers, and suicide note (arrows).



**Figure 3** (a and b) Ligature mark (arrows).



**Figure 4** Multiple wrist-cuts on right (a) and left (b).

starting from lateral and ending on the medial side of wrists with superficial incisions.

There was no hemorrhage of strap muscles and no injury of thyroid cartilage or hyoid bone, in internal examination. There was a soft tissue hemorrhage with 0.5 cm diameter around left greater horn of the thyroid cartilage. There was no injury of cervical vertebrae.

There was no injury of ulnar or radial vessels, while complete and incomplete dissection and of flexor pollicis longus muscles were noticed on right and left wrists, respectively.

No traces of alcohol or drugs were detected in toxicological analyses. Death was attributed to vehicle assisted ligature strangulation.

A complete forensic investigation revealed that the case was an unusual complex suicide by vehicle assisted ligature strangulation and wrist-cutting. The case was interesting in terms of involving car assisted ligature strangulation.

### 3. Discussion

The presented case is peculiar in terms of involving a combination of uncommon methods of planned complex suicide. In planned complex suicides, the purpose of committing a second method is to avoid failure of the first method.<sup>2,6,7</sup> In such cases, death may be due to the first or second method, or both. In our case autopsy findings indicated that death was caused by the second method, vehicle assisted ligature strangulation. Marcinkowski divides suicide methods into two groups as those “causing death” and those “with no death effect”.<sup>7</sup> In

the presented case, there was no fatal injury on anterior side of both wrists, which is compatible with definition of “method with no death effect”. However, as the second method, vehicle assisted ligature strangulation, was considered as the method “causing death”.

Determining manner of death in ligature strangulation cases is a challenging issue, and such cases are reported to be mostly homicidal.<sup>9,10</sup> On the other hand, ligature strangulation cases discovered in a secured area, presence of suicide note, previous suicide ideation and attempts, history of mental illnesses, catastrophic events in the victim’s recent life, and hesitation marks/scars or other related findings on the body might be indicative of suicide.<sup>10</sup> Similarly, in our case, the deceased was found dead in his automobile out of his hometown in and unpopulated area. There were no evidences of trespassing and struggle around the car or no findings indicating the body was moved after death, in crime scene investigation. There was a suicide note, clearly stating the motive for suicide, in death scene and there was a post indicating suicide ideation and suicidality in the deceased’s social media account. Furthermore there were hesitation cuts on both wrists.

Suicide notes play an important role as evidences in criminal investigations of possible suicidal deaths<sup>11</sup> because, these notes provide a direct connection to the victim.<sup>11,12</sup> Suicide notes are mostly left at places easy to find in crime scene.<sup>11,12</sup> On the other hand, notes or messages in social media accounts might be used as suicide notes or may indicate suicidality of individuals.<sup>13</sup> Similarly, in the presented case, a suicide note was found on the front panel of the car at the death scene.

Additionally, notes indicating thoughts about meaninglessness of life were noticed in social media accounts of the victim.

To the best of our knowledge, this is the first ever case of primary complex suicide by vehicle-assisted ligature strangulation combined with wrist-cutting. Furthermore, as a sole suicide method, vehicle-assisted ligature strangulation is reported to be very uncommon.<sup>9,14–21</sup> This method might result in decapitation, in relation to width and strength of the ligature material, running engine and slope of the road. At the internal examination hemorrhages and lacerations of sternocleidomastoid muscle, hyoid bone fractures, tracheal and/or esophageal ruptures/lacerations, carotid artery lacerations/ruptures, thyroid cartilage fractures, soft tissue hemorrhages of neck, cervical vertebrae fractures, lung edema and other signs of asphyxia are among reported findings seen in vehicle-assisted ligature strangulation cases.<sup>9,14–21</sup> However, there was only a soft tissue hemorrhage, measuring 0.5 cm in diameter, around left greater horn of the thyroid cartilage.

In conclusion, the presented case is extremely uncommon in terms of involving vehicle assisted ligature strangulation combined with wrist cutting. In such cases, the manner of death should be determined based on a complete criminal investigation supported by a detailed crime scene investigation and autopsy.

#### Financial disclosure

No financial support provided for this work.

#### Conflict of interest

The author(s) has no potential conflicts of interest to be disclosed.

#### Informed consent

No informed consent was obtained.

#### Ethical approval

Necessary ethical approval was obtained from the institute ethics committee.

#### References

- Demirci S, Dogan KH, Erkol Z, Deniz I. A series of complex suicide. *Am J Forensic Med Pathol* 2009;**30**(2):152–4.
- Blanco-Pampin J, Suarez-Penaranda J, Rico-Boquete R, Concheiro-Carro L. Planned complex suicide: an unusual suicide by hanging and gunshot. *Am J Forensic Med Pathol* 1997;**18**(1):104–6.
- Özdemir Ç, Tuğcu H, Asil H, Din H. Primary complex suicide combining hanging and burn: a case report. *Bull Legal Med* 2006;**11**(2):75–9.
- Cingolani M, Tsakri D. Planned complex suicide: report of three cases. *Am J Forensic Med Pathol* 2000;**21**(3):255–60.
- Bohnert M, Rothschild MA. Complex suicides by self-incineration. *Forensic Sci Int* 2003;**131**(2):197–201.
- Bohnert M. Complex suicides. In: Tsokos M, editor. *Forensic pathology reviews*. Springer; 2005. p. 127–43.
- Marcinkowski T, Pukacka-Sokolowska L, Wojciechowski T. Planned complex suicide. *J Forensic Sci* 1974;**3**:95–100.
- Türk E, Anders S, Tsokos M. Planned complex suicide: report of two autopsy cases of suicidal shot injury and subsequent self-immolation. *Forensic Sci Int* 2004;**139**(1):35–8.
- Subirana-Domènech M, Prunés-Galera E, Galdo-Ouro M. An uncommon suicide method: self-strangulation by vehicle-assisted ligature. *Egypt J Forensic Sci* 2014;**4**(1):21–4.
- Dolinak D, Matshes E, Lew EO. *Forensic pathology: principles and practice*. Burlington, San Diego, California: Academic Press; 2005.
- Salib E, Cawley S, Healy R. The significance of suicide notes in the elderly. *Aging Ment Health* 2002;**6**(2):186–90.
- Ho T, Yip PS, Chiu C, Halliday P. Suicide notes: what do they tell us? *Acta Psychiatr Scand* 1998;**98**(6):467–73.
- Tanriverdi H, Sağır S. Lise Öğrencilerinin Sosyal Ağ Kullanım Amaçlarının Ve Sosyal Ağları Benimseme Düzeylerinin Öğrenci Başarısına Etkisi. *Adıyaman Üniversitesi Sosyal Bilimler Enstitüsü Dergisi* 2014;**18**:775–822.
- Zhao D, Ishikawa T, Quan L, Li D-R, Michiue T, Maeda H. Suicidal vehicle-assisted ligature strangulation resulting in complete decapitation: an autopsy report and a review of the literature. *Leg Med* 2008;**10**(6):310–5.
- Türk EE, Tsokos M. Vehicle-assisted suicide resulting in complete decapitation. *Am J Forensic Med Pathol* 2005;**26**(3):292–3.
- Byard RW, Gilbert JD. Cervical fracture, decapitation, and vehicle-assisted suicide. *J Forensic Sci* 2002;**47**(2):392–4.
- Racette S, Vo TT, Sauvageau A. Suicidal decapitation using a tractor loader: a case report and review of the literature. *J Forensic Sci* 2007;**52**(1):192–4.
- Samberkar PN. Motor vehicle-assisted ligature strangulation causing complete decapitation: an autopsy report. *Am J Forensic Med Pathol* 2012;**33**(1):86–7.
- Hejna P, Havel R. Vehicle-assisted decapitation: a case report. *Am J Forensic Med Pathol* 2012;**33**(1):73–5.
- Byard RW, Gilbert JD. Characteristic features of deaths due to decapitation. *Am J Forensic Med Pathol* 2004;**25**(2):129–30.
- Hejna P, Bohnert M. Decapitation in suicidal hanging–vital reaction patterns. *J Forensic Sci* 2013;**58**(1):270–7.