

# Crevicular fluid levels of interleukin-8, interleukin-17 and soluble intercellular adhesion molecule-1 after regenerative periodontal therapy

Ebru Olgun Erdemir<sup>1</sup>, Meltem Karsiyaka Hendek<sup>1</sup>, H. Gencay Keceli<sup>2</sup>, Teoman Z. Apan<sup>3</sup>

**Correspondence:** Dr. Meltem Karsiyaka Hendek  
Email: mltnkrsyk@yahoo.com

<sup>1</sup>Department of Periodontology, Faculty of Dentistry, Kirikkale University, Merkez, Kirikkale, Turkiye,  
<sup>2</sup>Department of Periodontology, Faculty of Dentistry, Hacettepe University, Sıhhiye, Ankara, Turkiye,  
<sup>3</sup>Department of Medical Microbiology, Faculty of Medicine, Kirikkale University, Merkez, Kirikkale, Turkiye

## ABSTRACT

**Objective:** The aim of this study is to evaluate the influence of regenerative periodontal therapy on clinical parameters and interleukin-8 (IL-8), IL-17 and soluble intercellular adhesion molecule-1 (sICAM-1) levels in gingival crevicular fluid (GCF) of subjects with chronic periodontitis (CP). **Materials and Methods:** Fifteen patients received demineralized freeze-dried bone allograft (DFDBA) surgically to the site of infrabony defect. Clinical periodontal indices were recorded, and GCF samples were collected at baseline and at the 6<sup>th</sup> and the 9<sup>th</sup> month after the surgery. **Results:** Except plaque index, all clinical parameters improved following surgery ( $P < 0.05$ ). The volume of GCF diminished from baseline to follow-up periods ( $P < 0.05$ ). However, no effect was observed on the total amount of IL-8, IL-17 and sICAM-1 in GCF. **Conclusion:** DFDBA improved clinical outcome in CP subjects and was effective on decreasing the volume of GCF, but no effect was determined on IL-8, IL-17 and sICAM-1. Findings did not indicate a direct relationship between biochemical parameters and periodontal healing after demineralized freeze-dried bone grafting.

**Key words:** Demineralized freeze-dried bone allograft, gingival crevicular fluid, interleukin-17, interleukin-8, soluble intercellular adhesion molecule-1

## INTRODUCTION

Since more than 50 years, researchers have focused on periodontal regeneration that is today a usual and routine procedure in supporting structures of the teeth. For this purpose, different types of bone grafts and osteoinductive or osteoconductive materials have been used.<sup>[1]</sup> Early period of bone regeneration comprises of a wound healing process including cell migration, matrix synthesis and tissue remodeling. These events are influenced by the action of various mediators guiding inflammation and angiogenesis that are crucial events in cellular responses of early healing.<sup>[2]</sup>

The interleukins (ILs) are the mediator molecules that involved in the pathogenesis of chronic periodontitis

(CP) and have been identified in gingival crevicular fluid (GCF).<sup>[3]</sup> IL-8 is a chemokine that have the potential for gathering and actuation of human granulocytes. This cytokine is secreted by various host cells, including fibroblasts, monocytes/macrophages, and lymphocytes, endothelial and epithelial cells.<sup>[4]</sup> Recent studies showed that IL-8 is produced in response to lipopolysaccharide from periodontopathogens and is associated with neutrophil related tissue destruction in pathogenesis of periodontal disease.<sup>[5,6]</sup>

The effects of IL-17 on chemokine secretion by osteoblasts were reported to have significant implications in the etiology of inflammatory bone disease including periodontitis.<sup>[7]</sup> According to the related experiments; activated CD4<sup>+</sup> T cells and

**How to cite this article:** Erdemir EO, Hendek MK, Keceli HG, Apan TZ. Crevicular fluid levels of interleukin-8, interleukin-17 and soluble intercellular adhesion molecule-1 after regenerative periodontal therapy. Eur J Dent 2015;9:60-5.

Copyright © 2015 Dental Investigations Society.

DOI: 10.4103/1305-7456.149644

neutrophils were shown to produce this cytokine.<sup>[8]</sup> IL-17 phrase was also informed to be up-regulated in cells derived from human gingivitis and periodontitis tissues *in vitro* and *in vivo*.<sup>[9]</sup>

Intercellular adhesion molecule-1 (ICAM-1) is a transmembrane protein originated from endothelium and leukocytes. The soluble form of ICAM-1 (sICAM-1) was found in GCF of the healthy patients, as well as individuals with periodontal disease and has known potent immunomodulatory and anti-inflammatory characteristics.<sup>[10,11]</sup> It has a stabilizing function in cell-cell interactions and also facilitates endothelial transmigration of leukocytes.<sup>[12]</sup> As is evident from its name, ICAM-1 has a role in intracellular signaling events; important in immune response and inflammation.<sup>[13]</sup>

Demineralized freeze-dried bone allograft (DFDBA), a regenerative bone graft material, may create a difference in some cytokines that are primarily responsible from inflammation and/or bone resorption compared with pretreatment level. Determination of these markers' profile throughout the early period of periodontal healing after application of bone grafts may exhibit their association with periodontal bone growth and development of the clinical outcomes.<sup>[14,15]</sup> Therefore, the aim of this study was to examine the effect of grafting with DFDBA on the GCF levels of IL-8, IL-17 and sICAM-1.

## MATERIALS AND METHODS

Present clinical trial was conducted among patients with CP who attended to the Periodontology Department in Kirikkale University. The ethical approval was executed by the committee from Faculty of Dentistry, Kirikkale University and an informed consent form was signed prior to initiation of the study. Inclusion criteria were in ages between 30 and 60, having at least 20 natural teeth, CP diagnosis and presence of at least one proximal endosseous defect. Identification of CP was made according to the criteria of having at least six teeth with pocket depth deeper than 5 mm and 30% periodontal bone loss in three sites of each affected tooth.<sup>[16]</sup> Individuals who have systemic disease or pregnancy, tobacco use, history of periodontal treatment in previous 6 months, history of systemic antibiotic administration within the 3 months prior to the study or any other regular medication were excluded.

Among 72 individuals, a total of 20 met the inclusion criteria and agreed to participate in the study. However, five patients exhibited bleeding on probing (BOP)  $\geq 25\%$  at re-evaluation and therefore, excluded from the study [Figure 1]. The pretreatment recordings including BOP, gingival index (GI),<sup>[17]</sup> plaque index (PI),<sup>[18]</sup> probing depth (PD) and attachment level (AL) were utilized with a calibrated periodontal

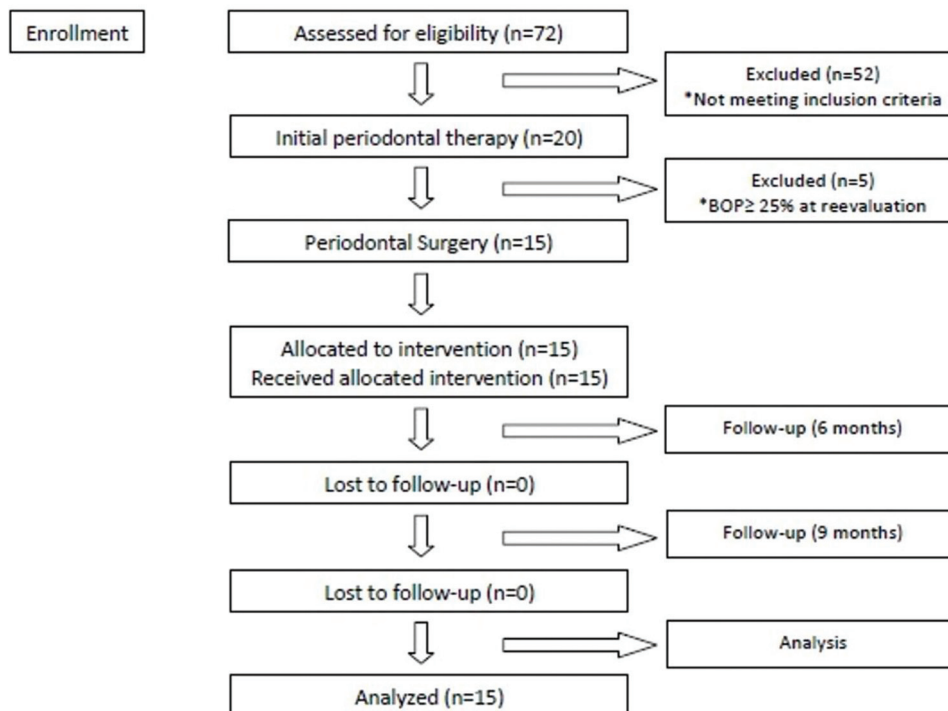


Figure 1: Flow diagram of the study

probe by one of the authors (M.K.H.). A panoramic radiograph was also obtained for each individual. GCF samples were collected at baseline from the proximal defect site of the target tooth treated with bone grafting and before the collection, supragingival plaque was gently removed. Then, the tooth was isolated with cotton rolls for keeping away from contamination, and the cervical region was gently dried with air-spray. The strips (Periopaper, Amityville, NY, USA) were placed inside the sulcus during 30 s *in situ* and then transported to a chair-side located Periotron 8000 (Oraflow Inc., Plainview, NY, USA) calibrated with known volumes of phosphate-buffered saline (PBS), for identifying GCF volume. Four strips from region of interest were immediately placed in a labeled tube containing 500 µl PBS and following 10 s vortexing and 20 min. Shaking, the tubes were centrifuged during 5 min at 5800 rpm for removing plaque and other cellular elements. After the process, the samples were placed into - 80°C freezer and stored for subsequent assays. The samples contaminated with blood were discarded. All GCF sample collection activities were performed prior to the clinical measurements. Before the surgical stage, patients received nonsurgical periodontal therapy including scaling-root planning and oral hygiene instructions. At 6 weeks after phase I treatment, PI, GI, BOP, CAL and PD were assessed once again. Patients presenting BOP  $\geq 25\%$  at reevaluation were excluded from the study.

One of the authors (E.O.E.) performed all periodontal surgical procedures. Immediately before the operation, local anesthesia was obtained by using lidocaine 2% including 1:100,000 amount of epinephrine. Buccal and lingual/palatal sulcular incisions were made, and a mucoperiosteal flap that extended from one tooth mesial to one tooth distal of the tooth of interest was elevated. Various periodontal instruments including Gracey curettes were used for defect debridement and subsequent root planning. After rinsing thoroughly with sterile saline, the defects were filled with DFDBA (LifeNet Health, Virginia Beach, VA, USA). Then, primary flap closure was provided with interdental sutures using 4-0 silk suture. Periodontal dressing (Coe-Pack, GC America, Alsip, IL, USA) was also placed over the surgical area. Postoperatively, analgesic medication was instructed to use twice a day for 3 days. 0.2% chlorhexidine digluconate (Klorhex, Drogosan, Ankara, Turkey) was prescribed, twice a day for 15 days, for plaque control. Sutures were removed 10 days following surgery and during this period, it was dictated to avoid tooth-brushing and flossing in the treated area.

Control visits were arranged every 2 weeks for the 1<sup>st</sup> months and then once a month thereafter. At each visit, the conditions of the soft tissues were examined, supragingival prophylaxis was carefully performed and oral hygiene instructions were reviewed. 6 and 9 months postsurgery, the samples of GCF were collected once again from the same sites of baseline collection, and clinical periodontal parameters were also measured.

### Statistical analysis

Normality of the data was analyzed with the Kolmogorov-Smirnov Goodness-of-Fit test in each study group. Mean values between two study groups were compared with Mann-Whitney U-test and the significance of the change between pre- and post-treatment values in each study group was evaluated with Wilcoxon matched-pair signed-rank test.  $P < 0.05$  was assumed as the acceptable level of significance in the present study.

## RESULTS

Whole study period was completed with 15 patients. No complications occurred except usual postsurgical swelling, and no wound edge necrosis or flap dehiscence existed in any patients. Eight female and seven male patients attended to the study with a mean age of 41.3 (range 30-50). All periodontal clinical measurements were shown in Table 1.

Mean values of PD, CAL and GI significantly decreased from baseline to 6 and 9 months visits. 9 months following surgery mean PD was significantly lower than its amount at 6<sup>th</sup> month ( $P < 0.05$ ). The total amounts of GCF, IL-8, IL-17 and sICAM-1 were demonstrated in Table 2.

The volume of GCF decreased from baseline to both follow-up measurements. However, there was no statistically significant difference in the total amounts of IL-8, IL-17 and sICAM-1 levels at all times.

**Table 1: The values of clinical parameters in sampling sites at baseline and follow-up visits (mean $\pm$ SD)**

Parameters	Baseline (n=15)	6 months (n=15)	9 months (n=15)
Probing depth	7.20 $\pm$ 1.32	3.53 $\pm$ 0.99*	2.93 $\pm$ 1.03* <sup>†</sup>
Attachment level	6.40 $\pm$ 1.84	3.27 $\pm$ 1.79*	3.20 $\pm$ 2.04*
Plaque index	0.60 $\pm$ 0.50	0.40 $\pm$ 0.50	0.40 $\pm$ 0.60
Gingival index	1.80 $\pm$ 0.41	0.93 $\pm$ 0.70*	0.87 $\pm$ 0.83*

Significantly different compared to baseline, \* $P < 0.05$ . Significantly different compared to 6 months follow-up, <sup>†</sup> $P < 0.05$ . SD: Standard deviation

**Table 2: The values of IL-8, IL-17 and sICAM-1 in GCF at baseline and follow-up visits (mean±SD) (ng)**

Parameters	Baseline (n=15)	6 months (n=15)	9 months (n=15)
IL-8	1.14±0.69	1.41±0.64	1.33±0.76
IL-17	1.38±0.63	1.43±0.51	1.25±0.77
sICAM-1	0.62±0.52	0.73±0.44	0.76±0.23
GCF (µl)	0.43±0.24	0.24±0.13*	0.30±0.17*

Soluble intercellular adhesion molecule-1, Gingival crevicular fluid. Significantly different compared to baseline, \* $P < 0.05$ . IL: Interleukin, SD: Standard deviation, Significantly different compared to baseline, \* $P < 0.05$ . SD: Standard deviation, IL: Interleukin, sICAM-1: Soluble intercellular adhesion molecule-1, GCF: Gingival crevicular fluid

## DISCUSSION

The present single-blind clinical trial assessed the efficacy of regenerative therapy on periodontal clinical parameters and GCF levels of IL-8, IL-17 and sICAM-1 in 15 endosseous defects of 15 patients. The defects were filled with DFDBA, and the evaluations were performed 6 and 9 months following surgical therapy. At the end of the assessments, the treatment protocol demonstrated a significant reduction in clinical variables of GI, PD and CAL. However, no change was detected in total amounts of biochemical parameters involving IL-8, IL-17 and sICAM-1 in relation with the surgical protocol.

Due to the commonly needed invasive technique and ethical considerations in histological evaluation, the most frequently preferred method to identify periodontal regeneration is measurement of PD and CAL. Although systematic review studies revealed that both conventional nonsurgical and surgical therapies are effective, regenerative treatment methods were found more successful in achieving improvements in terms of CAL gain and PD reduction.<sup>[19,20]</sup> According to the comparison between baseline and 6 and 9 months postsurgical results of the present study, mean PD decreased from  $7.20 \pm 1.32$  mm to  $3.53 \pm 0.99$  mm and  $2.93 \pm 1.03$  mm, respectively ( $P < 0.05$ ). CAL also exhibited a similar trend of reduction compared to beginning (from  $6.40 \pm 1.84$  mm to  $3.27 \pm 1.79$  mm and  $3.20 \pm 2.04$  mm, respectively) and these results were found parallel with the results of Markou *et al.*<sup>[21]</sup> and Sumer *et al.*<sup>[20]</sup>

Except a pilot study<sup>[22]</sup> that was published in 2007, no study tracking the transition of inflammation/bone loss indicators in GCF following the surgical allograft placement for infrabony defect treatment exist. Despite the detailed information given about

the short-term progress of the biochemical variables following therapy, we did not be able to encounter such information regarding the change in the amount of GCF volume from the study given above. When other studies evaluating the short-term effect of guided tissue regeneration on GCF volume were reviewed, controversial results were detected. According to these authors, it was interpreted that GCF production might have been increased in the early healing period due to the execution of the surgical intervention.<sup>[23,24]</sup> This elevation showed consistency only at the sites having nonabsorbable barrier membrane and was associated with the persistent inflammation around the material,<sup>[23,24]</sup> whereas a reduction towards the baseline values was detected in long-term evaluation of the bioabsorbable membrane.<sup>[25]</sup> In addition to other parameters, our group investigated the effects of regenerative periodontal therapy to the GCF volume and the surgical intervention involving DFDBA placement provided a significant volume decrease in long-term evaluation in correlation with the decrease in clinical parameters.

Interleukin-8 is a chemokine that is known to play a role in the periodontitis pathogenesis. When the effect of periodontal therapy is considered, decreasing GCF content of IL-8 has been determined.<sup>[26]</sup> This result was referring to the effect of nonsurgical treatment and contrarily, no remarkable IL-8 change was perceived in GCF of the individuals having surgical regenerative therapy in our investigation. Although it is not evident with the present findings, the authors commented this result as follows: The level of IL-8 during chronic inflammation period before treatment suddenly increased following development of acute inflammation with the surgical procedure and then turned back to its pretreatment level in late period with resolution of the inflammation.

It has been well-documented that periodontal inflammation process is influenced by the existence of IL-17.<sup>[9]</sup> In our study, mean total amount of IL-17 was  $1.38 \pm 0.63$  ng in CP patients and diminished to  $1.25 \pm 0.77$  ng 9 months following regenerative treatment (the difference was not statistically significant). The stable course of IL-17 following periodontal therapy showed a similar trend with the previous related literature.<sup>[27]</sup>

Soluble intercellular adhesion molecule-1 is the soluble form of a transmembrane protein that has

been thought to come up as a result of inflammation or damage of the affected tissue.<sup>[10]</sup> In the present single-blind study, there was no change in GCF total amount of sICAM-1 from baseline to 6<sup>th</sup> and 9<sup>th</sup> month posttreatment visits despite the reduction in clinical inflammation indices. Although this result is not agreeable with the possible alteration that was previously manifested, outcomes of our study had a similar trend with those of Kuru *et al.*<sup>[24]</sup> With the supporting evidence from Gunsolley *et al.*,<sup>[28]</sup> it is also important to emphasize the requirement of the higher number of individuals to be taken in our study.

Allografts have been successfully used for the treatment of osseous defects in periodontally diseased individuals. Seeing that it was principally aimed to evaluate the effect of regenerative periodontal therapy to the levels of specific biochemical parameters involving IL-8,-17 and sICAM-1, the type of the bone graft was thought as a secondary contributing factor in the selection of the variables of the present clinical and biochemical investigation. Anyhow, similar trials comparing the effects of different regenerative materials with a control group treated by conventional flap surgery on the specific biochemical parameters can be arranged. The presence of bone morphogenetic proteins contained within DFDBA aids in mesenchymal cell migration, attachment, and osteogenesis. DFDBA has both osteoinductive and osteoconductive activity and the ability to create and maintain the space.<sup>[14]</sup> Maturation of DFDBAs may take up to 8 months if used for regeneration and during this time they are important in immune response and may affect some cytokines that are primarily responsible from inflammation.

To abstain from disturbing the maturation of newly synthesized connective tissue, periodontal probing of the regenerative sites in early healing period is not recommended.<sup>[29]</sup> Thereby, clinical measurements were done before treatment and at 6 and 9 months follow-up visits in the present single-blind clinical trial. Furthermore, GCF samples were also taken at the same appointments in order to interpret the clinical and biochemical data together. Consequently, 6 and 9 months evaluations were beneficial to understand the relationship between DFDBA bone grafting and clinical-biochemical parameters. However, the influence of the treatment to the GCF volume and specific variables inside the crevicular fluid

in early healing period was not analyzed and therefore, can be indicated as a limitation of the study. Small sample size can be enumerated as the other limitation of the study.

## CONCLUSION

Within the limitations of the study, the DFDBA bone grafting improved the clinical outcome in subjects with CP and was effective on decreasing the volume of GCF, but no effect was determined on the total amount of IL-8, IL-17 and sICAM-1. All clinical and biochemical findings of our trial did not indicate a direct relationship between these biochemical parameters and late period periodontal healing after regenerative treatment including DFDBA bone grafting. Further longitudinal and randomized controlled studies are still necessary to determine the clinical values of the findings and to understand the exact roles of these molecules during periodontal disease and healing process.

## REFERENCES

1. Keles GC, Sumer M, Cetinkaya BO, Tutkun F, Simsek SB. Effect of autogenous cortical bone grafting in conjunction with guided tissue regeneration in the treatment of intraosseous periodontal defects. *Eur J Dent* 2010;4:403-11.
2. Alpiste Illueca FM, Buitrago Vera P, de Grado Cabanilles P, Fuenmayor Fernandez V, Gil Loscos FJ. Periodontal regeneration in clinical practice. *Med Oral Patol Oral Cir Bucal* 2006;11:E382-92.
3. Deo V, Bhongade ML. Pathogenesis of periodontitis: Role of cytokines in host response. *Dent Today* 2010;29:60-2.
4. Lawlor F, Camp R, Greaves M. Epidermal interleukin 1 alpha functional activity and interleukin 8 immunoreactivity are increased in patients with cutaneous T-cell lymphoma. *J Invest Dermatol* 1992;99:514-5.
5. Yoshimura A, Hara Y, Kaneko T, Kato I. Secretion of IL-1 beta, TNF-alpha, IL-8 and IL-1ra by human polymorphonuclear leukocytes in response to lipopolysaccharides from periodontopathic bacteria. *J Periodontol* 1997;32:279-86.
6. Bickel M. The role of interleukin-8 in inflammation and mechanisms of regulation. *J Periodontol* 1993;64:456-60.
7. Ruddy MJ, Shen F, Smith JB, Sharma A, Gaffen SL. Interleukin-17 regulates expression of the CXC chemokine LIX/CXCL5 in osteoblasts: Implications for inflammation and neutrophil recruitment. *J Leukoc Biol* 2004;76:135-44.
8. Ferretti S, Bonneau O, Dubois GR, Jones CE, Trifilieff A. IL-17, produced by lymphocytes and neutrophils, is necessary for lipopolysaccharide-induced airway neutrophilia: IL-15 as a possible trigger. *J Immunol* 2003;170:2106-12.
9. Takahashi K, Azuma T, Motohira H, Kinane DF, Kitetsu S. The potential role of interleukin-17 in the immunopathology of periodontal disease. *J Clin Periodontol* 2005;32:369-74.
10. Molé N, Kennel-de March A, Martin G, Miller N, Béné MC, Faure GC. High levels of soluble intercellular adhesion molecule-1 (ICAM-1) in crevicular fluid of periodontitis patients with plaque. *J Clin Periodontol* 1998;25:754-8.
11. Yusuf-Makagiansar H, Anderson ME, Yakovleva TV, Murray JS, Siahaan TJ. Inhibition of LFA-1/ICAM-1 and VLA-4/VCAM-1 as a therapeutic approach to inflammation and autoimmune diseases. *Med Res Rev* 2002;22:146-67.
12. Springer TA. Adhesion receptors of the immune system. *Nature* 1990;346:425-34.

13. Seth R, Raymond FD, Makgoba MW. Circulating ICAM-1 isoforms: Diagnostic prospects for inflammatory and immune disorders. *Lancet* 1991;338:83-4.
14. Xiao Y, Parry DA, Li H, Arnold R, Jackson WJ, Bartold PM. Expression of extracellular matrix macromolecules around demineralized freeze-dried bone allografts. *J Periodontol* 1996;67:1233-44.
15. Shigeyama Y, D'Errico JA, Stone R, Somerman MJ. Commercially-prepared allograft material has biological activity *in vitro*. *J Periodontol* 1995;66:478-87.
16. Armitage GC. Development of a classification system for periodontal diseases and conditions. *Ann Periodontol* 1999;4:1-6.
17. Loe H, Silness J. Periodontal disease in pregnancy. I. Prevalence and severity. *Acta Odontol Scand* 1963;21:533-51.
18. Silness J, Loe H. Periodontal disease in pregnancy. II. Correlation between oral hygiene and periodontal condition. *Acta Odontol Scand* 1964;22:121-35.
19. Heitz-Mayfield LJ. How effective is surgical therapy compared with nonsurgical debridement? *Periodontol* 2000 2005;37:72-87.
20. Sumer M, Keles GC, Cetinkaya BO, Balli U, Pamuk F, Uckan S. Autogenous cortical bone and bioactive glass grafting for treatment of intraosseous periodontal defects. *Eur J Dent* 2013;7:6-14.
21. Markou N, Pepelassi E, Kotsovilis S, Vrotsos I, Vavouraki H, Stamatakis HC. The use of platelet-rich plasma combined with demineralized freeze-dried bone allograft in the treatment of periodontal endosseous defects: A report of two clinical cases. *J Am Dent Assoc* 2010;141:967-78.
22. Preston RD, Meinberg TA, Payne JB, Schmid MJ, Lee HM, Golub LM, *et al.* Inflammatory mediator release following bone grafting in humans: A pilot study. *J Clin Periodontol* 2007;34:797-804.
23. Yan F, Marshall R, Wynne S, Xiao Y, Bartold PM. Glycosaminoglycans in gingival crevicular fluid of patients with periodontal class II furcation involvement before and after guided tissue regeneration. A pilot study. *J Periodontol* 2000;71:1-7.
24. Kuru L, Griffiths GS, Petrie A, Olsen I. Changes in transforming growth factor-beta1 in gingival crevicular fluid following periodontal surgery. *J Clin Periodontol* 2004;31:527-33.
25. Said S, Mohd H, Sander L, Rönkä H, Sorsa T, Kinane DF. GCF levels of MMP-3 and MMP-8 following placement of bioresorbable membranes. *J Clin Periodontol* 1999;26:757-63.
26. Gamonal J, Acevedo A, Bascones A, Jorge O, Silva A. Levels of interleukin-1 beta, -8, and -10 and RANTES in gingival crevicular fluid and cell populations in adult periodontitis patients and the effect of periodontal treatment. *J Periodontol* 2000;71:1535-45.
27. Emingil G, Gürkan A, Atilla G, Kantarci A. Subantimicrobial-dose doxycycline and cytokine-chemokine levels in gingival crevicular fluid. *J Periodontol* 2011;82:452-61.
28. Gunsolley JC, Elswick RK, Davenport JM. Equivalence and superiority testing in regeneration clinical trials. *J Periodontol* 1998;69:521-7.
29. Slots J, MacDonald ES, Nowzari H. Infectious aspects of periodontal regeneration. *Periodontol* 2000 1999;19:164-72.

Access this article online	
<p><b>Quick Response Code:</b></p> 	<p><b>Website:</b> www.eurjdent.com</p> <hr/> <p><b>Source of Support:</b> This study was supported by the grant BAPK 2007/20 from Research Foundation of Kirikkale University.</p> <p><b>Conflict of Interest:</b> None declared</p>