



ELSEVIER

INTERNATIONAL  
JOURNAL OF SURGERY

www.theijs.com

# Two unusual presentations of appendiceal masses

Baris D. Yildiz\*, Osman Abbasoglu<sup>a</sup>

Hacettepe University, Faculty of Medicine, General Surgery Department, 06100 Ankara, Turkey

Available online 24 October 2006

## KEYWORDS

Appendix;  
Appendicitis;  
Mucocele;  
Elderly

**Abstract** Appendix is one of the most common organs harboring intra-abdominal pathologies both in acute and chronic settings. Appendiceal diseases in elderly population is hard to differentiate owing to the age related changes and wide spectrum of differential diagnosis. Even uncomplicated diseases of the appendix can have features mimicking a neoplasm. Here we present two cases of appendiceal masses.

First case presented with symptoms and findings of an invasive neoplasm and the second case had findings of a pelvic mass. Both cases were treated successfully.

© 2006 Published by Elsevier Ltd on behalf of Surgical Associates Ltd.

## Introduction

Appendiceal pathologies mainly include acute appendicitis and appendiceal tumors. The most common acute abdominal emergency seen in developed countries is related to the appendix. Typical signs and symptoms of appendiceal diseases range from periumbilical pain, nausea, fever, and leukocytosis to intra-abdominal mass. The exact anatomic location of the appendix can be at any point on a 360-degree circle surrounding the base of the cecum and this accounts for the variations in the location of the abdominal pain in acute appendicitis. The most common appendiceal neoplasms are carcinoid tumor, adenocarcinoma and mucocele. These patients usually present with signs of acute appendicitis but a neoplasm may be diagnosed incidentally during an imaging study or operative procedures for other

reasons.<sup>1</sup> In this study, we present two cases of appendiceal pathologies with atypical symptoms and findings.

## Case reports

### Case 1

A 61-year-old female patient presented with weight loss, abdominal pain, vomiting and dysuria. She had been suffering from right lower quadrant pain for three months and had 3 kg of weight loss during this period. She had been prescribed a non-steroid anti-inflammatory drug for back pain a week before her complaints started. She did not have any co-morbid diseases. On physical examination there was minimal tenderness in the right lower quadrant. Systemic examination was unremarkable. Complete blood count and blood biochemistry tests were within normal limits. Tumor markers including carcinoembryogenic antigen and CA 19-9 were normal. Abdominal ultrasonography (US) did not show any positive findings. Upper gastrointestinal endoscopy revealed antral gastritis, minimal hiatal hernia and type I esophagitis. The colonoscopic examination was normal. A computed tomography (CT) scan was performed that

\* Corresponding author. Selanik cad 29/2 kizilay, 06650 Ankara, Turkey. Tel.: +90 312 419 28 30; fax: +90 312 424 15 20.

E-mail addresses: barisy@hacettepe.edu.tr, baris104@yahoo.com (B.D. Yildiz), osmanabbasoglu@yahoo.com (O. Abbasoglu).

<sup>a</sup> Tel.: +90 312 305 16 77.

showed a  $3.6 \times 2.1$  cm spiculating mass in right parailiac region close to the ileocecal valve (Fig. 1). The mass seemed to originate from small bowel wall and was compressing the right ureter and causing dilation of the proximal two-thirds of the ureter. The patient was operated on with presumptive diagnosis of small bowel cancer. After ureteral catheterization, a midline laparotomy was performed. A soft tissue mass was found in the ileocecal region. After meticulous dissection it was noticed that the mass was actually a periappendicular abscess (plastrone). There were not any findings indicating a malignancy (Fig. 2). Appendectomy was done. The postoperative period was uneventful. The pathology report turned out to be a perforated appendicitis.

## Case 2

A 54-year-old female patient without any significant complaints was admitted to hospital with intra-abdominal mass. This mass was diagnosed during her routine pelvic gynecologic examination. Abdominal US revealed a cystic mass in the pelvis. Abdominal CT showed a  $6 \times 5$  cm tubular mass in the right parailiac region in close proximity to the right ovary. Complete blood count and blood biochemistry tests were within normal limits. Colonoscopy did not reveal any pathological findings.

The patient underwent laparotomy and a large mucocele was noticed originating from the tip of the appendix (Fig. 3). Appendectomy was performed. The pathologic examination confirmed the diagnosis of benign mucocele.

## Discussion

Both of our patients had clinical and radiological findings that suggested intra-abdominal mass. The first case even had typical manifestations of a neoplasm with weight loss, abdominal pain and ureteral compression. Ureteral compression causing hydronephrosis due to benign diseases is rare and includes abdominal aortic aneurysm, inflammatory bowel disease, diverticulitis and retroperitoneal fibrosis.<sup>2-4</sup> Although imaging studies including US, CT and magnetic resonance imaging may help in the differential diagnosis, the accurate diagnosis may not be possible

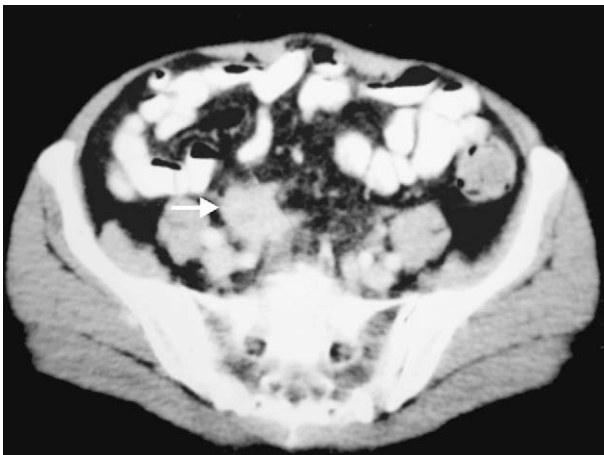


Figure 1 Open arrow shows the periappendiceal mass.

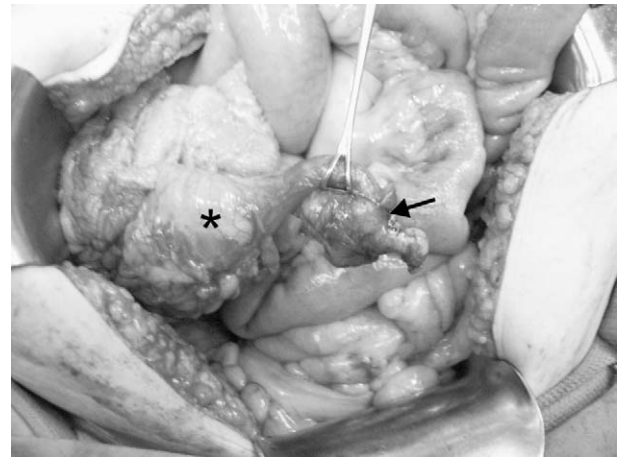

Figure 2 Asterisk shows cecum. Black arrow shows the inflamed, thickened appendix.

in some cases. The sensitivity and specificity of CT in detecting intra-abdominal pathology are between 88% and 98%, and 82% and 96%, respectively, in experienced centers.<sup>5</sup> Appendiceal tumors can mimic renal mass, ovarian carcinoma or other intra-abdominal invasive carcinomas.<sup>6-8</sup> When the age and presentation of our patients were taken into account, pessimistic expectations for neoplastic growth were to be anticipated.

Acute appendicitis has a yearly incidence of 11/10,000 with a peak incidence of 23/10,000 between the ages of 10 and 20 years.<sup>9</sup> Appendicitis is also a frequent disease in the elderly, accounting for 5% of all abdominal surgical emergencies in this population.<sup>10</sup> Classical presentation of appendicitis with abdominal pain showing typical migration from epigastrium to the right lower quadrant and mild leukocyte elevation may not be the case in a subgroup of patients.<sup>11</sup> Appendicitis in elderly deserves special attention as atypical presentations and complications are common.<sup>12</sup> Todd et al. showed that 24% of the patients older than 60 presenting with appendicitis symptoms actually had appendiceal

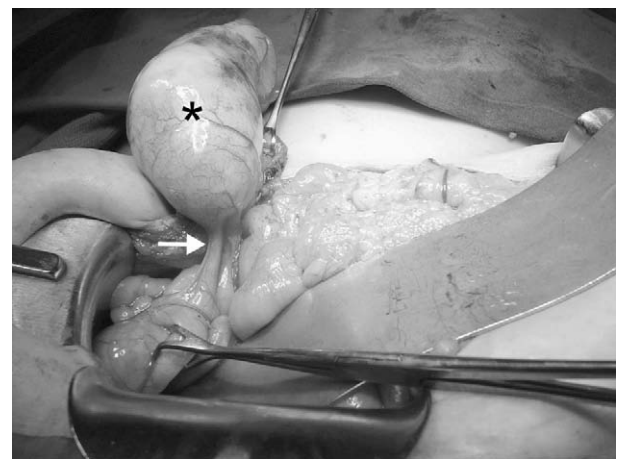


Figure 3 Asterisk shows mucocele. White arrow shows appendix.

tumors and non-specific symptoms such as weight loss were not found to be helpful in differential diagnosis.<sup>13</sup>

Mucocele is a term used for describing a lesion of the appendix, characterized by distention of the organ caused by accumulation of mucous inside the cavity. Mucus formation is usually the result of obstruction by a fecalith or other lesion such as an inflammatory stricture. About 10% of the cases occur as a consequence of cecal carcinoma.<sup>14</sup> Mucoceles are rare, accounting for only 0.2–0.3% of appendectomy specimens. Approximately 25% of mucoceles are asymptomatic and discovered incidentally either at surgery or radiological studies. Appendiceal mucocele can rarely cause intestinal obstruction.<sup>15</sup> Management of appendiceal mucoceles involves appendectomy for benign forms.<sup>16</sup> If there is suspicion of malignancy then right hemicolectomy is the treatment of choice.<sup>17</sup>

Appendiceal pathologies can behave as intra-abdominal aggressive masses. In elderly population diagnosis is more challenging. Even CT can mislead the surgeon. It would be wise to keep the usual diseases of the appendix in mind while taking necessary measures for a possible pathology with poor prognosis. In the era where some authors suggest non-operative management of acute appendicitis it is crucial to realize the consequences of leaving the inflamed appendix and surrounding tissues in place.<sup>18,19</sup> The differential diagnosis of the right lower quadrant intra-abdominal mass should include benign pathologies of the appendix even in the clinical picture of malignant presentation.

## References

1. Khatti S. Myeloid sarcoma of the appendix mimicking acute appendicitis. *AJR Am J Roentgenol* 01 May 2004;**182**:1194.
2. Oefelein MG. Urologic manifestations of nonurologic diseases: gastrointestinal disorders. *Urol Clin North Am* 2003 Feb;**30**:63–72.
3. Marcolongo R, Tavolini IM, Laveder F, Busa M, Noventa F, Bassi P. Immunosuppressive therapy for idiopathic retroperitoneal fibrosis: a retrospective analysis of 26 cases. *Am J Med* 2004 Feb 1;**116**:194–7.
4. Sánchez R, Arroyo A, Gesto R, Fernandez-Reyes MJ, Mon C, Alvarez-Ude F. Obstructive ARF caused by an inflammatory abdominal aortic aneurysm. *Am J Kidney Dis* 2003 Mar;**41**:E9.
5. Macari M, Balthazar EJ. The acute right lower quadrant: CT evaluation. *Radiol Clin North Am* 2003 Nov;**41**:1117–36.
6. Parsons JK, Freeswick PD, Jarrett TW. Appendiceal cystadenoma mimicking a cystic renal mass. *Urology* 2004 May;**63**:981–2.
7. Kawamura YJ. Intussusception of appendiceal adenoma mimicking invasive carcinoma. *Endoscopy* 2002 Sep;**34**:749.
8. Gehrig PA. Appendix cancer mimicking ovarian cancer. *Int J Gynecol Cancer* 01 Nov 2002;**12**:768–72.
9. Marshall MT, Rosen P, Berlin R, Greenon N. Appendicitis masquerading as tumor: a case of two diagnoses. *J Emerg Med* 2001 Nov;**21**:397–9.
10. Hendrickson M, Naparst TR. Abdominal surgical emergencies in the elderly. *Emerg Med Clin North Am* 2003 Nov;**21**:937–69.
11. Cornbleet PJ. Clinical utility of the band count. *Clin Lab Med* 2002 Mar;**22**:101–36.
12. Storm-Dickerson TL, Horattas MC. What have we learned over the past 20 years about appendicitis in the elderly? *Am J Surg* 2003 Mar;**185**:198–201.
13. Todd RD, Sarosi GA, Nwariaku F, Anthony T. Incidence and predictors of appendiceal tumors in elderly males presenting with signs and symptoms of acute appendicitis. *Am J Surg* 2004 Nov;**188**:500–4.
14. Pereira JCR, Trugilho JCV, Sarmat AA. Mucocele of the appendix. *Surgery* 01 Nov 2004;**136**:1096–7.
15. Mourad FH, Hussein M, Bahlawan M, Haddad M, Tawil A. Intestinal obstruction secondary to appendiceal mucocele. *Dig Dis Sci* 1999 Aug;**44**:1594–9.
16. Pitiakoudis M, Tsaroucha AK, Mimidis K, Polychronidis A. Mucocele of the appendix: a report of five cases. *Tech Coloproctol* 2004;**8**:109–12.
17. Andersson A, Bergdahl L, Boquist L. Primary carcinoma of the appendix. *Ann Surg* 183:53–7.
18. Dixon MR, Haukoos JS, Park IU, Oliak D, Kumar RR, Arnell TD, et al. An assessment of the severity of recurrent appendicitis. *Am J Surg* 2003 Dec;**186**:718–22.
19. Campbell MR, Johnston SL, Marshburn T, Kane J, Lugg D. Non-operative treatment of suspected appendicitis in remote medical care environments: implications for future spaceflight medical care. *J Am Coll Surg* 2004 May;**198**:822–30.