



Anaesthetic Management of a Patient with Brugada Syndrome

Halide Hande Şahinkaya¹, Erdem Yaşar², Zeki Tuncel Tekgül¹, Burcu Özalp Horsanalı¹, Ertaç Özeroğlu¹

¹*Clinic of Anaesthesiology, Bozyaka Training and Research Hospital, İzmir, Turkey*

²*Department of Algology, Hacettepe University School of Medicine, Ankara, Turkey*

Brugada Syndrome is a condition with an undetermined aetiology and a tendency for malignant arrhythmias, an electrocardiographic pattern of a right bundle branch block with persistent ST segment elevation in the right precordial leads (V1–V3) and no association with structural heart disease. We aimed to discuss the anaesthetic management of an asymptomatic 35-year-old patient with Brugada syndrome who had been diagnosed during the pre-anaesthetic assessment because of the family history of the early sudden cardiac death of his mother. As a result, we believe that detailed patient history and careful examination of laboratory tests and electrocardiography are crucial for early diagnosis of some diseases and for successful anaesthetic management.

Keywords: Anaesthesia, sudden cardiac death, Brugada syndrome, ST segment elevation

Introduction

Brugada syndrome is a condition with an undetermined aetiology and a tendency for malignant arrhythmias, an electrocardiography (ECG) pattern of a right bundle branch block with persistent ST segment elevation in the right precordial leads (V1–V3) and no association with structural heart disease (1). Of the patients with Brugada syndrome, 20%–25% have a mutation of the SCN5A gene that codes for the cardiac sodium ion channels. This gene has an autosomal dominant transmission (2). Patients are usually affected in their late thirties.

We aimed to discuss the anaesthetic management of an asymptomatic 35-year-old patient with Brugada syndrome who had been diagnosed during the pre-anaesthetic assessment because of a family history of early sudden cardiac death of his mother. This report was submitted after obtaining his written approval.

Case Presentation

A thirty-five-year-old male patient was admitted the emergency department with complaints of nausea and abdominal pain. The department of general surgery planned an operation with a diagnosis of acute appendicitis according to the patient's physical examination and laboratory results. A pre-anaesthetic assessment was conducted. The patient had no known disease and no symptoms such as palpitation, syncope, chest pain or dyspnoea. When he was asked regarding his family history, he informed about his mother's sudden cardiac death at the age of thirty-eight. His ECG revealed normal sinus rhythm with a heart rate of 58 beats/min and ST segment elevation in the V1-2 leads (Figure 1). The cardiology department was consulted. Echocardiography (ECO) imaging did not reveal a structural pathology. He was diagnosed with Brugada syndrome type 3 on the basis of his family history, ECG findings and normal ECO imaging. The cardiologist mentioned the severity of ventricular arrhythmias and pointed out the pro-arrhythmic medications.

The patient was accepted as ASA II E. After providing his written approval for anaesthesia, surgery and publication in a journal article, he was prepared for surgery. He was monitored with three leads ECG, a pulse oximeter and non-invasive blood pressure measurement. Automatic external defibrillator pads were attached to the patient's chest wall for cardioversion if required. Sinus arrhythmia was observed at the DII lead (Figure 2). His haemodynamic parameters were stable. For anaesthetic induction, 100 mcg fentanyl and 400 mg thiopental sodium were intravenously administered. Furthermore, 50 mg rocuronium bromide was intravenously administered to facilitate tracheal intubation. Anaesthesia was maintained with 4%–6% desflurane, 50%–50% oxygen-medical air and intravenous 0.5 mcg kg⁻¹ dk⁻¹ remifentanyl infusion. ECG revealed a normal sinus rhythm 10 min

after induction. No ST segment changes occurred intraoperatively. For postoperative pain relief, 50 mg deksketoprofen trometamol was intravenously administered. Surgery lasted for 40 min. Subsequently, 0.5 mg atropine sulphate and 1.5 mg neostigmine methyl-sulphate were intravenously administered, and tracheal extubation was successfully conducted. He was monitored and remained in the post-anaesthetic care unit for 6 h. Thus, haemodynamic stability was maintained, and ECG remained unchanged, and he was then taken to the ward. He was discharged from the hospital 2 days after the surgery. He was informed regarding the severity of the disease and further cardiologic assessment was recommended.

Discussion

In 2001, Gussak et al. (3) described minor and major criteria for the diagnosis of Brugada syndrome (Table 1). Minor and major criteria are considered to be enough for the diagnosis. Our patient's ECG revealed saddleback ST segment elevations that was lower than 1 mm in the right precordial leads. He had a normal ECO but a family history of sudden cardiac death. Therefore, he was diagnosed with Brugada syndrome type 3.

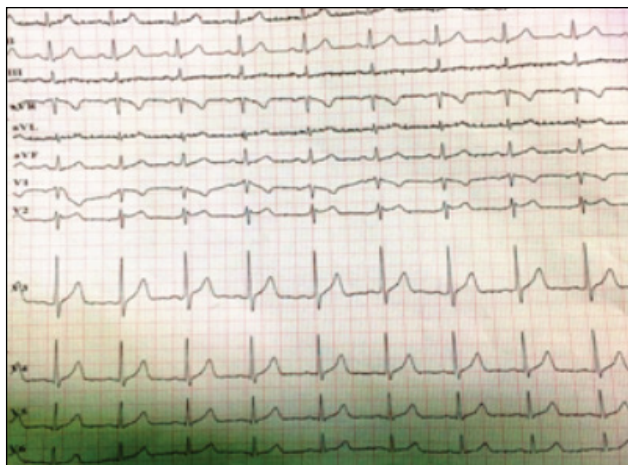


Figure 1. Preoperative electrocardiography

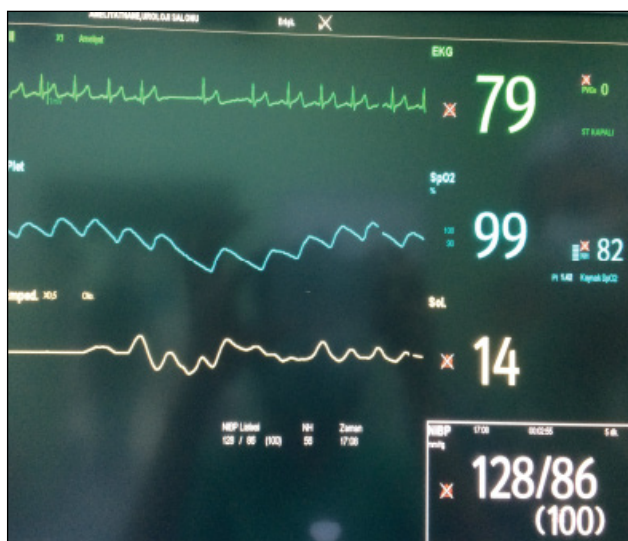

Figure 2. Intraoperative monitorization

Some anaesthetic agents are noted to have an association with ST segment elevations and can result in an increased risk of precipitating ventricular arrhythmias. The main course is early diagnosis to best prevent life-threatening arrhythmias and complications. There is a list of drugs (www.brugadadrugs.org) that are not recommended to be used to prevent cardiac death risk in patients with Brugada syndrome; for instance, propofol should be avoided. Moreover, many studies have been published regarding thiopental and its safe use. Kloesel et al. (4) published a case series and review regarding patients with Brugada syndrome. They noticed that ST elevation may occur after administering ketamine; however, thiopental did not have a similar effect. Ketamine and tramadol are the other drugs that should be avoided.

There are some reports concerning the relationship between local anaesthetic drugs used for regional anaesthesia and their complications in patients with Brugada syndrome. The local anaesthetic drugs are class Ib antiarrhythmic and sodium channel blockers. Phillips et al. (5) reported Brugada-like ECG changes of an asymptomatic patient after the thoracic epidural infusion of bupivacaine for 14 h. ECG revealed a normal sinus rhythm after 48 h. Klosel et al. (4) reported no complications after epidural fentanyl and bupivacaine combination for labour analgesia. ST segment elevation without any arrhythmia after intravenously administering lidocaine has been reported in the same case report series. Thus, local anaesthetics should be carefully used.

Postema et al. (6) reported the safe use of inhalational anaesthetics, opioids, neuromuscular blockers, neostigmine, atropine and glycopyrrolate without any adverse effects. However, neostigmine may cause ST segment elevation in a dose-dependent manner because of its vagotonic effect, whereas atropine may reduce elevation. Therefore, it may be wise to avoid neostigmine (7). There have been several reports regarding the successful neostigmine administration without problems (8, 9). Neostigmine did not cause any abnormalities in our case as well. Sugammadex could be effectively and safely used to an-

Table 1. Diagnostic criteria for Brugada syndrome

Major criteria

1. ECG findings associated with Brugada syndrome and no structural heart disease
2. Representing ECG findings associated with Brugada syndrome after administering sodium channel blockers

Minor criteria

1. Family history of sudden cardiac death
2. Undetermined aetiology of syncope
3. Documented ventricular tachycardia or ventricular fibrillation episodes
4. Ventricular tachycardia or ventricular fibrillation episodes after electrical stimulus
5. Genetic mutation of ion channels

ECG: electrocardiography

tagonize neuromuscular block (10). Although the most common opioid used in patients with Brugada syndrome is fentanyl (11), Ahn and Kim (12) reported the successful use of remifentanyl. Antiemetics, such as ondansetron, granisetron and dexametazone, may be used; however, phenothiazine should be avoided (6). Beta receptor antagonists and alpha receptor agonists may be the cause of ST segment elevation.

Tatlı et al. (13) suggested an electrophysiological study to determine the sudden death risk of patients with Brugada syndrome. If there is a ventricular tachycardia or ventricular fibrillation episode, their recommendation was to implant an implantable cardioverter defibrillator (ICD). Because of the emergency of the surgery, our patient did not have time for an electrophysiological study and ICD implantation. General anaesthesia was preferred. Induction of anaesthesia was performed with thiopental sodium, fentanyl and rocuronium bromure for tracheal intubation. Anaesthesia was maintained with 50%–50% oxygen-medical air and remifentanyl infusion. Dexketoprofen trometamol was intravenously administered for postoperative analgesia and neostigmine with atropine for extubation. There were no complications during anaesthesia or in the postoperative period. We had performed a successful anaesthetic management.

In this case, right precordial derivations were not monitored for ST segment changes. Also, it was not possible to monitor the depth of anaesthesia. Further monitorization should be available for safe anaesthetic management.

Conclusion

Detailed patient history is the most important step in pre-anaesthetic assessment. Careful examination of the laboratory tests and ECG are also crucial for the early diagnosis of some diseases as well as for successful anaesthetic management.

Informed Consent: Written informed consent was obtained from patient who participated in this case.

Peer-review: Externally peer-reviewed.

Author Contributions: Concept - H.H.Ş.; Design - H.H.Ş., Z.T.T.; Supervision - E.Y., Z.T.T.; Resources - H.H.Ş., B.Ö.H., E.Ö.; Materials - H.H.Ş.; Data Collection and/or Processing - B.Ö.H., E.Ö.; Analysis and/or Interpretation - H.H.Ş., E.Y., Z.T.T.; Literature Search - H.H.Ş., B.Ö.H., E.Ö.; Writing Manuscript - H.H.Ş.; Critical Review - E.Y., Z.T.T., B.Ö.H., E.Ö.; Other - H.H.Ş.

Conflict of Interest: No conflict of interest was declared by the authors.

Financial Disclosure: The authors declared that this study has received no financial support.

References

1. Brugada P, Brugada J. Right bundle branch block, persistent ST segment elevation and sudden cardiac death: a distinct clinical and electrocardiographic syndrome. A multicenter report. *J Am Coll Cardiol* 1992; 20: 1391-6. [\[CrossRef\]](#)
2. Hedley PL, Jorgensen P, Schlamowitz S, Moolman-Smook J, Kanters JK, Corfield VA, et al. The genetic basis of Brugada syndrome: a mutation update. *Hum Mutat* 2009; 30: 1256-66. [\[CrossRef\]](#)
3. Gussak I, Bjerregaard P, Hammill SC. Clinical diagnosis and risk stratification in patients with Brugada syndrome. *J Am Coll Cardiol* 2001; 37: 1635-8. [\[CrossRef\]](#)
4. Kloesel B, Ackerman MJ, Sprung J, Narr BJ, Weingarten TN. Anesthetic management of patients with Brugada syndrome: a case series and literature review. *Can J Anesth* 2011; 58: 824-36. [\[CrossRef\]](#)
5. Phillips N, Priestley M, Dennis AR, Uther JB. Brugada-type electrocardiographic pattern induced by epidural bupivacaine. *Anesth Analg* 2003; 97: 264-7. [\[CrossRef\]](#)
6. Postema PG, Wolpert C, Amin AS, Probst V, Borggreffe M, Roden DM, et al. Drugs and Brugada syndrome patients: review of literature, recommendations, and an up-to-date website (www.brugadadrugs.org). *Heart Rhythm* 2009; 6: 1335-41. [\[CrossRef\]](#)
7. Hayashida H, Miyauchi Y. Anaesthetic management in patients with high-risk Brugada syndrome. *Br J Anaesth* 2006; 97: 118-9. [\[CrossRef\]](#)
8. Edge CJ, Blackman DJ, Gupta K, Sainsbury M. General anaesthesia in a patient with Brugada syndrome. *Br J Anaesth* 2002; 89: 788-91. [\[CrossRef\]](#)
9. Inamura M, Okamoto H, Kuriowa M, Hoka S. General anaesthesia for patients with Brugada syndrome. A report of six cases. *Can J Anaesth* 2005; 52: 409-12. [\[CrossRef\]](#)
10. Konishi J, Suzuki T, Kondo Y, Baba M, Ogawa S. Rocuronium and sugammadex used effectively for electroconvulsive therapy in a patient with Brugada syndrome. *J ECT* 2012; 28: 21-2. [\[CrossRef\]](#)
11. Dulu A, Pastores SM, McAleer E, Voigt L, Halpern NA. Brugada electrocardiographic pattern in a postoperative patient. *Crit Care Med* 2005; 33: 1634-7. [\[CrossRef\]](#)
12. Ahn YH, Kim JY. Anesthetic management of a patient with Brugada syndrome for one-lung ventilation by total intravenous anaesthesia with propofol and remifentanyl: A case report. *Anesth Pain Med* 2009; 4: 310-3.
13. Tatlı E, Gül Ç, Sürücü H, Özçelik F. Brugada Syndrome: Clinical Evaluation, diagnosis and treatment modalities: Review. *Turkiye Klinikleri J Med Sci* 2005; 25: 560-4.