

Spontaneous Resolution of Syringomyelia Without Chiari Malformation

—Case Report—

Pinar Akdemir OZISIK, Burcu HAZER, Ibrahim M. ZIYAL,
and Osman Ekin OZCAN

Department of Neurosurgery, Faculty of Medicine, Hacettepe University, Ankara, Turkiye

Abstract

A 30-year-old woman presented with a cervical syrinx manifesting as hemihypesthesia. Neuroimaging found no evidence of Chiari malformation or tight cisterna magna. Serial magnetic resonance imaging studies over a 6-year period demonstrated spontaneous and complete resolution of the syrinx accompanied by an asymptomatic clinical course. The natural history of syringomyelia is highly unpredictable. The outcome of surgical treatment for patients with syringomyelia is not always satisfactory, so the indications for surgery are controversial. Spontaneous resolution of syringomyelia unrelated with foramen magnum lesion has various causes. Close follow up of the patient is necessary to monitor for recurrence.

Key words: syringomyelia, syringobulbia, spontaneous resolution, Chiari malformation

Introduction

Syringomyelia was first used by Ollivier d'Angers in 1827 to describe the cystic cavitation of the spinal cord. Syringomyelia now includes various conditions associated with the presence of a cavity in the spinal cord. Syringomyelia is usually associated with trauma or congenital abnormalities along the spinal neuraxis, typically at the craniocervical junction. In recent years, advanced neuroimaging techniques have affected the treatment modalities. Magnetic resonance (MR) imaging can identify lesions in the spinal cord such as syrinx or hydromyelia earlier, often before clinical symptoms occur. The exact pathogenesis of syringomyelia is not well understood and there is limited information on its natural history. Some patients show progressive clinical deterioration, whereas others show no change in symptoms over many years. Cases of spontaneous resolution of syringomyelia have increased the ongoing controversies about the optimal treatment of this disorder. Such cases are usually associated with resolution of Chiari malformation.

Here we describe a case of spontaneous resolution of idiopathic syringomyelia in an adult patient without Chiari malformation.

Case Report

A 30-year-old woman presented with sudden onset of right hemihypesthesia. She had had poliomyelitis at age 8 years. She was cured without neurological sequelae, and had no ventilation problems or paresis of the upper extremities during the course of the disease. She had no history of trauma.

On admission, neurological examination revealed right hemihypesthesia including the ipsilateral face, which she had not recognized, and very slight right hemiparesis without increase in muscle tone or myelopathic signs. The preliminary diagnosis was multiple sclerosis. Brain MR imaging showed no abnormalities, but the superior border of a cystic cavity in the lower cervical cord was identified. Cervical and whole spinal MR imaging identified a syrinx at the C-6 level (Fig. 1A, C). There was no enhancement after administration of gadolinium-diethylenetriaminepenta-acetic acid. MR angiography showed dominant left transverse sinus with high jugular bulb on the left (Fig. 1D). The posterior fossa was normal and no Chiari I malformation was identified (Fig. 1B).

Two days later, her hemihypesthesia and hemiparesis had totally resolved without treatment. She was followed up with MR imaging at 6-month intervals initially, then annually. Her complaints never came

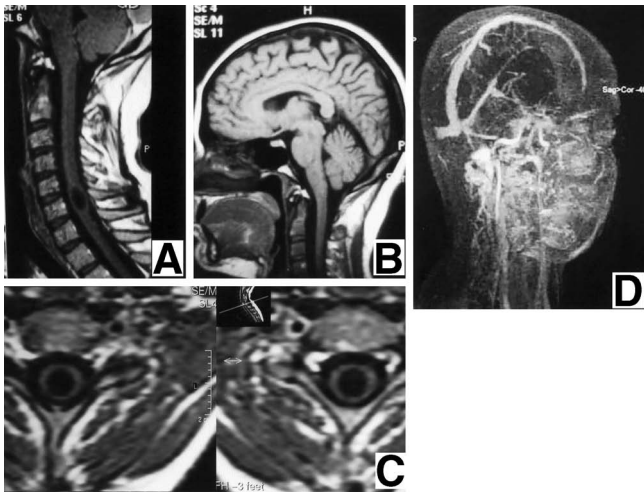


Fig. 1 Midline sagittal T₁-weighted magnetic resonance (MR) images of the cervical spine (A) and brain (B) showing a syrinx extending from the inferior border of C-5 to the superior aspect of C-7 and normal posterior fossa without Chiari malformation. Axial T₁-weighted cervical MR images (C) showing the regular border of the syrinx cavity and no enhancement after gadolinium-diethylenetriaminepenta-acetic acid administration. MR angiogram (D) emphasizing the dominant left and narrow right transverse sinuses.

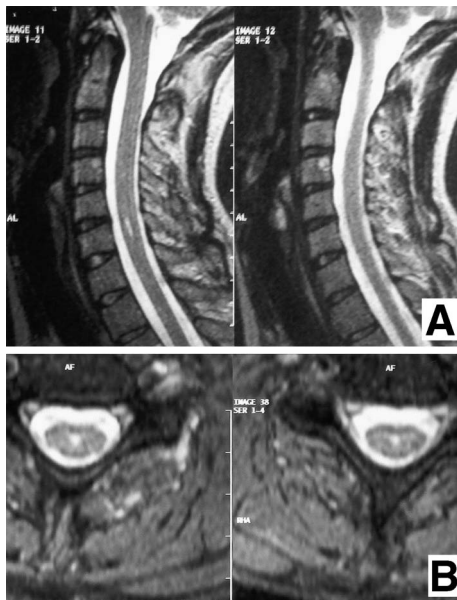


Fig. 2 Midline sagittal (A) and axial (B) T₂-weighted magnetic resonance images obtained 6 years later showing almost complete resolution of the syringomyelic cavity.

back. She had a very active life with participation in sport. The patient was subsequently lost to follow up for 2 years, but the last MR imaging obtained 6 years after the diagnosis of syringomyelia showed almost complete disappearance of the syrinx (Fig. 2).

Discussion

The association of syringomyelia with Chiari I malformation has been recognized for many years.^{15,28,31,42} Several theories have been proposed to explain the mechanisms of the development of syringomyelia and spontaneous resolution in the presence of Chiari I malformation. The hydrodynamic theory,¹² the craniospinal dissociation theory,^{48,49} and the tonsillary piston theory³³ rely on the cerebrospinal fluid (CSF) pressure pulsations or venous pressure changes in the cranium and spinal subarachnoid space during transient elevations in thoracic pressure during coughing, straining, or Valsalva maneuvers in individuals with hindbrain herniation. However, some other studies^{6,36} and necropsy findings fail to support these theories.^{4,29,32} Other authors have directed attention toward the spinal cord to explain the cause of syringomyelia.^{4,25,39}

Eleven adult (Table 1)^{11,19-21,23,24,35,41,47} and 10 pediatric cases (Table 2)^{2,3,9,14,24,38,43-45,50} of spontaneous resolution of syringomyelia as documented by MR imaging with no surgical intervention have been reported. Spontaneous resolution of Chiari I malformation-related syringomyelia was associated with Chiari I malformation improvement in almost all of the pediatric cases (8 patients had Chiari I malformation and 7 had resolution of Chiari malformation), whereas eight of 11 adult patients had Chiari I malformation and only three had resolution of Chiari malformation. A possible explanation for this phenomenon in children is that growth of the cranium continues after the cerebellum has reached more than 90% of its final size by age 2 years.⁴⁰ Therefore, the tonsils may regress intracranially in relation to the growing cranium²⁶ to the extent that free CSF passage is established, thus allowing the syrinx to decrease in size or even disappear completely. Even among older people, Chiari I malformations could be reduced by brain atrophy, especially of the cerebellar tonsils.^{7,26}

Other explanations for the resolution of syringomyelia include spontaneous rupture of the arachnoid thickening or scarring at the foramen magnum and foramen of Magendie in Chiari I malformation improves the passage of CSF at the foramen magnum,^{22,23,37} or resolution of the increased intracranial pressure after head trauma

Table 1 Summary of adult cases of spontaneous resolution of syringomyelia

Author (Year)	Age (yrs)	Sex	Presentation	Diagnosis	Location	Association of Chiari	Resolution of Chiari	Clinical course	Follow up	
Jack et al. (1991) ²⁰⁾	30	F	paresthesia, decreased sensation on chest wall and lt upper extremity	MR imaging	C1-lower T	+	-	less improvement	2 yrs	
Santoro et al. (1993) ⁴¹⁾	42	M	paresthesia, gait disturbance, atrophy of hand muscles	MR imaging	C1-T2	+	-	unchanged	3 yrs	
	31	F	incidental finding	MR imaging	C1-T7	+	-	asymptomatic	3 yrs	
Pierallini et al. (1997) ³⁵⁾	25	F	headache, dizziness	MR imaging	C2-4	+	improved	improved	4 yrs	
Fukutake and Hattori (1998) ¹¹⁾	40	F	recurrent thoracic girdle pain	MR imaging	T4-5	+	(mild)	?	disappeared	2 mos
Vinas et al. (2001) ⁴⁷⁾	58	M	pain on rt upper extremity, paresthesia, neck pain	MR imaging	C6-T1	-		improved	5 yrs	
Klekamp et al. (2001) ²³⁾	37	F	dysesthesia, hypesthesia in the rt arm and rt trigeminal distribution	MR imaging	C2-T2	+	complete resolution	improved (symptoms regress)	32 mos	
Itoyama et al. (2001) ¹⁹⁾	54	M	severe pain in the neck and rt arm	MR imaging	C2-3	+	-	improved	1 mo	
Kastrup et al. (2001) ²¹⁾	61	F	burning pain sense, loss of pain and thermal sense in rt chest wall, kyphoscoliosis	MR imaging	C1-conus	-		unchanged	7 yrs	
Kyoshima and Bogdanov (2003) ²⁴⁾	39	M	progressive weakness in lt leg, then both legs		C2-T2	+	improved	improved	6 mos	
Present case	30	F	rt hypesthesia, hemiparesis	MR imaging	C-6	-		asymptomatic	6 yrs	

MR: magnetic resonance.

either by time or treatment.^{30,34)} An alternative explanation for spontaneous resolution in adults involves a mechanism in which decompression of syringomyelia into the spinal subarachnoid space may occur through a tear in the spinal cord caused by increased pressure within the syringomyelia during Valsalva-like maneuvers.^{20,21,41)} Such communications between syrinx and subarachnoid space have been demonstrated by MR imaging⁴¹⁾ and neuropathological examinations.²⁷⁾ Spontaneous resolution of syringomyelia was reported in two patients with multiple sclerosis.^{1,10)} Cavities are thought to begin in the spinal cord parenchyma as a result of direct disruption or necrosis. Syringomyelia associated with spinal deformities,^{8,16,18,46)} and spontaneous resolution of the syrinx in some patients with scoliosis were also reported.⁴⁶⁾ Spontaneous resolution was also observed in spinal trauma-related

syringomyelia. A 29-year-old male presented with T-5 fracture, and C1-T5 and T5-8 syringomyelia probably caused by arachnoid scarring around the trauma area.⁵⁾

Our patient had no Chiari malformation or tight cisterna magna on admission or during the follow-up period. The syrinx was small, in a low cervical location, and seemed unrelated with any trauma or infectious cause. The only neuroimaging abnormalities in the posterior fossa were the narrow right transverse sinus and dominant left transverse sinus with high jugular bulb. It is impossible to prove in this case that incomplete venous thrombosis involving the posterior fossa followed by recanalization or establishment of sufficient collateral flow allowed CSF outflow from spinal subarachnoid space to be normalized with spontaneous resolution of syrinx.^{13,44)}

Table 2 Summary of pediatric cases of spontaneous resolution of syringomyelia

Author (Year)	Age	Sex	Presentation	Diagnosis	Location	Association of Chiari	Resolution of Chiari	Clinical course	Follow up
Sudo et al. (1990) ⁴³⁾	14 yrs	M	lt hypalgesia, hypesthesia	MR imaging	C2-T9	+	+	improved	2 yrs
Yeager and Lusser (1992) ⁵⁰⁾	19 mos	F	seizure, normal examination, incidental finding	MR imaging	C4-7	-		asymptomatic	2 yrs
Avellino et al. (1996) ³⁾	5 yrs	M	complex partial seizure, incidental finding of syringomyelia	MR imaging	C3-7, T5-8	+	improved	asymptomatic	6 yrs
Avellino et al. (1999) ²⁾	5 yrs	F	abnormal gait due to lt leg paresis and paresthesia, thoracic scoliosis	MR imaging	C2-T12	+	improved	unchanged	11 yrs
Sun et al. (2000) ⁴⁴⁾	11 yrs	M	complex partial seizures, few intermittent episodes in hands and feet	MR imaging	C2-T4	+	+	asymptomatic	2 yrs
Sun et al. (2001) ⁴⁵⁾	7 yrs	M	bitemporal headache for 1 mo associated with few nausea and vomiting attacks	MR imaging	C2-3	+	+	unchanged	6 yrs
Rafia and Pascual-Castroviejo (2001) ³⁸⁾	4 yrs	M	short stature, dysmorphic face, no neurological signs, incidental finding	MR imaging	cervical and dorso-lumbar	+	improved	improved	4 yrs
Kyoshima and Bogdanov (2003) ²⁴⁾	10 yrs	F	progressive occipitalgia for 3 yrs, neck pain for 6 mos, hypesthesia in rt facial and C5-L4 dermatomes	MR imaging	C4-T11	basilar impression		improved	22 mos
Coloma-Valverde (2003) ⁹⁾	2 yrs	M	neck pain	MR imaging	cervical	+	-	asymptomatic	3 yrs
Guillen and Costa (2004) ¹⁴⁾	6 yrs	F	scoliosis with 6 mos history	MR imaging	C3-T10	+	+	progression of curvature	8 yrs

MR: magnetic resonance.

Extensive forced movements of the spinal column may also another possible cause for the syringomyelia in our patient as she had been playing basketball and tennis for a long time but without regular exercise programs. A 40-year-old synchronized swimmer presented with recurrent thoracic girdle pain and reversible syringomyelia and developed insidious left thoracic pain 2 days after an underwater exhibition performance that was longer and more strenuous than usual.¹¹⁾ The combination of breath holding and movements including hyperextension or hyperflexion of the spine can markedly raise the intrathoracic and intracranial pressures and may

cause subtle Chiari malformation and syringomyelia. Therefore, repetitive forced extension of the spine might also be the cause of syringomyelia in our case.

The clinical and radiological follow up of our patient resemble the slit-like syrinx cavity presented in a series of patients with remnants of the prenatal persistent central canal without change in CSF flow dynamics.¹⁷⁾ Some cases of spontaneous resolution of syringomyelias without Chiari I malformation in adults might be accepted as incidental radiological findings after careful evaluation of their medical history, and neuroradiological and clinical examina-

tions.

Despite the clearly identified role of CSF flow abnormalities in the development and progression of most cases of syringomyelia, the specific mechanisms leading to the development and spontaneous resolution of syringomyelia remain to be determined, especially if the syrinx is small, located at low levels in the spinal cord, and the patient does not have Chiari malformation, as in our case. The evidence that syringomyelia can spontaneously resolve makes the treatment strategy controversial. Observation is frequently recommended if the patient is asymptomatic. However, close follow up is also needed after spontaneous resolution, because the pathophysiological cause is not completely understood and recurrence is possible.

References

- 1) Ando T, Kameyama T, Kawai K, Fukatsu H, Takahashi A: [Serial magnetic resonance imaging of spinal syrinx formation in a case of multiple sclerosis]. *Rinsho Shingeigaku* 32: 1288-1293, 1992 (Jpn, with Eng abstract)
- 2) Avellino AM, Britz GM, McDowell JR, Shaw DW, Ellenbogen RG, Roberts TS: Spontaneous resolution of a cervicothoracic syrinx in a child. *Pediatr Neurosurg* 30: 43-46, 1999
- 3) Avellino AM, Kim DK, Weinberger E, Roberts TS: Resolution of spinal syrinx and Chiari I malformation in a child: case illustration. *J Neurosurg* 84: 708, 1996
- 4) Ball MJ, Dayan AD: Pathogenesis of syringomyelia. *Lancet* 2: 799-801, 1972
- 5) Birbamer G, Buchberger W, Felber S, Posch A, Russegger L: Spontaneous collapse of posttraumatic syringomyelia: serial magnetic resonance imaging. *Eur Neurol* 33: 378-381, 1993
- 6) Cahan LD, Bentson JR: Considerations in the diagnosis and treatment of syringomyelia and the Chiari malformation. *J Neurosurg* 57: 24-31, 1982
- 7) Castillo M, Wilson JD: Spontaneous resolution of a Chiari I malformation: MR demonstration. *AJNR Am J Neuroradiol* 16: 1158-1160, 1995
- 8) Charry O, Koop S, Winter R, Lonstein J, Denis F, Bailey W: Syringomyelia and scoliosis: a review of twenty-five pediatric patients. *J Pediatr Orthop* 14: 309-317, 1994
- 9) Coloma-Valverde G: [Spontaneous resolution of the syrinx. A case report and survey of the literature]. *Rev Neurol* 36: 1156-1158, 2003 (Span, with Eng abstract)
- 10) Deguchi K, Takeuchi H, Yamada A, Katanaka J, Tsukaguchi M, Sasaki I, Nishioka M: [Multiple sclerosis with syringomyelia: Case report]. *No To Shinkei* 46: 65-69, 1994 (Jpn, with Eng abstract)
- 11) Fukutake T, Hattori T: Reversible hydromyelia in a synchronized swimmer with recurrent thoracic girdle pains. *J Neurol Neurosurg Psychiatry* 65: 606, 1998
- 12) Gardner WJ, Angel J: The cause of syringomyelia and its surgical treatment. *Cleve Clin Q* 25: 4-7, 1958
- 13) Girard N, Lasjaunias P, Taylor W: Reversible tonsillar prolapse in vein of Galen aneurysmal malformations: report of eight cases and pathophysiological hypothesis. *Childs Nerv Syst* 10: 141-147, 1994
- 14) Guillen A, Costa JM: Spontaneous resolution of a Chiari I malformation associated syringomyelia in one child. *Acta Neurochir (Wien)* 146: 187-191, 2004
- 15) Hertel G, Kramer S, Placzek E: [Syringomyelia. Clinical follow-up studies in 323 patients]. *Nervenarzt* 44: 1-13, 1973 (Ger)
- 16) Hida K, Iwasaki Y, Koyanagi I, Abe H: Pediatric syringomyelia with Chiari malformation: its clinical characteristics and surgical outcomes. *Surg Neurol* 51: 383-391, 1999
- 17) Holly TL, Batzdorf U: Slitlike syrinx cavities: a persistent central canal. *J Neurosurg* 97(2 Suppl): 161-165, 2002
- 18) Isu T, Chono Y, Iwasaki Y, Koyanagi I, Akino M, Abe H, Abumi K, Kaneda K: Scoliosis associated with syringomyelia presenting in children. *Childs Nerv Syst* 8: 97-100, 1992
- 19) Itoyama Y, Kitamura I, Ushio Y: [Spontaneous resolution of cervical syringomyelia: A case report]. *No Shinkei Geka* 29: 321-324, 2001 (Jpn, with Eng abstract)
- 20) Jack CR, Kokmen E, Onofrio BM: Spontaneous decompression of syringomyelia: magnetic resonance imaging findings. Case report. *J Neurosurg* 74: 283-286, 1991
- 21) Kastrup A, Nagele T, Topka H: Spontaneous resolution of idiopathic syringomyelia. *Neurology* 57: 1519-1520, 2001
- 22) Klekamp J, Batzdorf U, Samii M, Bothe HW: The surgical treatment of Chiari I malformation. *Acta Neurochir (Wien)* 138: 788-801, 1996
- 23) Klekamp J, Iaconetta G, Samii M: Spontaneous resolution of Chiari I malformation and syringomyelia. *Neurosurgery* 48: 664-667, 2001
- 24) Kyoshima K, Bogdanov EI: Spontaneous resolution of syringomyelia: report of two cases and review of the literature. *Neurosurgery* 53: 762-769, 2003
- 25) Levine DN: The pathogenesis of syringomyelia associated with lesions at the foramen magnum: a critical review of existing theories and proposal of a new hypothesis. *J Neurol Sci* 220: 3-21, 2004
- 26) Mikulis DJ, Diaz O, Egglin TK, Sanchez R: Variance of the position of the cerebellar tonsils with age: preliminary report. *Radiology* 183: 725-728, 1992
- 27) Milhorat TH, Capocelli AL Jr, Anzil AP, Kotzen RM, Milhorat RH: Pathological basis of spinal cord cavitation in syringomyelia: analysis of 105 autopsy cases. *J Neurosurg* 82: 802-812, 1995
- 28) Milhorat TH, Chou MW, Trinidad EM, Kula RW, Mandell M, Wolpert C, Speer MC: Chiari I malformation redefined: Clinical and radiographic findings for 364 symptomatic patients. *Neurosurgery* 44:

- 1005-1017, 1999
- 29) Milhorat TH, Kotzen RM, Anzil AP: Stenosis of central canal of spinal cord in man: incidence and pathological findings in 232 autopsy cases. *J Neurosurg* 80: 716-722, 1994
 - 30) Morioka T, Shono T, Nishio S, Yoshida K, Hasuo K, Fukui M: Acquired Chiari 1 malformation and syringomyelia associated with bilateral chronic subdural hematoma: Case report. *J Neurosurg* 83: 556-558, 1995
 - 31) Moriwaka F, Tashiro K, Tachibana S, Yada K: [Epidemiology of syringomyelia in Japan: the nationwide survey]. *Rinsho Shingegaku* 35: 1395-1397, 1995 (Jpn, with Eng abstract)
 - 32) Newman PK, Terenty TR, Foster JB: Some observations on the pathogenesis of syringomyelia. *J Neurol Neurosurg Psychiatry* 44: 964-969, 1981
 - 33) Oldfield EH, Muraszko K, Shawker TH, Patronas NJ: Pathophysiology of syringomyelia associated with Chiari I malformation of the cerebellar tonsils. Implications for diagnosis and treatment. *J Neurosurg* 80: 3-15, 1994
 - 34) Olivero WC, Dinh DH: Chiari I malformation with syringomyelia and spontaneous resolution. *Neurosurgery* 30: 758-760, 1992
 - 35) Pierallini A, Ferone E, Colonnese C: [Magnetic resonance imaging of a case of spontaneous resolution of syringomyelia associated with type I Chiari malformation]. *Radiol Med (Torino)* 93: 621-622, 1997 (Ital)
 - 36) Pojunas K, Williams AL, Daniels DL, Haughton VM: Syringomyelia and hydromyelia: magnetic resonance evaluation. *Radiology* 153: 679-683, 1984
 - 37) Quencer RM, Post MJ, Hinks RS: Cine MR in the evaluation of normal and abnormal CSF flow: intracranial and intraspinal studies. *Neuroradiology* 32: 371-391, 1990
 - 38) Rafia S, Pascual-Castroviejo I: [Syringohydromyelia. Report of a case which resolved spontaneously]. *Rev Neurol* 32: 635-637, 2001 (Span, with Eng abstract)
 - 39) Rice-Edwards M: Syringomyelia and the Chiari malformation, in Dudley H, Carter D, Russell RCG, Symon L, Thomas DGT, Clark K (eds): *Rob & Smith's Operative Surgery*, ed 4. London, Butterworths, 1989, pp 135-145
 - 40) Riedel A, Klekamp J, Harper C, Kretschmann HJ: Morphometric study on the postnatal growth of the cerebellum of Australian aborigines and Caucasians. *Brain Res* 499: 333-343, 1989
 - 41) Santoro A, Delfini R, Innocenzi G, Di Biasi C, Trasimeni G, Gualdi G: Spontaneous drainage of syringomyelia: report of two cases. *J Neurosurg* 79: 132-134, 1993
 - 42) Schliep G, Ritter U: [Clinical picture of syringomyelia]. *Fortschr Neurol Psychiatr Grenzgeb* 39: 53-82, 1971 (Ger)
 - 43) Sudo K, Doi S, Maruo Y, Tashiro K, Terae S, Miyasaka K, Isu T: Syringomyelia with spontaneous resolution. *J Neurol Neurosurg Psychiatry* 53: 437-438, 1990
 - 44) Sun JC, Steinbok P, Cochrane DD: Spontaneous resolution and recurrence of a Chiari I malformation and associated syringomyelia. Case report. *J Neurosurg* 92 (2 Suppl): 207-210, 2000
 - 45) Sun PP, Harrop J, Sutton L, Younkin D: Complete spontaneous resolution of childhood Chiari I malformation and associated syringomyelia. *Pediatrics* 107: 182-184, 2001
 - 46) Tokunaga M, Minami S, Isobe K, Moriya H, Kitahara H, Nakata Y: Natural history of scoliosis in children with syringomyelia. *J Bone Joint Surg Br* 83: 371-376, 2001
 - 47) Vinas FC, Pilitsis J, Wilner H: Spontaneous resolution of a syrinx. *J Clin Neurosci* 8: 170-172, 2001
 - 48) Williams B: The distending force in the production of "communicating syringomyelia." *Lancet* 2: 189-193, 1969
 - 49) Williams B: Current concepts of syringomyelia. *Br J Hosp Med* 4: 331-341, 1970
 - 50) Yeager BA, Lusser MA: Spontaneous resolution of idiopathic syringomyelia: MR features. *J Comput Assist Tomogr* 16: 323-324, 1992
-
- Address reprint requests to: P. A. Ozisik, M.D., Department of Neurosurgery, Faculty of Medicine, Hacettepe University, 06100 Sıhhiye, Ankara, Türkiye.
e-mail: kozisik@hotmail.com
pozisik@hacettepe.edu.tr