

## Paroxysmal Complete Atrioventricular Block: A Rare Cause of Syncope in Children

H Olgun<sup>1</sup>, N Ceviz<sup>1</sup>, T Karagoz<sup>2</sup>

### ABSTRACT

*Paroxysmal atrioventricular block (PAVB) is a rare cause of syncope, mostly reported in adults. In the present study, a child with recurrent syncope due to PAVB is reported. A 12-year old boy was admitted due to syncope. Some syncopal episodes were consistent with vasovagal syncope, while others had atypical features. Electrocardiography, echocardiography, and 24-hour electrocardiography monitoring were normal. Head-up tilt table test revealed mixed type vasovagal syncope. With beta-blocker treatment, the frequency of syncopal episodes decreased; however, the episodes with atypical features continued. Intracardiac electrophysiological study was normal, but repeated external loop recorder monitoring revealed transient AVB during a syncopal episode. In children with syncope with atypical features, PAVB should be kept in mind. Repeated external loop recorder monitoring may be useful in the diagnosis of such seldom seen arrhythmic causes.*

**Keywords:** Children, electrophysiological study, event recorder, paroxysmal atrioventricular block, recurrent syncope

## Bloqueo Auriculoventricular Completo Paroxístico: Una Rara Causa de Síncope en Niños

H Olgun<sup>1</sup>, N Ceviz<sup>1</sup>, T Karagoz<sup>2</sup>

### RESUMEN

*El bloqueo auriculoventricular paroxístico (BAVP) es una causa rara del síncope, reportada principalmente en adultos. El presente estudio, reporta el caso de un niño con síncope recurrente debido al BAVP. El niño, de 12 años de edad, fue ingresado a causa de un síncope. Algunos episodios sincopales correspondían a síncope vasovagales, mientras que otros tenían características atípicas. La electrocardiografía, la ecocardiografía y 24 horas de monitoreo con electrocardiografía fueron normales. La prueba de inclinación con mesa basculante reveló un síncope vasovagal de tipo mixto. Con el tratamiento con bloqueadores beta, disminuyó la frecuencia de los episodios sincopales. Sin embargo, continuaron los episodios con características atípicas. El estudio electrofisiológico intracardiaco arrojó resultados normales, el monitoreo repetido con grabador de bucle externo, reveló un BAV transitorio durante un episodio sincopal. En niños con síncope con características atípicas, la posibilidad de un BAVP debe tenerse en cuenta. El monitoreo repetido con grabador de bucle externo puede ser útil en el diagnóstico de esas causas arrítmicas raras veces vistas.*

**Palabras claves:** Niños, estudio electrofisiológico, grabador de eventos, bloqueo auriculoventricular paroxístico, síncope recurrente

West Indian Med J 2015; 64 (3): 275

From: <sup>1</sup>Division of Pediatric Cardiology, Ataturk University, Faculty of Medicine, Erzurum, Turkey and <sup>2</sup>Division of Pediatric Cardiology, Hacettepe University, Faculty of Medicine, Ankara, Turkey.

Correspondence: Dr H Olgun, Ataturk Universitesi, Tıp Fakültesi, Yakutiye Araştırma Hastanesi, Çocuk Kardiyoloji Polk, 25240 Erzurum, Turkey. Fax: + 90 (442) 2361301; e-mail: drholgun@hotmail.com

## INTRODUCTION

Syncope is a relatively common problem in childhood, and the most frequent type is vasovagal syncope with a benign course (1). Structural heart diseases and cardiac arrhythmias can result in severe syncopal attacks (2). While paroxysmal atrioventricular block (PAVB) has been reported as a cause of syncope in adults (3), it is a rare cause of syncope in children (1, 4). In the present study, a child with recurrent syncope due to PAVB is reported.

## CASE REPORT

A 12-year old boy was admitted with the complaint of syncope. He had a history of short episodes of loss of consciousness for the last two years. The frequency of attacks had increased in recent months. He described two types of syncopal episodes: a) while standing, he would experience dizziness and blackout/faint, lasting for approximately 2–3 minutes, and b) while sitting, he would experience chest pain, palpitation and dizziness, and lose consciousness for approximately 15–20 seconds. The syncopal attacks did not include convulsive characteristics. His medical history revealed two febrile convulsions at two and three years of age. In addition, two cousins were under treatment for epilepsy.

His physical examination, whole blood count and biochemical analysis including electrolytes were normal. Electrocardiography, 24-hour electrocardiography monitoring and echocardiographic study revealed no cause for the syncope. Neurological examination, electroencephalography and brain imaging were also normal. Because of the unexplained syncope, head-up tilt table test was performed, and a vasodepressor-type syncope developed at the 8<sup>th</sup> minute of the test. Metoprolol was started. During the following six months, the frequency of attacks decreased, but three new attacks were reported. The first occurred while sitting, with syncope lasting 3–4 seconds following chest pain and dizziness; the second was a short presyncope while sitting, without any prodromal sign, and the third was a short syncope while sitting without any prodrome. Neurological evaluation was again normal. Clinical signs did not suggest epilepsy. Although the recent attacks were not thought to be vasovagal, beta-blocker was continued. One month later, he presented with a new syncopal episode. While sitting, he felt palpitation and chest pain prior to a 3–4-second loss of consciousness. The patient was prescribed an event recorder, and the recording obtained after a syncope similar to the previous attacks was normal. An intracardiac electrophysiological study was performed and all measurements were normal, and no tachycardia could be induced. As his attacks continued, the event recorder was prescribed again. The electrocardiogram (ECG) recorded during a new syncope revealed 3:1 and 2:1 atrioventricular blocks (AVB) following two short complete AVB attacks (Figs. 1, 2).

Atrioventricular blocks occurred without P-P cycle lengthening, and the PR interval remained stable before and at the end of the pauses. The family refused permanent pacemaker implantation. The patient was followed, and at the last

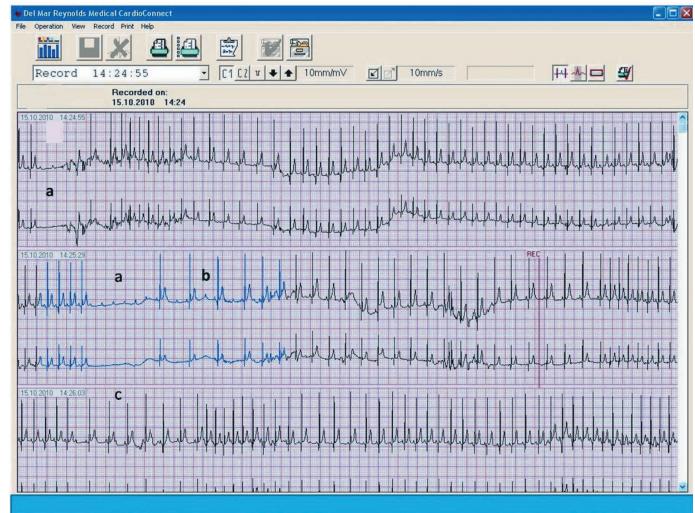

Fig. 1: The electrocardiogram recorded during a syncope revealed two short complete atrioventricular block attacks (a).

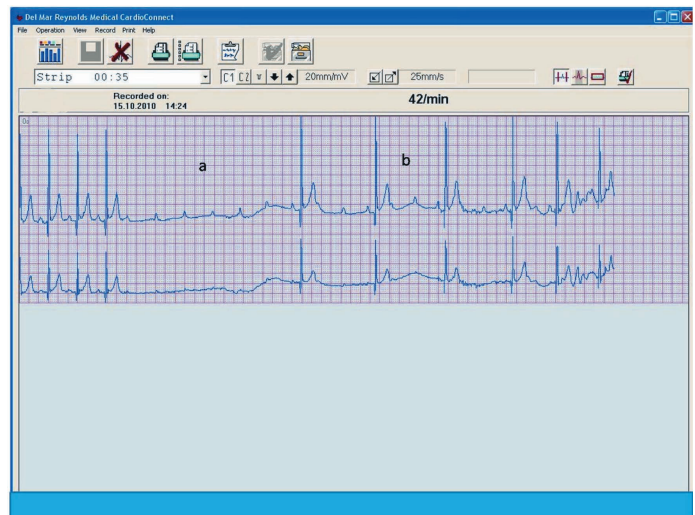


Fig. 2: 3:1 (b) and 2:1 (c) [in Fig.1] atrioventricular block periods followed the complete atrioventricular block attack (a).

visit (28 months after the diagnosis), he was still experiencing brief syncopal episodes. Electrocardiogram and Holter monitoring did not show progression to persistent AVB.

## DISCUSSION

Syncope is defined as sudden transient loss of consciousness, usually leading to falling (2). In addition to structural cardiac diseases, arrhythmias can also cause syncope (2). Tachyarrhythmias with a high heart rate, either supraventricular or ventricular, may critically decrease the cardiac output and result in syncope or sudden death (5). Bradyarrhythmias may also cause syncope. In children, high-grade AVB, either congenital or acquired, is the most commonly encountered cause of bradyarrhythmia causing syncope (6). The permanent form of high-grade AVB is a result of intrinsic disease of the AV conduction system [inflammatory, degenerative, congenital, *etc*]

(7, 8). There are various case reports of PAVB in adults with normal cardiac anatomy (3, 9, 10). Although there are case series of paediatric patients with PAVB in a normal heart (1, 4), the frequency of the disease among the causes of syncope is not known.

The paroxysmal form of the disease may be the result of an intrinsic disease of the AV conduction or the other known form of block, namely, vagal (extrinsic) PAVB (11). In the index case, the absence of any evidence of cardiac abnormalities, the younger age, and the outcome showing no progression of the block toward permanent forms for several years argue against an intrinsic cardiac aetiology. Non-inducibility of AVB by atrial, His, or ventricular premature extrasystole, increased heart rate (tachycardia-dependent AVB), and decreased heart rate (bradycardia-dependent AVB) are features that support a diagnosis of intrinsic AVB (12, 13). As most of these features were absent in our patient, intrinsic AVB was not considered.

At the first admission, the patient's syncopal episodes were defined with features consistent with vasovagal syncope (recurrent attacks while standing with prodromal symptoms). The head-up tilt table test revealed a vasodepressor-type response. Beta-blocker treatment resulted in resolution of this type of syncope, but the attacks with atypical features, which were also present prior to beta-blocker treatment, continued. We believed that there was another cause for these syncopal attacks.

The classic vagal effect on the conduction system includes gradual slowing of the sinus rate (P-P interval) and AV conduction (prolonging PR), which are occasionally followed by sinus arrest or complete AVB. The two conditions frequently coexist, indicating a simultaneous vagal action on the sinus node and AV node. Even when a more prominent AV response occurs, vagally mediated AVB is usually preceded by significant PR prolongation or Wenckebach; the P-P interval is also prolonged markedly during asystole, and there is significant PR prolongation on resumption of AV conduction (12–16). These features, which suggest an idiopathic PAVB, were absent in our patient's ECG during the event.

Elucidating the underlying cause of unexplained syncope can pose a clinical challenge, which is difficult yet worthwhile, as an underlying cardiac disease in patients with syncope is associated with higher rates of mortality and morbidity (17). An echocardiography can reveal the structural heart diseases; however, in patients in whom arrhythmia is suspected as the possible cause of the syncope, it is essential to make a symptom rhythm correlation. In patients with frequent attacks, symptom rhythm correlation can be achieved by 24-hour ECG monitoring. Nonetheless, the overall diagnostic yield of Holter monitoring is low. In a pooled analysis by Linzer *et al* (18) among patients with symptoms of syncope or presyncope, there was a 4% correlation between symptoms and arrhythmias with Holter monitoring for more than 12 hours (18). Monitoring with external loop recorders increases the rate of

symptom rhythm correlation [24%–47%] (19–21) and monitoring with an implantable loop recorder for a longer time has the highest diagnostic yield (22). As the patient's social security did not allow for the implantable recorder, it could not be used. Instead, a symptom rhythm correlation could be made during a second attempt with an external loop recorder.

In conclusion, our case suggests that two different mechanisms may be responsible for syncope in children. If clinical features are atypical, repeated monitoring with an external loop recorder may facilitate a diagnosis and catch some uncommon arrhythmias, such as PAVB.

## REFERENCES

1. Silver ES, Pass RH, Hordof AJ, Liberman L. Paroxysmal AV block in children with normal cardiac anatomy as a cause of syncope. *Pacing Clin Electrophysiol* 2008; **31**: 322–6.
2. The Task Force on Syncope, European Society of Cardiology. Guidelines on management (diagnosis and treatment) of syncope – update 2004. *Europace* 2004; **6**: 467–537.
3. Castellanos A, Moleiro F, Acosta H, Ferreira A, Cox MM, Interian A Jr et al. Sudden Wenckebach periods and their relationship to neurocardiogenic syncope. *PACE* 1998; **21**: 1580–8.
4. Silvetti MS, Grutter G, Di Ciommo V, Drago F. Paroxysmal atrioventricular block in young patients. *Pediatr Cardiol* 2004; **25**: 506–12.
5. Merghani A, Sharma S. Identifying patients at risk of sudden arrhythmic death. *Practitioner* 2012; **256**: 15–8.
6. Doniger SJ, Sharieff GQ. Pediatric dysrhythmias. *Pediatr Clin North Am* 2006; **53**: 85–105.
7. Ambrosi A, Wahren-Herlenius M. Congenital heart block: evidence for a pathogenic role of maternal autoantibodies. *Arthritis Res Ther* 2012; **14**: 208.
8. Batra AS, Epstein D, Silka MJ. The clinical course of acquired complete heart block in children with acute myocarditis. *Pediatr Cardiol* 2003; **24**: 495–7.
9. Brignole M, Gaggioli G, Menozzi C, Gianfranchi L, Bartoletti A, Bottoni N et al. Adenosine-induced atrioventricular block in patients with unexplained syncope. The diagnostic value of ATP testing. *Circulation* 1997; **96**: 3921–7.
10. Brignole M, Menozzi C. Methods other than tilt testing for diagnosing neurocardiogenic (neurally mediated) syncope. *PACE* 1997; **20**: 795–800.
11. Brignole M, Deharo JC, De Roy L, Menozzi C, Blommaert D, Dabiri L et al. Syncope due to idiopathic paroxysmal atrioventricular block: long-term follow-up of a distinct form of atrioventricular block. *J Am Coll Cardiol* 2011; **58**: 167–73.
12. Lee S, Wellens JJ, Josephson M. Paroxysmal atrioventricular block. *Heart Rhythm* 2009; **6**: 1229–34.
13. El-Sherif N, Jalife J. Paroxysmal atrioventricular block: are phase 3 and phase 4 block mechanisms or misnomers? *Heart Rhythm* 2009; **6**: 1514–21.
14. Sud S, Klein GJ, Skanes AC, Gula LJ, Yee R, Krahn AD. Implications of mechanism of bradycardia on response to pacing in patients with unexplained syncope. *Europace* 2007; **9**: 312–8.
15. Brignole M, Moya A, Menozzi C, Garcia-Civera R, Sutton R. Proposed electrocardiographic classification of spontaneous syncope documented by an implantable loop recorder. *Europace* 2005; **7**: 14–8.
16. Zysko D, Gajek J, Koźluk E, Mazurek W. Electrocardiographic characteristics of atrioventricular block induced by tilt testing. *Europace* 2009; **11**: 225–30.
17. Kapoor WN, Hanusa BH. Is syncope a risk factor for poor outcomes? Comparison of patients with and without syncope. *Am J Med* 1996; **100**: 646–55.
18. Linzer M, Yang EH, Estes NA 3rd, Wang P, Vorperian VR, Kapoor WN. Diagnosing syncope. Part 2: unexplained syncope. Clinical Efficacy Assessment Project of the American College of Physicians. *Ann Intern Med* 1997; **127**: 76–86.

19. Linzer M, Pritchett EL, Pontinen M, McCarthy E, Divine GW. Incremental diagnostic yield of loop electrocardiographic recorders in unexplained syncope. *Am J Cardiol* 1990; **66**: 214–9.
20. Cumbee SR, Pryor RE, Linzer M. Cardiac loop ECG recording: a new noninvasive diagnostic test in recurrent syncope. *South Med J* 1990; **83**: 39–43.
21. Brown AP, Dawkins KD, Davies JG. Detection of arrhythmias: use of a patient-activated ambulatory electrocardiogram device with a solid-state memory loop. *Br Heart J* 1987; **58**: 251–3.
22. Al Dhahri KN, Potts JE, Chiu CC, Hamilton RM, Sanatani S. Are implantable loop recorders useful in detecting arrhythmias in children with unexplained syncope? *Pacing Clin Electrophysiol* 2009; **32**: 1422–7.