

Original Article

Endothelin-1 and Nitric Oxide Levels in Exudative Age-Related Macular Degeneration

Yüksel Totan¹, MD; Cemile Koca², MD; Mesut Erdurmuş³, MD; Uğurcan Keskin⁴, MD
Ramazan Yiğitoğlu², MD

¹Department of Ophthalmology, Turgut Özal University Medical School, Ankara, Turkey

²Department of Biochemistry, Yıldırım Beyazıt University Medical School, Ankara, Turkey

³Department of Ophthalmology, Hacettepe University Medical School, Ankara, Turkey

⁴Department of Ophthalmology, Mustafa Kemal University Medical School, Hatay, Turkey

Abstract

Purpose: To evaluate plasma levels of endothelin-1 (ET-1) and nitric oxide (NO) in patients with exudative age-related macular degeneration (AMD).

Methods: In this study, ET-1 levels, as well as nitrite plus nitrate concentrations as an indicator of plasma NO level, were measured in the plasma of 20 subjects with exudative AMD and compared with 20 healthy age and sex matched controls.

Results: Mean plasma ET-1 level was significantly higher in exudative AMD patients as compared to control subjects (0.35 ± 0.06 fmol/ml versus 0.17 ± 0.03 fmol/ml, $P = 0.015$). Patients with exudative AMD also showed significantly lower mean plasma levels of nitrite plus nitrate as compared to the controls (58.9 ± 2.7 μ mol/l versus 82.6 ± 5.9 μ mol/l, $P = 0.001$).

Conclusion: Increased concentrations of ET-1 and reduced levels of NO in the plasma may suggest an imbalance between vasoconstrictor and vasodilator agents, respectively, as a reflection of endothelial dysfunction in the pathogenesis of AMD. These findings may also imply the role of vasoconstriction in exudative AMD.

Keywords: Age-related Macular Degeneration; Endothelial Dysfunction; Endothelin-1; Nitric Oxide

J Ophthalmic Vis Res 2015; 10 (2): 151-154.

INTRODUCTION

The precise etiopathogenesis of age-related macular degeneration (AMD) is still unknown; however, it is most probably a multifactorial disease of aging.

Correspondence to:

Mesut Erdurmuş, MD. Department of Ophthalmology, Hacettepe University Medical School, Sıhhiye, 06100 Ankara, Turkey.

E-mail: merdurmus@yahoo.com

Received: 12-09-2013

Accepted: 17-11-2014

Oxidative stress caused by free radicals,^[1,2] perfusion abnormalities^[3,4] and nutrition are believed to play a role in the pathogenesis of AMD. Involvement of oxidative damage and nitric oxide as a part of the vascular theory in the development of AMD has been previously reported.^[5]

Endothelial dysfunction (ED) is a systemic pathological condition occurring due to an imbalance between the vasodilating and vasoconstricting capacity of the endothelium in response to various physicochemical stimuli. Increased activity of a potent vasoconstrictor such as ET-1 may influence the vasodilating capacity of

This is an open access article distributed under the terms of the Creative Commons Attribution-NonCommercial-ShareAlike 3.0 License, which allows others to remix, tweak, and build upon the work non-commercially, as long as the author is credited and the new creations are licensed under the identical terms.

For reprints contact: reprints@medknow.com

How to cite this article: Totan Y, Koca C, Erdurmuş M, Keskin U, Yiğitoğlu R. Endothelin-1 and Nitric Oxide levels in exudative age-related macular degeneration. *J Ophthalmic Vis Res* 2015;10:151-4.

Access this article online

Quick Response Code:



Website:

www.jovr.org

DOI:

10.4103/2008-322X.163765

the endothelium along with aging.^[6] In an experimental study on rodents, aging was associated with an upregulation of ET-1 and a decrease in nitrite/nitrate levels in kidneys.^[7] Moreover, mRNA expression of the precursor of ET-1, pre-proendothelin-1, and ET-1 levels were increased in the aged rats' aorta.^[8]

Nitric oxide (NO) is influenced by a dynamic equilibrium between its synthesis and degradation in tissues. Free radicals rapidly inactivate NO. In normal physiological conditions, endogenous defense systems against oxidation maintain the equilibrium between NO synthesis and degradation by oxygen free radicals. However, this delicate balance may be altered, particularly in the course of aging and senile macular degeneration^[1,2,5] resulting in a reduced NO level and thus impaired vascular relaxation. Furthermore, various situations have been found to be associated with increased ET-1 and decreased NO availability which implies that these two elements have reciprocal regulation.^[9]

In the present study, we aimed to determine plasma levels of ET-1 and NO in patients with exudative AMD and compare them to age and sex matched controls.

METHODS

This study was performed on 20 patients including 13 female and 7 male subjects with wet type (exudative) AMD in at least one eye at the retina service of Turgut Özal University Medical School, Ankara, Turkey. Approval from the Institutional Review Board was obtained and all participants provided written informed consent. A detailed history was obtained from all participants. Ophthalmological examination included biomicroscopy, intraocular pressure measurement, dilated fundus examination, and fluorescein angiography. Exclusion criteria included ocular diseases such as significant cataracts and glaucoma, and retinal diseases except AMD. Subjects with systemic diseases (except controlled systemic hypertension and atherosclerosis) and patients using antioxidant vitamins which may interact with plasma ET-1 or NO levels were also excluded. Twenty age and sex matched healthy individuals without AMD including 11 female and 9 male subjects served as the control group. No history of smoking was present in either study group.

Fasting venous blood samples from an antecubital vein were obtained, centrifuged and stored in Eppendorf tubes at -80°C until analysis. Plasma concentrations of ET-1 were determined in duplicate by enzyme-linked immunosorbent assay (ELISA) (Biomedica Medizinprodukte GmbH, Wien, Austria) according to the manufacturer's instructions.^[10] Results were expressed as fmol/ml.

The measurement method for plasma NO levels using plasma nitrite plus nitrate concentrations has

been described previously.^[11] In brief, determination of nitrite and nitrate concentrations was based on the Griess reaction. In this method, a chromophore with peak absorbance at 540 nm is formed through nitrite and naphthylethylenediamine and sulphanilamide mixture reaction. For quantification of nitrite levels, the absorbance was measured using a spectrophotometer (Ultraspec Plus, Pharmacia LKB Biochrom Ltd, Cambridge, UK). Nitrate concentration was detected by treating the samples with copperized cadmium in glycine buffer at pH of 9.7 for reducing nitrate to nitrite. Thus, the concentration was represented as the total nitrite plus nitrate. A standard curve was established with a set of serial dilutions of sodium nitrite. The plasma was studied in duplicate. The measurements were stated in $\mu\text{mol/l}$ units.

All statistical analyses were performed using SPSS Software (Version 15.0; SPSS, Chicago, IL, USA). Data were shown as mean \pm standard deviation for continuous variables, and frequency with percentage for categorical variables. Means were compared using Student *t* or Mann-Whitney *U* test, where appropriate. Pearson correlation test was used to investigate the relationship between ET-1 and NO levels in the groups. Categorical comparisons were made using Chi-square test. *P* values less than 0.05 were considered as statistically significant.

RESULTS

Mean age in the exudative AMD and control groups was 71.6 ± 5.5 and 69.4 ± 6.6 years, respectively. There was no significant difference between AMD and control subjects in terms of age ($P = 0.26$) and sex ($P = 0.52$).

Mean plasma ET-1 level in patients with exudative AMD was 0.35 ± 0.06 (median, 0.21) fmol/ml which was significantly higher than that in the control group which was 0.17 ± 0.03 (median, 0.14) fmol/ml ($P = 0.015$). Plasma nitrite plus nitrate levels were significantly lower in the exudative AMD group (mean, 58.9 ± 2.7 ; median $57.7 \mu\text{mol/l}$) as compared to the control group (mean, 82.6 ± 5.9 ; median, $77.8 \mu\text{mol/l}$, $P = 0.001$). A significant negative correlation ($r = -0.47$, $P = 0.036$) was found between plasma ET-1 levels and nitrite plus nitrate levels in the exudative AMD group. Box plot graphs of plasma ET-1 and nitrite plus nitrate levels in the study groups are shown in Figures 1 and 2, respectively.

DISCUSSION

AMD is the leading cause of blind registration in the developed world.^[12] Despite intensive research, the precise etiology of molecular events that underlie AMD is poorly understood. Advanced age is the main risk factor, however there are other factors associated with AMD including cigarette smoking, elevated levels of cholesterol, systemic arterial hypertension,

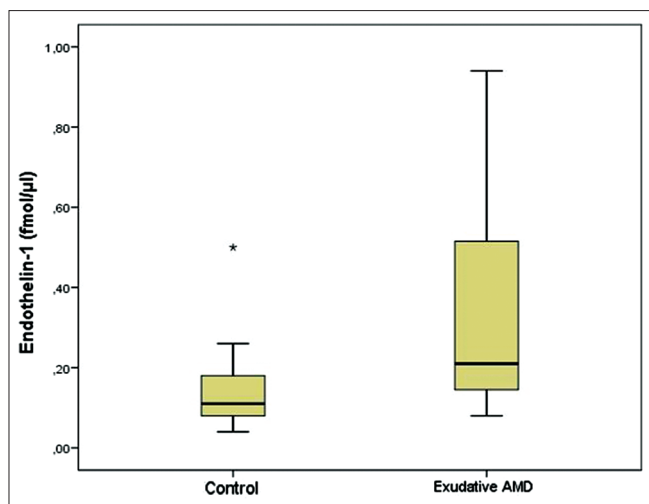


Figure 1. Box plot graph of plasma endothelin-1 levels in patients with exudative age-related macular degeneration and control subjects.

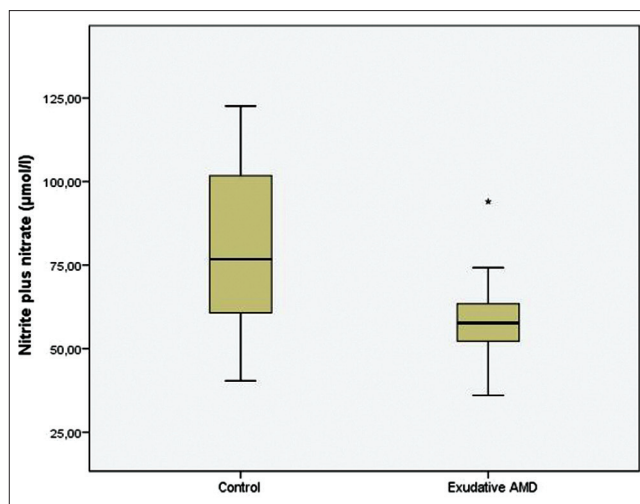


Figure 2. Box plot graph of plasma nitrite plus nitrate levels in patients with age related macular degeneration and control subjects.

ultraviolet exposure, cardiovascular disease, systemic arterial stiffness, race, gender and family history.^[13-15] The majority of risk factors for AMD are themselves age-related including hypertension, cardiovascular disease, and total pack-years of cigarette smoking.^[16]

Oxidative stress has been implicated in many chronic disease processes such as AMD. The retina includes high levels of antioxidants, e.g., lutein and zeaxanthin to resist oxidative stress; however, it is particularly susceptible to oxidative injury due to its high oxygen consumption, high concentration of polyunsaturated fatty acids, continuous exposure to visible light, and high levels of blood flow and oxygen in the choriocapillaris.^[17] In an earlier study, increased levels of malondialdehyde (MDA), a reliable and commonly used biomarker for lipid peroxidation, and lower NO levels were detected in the plasma of patients with AMD as compared with control subjects.^[5]

Endothelial cells produce a number of vasoactive substances to modulate vascular function including the potent vasorelaxant NO and vasoconstrictor ET-1. These cells are also exposed to oxygen free radicals from both intracellular sources and products in the circulation. Thus, vascular function can be affected by oxidative stress through a number of mechanisms, such as the NO pathway. Oxidative damage to the vascular endothelium causes endothelial dysfunction with a resultant decrease in endothelial nitric oxide synthase (eNOS) activity leading to low levels of plasma NO. Impaired availability of NO is also associated with enhanced synthesis of ET-1 as a potent vasoconstrictor agent.^[18] Consequently, increased ET-1 and decreased NO levels may induce vasoconstriction in small caliber blood vessels and thus be partly associated with choriocapillaris ischemia in AMD patients.

Vascular endothelial growth factor (VEGF) is a major mediator of intraocular neovascularization

and permeability.^[19] Ischemia of the choriocapillaris and decreased NO content may cause VEGF increment and presumably play a role in choroidal neovascularization (CNV) in an eye with AMD. There is evidence that the choroidal blood flow is impaired in patients with AMD; however, the exact nature of damage has not been elucidated. Computer-assisted analysis of angiographic images revealed that the age-related decrease in foveal choriocapillaris blood flow is further attenuated in AMD patients.^[20,21] In eyes with AMD, there are watershed areas or areas of focal hypofluorescence in the macula; interestingly, CNV develops in these areas.^[22] Sakai et al^[23] reported elevated levels of ET-1 in patients with AMD as compared to control subjects. Our data suggest that age-related reduction of endothelial function through reciprocal regulation of the NO and ET-1 levels may explain decreased choroidal blood flow and to some extent the development of CNV in AMD.

Cardiovascular risk factors have been hypothesized as important pathogenetic factors for the development of AMD.^[12] Elevated plasma homocysteine level, a systemic biomarker of cardiovascular disease, is an independent risk factor for AMD.^[24] Furthermore, increased plasma homocysteine content is negatively correlated with decreased antioxidant capacity in subjects with exudative AMD^[25] supporting the results of the present and previous studies, which suggest the association of vascular and oxidative stress parameters and thus, the involvement of a more common basic mechanism underlying AMD, i.e. endothelial dysfunction.

The main variation attributed to endothelial dysfunction is reduction of NO availability due to increased free oxygen radicals. In addition to its vasodilating property, NO inhibits platelet aggregation and ET-1 synthesis and prevents the vascular bed from events leading to thrombosis and atherosclerosis,^[18]

which are also implicated in the pathogenesis of AMD.^[26] Therefore, endothelial dysfunction accompanied by overproduction of ET-1 and decreased NO levels, may play a key role in the occurrence or progression of AMD.

In conclusion, the increased ET-1 and reduced NO levels in patients with exudative AMD may induce microvascular constriction in the macular area with subsequent regional ischemia, which may be involved in VEGF upregulation and CNV formation.

Financial Support and Sponsorship

Nil.

Conflicts of Interest

There are no conflicts of interest.

REFERENCES

- Delcourt C, Cristol JP, Léger CL, Descomps B, Papoz L. Associations of antioxidant enzymes with cataract and age-related macular degeneration. The POLA Study. *Pathologies Oculaires Liées à l'Age. Ophthalmology* 1999;106:215-222.
- Hogg R, Chakravarthy U. AMD and micronutrient antioxidants. *Curr Eye Res* 2004;29:387-401.
- Pemp B, Schmetterer L. Ocular blood flow in diabetes and age-related macular degeneration. *Can J Ophthalmol* 2008;43:295-301.
- Harris A, Chung HS, Ciulla TA, Kagemann L. Progress in measurement of ocular blood flow and relevance to our understanding of glaucoma and age-related macular degeneration. *Prog Retin Eye Res* 1999;18:669-687.
- Totan Y, Cekiç O, Borazan M, Uz E, Sögüt S, Akyol O. Plasma malondialdehyde and nitric oxide levels in age related macular degeneration. *Br J Ophthalmol* 2001;85:1426-1428.
- Matz RL, Andriantsitohaina R. Age-related endothelial dysfunction: Potential implications for pharmacotherapy. *Drugs Aging* 2003;20:527-550.
- Barton M, Lattmann T, d'Uscio LV, Lüscher TF, Shaw S. Inverse regulation of endothelin-1 and nitric oxide metabolites in tissue with aging: Implications for the age-dependent increase of cardiorenal disease. *J Cardiovasc Pharmacol* 2000;36:S153-S156.
- Goettsch W, Lattmann T, Amann K, Szibor M, Morawietz H, Münter K, et al. Increased expression of endothelin-1 and inducible nitric oxide synthase isoform II in aging arteries *in vivo*: Implications for atherosclerosis. *Biochem Biophys Res Commun* 2001;280:908-913.
- Rossi GP, Seccia TM, Nussdorfer GG. Reciprocal regulation of endothelin-1 and nitric oxide: Relevance in the physiology and pathology of the cardiovascular system. *Int Rev Cytol* 2001;209:241-272.
- Kinugawa T, Kato M, Ogino K, Osaki S, Igawa O, Hisatome I, et al. Plasma endothelin-1 levels and clinical correlates in patients with chronic heart failure. *J Card Fail* 2003;9:318-324.
- Cortas NK, Wakid NW. Determination of inorganic nitrate in serum and urine by a kinetic cadmium-reduction method. *Clin Chem* 1990;36:1440-1443.
- Ambati J, Ambati BK, Yoo SH, Ianchulev S, Adamis AP. Age-related macular degeneration: Etiology, pathogenesis, and therapeutic strategies. *Surv Ophthalmol* 2003;48:257-293.
- Silva R, Cachulo ML, Fonseca P, Bernardes R, Nunes S, Vilhena N, et al. Age-related macular degeneration and risk factors for the development of choroidal neovascularisation in the fellow eye: A 3-year follow-up study. *Ophthalmologica* 2011;226:110-118.
- Sato E, Feke GT, Appelbaum EY, Menke MN, Trempe CL, McMeel JW. Association between systemic arterial stiffness and age-related macular degeneration. *Graefes Arch Clin Exp Ophthalmol* 2006;244:963-971.
- Ehrlich R, Kheradiya NS, Winston DM, Moore DB, Wirosko B, Harris A. Age-related ocular vascular changes. *Graefes Arch Clin Exp Ophthalmol* 2009;247:583-591.
- Hawkins BS, Bird A, Klein R, West SK. Epidemiology of age-related macular degeneration. *Mol Vis* 1999;5:26.
- Beatty S, Koh H, Phil M, Henson D, Boulton M. The role of oxidative stress in the pathogenesis of age-related macular degeneration. *Surv Ophthalmol* 2000;45:115-134.
- Vanhoutte PM. Endothelial dysfunction and atherosclerosis. *Eur Heart J* 1997;18 Suppl E: E19-E29.
- Kalouda P, Anastasakis A, Tsika C, Tsilimbaris KM. The effect of intravitreal anti-VEGF on the pigment epithelial detachment in eyes with the exudative type of age-related macular degeneration. *Semin Ophthalmol* 2015;30:6-10.
- Grunwald JE, Hariprasad SM, DuPont J. Effect of aging on foveolar choroidal circulation. *Arch Ophthalmol* 1998;116:150-154.
- Grunwald JE, Hariprasad SM, DuPont J, Maguire MG, Fine SL, Brucker AJ, et al. Foveolar choroidal blood flow in age-related macular degeneration. *Invest Ophthalmol Vis Sci* 1998;39:385-390.
- Ross RD, Barofsky JM, Cohen G, Baber WB, Palao SW, Gitter KA. Presumed macular choroidal watershed vascular filling, choroidal neovascularization, and systemic vascular disease in patients with age-related macular degeneration. *Am J Ophthalmol* 1998;125:71-80.
- Sakai T, Matsushima M, Tsuneoka H. Endothelin-1 in neovascular AMD. *Ophthalmology* 2011;118:1217.e1.
- Rochtchina E, Wang JJ, Flood VM, Mitchell P. Elevated serum homocysteine, low serum vitamin B12, folate, and age-related macular degeneration: The Blue Mountains Eye Study. *Am J Ophthalmol* 2007;143:344-346.
- Coral K, Raman R, Rathi S, Rajesh M, Sulochana KN, Angayarkanni N, et al. Plasma homocysteine and total thiol content in patients with exudative age-related macular degeneration. *Eye (Lond)* 2006;20:203-207.
- Vine AK, Stader J, Branham K, Musch DC, Swaroop A. Biomarkers of cardiovascular disease as risk factors for age-related macular degeneration. *Ophthalmology* 2005;112:2076-2080.