

Effects of Fuchs uveitis syndrome on the ultrastructure of the anterior lens epithelium: A transmission electron microscopic study

Kemal Tekin, Yasemin Ozdamar Erol, Mustafa Fevzi Sargon¹, Merve Inanc, Pinar Cakar Ozdal, Nilufer Berker

Purpose: The purpose of the study was to investigate the electron microscopic findings of the lens epithelial cells (LECs) in patients with Fuchs uveitis syndrome (FUS) who suffered from cataracts and to compare those with age-matched controls. **Methods:** This study was a prospective, comparative case series. The anterior lens capsules (ALC: basement membrane and associated LECs) were taken from 12 eyes of 12 cases of FUS and ten eyes of ten control patients. The ALCs were obtained from cataract surgery and prepared for transmission electron microscopy (TEM). **Results:** There were no statistically significant differences regarding the age or gender between the FUS group and the control group ($P > 0.05$). In the TEM examinations of the ALCs, all of the FUS cases revealed similar significant ultrastructural changes when compared to the control patients. In the FUS group, the LECs showed homogeneous thickening and irregularity which included some small vacuoles in different areas of the epithelial tissue. Moreover, in some areas of the LECs, widespread, oval-shaped, pigment clusters were detected. Conversely, in the control group, the LECs and all of their elements were in normal ultrastructural patterns, with the exception of some small intraepithelial vacuoles which were fewer and smaller than those in the FUS group. **Conclusion:** Ultrastructural analysis of the ALC of the patients with FUS disclosed some significant alterations which may be related to the summation of oxidative stress, intraocular inflammation, and iris atrophy.

Key words: Fuchs uveitis syndrome, lens epithelium, transmission electron microscopy, ultrastructure

Fuchs uveitis syndrome (FUS) is an uncommon uveitic entity which accounts for 1%–6% of all uveitis cases.^[1,2] Although its etiology remains controversial, associations with ocular toxoplasmosis, herpes simplex, and the rubella virus have been implicated in its pathogenesis.^[3,4] The diagnosis of FUS is based mainly on the clinical picture, which is characterized by typically unilateral, low grade, chronic anterior uveitis.^[5,6] The classic ocular features of FUS include characteristic, diffusely spread, small- or medium-sized stellate keratic precipitates (KPs), low-grade anterior uveitis, diffuse iris stromal atrophy with or without heterochromia, and the presence of cells and opacities in the anterior vitreous fluid.^[7,8] The most damaging complications of FUS are secondary open-angle glaucoma and cataracts.^[8] Unfortunately, the occurrence of cataractogenesis secondary to intraocular inflammation remains unclear.

The avascular lens consists of three different components, the capsule, epithelium, and lens fibrils and is nourished by the intraocular environment (aqueous humor and vitreous fluid) in which it is located.^[9] The anterior lens capsule (ALC) and the epithelium are the primary targets of different stressors originating from the interior of the eye and the environment.^[10,11] Morphological studies of the ALC and epithelium have revealed different alterations in their ultrastructure in age-related cataracts.^[12-14] However,

the ultrastructure of the ALC and epithelium in FUS-related cataracts has not been studied extensively. Therefore, the aim of this study was to investigate the transmission electron microscopic findings of the lens epithelial cells (LECs) in patients with FUS and to compare those with age-matched controls.

Methods

This prospective, comparative study was performed at a single institution from August 2015 to December 2016. The study protocol was approved by the Ethics Committee, and the study was carried out in accordance with the Declaration of Helsinki. Since the cataract morphology may be associated with ultrastructural changes in the lens capsule and epithelium, only those patients with posterior subcapsular cataracts (PSCs) were included in this study.

The ALCs (ALC: basement membrane and associated LECs) were obtained from 12 eyes of 12 consecutive cases of FUS that were followed up at our uvea department and undergoing cataract surgery for visually significant subcapsular cataracts during this period in our institution (FUS group). The diagnosis

This is an open access article distributed under the terms of the Creative Commons Attribution-NonCommercial-ShareAlike 3.0 License, which allows others to remix, tweak, and build upon the work non-commercially, as long as the author is credited and the new creations are licensed under the identical terms.

For reprints contact: reprints@medknow.com

Cite this article as: Tekin K, Erol YO, Sargon MF, Inanc M, Ozdal PC, Berker N. Effects of Fuchs uveitis syndrome on the ultrastructure of the anterior lens epithelium: A transmission electron microscopic study. *Indian J Ophthalmol* 2017;65:1459-64.

Department of Ophthalmology, Ulucanlar Eye Training and Research Hospital, ¹Department of Anatomy, Hacettepe University, Ankara, Turkey

Correspondence to: Dr. Kemal Tekin, Department of Ophthalmology, Kars State Hospital, 36000, Kars, Turkey. E-mail: kemal_htepe@hotmail.com

Manuscript received: 05.08.17; Revision accepted: 09.10.17

Access this article online

Website:

www.ijo.in

DOI:

10.4103/ijo.IJO_691_17

Quick Response Code:



of FUS was made based on the clinical features including a lack of acute symptoms such as pain, photophobia, or ciliary injection; characteristic diffusely spread small or medium-sized KPs; a chronic low-grade anterior chamber reaction; diffuse iris stromal atrophy, with or without heterochromia; or a lack of posterior synechiae, a lack of cystoid macular edema, retinal vasculitis, snowbanks, or chorioretinal infiltrates, despite the presence of vitreous cells and debris or cells and opacities in the anterior vitreous. A detailed medical history was obtained in all of the cases including previous diagnoses, therapy, and surgical interventions (if any). All of the patients were in remission at the time of the cataract surgery. The exclusion criteria for the FUS group included trauma, a history of previous intraocular surgery, a history of bilateral uveitis, corneal abnormalities, and other immune-mediated or infectious diseases.

The control group included ten eyes of ten patients with idiopathic subcapsular cataracts who were operated on at the same institution and during the same time period. For the control group, patients with any of the following conditions were excluded: a history of any systemic disease or uveitis, ocular trauma or ocular surgery, a history of steroid usage of any form, chronic use of topical ocular medications, patients with an intraocular pressure (IOP) of >21 mmHg through applanation tonometry, the appearance of a glaucomatous optic nerve, corneal disease, retinal disease, neurological disease, or other diseases of the visual pathways.

All of the participants underwent comprehensive ophthalmic examinations including the best-corrected visual acuity using the Snellen chart, an intraocular pressure measurement, slit-lamp biomicroscopy, dilated fundoscopy, and an intraocular lens (IOL) power assessment using the Sanders-Retzlaff-Kraff-II formula. A fundus fluorescein angiography was also performed in selected FUS cases to rule out subclinical retinal vasculitis and macular edema.

Surgical procedure

All of the cases underwent uncomplicated phacoemulsification surgeries including anterior capsulorhexis, phacoemulsification, and primary IOL implantation through a clear corneal incision under local anesthesia. All of the operations were performed using the Alcon Infinity Vision System Phacoemulsification Machine (Alcon Laboratories, Fort Worth, TX, USA) by the same surgeons. The anterior chamber was entered using a 2.8 mm keratome at the limbus, and an ophthalmic viscosurgical device was injected into the anterior chamber. An anterior capsule flap was created, anterior capsulorhexis was performed.

During the capsulorhexis, the ALC was opened with a cystotome, and capsulorhexis forceps were used to meticulously perform a continuous curvilinear capsulorhexis. Every attempt was made to keep the size of the anterior capsulorhexis between 5.0 and 5.5 mm. The central circle of the ALC was removed from the eye with the aid of a viscoelastic cushion and gentle forceps manipulation to minimize the mechanical trauma. The ALC materials that were obtained were sent to the histopathology department immediately after surgery.

Electron microscopic analysis

The electron microscopic specialist had no information regarding the patients' conditions. The central 1 mm × 1 mm areas of the ALC materials were used for electron microscopic evaluation for the consistency of FUS and control groups. The

tissue samples were put into 2.5% glutaraldehyde for 24 h for primary fixation; then, these samples were washed with Sorenson's phosphate-buffered solution (pH 7.4) and postfixed in 1% osmium tetroxide. After the postfixation, they were washed with the same buffer and dehydrated in increasing concentrations of an alcohol series. After dehydration, the tissues were washed with propylene oxide and embedded in epoxy resin; then, the semi-thin and ultrathin sections of the obtained tissue blocks were cut with an ultramicrotome (LKB Nova, Sweden). These semi-thin sections, which were about 2 μm in thickness, were stained with methylene blue and examined under a light microscope (Nikon, Japan). Following this procedure, trimming was done to the tissue blocks and their ultrathin sections, which were about 60 nm in thickness and taken by the same ultramicrotome. These ultrathin sections were stained with uranyl acetate and lead citrate and examined under a Jeol JEM 1200 EX (Japan) transmission electron microscope. The electron micrographs of the specimens were taken by the same microscope. The ALC wrinkles were not observed during the preparation of the tissues.

Statistical analysis

The study data were entered into the computer and analyzed using the Statistical Package for the Social Sciences for Windows version 22.0 (SPSS Inc., Chicago, IL, USA). The descriptive statistics were presented as the mean ± standard deviation, frequency distribution, and percentages. Pearson's Chi-squared and one sample Chi-squared tests were used in the analysis of the categorical variables. The quantitative variables were compared with Mann-Whitney U-test. The statistical significance level was set at $P < 0.05$.

Results

This study included 22 eyes of 22 patients; 12 of them were in the FUS group, and the remaining 10 were in the control group. The FUS group consisted four men and eight women with a mean age of 41.00 ± 9.56 years old (range: 28–56), whereas the controls included four men and six women with a mean age of 45.30 ± 7.98 years old (range: 32–57). There were no statistically significant differences regarding the age or gender between the FUS group and controls ($P > 0.05$).

In the transmission electron microscopic examinations of the ALCs, all of the FUS cases revealed significant ultrastructural changes when compared to the control group. Similar ultrastructural alterations were observed in all of the ALC samples of the FUS cases. In the FUS group, the LECs showed homogeneous thickening and irregularity [Fig. 1], which included some small vacuoles in different areas of the epithelial tissue as a remarkable alteration [Figs. 1-3]. Moreover, in some areas of the LECs, widespread, oval-shaped, pigment clusters were detected [Fig. 4]. Conversely, in the controls, the LECs and all of their elements were in normal ultrastructural patterns, with the exception of some small intraepithelial vacuoles [Fig. 5]. Neither epithelial thickening nor pigment clusters were seen in the control group; however, some small intraepithelial vacuoles, which were fewer and smaller than those in the FUS group, were also seen in the controls [Fig. 5].

Discussion

In this study, we investigated the transmission electron microscopic findings of LECs in patients with FUS who




Figure 1: Electron micrograph of the lens capsule specimen in a Fuchs uveitis syndrome case demonstrating some small vacuoles in an irregularly thickened lens epithelium. The stars indicate the thickened epithelium and the arrows indicate the intraepithelial vacuoles




Figure 2: Electron micrograph of a patient with Fuchs uveitis syndrome showing some irregular intraepithelial vacuoles and a normal euchromatic nucleus in an irregularly thickened lens epithelium. n: Euchromatic nucleus, b: Basal membrane

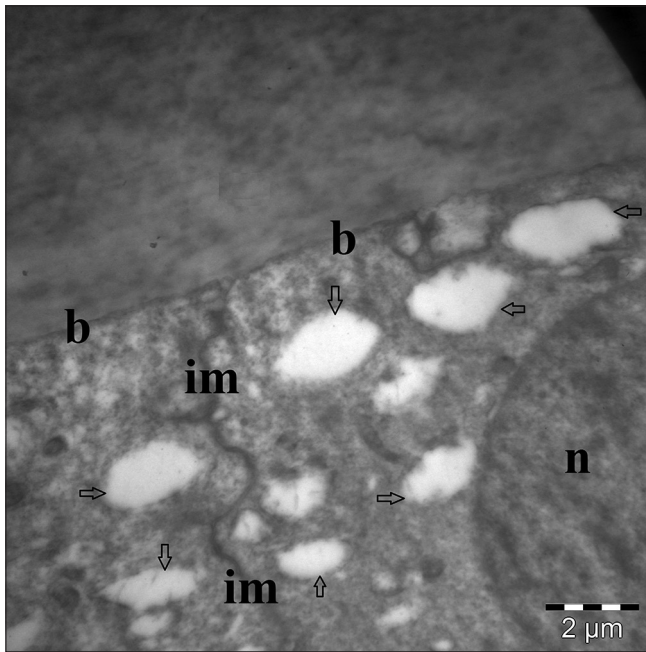


Figure 3: Electron micrograph of a patient with Fuchs uveitis syndrome showing some irregular intraepithelial vacuoles and a normal euchromatic nucleus. n: Euchromatic nucleus, b: Basal membrane, im: Intercellular membrane. The vacuoles are demonstrated with arrows.




Figure 4: Electron micrograph of the lens capsule of a patient with Fuchs uveitis syndrome revealing widespread, oval-shaped, pigment clusters. p: Pigment clusters, im: Intercellular membrane, n: Euchromatic nucleus

suffered from cataracts and compared them with age-matched cases with idiopathic subcapsular cataracts. All of the ALCs of the FUS cases showed similar significant ultrastructural changes. To the best of our knowledge, this is the most comprehensive study evaluating the histopathological

alterations in the LECs of the patients with FUS-associated cataracts.

The lens capsule is produced anteriorly by the lens epithelium and posteriorly by the elongating lens fibers and completely surrounds the lens. It is the thickest basement membrane, with

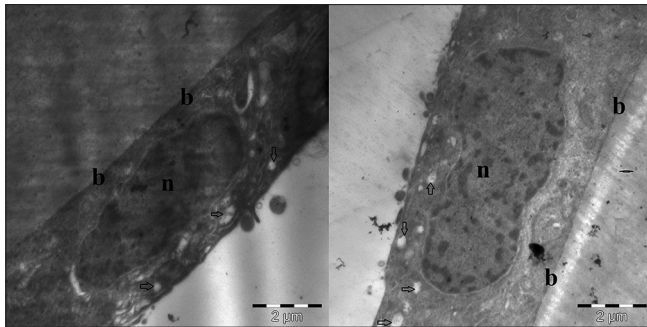


Figure 5: Electron micrographs of two different patients in the control group revealing some relatively small intraepithelial vacuoles. The lens epithelial cells are normal, flattened, cuboidal, and hexagonal in shape, and all of the elements are in a normal ultrastructural pattern, except some small intraepithelial vacuoles. n: Nucleus, b: Basal membrane. The small vacuoles are demonstrated with arrows

a special transparent structure and function in the human body.^[15] When examined under light microscopy, the normal lens capsule appears to be dense and homogeneous; when examined under an electron microscope, it consists of parallel lamellae more tightly packed toward the outer surface.^[15] Moreover, it exhibits a special structure containing Type IV collagen, laminin, and sulfated glycosaminoglycans.^[16,17] The anterior LECs contain a round nucleus with a few apically distributed organelles, are flattened, cuboidal, and hexagonal in shape, and are tightly packed into a single layer with very little intercellular space.^[18] In addition to their physical and mechanical roles, the lens capsule and epithelium act as a regulatory barrier between the aqueous humor and the lens fibers.^[18] This also permits the passive exchange of metabolic substrates, expulsion of waste, and selective filtering of molecules based on the size and charge, which play essential roles in preserving the lens transparency.^[16-20] Any factors that disturb the organization of the macromolecular network of the lens capsule and epithelium are thought to facilitate the passage of water, ions, and possibly larger molecules across the basement membrane, leading to cataract formation.^[20,21]

Cataracts are the primary cause of decreased visual acuity and the most common complications in patients with FUS.^[5,22] The cataract rate ranges from 15% to 80% in patients with FUS.^[22,23] This broad variation may be explained by differences in the disease duration and in the chronic nature of the disease.^[23] It usually begins as PSC similar to that which occurs secondary to other types of chronic uveitis. PSC pathologically associated with the posterior migration of LECs beneath the lens capsule behind the lens equator where the monolayer of anterior lens epithelium normally terminates.^[24,25] Eshaghian and Streeten^[26] investigated the ultrastructure of these posteriorly migrating LECs in 13 human lenses with PSC. They showed that these migrating LECs contributed to the cataractogenesis through secretion, cytolysis, and probably by release of lysosomal enzymes. Although the exact mechanism of FUS-related cataract is not known, it may develop due to changes in the lens permeability resulting from recurrent uveitic attacks.^[27,28] In addition, unnecessary steroid treatment increases the risk of cataractogenesis in patients with FUS. Synder *et al.*^[29] analyzed the ultrastructure of LECs in different types of human cataracts by light and electron microscopy and for cellular characteristics by immunohistochemistry.

They revealed the consecutive degenerative changes which were observed in most of the LECs: multilayered cells, nuclei of abnormal diameters and shapes, and vacuolation of nuclei and cytoplasm. In addition, LECs were immunohistochemically positive for cytokeratin and vimentin or only for vimentin in all types of cataract. In another study, Nagata *et al.*^[30] investigated the ultrastructure of twenty eyes with PSC and revealed the following changes: markedly swollen and liquefied lens fibers of the subcapsular cortex with various sized granules in 13 eyes, various vacuoles or wide separations of the cell membrane in four eyes, and high electron density narrow lens fibers in three eyes. In addition, Greiner and Cyclack^[31] evaluated the histopathological features of anterior, equatorial, and posterior regions of five steroid-associated cataracts. They also compared the results with five age-matched senile PSCs and five nuclear cataractous lenses with no cortical opacities. They found the same basic histopathologic abnormalities in steroid-associated cataracts and in nonsteroid PSCs. However, in our study, the ultrastructure of the LECs in FUS group was different from the age-matched controls, even if all the patients in the study had PSCs. It might support that FUS-related cataractogenesis is complicated and not only associated with steroid usage.

In our study, all of the FUS cases showed some lens epithelial changes including homogeneous thickening with small intraepithelial vacuoles. However, some small intraepithelial vacuoles, which were fewer and smaller than those in the FUS group, were also seen in the control group. The ALC and the lens epithelium are the first targets of different stressors from the eye interior and the environment.^[10,11] In recent years, oxidative damage to the lens and associated structures by free oxygen radicals has been shown to play a role in the pathogenesis of lens opacification. Studies have shown that oxidative stress can cause a variety of morphological changes in the LECs including the formation of perinuclear vacuoles and intercellular spaces, mitochondrial swelling, chromatin condensation, and thinning and irregularity of the epithelium in age-related cataracts.^[32-34]

Synder *et al.*^[29] evaluated the characteristics of cataract changes in LECs and reported the following consecutive degenerative changes in most of these cells: multilayered cells, nuclei with abnormal diameters and shapes, and vacuolization of the nuclei and cytoplasm. We suppose that while the small intraepithelial vacuoles, which were seen in both groups, could have been caused by oxidative stress, the epithelial thickening could have been caused by the summation of oxidative stress and intraocular inflammation. In addition, we presume that additional intraocular inflammation may have caused the increase in the count and size of the intraepithelial vacuoles in the FUS group.

Similarly, Stunf *et al.*^[35] investigated the ultrastructure of the ALC and lens epithelium in different types of uveitic cataracts and observed that all of the uveitic capsules showed ultrastructural changes at the level of the basement membrane, the capsular-epithelial border, and within the anterior LECs. They proposed that mild and moderate epithelial changes (segmental or diffuse) and vacuolization of the epithelial cellular cytoplasm with euchromatic nuclei, intercellular spaces, and detachment of the epithelium might be caused by oxidative stress. In addition, when the cells became fibroblast like, this might be have been caused by intraocular

inflammation in addition to oxidative stress. Fibroblast-like epithelial cells were only observed in their cases with idiopathic anterior uveitis, idiopathic panuveitis, sarcoidosis, or herpes simplex. None of the patients with FUS showed fibroblast-like epithelial cells, which was similar to our outcome, and this may have been related to the characteristic low-grade anterior uveitis of FUS.

Another remarkable alteration in the LECs was widespread, oval-shaped, pigment clusters, which were detected using transmission electron microscopy (TEM) in all of the FUS cases. However, in the preoperative biomicroscopic examination, none of the FUS patients showed pigment accumulation in the lens capsule, indicating that the intraepithelial pigment clusters could only be detected with TEM. Diffuse iris stromal atrophy with or without heterochromia is one of the diagnostic criteria for FUS. It has been shown that all of the layers of the iris, including the anterior border layer, stroma and posterior pigment epithelium, lose pigment, and volume.^[22,23] Some studies have revealed that although heterochromia is not a constant sign, iris stromal atrophy, which causes heterochromia, is always present in FUS cases.^[5,36,37] However, Tugal-Tutkun *et al.*^[22] reported 88.4% diffuse iris atrophy with 48.6% heterochromia in 172 patients with FUS. In addition, electron microscopic studies on iridectomy specimens from patients with FUS have shown a loss of anterior border cells, a decreased number of stromal melanocytes with smaller, irregular melanosomes, and degeneration of the iris pigment epithelium.^[38,39] We presumed that, in the process of iris atrophy in FUS, the pigmented iris cells may accumulate in the ALC and cause ultrastructural pigment clusters in the LECs even though this accumulation could not be detected through biomicroscopic examination in the early stages of FUS.

Our study did have a number of limitations. For instance, it consisted of a small sample size. In addition, we only included patients with PSCs since the ultrastructure of the lens capsule may differ in the other morphological types of cataracts. For this reason, these findings cannot be generalized based on this study alone. Moreover, the oxidative stress status and apoptosis factors of LECs could not be analyzed.

Conclusion

The ultrastructure of the LECs of the patients with FUS revealed some significant alterations such as epithelial thickening, intraepithelial vacuoles, and pigment clusters. These ultrastructural changes may have been related to the summation of oxidative stress, intraocular inflammation, and iris atrophy in FUS patients.

Financial support and sponsorship

Nil.

Conflicts of interest

There are no conflicts of interest.

References

- Kazokoglu H, Onal S, Tugal-Tutkun I, Mirza E, Akova Y, Ozyazgan Y, *et al.* Demographic and clinical features of uveitis in tertiary centers in Turkey. *Ophthalmic Epidemiol* 2008;15:285-93.
- Rathinam SR, Namperumalsamy P. Global variation and pattern changes in epidemiology of uveitis. *Indian J Ophthalmol* 2007;55:173-83.
- Cimino L, Aldigeri R, Parmeggiani M, Belloni L, Zotti CA, Fontana L, *et al.* Searching for viral antibodies and genome in intraocular fluids of patients with Fuchs uveitis and non-infectious uveitis. *Graefes Arch Clin Exp Ophthalmol* 2013;251:1607-12.
- Kreps EO, Derveaux T, De Keyser F, Kestelyn P. Fuchs' uveitis syndrome: No longer a syndrome? *Ocul Immunol Inflamm* 2016;24:348-57.
- Yang P, Fang W, Jin H, Li B, Chen X, Kijlstra A, *et al.* Clinical features of Chinese patients with Fuchs' syndrome. *Ophthalmology* 2006;113:473-80.
- Tandon M, Malhotra PP, Gupta V, Gupta A, Sharma A. Spectrum of Fuchs uveitic syndrome in a North Indian population. *Ocul Immunol Inflamm* 2012;20:429-33.
- Al-Mansour YS, Al-Rajhi AA, Al-Dhibi H, Abu El-Asrar AM. Clinical features and prognostic factors in Fuchs' uveitis. *Int Ophthalmol* 2010;30:501-9.
- Bonfioli AA, Curi AL, Orefice F. Fuchs' heterochromic cyclitis. *Semin Ophthalmol* 2005;20:143-6.
- Michael R, Bron AJ. The ageing lens and cataract: A model of normal and pathological ageing. *Philos Trans R Soc Lond B Biol Sci* 2011;366:1278-92.
- Spector A. Oxidative stress-induced cataract: Mechanism of action. *FASEB J* 1995;9:1173-82.
- Truscott RJ. Age-related nuclear cataract-oxidation is the key. *Exp Eye Res* 2005;80:709-25.
- Straatsma BR, Lightfoot DO, Barke RM, Horwitz J. Lens capsule and epithelium in age-related cataract. *Am J Ophthalmol* 1991;112:283-96.
- Joo CK, Lee EH, Kim JC, Kim YH, Lee JH, Kim JT, *et al.* Degeneration and transdifferentiation of human lens epithelial cells in nuclear and anterior polar cataracts. *J Cataract Refract Surg* 1999;25:652-8.
- Charakidas A, Kalogeraki A, Tsilimbaris M, Koukoulomatis P, Brouzas D, Delides G, *et al.* Lens epithelial apoptosis and cell proliferation in human age-related cortical cataract. *Eur J Ophthalmol* 2005;15:213-20.
- Danysh BP, Duncan MK. The lens capsule. *Exp Eye Res* 2009;88:151-64.
- Krag S, Andreassen TT. Mechanical properties of the human lens capsule. *Prog Retin Eye Res* 2003;22:749-67.
- Parmigiani CM, McAvoy JW. The roles of laminin and fibronectin in the development of the lens capsule. *Curr Eye Res* 1991;10:501-11.
- Bhat SP. The ocular lens epithelium. *Biosci Rep* 2001;21:537-63.
- Andley UP. The lens epithelium: Focus on the expression and function of the alpha-crystallin chaperones. *Int J Biochem Cell Biol* 2008;40:317-23.
- Andjelic S, Drašlar K, Hvala A, Lopic N, Strancar J, Hawlina M, *et al.* Anterior lens epithelial cells attachment to the basal lamina. *Acta Ophthalmol* 2016;94:e183-8.
- Meyer LM, Wegener AR, Holz FG, Kronschlager M, Bergmanson JP, Soderberg PG, *et al.* Ultrastructure of UVR-B-induced cataract and repair visualized with electron microscopy. *Acta Ophthalmol* 2014;92:635-43.
- Tugal-Tutkun I, Güney-Tefekli E, Kamaci-Duman F, Corum I. A cross-sectional and longitudinal study of Fuchs uveitis syndrome in Turkish patients. *Am J Ophthalmol* 2009;148:510-50.
- Jones NP. Fuchs' heterochromic uveitis: A reappraisal of the clinical spectrum. *Eye (Lond)* 1991;5(Pt 6):649-61.
- Al-Ghoul KJ, Novak LA, Kuszak JR. The structure of posterior subcapsular cataracts in the royal college of surgeons (RCS) rats. *Exp Eye Res* 1998;67:163-77.
- Eshagian J. Human posterior subcapsular cataracts. *Trans Ophthalmol Soc U K* 1982;102(Pt 3):364-8.

26. Eshaghian J, Streeten BW. Human posterior subcapsular cataract. An ultrastructural study of the posteriorly migrating cells. *Arch Ophthalmol* 1980;98:134-43.
27. Gupta R, Murray PI. Chronic non-infectious uveitis in the elderly: Epidemiology, pathophysiology and management. *Drugs Aging* 2006;23:535-58.
28. Hooper PL, Rao NA, Smith RE. Cataract extraction in uveitis patients. *Surv Ophthalmol* 1990;35:120-44.
29. Synder A, Omulecka A, Ratyńska M, Omulecki W. A study of human lens epithelial cells by light and electron microscopy and by immunohistochemistry in different types of cataracts. *Klin Oczna* 2002;104:369-73.
30. Nagata M, Matsuura H, Fujinaga Y. Ultrastructure of posterior subcapsular cataract in human lens. *Ophthalmic Res* 1986;18:180-4.
31. Greiner JV, Chylack LT Jr. Posterior subcapsular cataracts: Histopathologic study of steroid-associated cataracts. *Arch Ophthalmol* 1979;97:135-44.
32. Cheng HM, Fagerholm P, Chylack LT Jr. Response of the lens to oxidative-osmotic stress. *Exp Eye Res* 1983;37:11-21.
33. Nita M, Grzybowski A. The role of the reactive oxygen species and oxidative stress in the pathomechanism of the age-related ocular diseases and other pathologies of the anterior and posterior eye segments in adults. *Oxid Med Cell Longev* 2016;2016:3164734.
34. Berthoud VM, Beyer EC. Oxidative stress, lens gap junctions, and cataracts. *Antioxid Redox Signal* 2009;11:339-53.
35. Stunf S, Hvala A, Vidovič Valentinčič N, Kraut A, Hawlina M. Ultrastructure of the anterior lens capsule and epithelium in cataracts associated with uveitis. *Ophthalmic Res* 2012;48:12-21.
36. Norrsell K, Sjödel L. Fuchs' heterochromic uveitis: A longitudinal clinical study. *Acta Ophthalmol* 2008;86:58-64.
37. La Hey E, Baarsma GS, De Vries J, Kijlstra A. Clinical analysis of Fuchs' heterochromic cyclitis. *Doc Ophthalmol* 1991;78:225-35.
38. McCartney AC, Bull TB, Spalton DJ. Fuchs' heterochromic cyclitis: An electron microscopy study. *Trans Ophthalmol Soc U K* 1986;105(Pt 3):324-9.
39. Melamed S, Lahav M, Sandbank U, Yassar Y, Ben-Sira I. Fuch's heterochromic iridocyclitis: An electron microscopic study of the iris. *Invest Ophthalmol Vis Sci* 1978;17:1193-9.