

## Soft spot: the important zone at the standard posterior portal of shoulder arthroscopy

Burcu ERÇAKMAK<sup>1\*</sup>, Ceren GÜNENÇ BEŞER<sup>1</sup>, M. Hakan ÖZSOY<sup>2</sup>,  
M. Deniz DEMİRYÜREK<sup>1</sup>, Alp BAYRAMOĞLU<sup>3</sup>, K. Mutlu HAYRAN<sup>4</sup>

<sup>1</sup>Department of Anatomy, Faculty of Medicine, Hacettepe University, Ankara, Turkey

<sup>2</sup>Department of Orthopedic Surgery and Traumatology, Memorial Hospital, Ankara, Turkey

<sup>3</sup>Department of Anatomy, Faculty of Medicine, Acıbadem University, İstanbul, Turkey

<sup>4</sup>Department of Preventive Oncology, Faculty of Medicine, Hacettepe University, Ankara, Turkey

Received: 10.08.2017 • Accepted/Published Online: 25.11.2017 • Final Version: 23.02.2018

**Background/aim:** The localization of the standard posterior portal of shoulder arthroscopy and landmarks mentioned in the literature are unclear. The purpose of this prospective cadaveric study was to determine the localization of the standard posterior portal and its distance to the neural structures.

**Materials and methods:** One fresh frozen and 10 formalin-fixed adult cadaveric shoulders were dissected. In the beach chair position, a 5-mm trocar was placed anteroposteriorly from the superior edge of the subscapularis muscle, superior to the tip of the coracoid process and tangent to the glenoid. The relevant distances of the posterior exit point were measured.

**Results:** In all specimens, the exit point was a triangular fibrous area, between the posterior and lateral parts of the deltoid. Medial and inferior distances of the trocar to the posterolateral tip of the acromion were  $1.88 \pm 0.53$  cm and  $1.35 \pm 0.34$  cm and distances to the axillary and suprascapular nerves were  $4.54 \pm 1.08$  cm and  $2.54 \pm 0.85$  cm, respectively.

**Conclusion:** The most important finding of this study was the superficial localization of the soft spot between the posterior and lateral parts of deltoid.

**Key words:** Shoulder arthroscopy, posterior portal, soft spot, anatomy

### 1. Introduction

Shoulder arthroscopy is an accepted and frequently performed procedure that allows the detailed exploration of the complex three-dimensional configuration and anatomical structures of the glenohumeral joint with low risk (1-7).

There are many arthroscopic portals introduced in the literature; five of them are commonly used basic standard portals, and some are specific advanced portals that are applied for various pathologies. Basic portals are listed in the literature according to their anatomic locations. Two of these portals are posterior, two of them are anterior, and the last one is the superior portal (1,8).

The standard anterior portal is placed lateral to the tip of the coracoid process and inferior to the anterolateral corner of the acromion during shoulder arthroscopy. This process can be performed under direct visualization by inserting a spinal needle into the intraarticular triangle, which is formed between the biceps tendon, glenoid labrum, and humeral head, with two methods: outside-

in technique and inside-out technique (Wissinger rod/switching stick technique) (1,4). During the inside-out technique (Wissinger rod), first the posterior portal is established and then a Wissinger rod/switching stick is inserted through the scope sheath, parallel to the articular surface of the glenoid, and it is advanced up to the anterior capsule of the shoulder (1,5,6,9,10). The rod courses tangent to the posterior and anterior glenoid labrums and exits just proximal to the subscapularis tendon. Then an anterior incision is performed through the skin and capsule to allow the Wissinger rod/switching stick to penetrate the skin (11).

The standard posterior portal (SPP) is the first portal used by arthroscopic surgeons during shoulder arthroscopy (6,12,13). The SPP is the most effective and preferred portal, which allows excellent visualization of the glenohumeral joint, posterior glenoid cavity, and subacromial space with a lower risk than the other portals and also it paves the way for other approaches (1,6,9,12-14). In the literature the posterior portal has been classified

\* Correspondence: burcue@hacettepe.edu.tr

as posteroinferior, posterosuperior, and posterolateral with respect to the posterolateral corner of the acromion (5,8). The primary viewing portal is the posterosuperior one (8). The definition for the localization of the SPP in shoulder arthroscopy varies in the literature. In general, the SPP is parallel to the glenoid surface and it is located 2–3 cm inferior and 1–2 cm medial to the posterolateral corner of the acromion (2,4,5,8,9,13–15). Because this area is softer than the surrounding tissues during digital palpation, it is commonly called the “soft spot” (SS) (1–5,9,14,15). The localization of the SS is above the glenohumeral joint in the interval between the infraspinatus superiorly and teres minor inferiorly (1,14). Portal placement can be facilitated by palpating the bony structures and estimating the SS (4,14). The coracoid process is an essential reference point for portal placement (1,4). Although the bony landmarks are easily palpated, the muscles and the SS cannot be superficially palpated properly due to their deep locations. Especially in obese patients, determining the anatomical landmarks is much more difficult (6).

During the trocar entry of the arthroscope, improper placement of the portal may increase the risk of complications and result in visualization problems and iatrogenic injuries of the humeral head cartilage. In addition to this, direct injury to the neurovascular structures may also occur during portal placement. The structures that are at most risk are the suprascapular nerve medially and the axillary nerve and posterior humeral circumflexed vessels inferiorly (1–6,8,9).

The primary purpose of this study was to describe the proper definition of the most superficial localization of the SS by applying the inside-out technique in a reverse manner from the anteroposterior direction and to evaluate the risk of neural structure injuries while using a posterior portal.

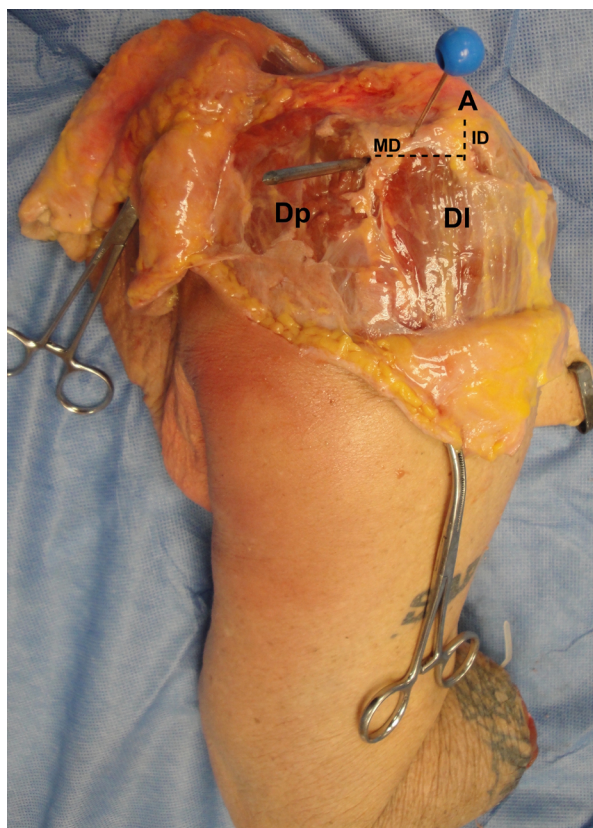
## 2. Material and methods

This prospective cadaveric study was carried out in the Hacettepe University Faculty of Medicine's Department of Anatomy between June 2012 and June 2014. One fresh frozen and 10 formalin-fixed (5 left, 6 right) adult cadaveric shoulders were dissected in the beach chair position. The specimens had neither massive rotator cuff lesions nor severe glenohumeral arthritis. In order to standardize the location of the entry of the SPP, a retrograde approach (anteroposterior) was selected. The anterior part of the shoulder was dissected, including the subscapularis tendon. A capsulotomy was performed proximal to the subscapularis. The tendon of the long head of the biceps and the anterior part of the glenoid were visualized. A 5-mm trocar was placed in the anteroposterior direction from the superior border of the subscapularis just below the tip of the coracoid. The trocar was inserted tangentially

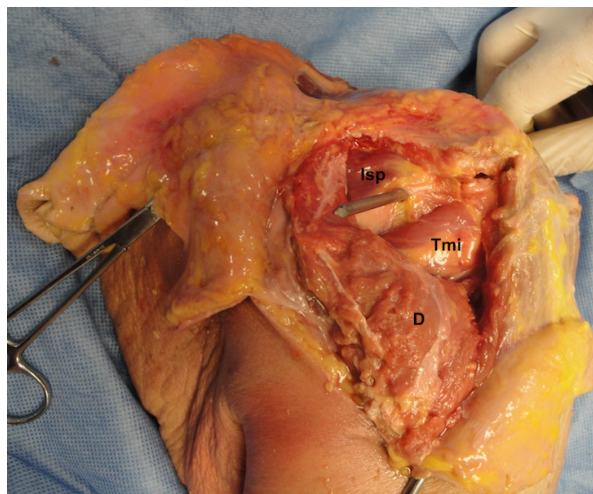
to the anterior and posterior rims of the glenoid, slightly touching them. Then the trocar was pushed to exit from the posterior surface of the shoulder region. Ultimately the posterior aspect of the shoulder was dissected in layers. The distances between the posterior exit point and the axillary nerve (AN) and suprascapular nerve (SN) were measured. In addition, the medial distance (MD) and inferior distance (ID) to the posterolateral tip of the acromion were also measured. The muscle injuries in the pathway of the trocar were recorded. Statistical analyses were performed using SPSS 15.

## 3. Results

In all specimens, the trocar was inserted into the glenohumeral cavity from the anteroposterior direction from the superior edge of the subscapularis muscle just below the tip of the coracoid process and the exit points were noted. As shown in Figures 1 and 2, the posterior exit points were between the posterior and lateral parts of the deltoid, which is a triangular fibrous area devoid of muscle fibers. The localization of the posterior portal



**Figure 1.** The posterior exit point between the posterior and lateral parts of deltoid. \*: Exit point, Dp: posterior part of deltoid, Dl: lateral part of deltoid, A: acromion, dashed lines: distances between exit point and posterolateral tip of the acromion, MD: medial distance, ID: inferior distance.

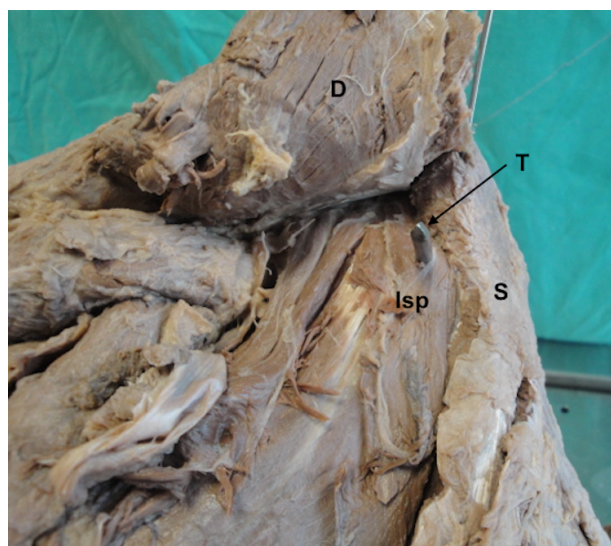


**Figure 2.** Trocar passing between deeply located teres minor and infraspinatus. Isp: Infraspinatus, Tmi: teres minor, D: deltoid.

varied between cadavers. Mean distances between the exit points and AN, SN, MD, and ID were  $4.54 \pm 1.08$  cm (range: 2.8–5.8 cm),  $2.54 \pm 0.85$  cm (range: 1.4–4.4 cm),  $1.88 \pm 0.53$  cm (range: 1.4–2.8 cm), and  $1.35 \pm 0.34$  mm (range: 0.9–2 cm), respectively. In six specimens, as shown in Figure 3, the infraspinatus muscles were injured by the trocar. In the rest of the cases, the trocar passed between the infraspinatus and teres minor.

#### 4. Discussion

In this study, a retrograde approach (inside-out technique) was used for the first time in the literature to define the exact location of the entry of the SPP. To date, all cadaveric



**Figure 3.** Infraspinatus muscle injured by the trocar. D: Deltoid, Isp: infraspinatus, T: trocar, S: spine of scapula.

studies related to SPP placement have been performed with an outside-in technique (2,3,5,9). The principal finding of this study is the location of the most superficial point of the SPP, which was between the posterior and lateral parts of the deltoid muscle.

The optimal entry point of the SPP is approximately 1 cm medial and 2 cm inferior to the posterolateral acromial edge in the SS (1,2,8). Andrews et al. defined the localization of the SS approximately 3 cm inferior and slightly medial to the posterolateral tip of the acromion (14). Wolf described a central posterior portal with the skin incision located 2 cm medial and 3 cm distal to the posterolateral corner of acromion on 78 fresh cadavers (16). DiFelice et al. studied six fresh frozen cadavers and placed the SPP at  $1.37 \pm 0.17$  cm medial and  $2.54 \pm 0.10$  cm inferior to the posterolateral edge of the acromion (2). Meyer et al. performed arthroscopy on 12 embalmed cadaveric shoulders through a point located 2 cm medial and 2 cm inferior to the posterolateral corner of the acromion (9). Espinosa-Urbe et al. used 13 embalmed cadaveric shoulders and placed the SPP at a point located 2 cm medial and 2 cm inferior to the posterolateral border of the acromion (3).

In this study, average distances between the SS and medial and inferior distances to the tip of the acromion were measured as  $1.88 \pm 0.53$  cm and  $1.35 \pm 0.34$  cm, respectively.

Di Giacomo et al. mentioned that the trocar pierces the posterior deltoid muscle and courses through the interval between the infraspinatus and teres minor muscles (1). Meyer et al. reported that in 1 of the 12 cases, the teres minor and infraspinatus muscles were injured by the trocar (9). In this study, the trocar coursed between the lateral and posterior parts of the deltoid muscle in all specimens and the exit points were located at the SS. In addition, six of the infraspinatus muscles were injured by the trocar and in the rest of the cases it passed through the deeply located interval between the infraspinatus and teres minor muscles, which is defined as the SS in the literature (1,14).

Neurovascular injuries related to shoulder arthroscopy are frequently reported in the literature (1,3,6,9). The structures that are at high risk of being injured during arthroscopy are the suprascapular artery and the axillary and suprascapular nerves (1,3,6,9). Brachial plexus injuries due to traction device and axillary nerve damage are often encountered after shoulder arthroscopy (13,17). Meyer et al. found that the axillary and suprascapular nerves were situated at mean distances of 49 mm and 29 mm from the portals, respectively. Also in this study, deeply located teres minor and infraspinatus muscles were injured (9). DiFelice et al. placed the SPP in the SS and the average distance of this portal from the subscapular nerve was  $2.88 \pm 0.30$  cm (2). Lo et al. found that the mean distance

from the SPP to the axillary nerve was 36.4 mm (5). In this study, the average distance of the SPP to the AN was  $4.54 \pm 1.08$  cm and to the SN was  $2.54 \pm 0.85$  cm.

The trocar was introduced at a predetermined and constant point. The exit point varied among individuals. The reason why the anterior to posterior insertion of the trocar was selected in this study was to standardize the superficial localization of the SS. Contrary to recent studies, the SS was found between the posterior and lateral parts of the deltoid. Placement of the SPP with respect to the acromial edge also varies between individuals because of their heights. Therefore, defining an exact distance for the SPP is not suitable. In this study, a retrograde approach (anteroposterior) was used to examine the exact location of the posterior exit point. With this method, the ideal entry point at the posterior shoulder, which was just parallel to the glenoid, as mentioned by Nord et al. (13), was sought.

According to these findings and the previous studies, this localization of SPP placement is considerably trustworthy.

The major limitation of this study is the number of cadaveric specimens. It is possible to mention a proper point for the SS that surgeons may easily find while placing the SPP. The most important finding in this cadaveric study is the anatomical definition of the SS. In all specimens, the trocar exited at the SS, an area consisting of fibrous tissue devoid of muscle fibers, between the posterior and lateral parts of the deltoid. Moreover, it was superficially located and palpable. Although previous studies defined the SS in the interval between the infraspinatus and teres minor muscles, we strongly recommend that it be located superficially between the lateral and posterior parts of deltoid.

## References

1. Di Giacomo G, Costantini A. Arthroscopic shoulder surgery anatomy: basic to advanced portal placement. *Oper Tech Sports Med* 2004; 12: 64-74.
2. DiFelice GS, Williams RJ, Cohen MS, Warren RF. The accessory posterior portal for shoulder arthroscopy. *Arthroscopy* 2001; 17: 888-891.
3. Espinosa-Urbe AG, Morales-Avalos R, Gutierrez-de la J, Garcia-de Leon OR, Torres-Garcia JK, Guzman-Avilan K, Vilchez-Cavazos F, de la Garza-Castro O, Guzman-Lopez S, Elizondo-Omana RE. Safe areas for the placement of standard shoulder arthroscopy portals. An anatomical study. *Int J Morphol* 2015; 33: 1386-1392.
4. Farmer KW, Wright TW. Shoulder arthroscopy: the basics. *J Hand Surg Am* 2015; 40: 817-821.
5. Lo IKY, Lind CC, Burkhart SS. Glenohumeral arthroscopy portals established using an outside-in technique: neurovascular anatomy at risk. *Arthroscopy* 2004; 20: 596-602.
6. Paxton ES, Backus J, Keener J, Brophy RH. Shoulder arthroscopy: basic principles of positioning, anesthesia, and portal anatomy. *J Am Acad Orthop Surg* 2013; 21: 332-342.
7. Bozkurt M, Simsek ME, Açar Hİ. Arthroscopic anatomy of shoulder. In: Bozkurt M, Açar Hİ, editors. *Clinical Anatomy of the Shoulder. An Atlas*. Berlin, Germany: Springer; 2017. pp. 17-23.
8. Caborn DNM, Fu FH. Arthroscopic approach and anatomy of the shoulder. *Oper Tech Orthop* 1991; 1: 126-133.
9. Meyer M, Graveleau N, Hardy P, Landreau P. Anatomic risks of shoulder arthroscopy portals: anatomic cadaveric study of 12 portals. *Arthroscopy* 2007; 23: 529-536.
10. Davidson PA, Tibone JE. Anterior-inferior (5 o'clock) portal for shoulder arthroscopy. *Arthroscopy* 1995; 11: 519-525.
11. Imhoff AB, Ansah P, Tischer T, Reiter C, Bartl C, Hench M, Spang JT, Vogt S. Arthroscopic repair of anterior-inferior glenohumeral instability using a portal at the 5:30-o'clock position: analysis of the effects of age, fixation method, and concomitant shoulder injury on surgical outcomes. *Am J Sports Med* 2010; 38: 1795-1803.
12. Goubier JN, Iserin A, Augereau B. The posterolateral portal: a new approach for shoulder arthroscopy. *Arthroscopy* 2001; 17: 1000-1002.
13. Nord KD, Brady PC, Yazdani RS, Burkhart SS. The anatomy and function of the low posterolateral portal in addressing posterior labral pathology. *Arthroscopy* 2007; 23: 999-1005.
14. Andrews JR, Carson WG Jr, Ortega K. Arthroscopy of the shoulder: technique and normal anatomy. *Am J Sports Med* 1984; 12: 1-7.
15. Mirouse G, Nourissat G. The split portal: description of a new accessory posterior portal for arthroscopic shoulder instability procedures. *Knee Surg Sports Traumatol Arthrosc* 2016; 24: 625-629.
16. Wolf EM. Anterior portals in shoulder arthroscopy. *Arthroscopy* 1989; 5: 201-208.
17. Iamsung C, Chernchujit B. The supine position for shoulder arthroscopy. *Arthrosc Tech* 2016; 5: e1117-e1120.