

A Variation of a Coeliac Trunk

By

Mehtap YUKSEL and Mustafa SARGON

Department of Anatomy, Faculty of Medicine, Hacettepe University, Ankara, TURKEY

— Received for Publication, April 14, 1992 —

Key Word: The coeliac trunk

Summary: The coeliac trunk is a wide branch of the abdominal aorta which arises from just below the aortic hiatus. It is about 1.25 cm. long (5). In our cadaver the length of the coeliac trunk was observed to be 4.5 cm. Additionally the inferior phrenic arteries which normally arise from the abdominal aorta were derived from the coeliac artery.

The ventral splanchnic arteries are usually paired vessels which are distributed to the capillary plexus in the wall of the yolk sac. After fusion of the dorsal aorta they merge as unpaired trunks distributed to the increasingly defined and lengthening primitive digestive tube forming dorsal and ventral splanchnic anastomoses. These vessels form many subdiaphragmatic vessels, and are later reduced to three;

- the coeliac trunk
- superior mesenteric artery
- inferior mesenteric artery (Fig. 1)

The coeliac trunk gives off its three main branches after it is derived from the abdominal aorta. These branches are;

- left gastric artery
- splenic artery
- common hepatic artery (5, 4, 1)

The other ventral branch of the abdominal aorta which is the superior mesenteric artery may rarely arise directly from the coeliac trunk or the coeliac trunk may have an intrathoracic origination of the artery³). The coeliac trunk may be incomplete when the right, or left hepatic artery arises from some other source (right hepatic artery from the superior mesenteric artery, left hepatic artery from the left gastric artery), thus constituting an incomplete hepatolienogastric trunk. The coeliac trunk may omit the left gastric artery, forming a hepatolienal trunk, or it may omit the hepatic artery in which case a lienogastric trunk is formed. Furthermore, the splenic artery may also be missing from the trunk, its absence resulting in the formation of a hepatogastric trunk. The coeliac trunk may also give origin to the dorsal pancreatic, inferior phrenic and although

rare, to the middle colic or accessory middle colic arteries¹).

Materials and Methods

We have encountered this variation during the dissection of a 60 year-old male cadaver in our department.

Case Report

During the dissection of the posterior abdominal wall, the coeliac trunk was found to be 4.5 cm. long in our cadaver. In addition to this variation, the inferior phrenic arteries which arise normally from the abdominal aorta as its first lateral branches were derived directly from the coeliac trunk (Fig. 1). The left phrenic artery originated from 1 cm. below the splenic artery while the right, from 2 cm. below the common hepatic artery (Figs. 2, 3).

We have also observed a few arteries which arose directly from the coeliac trunk, but the regions which they supplied were not clear.

Discussion

The coeliac trunk gives off three main branches in the abdomen. It arises from the abdominal aorta just below the aortic hiatus. The coeliac trunk may show variations in its origination and branches. It is normally 1.25 cm. long. If the coeliac trunk is of

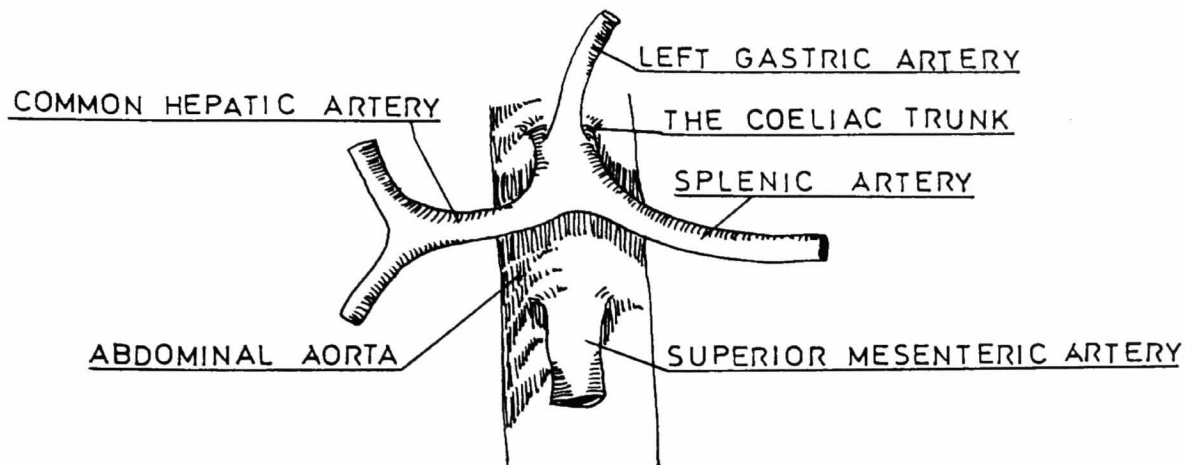


Fig. 1. The coeliac trunk

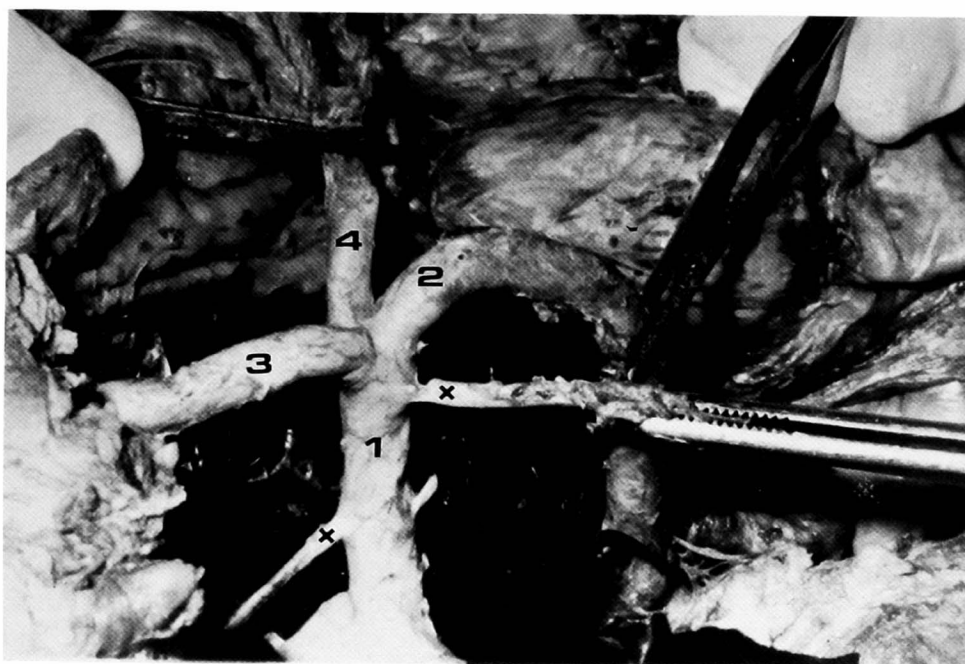


Fig. 2. 1. Coeliac trunk
2. Splenic artery
3. Common hepatic artery
4. Left gastric artery
*. Inferior phrenic arteries

greater length than normal, the surrounding tissues could be more liable to possible diseases. Also, compression of the coeliac trunk by the median arcuate ligament may be observed in addition to obstruction which may develop due to different causes²⁾.

Patients who come with stomach-ache and coeliac trunk compression syndrome should be evaluated according to a probable existence of a congenitally formed long coeliac trunk.

References

- 1) Netter, F. H.: Upper digestive trunk, Vol. 3, Part 1. The CIBA collection of medical illustrations, pp. 56-7, 1959.
- 2) Lord, R. S. A., Tracy, G. D.: Coeliac artery compression, Br. J. Surg, **67**: 590-93, 1980.
- 3) Gutnik, L. M.: Coeliac artery compression syndrome. The American Journal of Medicine, Volume. 76, pp. 334-6, 1984.
- 4) Moore, K. L. Clinically Oriented Anatomy. 2. Ed. Williams and Wilkins. pp. 283-85, 1985.
- 5) Williams, P. L., Warwick, R. Gray's Anatomy, 37. Ed., Churchill Livingstone, p. 218, pp. 766-7, 1989.

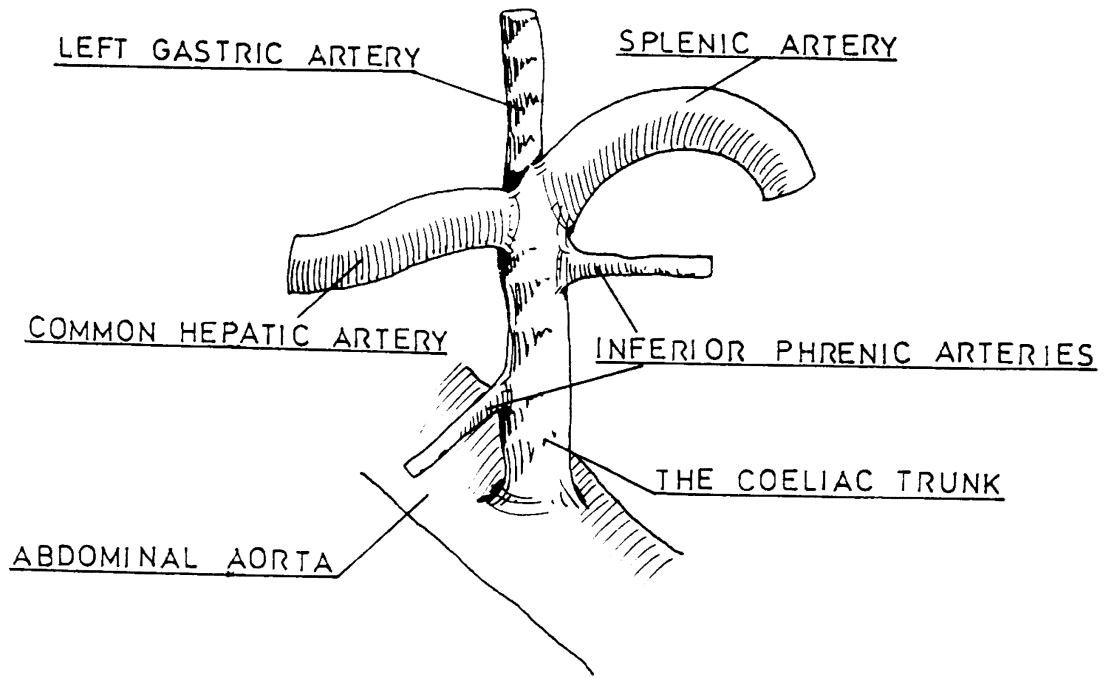


Fig. 2-3. The coeliac trunk in our cadaver showing variation in origin and branches.