

Pipeline for Uncoilable or Failed Aneurysms: Results from a Multicenter Clinical Trial¹

Tibor Becske, MD
 David F. Kallmes, MD
 Isil Saatci, MD
 Cameron G. McDougall, MD
 István Szikora, MD, PhD
 Giuseppe Lanzino, MD
 Christopher J. Moran, MD
 Henry H. Woo, MD
 Demetrius K. Lopes, MD
 Aaron L. Berez, MD
 Daniel J. Cher, MD
 Adnan H. Siddiqui, MD, PhD
 Elad I. Levy, MD
 Felipe C. Albuquerque, MD
 David J. Fiorella, MD, PhD
 Zsolt Berentei, MD
 Miklós Marósfői, MD
 Saruhan H. Cekirge, MD
 Peter K. Nelson, MD

¹From the Neurointerventional Service, Departments of Radiology and Neurology, New York University Medical Center, 560 First Ave, Room HE 208, New York, NY 10016 (T.B., P.K.N.); Department of Neurosurgery, Mayo Clinic, Rochester, Minn (D.F.K., G.L.); Department of Radiology, Hacettepe University Hospitals, Ankara, Turkey (I. Saatci, S.H.C.); Division of Neurologic Surgery, Barrow Neurologic Institute, Phoenix, Ariz (C.G.M., F.C.A.); National Institute of Neurosciences, Budapest, Hungary (I. Szikora, Z.B., M.M.); Division of Interventional Neuroradiology, Mallinckrodt Institute of Radiology, Washington University School of Medicine, St Louis, Mo (C.J.M.); Department of Neurologic Surgery, Stony Brook University, Stony Brook, NY (H.H.W., D.J.F.); Department of Neurologic Surgery, Rush University, Chicago, Ill (D.K.L.); Covidien, Menlo Park, Calif (A.L.B., D.J.C.); and Department of Neurosurgery, University at Buffalo, Buffalo, NY (A.H.S., E.I.L.). Received February 17, 2012; revision requested June 11; revision received October 2; accepted October 11; final version accepted December 6. Supported by ev3/Covidien, Irvine, Calif.

Address correspondence to T.B. (e-mail: Tibor.Becske@nyumc.org).

© RSNA, 2013

Purpose:

To evaluate the safety and effectiveness of the Pipeline Embolization Device (PED; ev3/Covidien, Irvine, Calif) in the treatment of complex intracranial aneurysms.

Materials and Methods:

The Pipeline for Uncoilable or Failed Aneurysms is a multicenter, prospective, interventional, single-arm trial of PED for the treatment of uncoilable or failed aneurysms of the internal carotid artery. Institutional review board approval of the HIPAA-compliant study protocol was obtained from each center. After providing informed consent, 108 patients with recently unruptured large and giant wide-necked aneurysms were enrolled in the study. The primary effectiveness endpoint was angiographic evaluation that demonstrated complete aneurysm occlusion and absence of major stenosis at 180 days. The primary safety endpoint was occurrence of major ipsilateral stroke or neurologic death at 180 days.

Results:

PED placement was technically successful in 107 of 108 patients (99.1%). Mean aneurysm size was 18.2 mm; 22 aneurysms (20.4%) were giant (>25 mm). Of the 106 aneurysms, 78 met the study's primary effectiveness endpoint (73.6%; 95% posterior probability interval: 64.4%–81.0%). Six of the 107 patients in the safety cohort experienced a major ipsilateral stroke or neurologic death (5.6%; 95% posterior probability interval: 2.6%–11.7%).

Conclusion:

PED offers a reasonably safe and effective treatment of large or giant intracranial internal carotid artery aneurysms, demonstrated by high rates of complete aneurysm occlusion and low rates of adverse neurologic events; even in aneurysms failing previous alternative treatments.

© RSNA, 2013

Large and giant wide-necked aneurysms are a challenge to treat. If left untreated, lesions that involve the intradural anterior cerebral circulation (internal carotid artery distribution) are associated with a 5-year cumulative risk of rupture of 14.5%–40%, depending on location (1,2). Traditional endovascular methods of treatment for these aneurysms have included either a reconstructive approach, where the aneurysm sac is filled with an embolic material (usually detachable platinum coils), or parent artery occlusion. However, neither of these approaches addresses the underlying pathology of the aneurysmal parent artery segment (3–6).

Treatment of large and giant wide-neck aneurysms with coils is associated with low rates (~35%) of initial angiographic occlusion (7) and high rates (>50%) of recurrence (3,5–10). Even with the use of advanced coiling techniques (including adjunctive balloons, stents, and complex-shaped and biologically enhanced coils), improved outcomes remain elusive (11–14). It is conceivable that the failure to achieve definitive, complete, and durable exclusion of such

aneurysms may leave patients vulnerable to aneurysm growth or rupture.

Recently, an alternative endoluminal approach to aneurysm treatment has emerged. This novel approach uses flexible low-porosity endoluminal sleeves that enable direct reconstruction of the affected parent artery (15,16). These devices have been designed to reduce hemodynamic exchange between the aneurysm and parent artery (17–19), which promotes thrombosis within the aneurysm sac, and to provide scaffolding for neointimal overgrowth of the aneurysm neck (20,21). The incorporation of the endoluminal device into the vessel wall creates a more anatomically definitive and durable treatment of the aneurysm (15,16).

Herein we present results of the Pipeline for Uncoilable or Failed Aneurysms (PUFS) study, a multicenter, prospective, single-arm clinical trial of the Pipeline Embolization Device (PED; ev3/Covidien, Irvine, Calif), for the treatment of large and giant wide-necked aneurysms of the internal carotid artery. The purpose of this study was to evaluate the safety and effectiveness of the PED in the treatment of complex intracranial aneurysms. The primary effectiveness endpoint was angiographic evaluation that demonstrated complete

aneurysm occlusion and absence of major stenosis at 180 days. The primary safety endpoint was the occurrence of major ipsilateral stroke or neurologic death at 180 days.

Materials and Methods

Industry Support

Our trial was supported by Chestnut Medical and ev3 (Covidien). The funding source provided financial support to the participating sites based on patient enrollment in the trial. Additional support from the funding source included frequent monitor visits to verify source data and ensure compliance with protocol. Both the funding source and the two largest enrolling U.S. clinical sites were inspected and audited by the U.S. Food and Drug Administration. Two of the authors (D.J.C. and A.B.) were employees of the sponsor at the time of the trial; however, they are no longer employees of the sponsor. With the exception of one author (P.K.N.), who was a shareholder in and advisor to the initial sponsor (Chestnut Medical), the investigators had no financial conflict of interest during enrollment. After completion of enrollment, nine authors (T.B., C.J.M., D.F.K., D.J.F., D.K.L., Isil S., István S., S.H.C., and E.I.L.) became clinical proctors and/or consultants for ev3 (Covidien), either

Advances in Knowledge

- The treatment of large and giant cerebral aneurysms with low porosity endoluminal sleeves is feasible and effective, with a reasonable margin of safety.
- Branch vessels, such as the ophthalmic artery, can be covered by the device with a reasonable margin of safety.
- Low porosity self-expanding endoluminal sleeves can be used in the treatment of intracranial aneurysms with a low rate of in-construct stenosis.
- Braided implants can conform well to tortuous vascular anatomy.
- Endoluminal reconstruction of the parent artery is achievable, and leads to occlusion of the aneurysm and anatomic resolution of mass effect.

Implications for Patient Care

- The Pipeline Embolization Device (PED) may offer clinicians the option to treat complex internal carotid artery aneurysms without resorting to parent vessel occlusion.
- Aneurysm occlusion with PED appears to be maintained over time with low rates of recurrence and may decrease the need for continuous radiographic surveillance, potentially resulting in less radiation exposure and cost savings.
- PED has the potential to offer faster, more effective, and lower cost treatment of large and giant aneurysms compared with coil-based treatment.

Published online before print

10.1148/radiol.13120099 Content codes: **HN** **NR**

Radiology 2013; 267:858–868

Abbreviations:

mRS = modified Rankin Scale
 PED = Pipeline Embolization Device
 PUFS = Pipeline for Uncoilable or Failed Aneurysms

Author contributions:

Guarantor of integrity of entire study, T.B.; study concepts/study design or data acquisition or data analysis/interpretation, all authors; manuscript drafting or manuscript revision for important intellectual content, all authors; approval of final version of submitted manuscript, all authors; literature research, T.B., H.H.W., D.K.L., A.L.B., P.K.M.; clinical studies, T.B., D.F.K., I. Saatci, I. Szikora, C.J.M., H.H.W., D.K.L., A.L.B., F.C.A., D.J.F., Z.B., M.M., S.C., P.K.M.; experimental studies, T.B., H.H.W., D.K.L., A.L.B., Z.B.; statistical analysis, T.B., D.K.L.; and manuscript editing, T.B., D.F.K., I. Saatci, G.L., C.J.M., H.H.W., D.K.L., A.L.B., F.C.A., D.J.F., S.C., P.K.M.

Conflicts of interest are listed at the end of this article.

directly or indirectly through their respective institutions. Those authors who were not employees of or consultants for Chestnut Medical, ev3, or Covidien had control over inclusion of data and information that might present a conflict of interest for those authors who are employees or consultants.

Study Enrollment and Patient Selection

Between November 2008 and July 2009, 108 patients from 10 centers were prospectively enrolled. The study was conducted according to U.S. Food and Drug Administration regulations regarding investigational device exemption. Written informed consent was obtained from all patients after the nature of the research was explained. The institutional review board or ethics committee of each institution approved the protocol and the informed consent form. Patient inclusion criteria was the presence of an aneurysm arising from the internal carotid artery (petrous through the superior hypophyseal segments) that measured at least 10 mm in maximum diameter and had a neck of at least 4 mm. Aneurysm dimensions were typically measured by using three-dimensional reformatted images that were derived from rotational catheter angiograms acquired at the time of device placement; in aneurysms with partial thrombosis, maximum dimension was estimated from cross-sectional imaging. Patients were excluded if they had subarachnoid hemorrhage within the previous 60 days, any intracranial hemorrhage or major surgery within the last 42 days, a history of bleeding disorder or low platelet count, previously placed stent at the target aneurysm, contraindication to computed tomographic and magnetic resonance (MR) imaging, known allergy to platinum or cobalt and chromium alloys, evidence of active infection, or major stenosis of the ipsilateral carotid artery. No patient who met inclusion criteria was turned away at any of the participating centers unless the predetermined exclusion criteria were simultaneously violated. Furthermore, during the study, there were no parallel (nonenrolling) compassionate use pathways available to patients who were qualified. Patients with recurrent

or incompletely occluded aneurysms after surgical or coil-endovascular therapy were not excluded unless they had an indwelling stent previously placed across the neck of the target aneurysm.

Baseline Assessments

Prior to placement of the PED, patients underwent a baseline neurologic examination and a detailed neuro-ophthalmologic assessment to document the presence of oculomotor cranial neuropathy or deficits in visual acuity and visual fields.

Dual Antiplatelet Therapy

Patients were asked to take aspirin (325 mg per day orally for 2 days) and clopidogrel (75 mg per day for 7 days) prior to PED placement. Alternatively, a 600-mg loading dose of clopidogrel 1 day prior to the procedure was allowed. After the procedure, patients were asked to take 325 mg of aspirin daily for at least 6 months, and 75 mg of clopidogrel daily for at least 3 months (most were maintained on combination antiplatelet therapy for 6 months).

Description of Study Device and Placement Procedure

PED has been previously described (22). All procedures were performed under general anesthesia by using standard transfemoral approaches. Intravenous heparin was typically administered at 50–100 U/kg to achieve an activated clotting time of greater than 250 seconds. A standard microcatheter with a 0.027-inch internal diameter (Hi-Flo Renegade; Boston Scientific, Fremont, CA; or Marksman Catheter; ev3/Covidien) was used. Additional PEDs were deployed, as needed, through the same delivery microcatheter to increase either the length of the construct or the mesh density. The decision to implant multiple stents was made for a variety of reasons, mostly having to do with creation of a stable endoluminal construct. Multiple partially overlapping stents (up to 15 in one patient) were sometimes required to bridge many of the complex aneurysms that were treated.

There was no roll-in period, but early cases at each site were proctored by experienced operators (P.K.N., A.B.). All

operators underwent hands-on training in an *in vitro* model prior to their first human use of the device to familiarize them with the properties and behavior of the device. The delivery microcatheters and introductory handling of the device share common features with precedent devices familiar to the operators.

Follow-up Assessments

Patients underwent repeat neurologic examinations at 30 and 180 days after PED placement and had a follow-up telephone call at 90 days. Further periodic follow-ups are scheduled through year 5. In addition, patients underwent conventional angiography and a focused neuro-ophthalmologic examination at 180 days. Angiographic images in standard and working views that corresponded to the treatment angiograms were interpreted by an independent core radiology laboratory. Each core radiology laboratory member (S.W., E.K., S.M.) independently adjudicated aneurysms for degree of occlusion according to the scale of Roy (7) (complete occlusion, residual neck, or residual aneurysm), the presence and degree of stenosis according to the method of Samuels, et al (23), and the occurrence of implant migration.

Safety Reporting

Investigators were asked to report as adverse events all negative changes in health. Investigators were also asked to judge the relationship of the event to both the PED and the PED placement procedure. In addition, all serious adverse events were reviewed and adjudicated by an independent clinical events committee (B.F.F., A.S.T., V.R.D.).

Study Endpoints

The primary effectiveness endpoint of our study was complete occlusion (yes or no) of the target aneurysm without major (>50%) stenosis of the parent artery or adjunctive use of a complementary embolic agent as seen on the 180-day angiogram and judged by an independent core laboratory of three interventional neuroradiologists. A case was considered successful if it was deemed to meet these criteria by at least two of the three core laboratory members. The primary safety

Table 1

Baseline Characteristics (n = 108)	
Characteristic	Value
Mean age (y)*	57.0 (11.3, 30.2–75.1)
Female sex	96 (88.9)
Race	
White	99 (91.7)
Black	6 (5.6)
Not reported	3 (2.8)
Medical history	
Remote subarachnoid hemorrhage	8 (7.4)
Stroke	7 (6.5)
Hypertension	60 (55.6)
History of smoking	
Never a smoker	46 (42.6)
Current smoker	31 (28.7)
Previous smoker	31 (28.7)
Prior treatments for target aneurysm	
Coil embolization	6 (5.6)
Surgery	1 (0.9)
Other	1 (0.9)
mRS score	
0	60 (55.6)
1	34 (31.5)
2	9 (8.3)
3	2 (1.9)
4	1 (0.9)
Not performed	2 (1.9)
Cranial neuropathy	
CN 2	20 (18.5)
CN 3	20 (18.5)
CN 4	3 (2.8)
CN 5	7 (6.5)
CN 6	21 (19.4)

Table 1 (continues)

endpoint was the incidence of major ipsilateral stroke (increase of four or more points according to the National Institute of Health Stroke Scale Score), which was adjudicated by the clinical events committee, or neurologic death within 180 days after PED placement. Prespecified subgroup analyses for both the primary effectiveness and safety endpoints included the following four subgroups: aneurysm maximum dimension of 25 mm or larger versus less than 25 mm; neck size 6 mm or larger versus less than 6 mm; aneurysm partially thrombosed at baseline or not; and current or former smoker versus a patient who never smoked. The

Table 1 (continued)

Baseline Characteristics (n = 108)	
Characteristic	Value
Location	
Petrous	4 (3.7)
Cavernous	44 (40.7)
Carotid cave	2 (1.9)
Superior hypophyseal	10 (9.3)
Lateral clinoidal	2 (1.9)
Paraophthalmic	35 (32.4)
Supraclinoid	10 (9.2)
Posterior communicating	1 (0.9)
Mean maximum fundus diameter (mm)*	18.2 (6.4, 6.2 [†] –36.1)
Small: <10 mm	1 [†] (0.9)
Large: 10 to <25 mm	85 (78.7)
Giant: ≥ 25 mm	22 (20.4)
Mean neck size (mm)*	8.8 (4.3, 4.1–36.1)
No. with neck measurement ≥ 6 mm	85 (78.7)
No. with neck measurement < 6 mm	22 (20.4)
Mean dome size (mm)*	14.6 (5.5, 4.4–29.5)
No. of target aneurysms partially thrombosed	17 (15.7)

Note.—Numbers in parentheses are percentages unless otherwise noted.
 *Numbers in parentheses are standard deviation and range.
 †Patient with 6.2-mm aneurysm excluded from effectiveness cohort.

major secondary endpoints of our study included complete occlusion of the target aneurysm at 1, 3, and 5 years, and change in modified Rankin Scale (mRS) score of more than 2 points at 180 days.

Statistical Analysis

Effectiveness analysis focused on the rate of complete occlusion of the target aneurysm, and the goal was to show that the rate statistically exceeded 50%. Safety analysis focused on the rate of major ipsilateral stroke or neurologic death, and the goal was to show that the rate was statistically lower than 20%. The posterior Bayesian distribution of the rate of complete target aneurysm occlusion was calculated by using a noninformative beta prior (1, 1) distribution. The posterior probability that the effectiveness rate exceeded the study's predetermined

effectiveness success threshold of 50% was calculated. The 50% threshold was an upper limit of effectiveness success based on a comprehensive prestudy literature review that summarized the rate of complete intracranial aneurysm occlusion in cohorts of 10 or more patients undergoing coil embolization for large or giant intracranial aneurysms. Our study's primary endpoint safety rate was analyzed similarly, including a calculation of the probability that the safety rate was at most 20%. The 20% threshold was based on the same review of literature regarding major neurologic complications and death that occurred after both coil embolization and surgical treatments of patients with large and giant intracranial aneurysms. The effectiveness cohort was composed of patients with qualifying aneurysms in which the physician was able to pass an access microcatheter into the distal parent artery. The safety cohort was all patients in which PEDs were deployed. Our study was considered an overall success if the posterior probabilities for both primary endpoints were greater than 0.975. Both Bayesian and standard frequentist approaches were used. Analyses were performed by using statistical analysis software (R Project for Statistical Computing, www.r-project.org; and SAS version 9.0, SAS Institute, Cary, NC).

Results

Patient and Aneurysm Characteristics

Of the 108 enrolled patients, 96 (88.9%) were women, and their mean age was 57 years (Table 1). Hypertension was present in 60 of 108 patients (55.6%), and 62 patients (57.4%) were current or former smokers. Mean aneurysm size was 18.2 mm; 22 of 108 aneurysms (20.4%) were larger than 25 mm in maximum dimension. Most aneurysms involved the cavernous or paraophthalmic segments of the internal carotid artery. Eight patients underwent prior failed treatment of their index aneurysm, primarily coil embolization.

Patient Disposition

Patient disposition in the PUFs trial is depicted in Figure 1. Of 108 patients

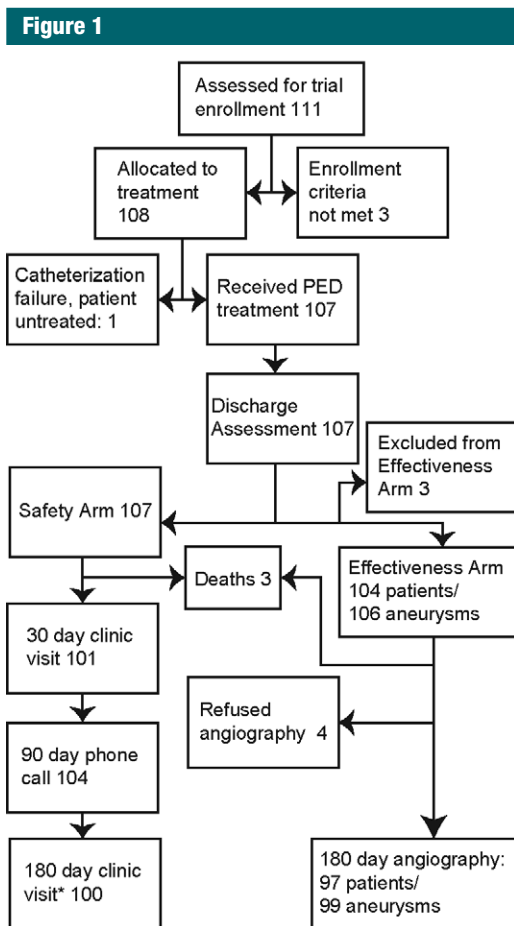


Figure 1: Patient disposition in the PUFs trial. * = Four patients who did not return for 180-day follow-up remained in telephone contact with an investigator.

assigned to treatment, 107 patients underwent PED treatment and completed discharge evaluation. PED placement was not attempted in one patient because the parent artery could not be catheterized. Three patients died on postoperative days 4, 11, and 14. Of the 104 patients who were alive at 180 days after successful PED placement, complete scheduled clinical follow-up was performed in 100 patients (96.2%), and 180-day catheter angiography was performed in 97 patients (93.3%) with 99 treated aneurysms.

Device Placement

PED was successfully placed in 99.1% (107 of 108) of the patients. Of the treated patients, 98.1% (105 of 107) received more than one PED, with a median

average of three PEDs (range, one to 15) per target aneurysm. Two patients underwent PED treatment of both the target aneurysm and a qualifying contralateral aneurysm. Procedure time averaged 124 minutes, and fluoroscopy time averaged 48 minutes. Adjunctive balloon angioplasties were used in 18 patients. In the vast majority of cases, the goal was to dilate compressed perianeurysmal segments of the parent artery prior to device delivery, particularly where the constrained native vessel diameter may have complicated deployment. In other cases, a balloon was used to facilitate microcatheterization of the parent vessel distal to the aneurysm. There were a few instances where a balloon was used to secondarily dilate a suboptimally expanded device, typically under

Table 2

Primary Effectiveness Endpoint Evaluation at Day 180

Met Primary Effectiveness Outcome	Aneurysms (n = 106)
Yes	78 (73.6)
No	28 (26.4)
Reason for effectiveness failure	
Residual neck	8 (7.5)
Residual aneurysm filling	6 (5.7)
Death	3 (2.8)
Carotid occlusion	3 (2.8)
Withdrawn from study	2 (1.8)
Refused angiogram	2 (1.8)
Parent artery stenosis > 50%	2 (1.8)
Adjunctive coils used in aneurysm fundus	1 (0.9)
Carotid-cavernous fistula	1 (0.9)

Note.—Numbers in parentheses are percentages.

circumstances where the device was deployed with excessive traction through excessively tortuous anatomy.

Primary Effectiveness Endpoint

Four of the 108 enrolled patients were excluded from the effectiveness cohort: in two patients, the target aneurysms involved nonqualifying segments of the internal carotid artery (posterior communicating segment and cervical internal carotid artery, respectively). In one patient, the aneurysm size was determined at treatment angiography to be too small (6 mm), and in another patient, the distal parent vessel could not be catheterized and the aneurysm was not treated. Two additional qualifying contralateral aneurysms were treated with PED, which made the effectiveness cohort 106 aneurysms in 104 patients. Of the aneurysms, 73.6% (78 of 106) met the study's combined primary effectiveness endpoint of complete occlusion at day 180 without major stenosis or use of adjunctive coils (95% posterior probability interval: 64.4%, 81.0%; *P* < .001 versus fixed rate of 50%). The posterior probability that the primary effectiveness endpoint exceeded the predetermined success threshold of 50% was 0.999999 (Table 2). The reasons that patients did

Figure 2

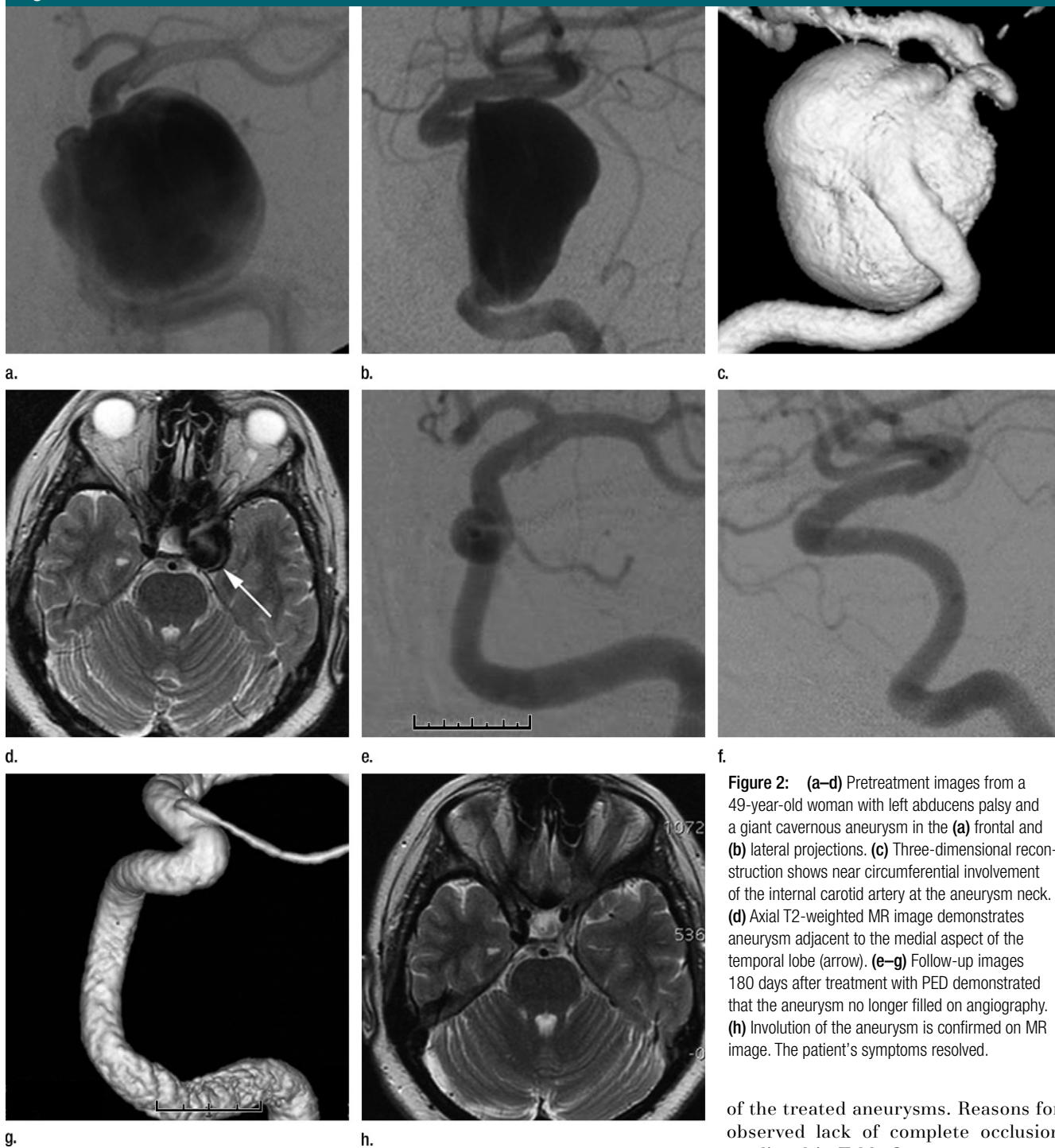


Figure 2: (a–d) Pretreatment images from a 49-year-old woman with left abducens palsy and a giant cavernous aneurysm in the (a) frontal and (b) lateral projections. (c) Three-dimensional reconstruction shows near circumferential involvement of the internal carotid artery at the aneurysm neck. (d) Axial T2-weighted MR image demonstrates aneurysm adjacent to the medial aspect of the temporal lobe (arrow). (e–g) Follow-up images 180 days after treatment with PED demonstrated that the aneurysm no longer filled on angiography. (h) Involution of the aneurysm is confirmed on MR image. The patient’s symptoms resolved.

not meet the primary effectiveness endpoint at day 180 are given in Table 2. An example of complete aneurysm occlusion is shown in Figure 2.

At the 1-year follow-up, 89 patients with 91 treated aneurysms had catheter angiography. Complete occlusion was seen in 79 of 91 (86.8%)

of the treated aneurysms. Reasons for observed lack of complete occlusion are listed in Table 3.

Primary Safety Endpoint

Six of the 107 patients (5.6%) in the safety cohort (95% posterior probability interval: 2.6%, 11.7%; $P < .001$

Table 3

Aneurysm Occlusion Rates at 1-year Angiographic Follow-up

Occlusion Type*	Rate (%)†
Complete occlusion	86.8 (79 of 91)
Residual neck	5.5 (5 of 91)
Residual aneurysm	5.5 (5 of 91)
Carotid occlusion not seen at 180 days	2.2 (2 of 91)

* Data are for 91 aneurysms in 89 patients.

† Numbers in parentheses were used to calculate the occlusion rate.

Table 5

Serious Adverse Events in PUFs

Event Type	No. of Patients
Amaurosis fugax	5 (4.7)
Headache	5 (4.7)
Intracranial hemorrhage	5 (4.7)
Nonneurologic bleeding	5 (4)
Ischemic stroke	4 (3.7)
Cardiac arrhythmia	3 (2.8)
Dizziness or tinnitus	2 (1.9)
Carotid cavernous fistula	2 (1.9)
Carotid occlusion; patient also counted as ischemic stroke	1 (0.9)
Cilioretinal artery embolism	1 (0.9)
Diplopia	1 (0.9)
Possible intracranial hemorrhage	1 (0.9)
Colitis	1 (0.9)
Deep venous thrombosis	1 (0.9)
Lightheadedness or palpitations	1 (0.9)
Lung cancer	1 (0.9)
Pulmonary embolism	1 (0.9)
Rectovaginal fistula	1 (0.9)
Recurrent breast cancer	1 (0.9)
Pneumonia or urinary tract infection	1 (0.9)
Visual field worsened	1 (0.9)
Total no. of patients	44

Note.—Numbers in parentheses are percentages.

versus fixed rate of 20%) were judged by the clinical events committee to have had major ipsilateral stroke or neurologic death (Table 4), which was the study's primary safety endpoint. The posterior probability that the major safety endpoint rate was less than

Table 4

Primary Safety Endpoint Data by Day 180

Patient No.	Event Description	Results (%)
1	Ischemic stroke (perioperative) related to PED-associated thrombosis (patient later experienced delayed fatal hemorrhage after traumatic fall in rehabilitation facility)	2.8 (3 of 107)*
2	Ischemic stroke (delayed) secondary to major in-construct (PED) stenosis	...
3	Ischemic stroke (delayed) from noncompliance with the required oral antiplatelet regimen	...
4	Ipsilateral intraparenchymal hemorrhage (perioperative)	1.9 (2 of 107)†
5	Ipsilateral intraparenchymal hemorrhage (delayed) on day 14 (fatal)	...
6	Rapidly fatal event possibly neurologic in origin	0.9 (1 of 107)

Note.—Data relates to the 5.6% (six of 107) of patients who had major ipsilateral stroke or neurologic death by day 180.

Numbers in parentheses were used to calculate percentages.

* Results data apply to patients 1, 2, and 3.

† Results data apply to patients 4 and 5.

20% (the predetermined safety success threshold) was 0.999979.

Other Safety Outcomes

All adverse events that occurred before 180 days were adjudicated according to the International Organization for Standardization definition of a serious adverse event. Thirty-eight additional non-qualifying serious adverse events were encountered. The causes of these events, together with those of the six qualifying events captured by the primary safety endpoints, are listed in Table 5. Twenty-one of these events were judged as being definitely (six events) or probably (15 events) device related. Further details on the five intracranial hemorrhages are provided in Table 6.

At 180 days, mRS scores were available in 101 patients. The mRS scores were improved at 180 days in 21 of 107 patients (19.6%), unchanged in 70 patients (65.4%), worse in 10 patients (9.3%), and not available (due to incomplete study participation) in 6 patients (5.6%). Ninety-four of 107 patients (87.9%) had a mRS score of 1 or less at 180 days. Causes for worsened mRS scores were death (three patients), chronic headache (two patients), residual symptoms from stroke (two patients), diplopia (one patient), ptosis (one patient) and tinnitus (one patient).

Subgroup Analysis

Subgroup analysis of the primary effectiveness and safety endpoints showed that no preplanned subgroup had a statistically increased rate of either effectiveness or safety.

Discussion

Our PUFs trial demonstrated a high complete occlusion rate of large or giant wide-necked internal carotid artery aneurysms that were recently unruptured and treated with PED. The safety profile is encouraging, especially given the challenging nature of the enrolled aneurysms and the outcomes typically associated with this population. Taken together, the data indicated that PED is safe and effective for the target population of large and giant wide-necked internal carotid artery aneurysms.

The gender bias was evident in our study and may have been enhanced by selection of aneurysms that involved proximal internal carotid artery locations as the target population, many of which were cavernous or paraophthalmic sites known to have pronounced gender asymmetry (24). However, while there was no deliberate gender discrimination during patient selection, a component of referral bias from the

Table 6

Description of Patients with Intracranial Hemorrhage

Patient No.	Description	Associated Risk Factors	Clinical Outcome
1	Intracranial hemorrhage after head trauma	Postoperative thrombotic stroke, witnessed fall in rehabilitation facility; patient no. 1 in Table 4	Death
2	Intracranial hemorrhage, postprocedure	Occurred after administration of IIb/IIIa inhibitor	Major hemorrhagic stroke (change > 4 in NIHSS Score) with full recovery by 30 days
3	Intracranial hemorrhage on postoperative day 14	History of alcohol use, hypertension, and head trauma; patient no. 5 in Table 4	Death
4	Intracranial hemorrhage on postoperative day 3	Factor V Leiden, on warfarin sodium with elevated prothrombin time at time of bleeding event	Minor hemorrhagic stroke (change < 4 in NIHSS score)
5	Intracranial hemorrhage on postoperative day 6	Postoperative diffusion-weighted MR imaging showed small areas of restricted diffusion at site of hemorrhage	Minor hemorrhagic stroke (change < 4 in NIHSS score); returned to normal neurologic function by day 10

Note.—NIHSS = National Institute of Health Stroke Scale.

referring community of physicians cannot be ruled out.

Previous studies (16,22,25–27) have evaluated the use of flow diversion devices in intracranial aneurysms. These prior reports, as in this series, targeted sidewall aneurysms of the internal carotid artery, but had fewer patients (30–60 patients), and included smaller aneurysms than those in our study. PUFs provided additional value to existing literature because of the prospective study design, high rate of patient follow-up, independent monitoring and source verification of all case report form data fields, and independent adjudication of both safety and effectiveness outcomes.

The safety and efficacy observed in PUFs compare favorably with those of prior studies that used reconstructive coil-endosaccular treatment (28–33). Adverse events in our study are as low as or lower than most studies (28) that focused on endosaccular treatment of large and giant internal carotid artery aneurysms. Moreover, rates of complete aneurysm obliteration at follow-up are substantially higher with the PED than those that were observed after coiling, with or without the adjunctive use of higher porosity stents (13). Compared with deconstructive therapies, treatment with the PED may offer a similar safety profile with the advantage of parent artery preservation, particularly for those

patients lacking adequate collateral support who would require a surgical bypass prior to parent vessel sacrifice.

A series of 13 patients (34) who underwent delayed rupture of aneurysms treated with flow diversion devices raised questions as to the point in time after treatment and degree to which aneurysms treated in this fashion were protected against rupture. While no patient treated with PED in PUFs experienced aneurysm rupture that resulted in subarachnoid hemorrhage to date, one patient developed a subacute carotid cavernous fistula after PED treatment of a cavernous segment aneurysm—an untoward outcome also infrequently known to complicate stent-assisted coil treatment of cavernous segment aneurysms (35). Rupture of previously unruptured intradural aneurysms has also been described (31,36,37) after treatment with parent vessel occlusion and coil placement, however, as with endoluminal devices such as PED, the causative mechanism of this adverse occurrence remains obscure.

Intraparenchymal hemorrhage distant from the aneurysm has been noted previously after treatment with flow diversion devices (38) and stent-assisted coil treatments that use other (higher porosity) intracranial stents (29). In our series, this type of hemorrhage was seen in five patients. We believe that the most likely cause for ipsilateral

hemispheric intracranial hemorrhage is intraprocedural embolization of some type of material—thrombus, air bubbles, catheter coating that results in microvascular damage, transient occlusion with microinfarction, or hemorrhagic reperfusion. An alternative possibility of post-flow-diversion hyperperfusion or enhanced pressure transmission phenomenon has been proposed; however, to the authors' knowledge, none of these hypotheses have been validated.

Finally, late stenothrombotic occlusion that is device associated has been noted in other series with stent-assisted coil placement, sometimes related to noncompliance or resistance to antiplatelet therapy (39) or by developing as a consequence of severe in-stent stenosis. Five delayed parent vessel occlusions were observed in our series through 1-year follow-up, and one delayed parent vessel occlusion was definitively related to noncompliance with antiplatelet medication. The degree of antiplatelet effectiveness was not routinely evaluated during this study, but, such monitoring could be useful to reduce this complication.

Overall, the data from our study provided evidence that supported endoluminal-focused treatment of large and giant aneurysms with PED. However, our study had some limitations.

One limitation was that PUFs did not include a concurrent control group, and, thus, direct comparisons with other

aneurysm therapies were not possible. The lack of a clearly acceptable endovascular or neurosurgical alternative that is likely to provide safe, definitive, vessel-sparing treatment for aneurysms targeted in PUFs made randomization impractical. By considering the morphologic features of the targeted aneurysms, randomization against aneurysm coils would likely have required an unacceptable degree of crossover from the control arm, which would have exposed patients to additional risk when securing final treatment of their aneurysms. Medical management of these complex cases remains heterogeneous and unoptimized, so it was not examined in our study.

Another limitation was that the aneurysms treated in PUFs represented a limited anatomic distribution. Therefore, the safety and effectiveness outcomes may not be generalizable to all cerebral aneurysms. Specifically, the risk of perforator injury was not explicitly addressed by our study. Moreover, the low numbers of intradural aneurysms (64 intradural aneurysms) make it difficult to assess the true frequency of posttreatment delayed aneurysmal subarachnoid hemorrhage.

A final limitation was that the number of devices used to treat each aneurysm was not standardized, and it incorporated a variety of strategies that made it difficult to draw any conclusions regarding the number of PEDs necessary to effectively treat PUFs-like aneurysms. The per-aneurysm device use in our trial was higher than previously reported in other PED experiences. This was likely due to the unique complexity of aneurysms in the study population, which included only lesions that were both large or giant and wide-necked. Additionally, our study sought to determine the effectiveness of PED as a stand-alone device (by penalizing adjunctive use of coils) and may have biased practice in our trial toward the use of multiple PEDs to achieve higher degrees of aneurysm coverage.

In summary, PUFs demonstrated a high rate (78 of 108, 73.6%) of complete occlusion of large and giant wide-necked aneurysms of the internal carotid artery and a reasonably low

rate of major safety events (six of 107, 5.6% rate of major stroke or neurologic death). Continued study of PED to refine therapy and further understand certain complications that occur infrequently is warranted.

Acknowledgment: The authors acknowledge the critically important contributions of members of the Clinical Events Committee: Brian-Fred Fitzsimmons, MD (Milwaukee, Wis), Aqulla S. Turk, DO (Charleston, SC), and Vivek R. Desmukh, MD (Washington DC); and members of the Core Radiology Laboratory: Stephan Wetzel, MD (Zurich, Switzerland); Eberhard Kirsch, MD (Aarau, Switzerland); and Stephan Meckel, MD (Freiburg, Germany).

Disclosures of Conflicts of Interest: **T.B.** Financial activities related to the present article: received support from ev3/Covidien for travel to meetings to present results of PUFs trial. Financial activities not related to the present article: received proctoring and consulting honoraria from ev3/Covidien for training and proctoring physicians using Pipeline; received per diem compensation from ev3/Covidien for running US Pipeline training courses and for presenting Pipeline experiences in various meetings; received payment for development of educational presentations from ev3/Covidien for preparing US Pipeline training course. Other relationships: none to disclose. **D.F.K.** Financial activities related to the present article: institution received grant from Chestnut Medical and ev3/Covidien for funding for clinical trial; institution received support for travel to meetings for the study or other purposes from MicroVention. Financial activities not related to the present article: institution received money for consultancy from Medtronic and ev3/Covidien; institution received money for grants/pending grants from ev3/Covidien, MicroVention, Sequent, Micrus, Benvenue Medical for preclinical studies and clinical trials; received royalties from UVA Patent Foundation; institution received payment for development of educational presentations from ev3/Covidien and CareFusion; institution received travel/accommodations/meeting expenses unrelated to activities listed from MicroVention, ev3/Covidien. Other relationships: none to disclose. **I. Saatici** Financial activities related to the present article: institution received fees for participation in review activities from Chestnut Medical. Financial activities not related to the present article: received money from ev3/Covidien for a consultancy. Other relationships: none to disclose. **C.G.M.** Financial activities related to the present article: none to disclose. Financial activities not related to the present article: received money from Covidien Medical Advisory Board for consultancy. Other relationships: none to disclose. **I. Szikora** Financial activities related to the present article: author and institution received consulting fees or honorarium from Chestnut Medical. Financial activities not related to the present article: received money from Stryker Neurovascular and ev3/Covidien for

consultancy; received payment for lectures including service on speakers bureaus from Stryker Neurovascular and ev3/Covidien. Other relationships: none to disclose. **G.L.** Financial activities related to the present article: institution received consulting fees or honoraria from ev3/Covidien; institution received support for travel to meetings for the study or other purposes from ev3/Covidien for presentation to US Food and Drug Administration panel. Financial activities not related to the present article: institution received an Unrestricted Educational Grant from ev3/Covidien. Other relationships: none to disclose. **C.J.M.** Financial activities related to the present article: institution received grant from ev3/Covidien. Financial activities not related to the present article: received money from ev3/Covidien for a consultancy; received money from ev3/Covidien for lectures; received money from ev3/Covidien for development of educational presentations. Other relationships: none to disclose. **H.H.W.** Financial activities related to the present article: none to disclose. Financial activities not related to the present article: institution received money for grant or grants pending from Siemens; institution received money for grants or grants pending from MicroVention; received royalties paid by Codman and Shurtleff for an acute stroke device secondary to acquisition of Revasc; received travel/accommodations/meeting expenses unrelated to activities listed from Siemens; author is the President/CFO of Vascular Simulations. Other relationships: none to disclose. **D.K.L.** Financial activities related to the present article: none to disclose. Financial activities not related to the present article: author has stock/stock options in Chestnut Medical. Other relationships: none to disclose. **A.L.B.** Financial activities related to the present article: author was an employee of Chestnut Medical and ev3/Covidien. Financial activities not related to the present article: author received money for patents from Covidien; author has stock/stock options in Chestnut Medical and Covidien, and is a founder and employee of Chestnut; received travel/accommodations/meeting expenses unrelated to activities listed from Chestnut Medical and ev3/Covidien. Other relationships: author is the founder and CEO of Chestnut Medical, the company that developed the PED, and is the inventor named on the patents. **D.J.C.** Financial activities related to the present article: none to disclose. Financial activities not related to the present article: author employed by Chestnut Medical; author has stock/stock options in Chestnut Medical. Other relationships: none to disclose. **A.H.S.** Financial activities related to the present article: none to disclose. Financial activities not related to the present article: received money from Codman & Shurtleff for being on advisory board; received money for consultancy from Codman & Shurtleff, Concentric Medical, ev3/Covidien, GuidePoint Global Consulting, and Penumbra; grants/grants pending from National Institutes of Health and University at Buffalo (SUNY); payment for lectures including service on speakers bureaus from Codman & Shurtleff and Genetech; received money for stock/stock

options from Hotspur, Intratech Medical, Stim-Sox, and Valor Medical; institution received money for travel/accommodations/meeting expenses unrelated to activities listed from 44th Neuroendovascular Complication Meeting and Asia Pacific Stroke Conference; received honoraria from Abbott Vascular, American Association of Neurological Surgeons' courses, and Genetech. Other relationships: author has a nonfinancial relationship with Penumbra and sits on the National Steering Committee for 3D Separator Trial. **E.J.L.** Financial activities related to the present article: none to disclose. Financial activities not related to the present article: author is a board member of Codman & Shurtleff; received money from consultancies from Codman & Shurtleff, ev3/Covidien, TheraSyn Sensors; provided expert testimony for Medical Legal Review; grants/grants pending from SARIS, Codman & Shurtleff, ev3/Covidien, Boston Scientific; received honoraria from Boston Scientific; received payment for lectures from Boston Scientific; received money from stock/stock options from Intratech Medical, Mynx; received fees for carotid stent training from Abbott Vascular. Other relationships: none to disclose. **F.C.A.** No conflicts of interest to disclose. **D.J.F.** Financial activities related to the present article: received money from a grant from SAMMPRIS-NIH. Financial activities not related to the present article: received money from consultancies from Codman & Shurtleff, ev3/Covidien, NFocus, Cordis; grants/grants pending from Siemens, MicroVention; stock/stock options from Vascular Simulators. Other relationships: none to disclose. **Z.B.** No conflicts of interest to disclose. **M.M.** No conflicts of interest to disclose. **S.H.C.** Financial activities related to the present article: institution received money for participation in review activities from Chestnut Medical. Financial activities not related to the present article: received money for consultancies from ev3/Covidien, MicroVention. Other relationships: none to disclose. **P.K.N.** Financial activities related to the present article: institution received money for participation in review activities from Chestnut Medical. Financial activities not related to the present article: received money for consultancy from ev3/Covidien; received royalties from Boston Scientific, Stryker; received money for stock/stock options from Chestnut Medical. Other relationships: none to disclose.

References

1. Wiebers DO, Whisnant JP, Huston J 3rd, et al. Unruptured intracranial aneurysms: natural history, clinical outcome, and risks of surgical and endovascular treatment. *Lancet* 2003;362(9378):103–110.
2. Wiebers DO. Unruptured intracranial aneurysms: natural history and clinical management. Update on the international study of unruptured intracranial aneurysms. *Neuroimaging Clin N Am* 2006;16(3):383–390, vii.
3. Campi A, Ramzi N, Molyneux AJ, et al. Retreatment of ruptured cerebral aneurysms in patients randomized by coiling or clipping in the International Subarachnoid Aneurysm Trial (ISAT). *Stroke* 2007;38(5):1538–1544.
4. Molyneux A, Kerr R; International Subarachnoid Aneurysm Trial (ISAT) Collaborative Group, et al. International Subarachnoid Aneurysm Trial (ISAT) of neurosurgical clipping versus endovascular coiling in 2143 patients with ruptured intracranial aneurysms: a randomized trial. *J Stroke Cerebrovasc Dis* 2002;11(6):304–314.
5. Molyneux AJ. Indications for treatment of cerebral aneurysms from an endovascular perspective: the creation of an evidence base for interventional techniques. *Neurosurg Clin N Am* 2005;16(2):313–316, ix.
6. Molyneux AJ, Kerr RS, Birks J, et al. Risk of recurrent subarachnoid haemorrhage, death, or dependence and standardised mortality ratios after clipping or coiling of an intracranial aneurysm in the International Subarachnoid Aneurysm Trial (ISAT): long-term follow-up. *Lancet Neurol* 2009;8(5):427–433.
7. Raymond J, Guilbert F, Weill A, et al. Long-term angiographic recurrences after selective endovascular treatment of aneurysms with detachable coils. *Stroke* 2003;34(6):1398–1403.
8. Blanc R, Weill A, Piotin M, Ross IB, Moret J. Delayed stroke secondary to increasing mass effect after endovascular treatment of a giant aneurysm by parent vessel occlusion. *AJNR Am J Neuroradiol* 2001;22(10):1841–1843.
9. Brisman JL, Song JK, Newell DW. Cerebral aneurysms. *N Engl J Med* 2006;355(9):928–939.
10. Molyneux AJ, Kerr RS, Yu LM, et al. International subarachnoid aneurysm trial (ISAT) of neurosurgical clipping versus endovascular coiling in 2143 patients with ruptured intracranial aneurysms: a randomised comparison of effects on survival, dependency, seizures, rebleeding, subgroups, and aneurysm occlusion. *Lancet* 2005;366(9488):809–817.
11. Geyik S, Ertugrul O, Yavuz K, Geyik P, Saatci I, Cekirge HS. Comparison of bioactive coils and bare platinum coils for treatment of intracranial aneurysms: a matched-pair analysis. *J Neurosurg* 2010;112(4):709–713.
12. Linfante I, DeLeo MJ 3rd, Gounis MJ, Brooks CS, Wakhloo AK. Cerecyte versus platinum coils in the treatment of intracranial aneurysms: packing attenuation and clinical and angiographic mid-term results. *AJNR Am J Neuroradiol* 2009;30(8):1496–1501.
13. Pierot L, Leclerc X, Bonafé A, Bracard S; French Matrix Registry Investigators. Endovascular treatment of intracranial aneurysms with matrix detachable coils: mid-term anatomic follow-up from a prospective multicenter registry. *AJNR Am J Neuroradiol* 2008;29(1):57–61.
14. Shapiro M, Becske T, Sahlein D, Babb J, Nelson PK. Stent-supported aneurysm coiling: a literature survey of treatment and follow-up. *AJNR Am J Neuroradiol* 2012;33(1):159–163.
15. Fiorella D, Kelly ME, Albuquerque FC, Nelson PK. Curative reconstruction of a giant midbasilar trunk aneurysm with the pipeline embolization device. *Neurosurgery* 2009;64(2):212–217; discussion 217.
16. Lylyk P, Miranda C, Ceratto R, et al. Curative endovascular reconstruction of cerebral aneurysms with the pipeline embolization device: the Buenos Aires experience. *Neurosurgery* 2009;64(4):632–642; discussion 642–643; quiz N6.
17. Cantón G, Levy DI, Lasheras JC, Nelson PK. Flow changes caused by the sequential placement of stents across the neck of sidewall cerebral aneurysms. *J Neurosurg* 2005;103(5):891–902.
18. Lieber BB, Stancampiano AP, Wakhloo AK. Alteration of hemodynamics in aneurysm models by stenting: influence of stent porosity. *Ann Biomed Eng* 1997;25(3):460–469.
19. Sadasivan C, Lieber BB, Cesar L, Miskolczi L, Seong J, Wakhloo AK. Angiographic assessment of the performance of flow diverters to treat cerebral aneurysms. *Conf Proc IEEE Eng Med Biol Soc* 2006;1:3210–3213.
20. Nelson PK, Sahlein D, Shapiro M, et al. Recent steps toward a reconstructive endovascular solution for the orphaned, complex-neck aneurysm. *Neurosurgery* 2006;59(5 Suppl 3):S77–S92; discussion S3–S13.
21. Kallmes DF, Ding YH, Dai D, Kadirvel R, Lewis DA, Cloft HJ. A second-generation, endoluminal, flow-disrupting device for treatment of saccular aneurysms. *AJNR Am J Neuroradiol* 2009;30(6):1153–1158.
22. Nelson PK, Lylyk P, Szikora I, Wetzel SG, Wanke I, Fiorella D. The pipeline embolization device for the intracranial treatment of aneurysms trial. *AJNR Am J Neuroradiol* 2011;32(1):34–40.
23. Samuels OB, Joseph GJ, Lynn MJ, Smith HA, Chimowitz MI. A standardized method for measuring intracranial arterial stenosis. *AJNR Am J Neuroradiol* 2000;21(4):643–646.
24. Halbach VV, Higashida RT, Dowd CF, et al. Cavernous internal carotid artery aneurysms

- treated with electrolytically detachable coils. *J Neuroophthalmol* 1997;17(4):231–239.
25. Byrne JV, Beltechi R, Yarnold JA, Birks J, Kamran M. Early experience in the treatment of intra-cranial aneurysms by endovascular flow diversion: a multicentre prospective study. *PLoS ONE* 2010;5(9):e12492.
 26. Lubicz B, Collignon L, Raphaeli G, et al. Flow-diverter stent for the endovascular treatment of intracranial aneurysms: a prospective study in 29 patients with 34 aneurysms. *Stroke* 2010;41(10):2247–2253.
 27. Szikora I, Berentei Z, Kulcsar Z, et al. Treatment of intracranial aneurysms by functional reconstruction of the parent artery: the Budapest experience with the pipeline embolization device. *AJNR Am J Neuroradiol* 2010;31(6):1139–1147.
 28. Darsaut TE, Darsaut NM, Chang SD, et al. Predictors of clinical and angiographic outcome after surgical or endovascular therapy of very large and giant intracranial aneurysms. *Neurosurgery* 2011;68(4):903–915; discussion 915 .
 29. Fiorella D, Albuquerque FC, Woo H, Rasmussen PA, Masaryk TJ, McDougall CG. Neuroform stent assisted aneurysm treatment: evolving treatment strategies, complications and results of long term follow-up. *J Neurointerv Surg* 2010;2(1):16–22.
 30. Heran NS, Song JK, Kupersmith MJ, et al. Large ophthalmic segment aneurysms with anterior optic pathway compression: assessment of anatomical and visual outcomes after endosaccular coil therapy. *J Neurosurg* 2007;106(6):968–975.
 31. Murayama Y, Nien YL, Duckwiler G, et al. Guglielmi detachable coil embolization of cerebral aneurysms: 11 years' experience. *J Neurosurg* 2003;98(5):959–966.
 32. Piotin M, Blanc R, Spelle L, et al. Stent-assisted coiling of intracranial aneurysms: clinical and angiographic results in 216 consecutive aneurysms. *Stroke* 2010;41(1):110–115.
 33. Sluzewski M, Menovsky T, van Rooij WJ, Wijnalda D. Coiling of very large or giant cerebral aneurysms: long-term clinical and serial angiographic results. *AJNR Am J Neuroradiol* 2003;24(2):257–262.
 34. Kulcsár Z, Houdart E, Bonafé A, et al. Intra-aneurysmal thrombosis as a possible cause of delayed aneurysm rupture after flow-diversion treatment. *AJNR Am J Neuroradiol* 2011;32(1):20–25.
 35. Chan HW, Haliasos N, Derakhshani S, Vindlacheruvu R, Chawda S. Delayed carotid-cocavernous fistula after stent-assisted coil embolization of intracavernous carotid aneurysm: should we manage conservatively? *Acta Neurochir (Wien)* 2011;153(6):1291–1295.
 36. Gurian JH, Viñuela F, Gobin YP, Waston VE, Duckwiler GR, Gulielmi G. Aneurysm rupture after parent vessel sacrifice: treatment with Guglielmi detachable coil embolization via retrograde catheterization: case report. *Neurosurgery* 1995;37(6):1216–1220; discussion 1220–1221.
 37. Vincent F, Weill A, Roy D, Raymond J, Guilbert F. Carotid ophthalmic aneurysm rupture after parent vessel occlusion. *AJNR Am J Neuroradiol* 2005;26(6):1372–1374.
 38. Fischer S, Vajda Z, Aguilar Perez M, et al. Pipeline embolization device (PED) for neurovascular reconstruction: initial experience in the treatment of 101 intracranial aneurysms and dissections. *Neuroradiology* 2012;54(4):369–382.
 39. Mocco J, Fargen KM, Albuquerque FC, et al. Delayed thrombosis or stenosis following enterprise-assisted stent-coiling: is it safe? Midterm results of the interstate collaboration of enterprise stent coiling. *Neurosurgery* 2011;69(4):908–913; discussion 913–914.