



## Case Report

## Iliac arteriovenous fistulas after lumbar spinal surgery



Osman Ocal<sup>a,\*</sup>, Bora Peynircioglu<sup>a</sup>, Gonca Eldem<sup>a</sup>, Erhan Akpinar<sup>a</sup>, Mehmet Ruhi Onur<sup>a</sup>, Giray Kabakci<sup>b</sup>

<sup>a</sup> Department of Radiology, Faculty of Medicine, Hacettepe University, Ankara, Turkey

<sup>b</sup> Department of Cardiology, Faculty of Medicine, Hacettepe University, Ankara, Turkey

## ARTICLE INFO

## Article history:

Received 18 December 2016

Received in revised form

15 March 2017

Accepted 17 March 2017

Available online 16 June 2017

## Keywords:

Arteriovenous fistula

Spinal

Surgery

Endovascular

## ABSTRACT

Iatrogenic arteriovenous fistula (AVF) is an unusual and potentially fatal complication of lumbar spinal surgery. The presentation of these injuries is usually late, with symptoms such as leg swelling or cardiac failure. It is crucial to suspect AVF in the patient which presents to emergency with lumbar spinal surgery history. The diagnosis is often based on imaging studies such as computed tomography (CT) or magnetic resonance (MR) angiography. Surgery was the first choice of treatment, but with recent advances in stent technology endovascular approach has become widely popular. We present two cases of AVF secondary to lumbar spinal surgery, one of them presenting with overt heart failure and the other one with leg swelling.

Copyright © 2017 The Emergency Medicine Association of Turkey. Production and hosting by Elsevier B.V. on behalf of the Owner. This is an open access article under the CC BY-NC-ND license (<http://creativecommons.org/licenses/by-nc-nd/4.0/>).

## 1. Introduction

Arteriovenous fistula (AVF) is an abnormal communication between an artery and a vein. It is frequently a consequence of trauma or iatrogenic injury. Iliac AVF can be seen after lumbar spinal surgery. It may present to an emergency department with symptoms of deep venous thrombosis or heart failure. History and physical examination findings can suggest AVF but the diagnosis is often based on imaging studies such as Doppler ultrasonography (US), CT or MR angiography. Although surgery is usually preferred as the first choice of treatment in this disorder endovascular approach has been more commonly used due to recent advances in stent technology. We present two cases of iatrogenic high flow iliac AVF occurred secondary to lumbar spinal surgery and treated with an endovascular stent graft.

## 2. Case presentation 1

A 42-year-old male presented to our clinic with palpitation, abdominal distention and bilateral lower limb swelling especially in the right leg for a month. He was admitted to the hospital with

the diagnosis of heart failure. He had a history of L4-L5 lumbar discectomy four months ago. His medical history did not confirm the presence of ischemic heart disease. Physical examination revealed bilateral marked lower limb edema and prominent right femoral pulse. The patient denied acute or chronic leg pain and no Homan's sign was detected suggesting deep venous thrombosis (DVT). A murmur was heard in the right groin at auscultation. Chest X-ray showed cardiac enlargement and prominent vascular markings in the lung parenchyma. Dilated right atrium and ventricle, patent foramen ovale, increased pulmonary arterial pressure and suspicious right atrial septum abnormality were depicted on echocardiogram. Left ventricular ejection fraction was in normal range.

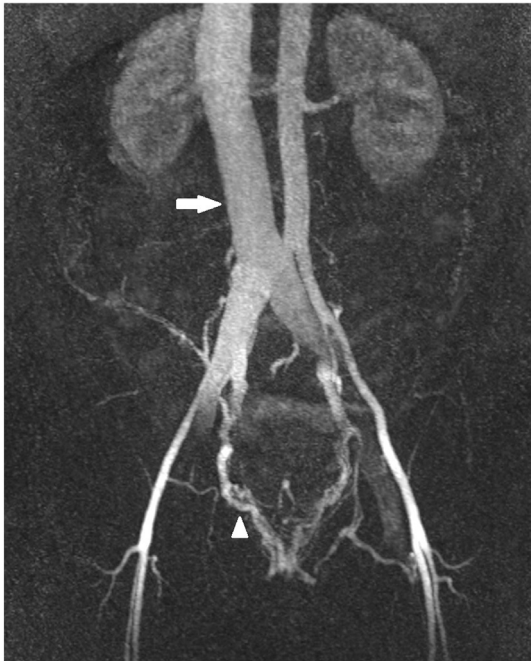
Coronary and abdomen CT was performed to assess suspected right atrial septum abnormality and a reason for abdominal distention, respectively. Abdomen CT revealed early opacified and dilated inferior vena cava (IVC) and right common iliac vein and suspected fistula between right common iliac artery and vein. Ascites, hepatomegaly and dilated hepatic veins were accompanying findings on CT. MR angiography demonstrated fistula between right common iliac artery and vein with dilated pelvic veins secondary to increased venous pressure (Fig. 1).

Abdominal aorta digital subtraction angiography (DSA) showed communication between the right common iliac artery and right common iliac vein, 1.5 cm distal to the aortic bifurcation. After diagnostic angiography, an 11F vascular sheath was placed via the

\* Corresponding author.

E-mail address: [osman.ocal@hacettepe.edu.tr](mailto:osman.ocal@hacettepe.edu.tr) (O. Ocal).

Peer review under responsibility of The Emergency Medicine Association of Turkey.



**Fig. 1.** Maximum intensity projection (MIP) image of contrast enhanced MR Angiography demonstrates early opacification of IVC (arrow), and proximal common iliac veins. Pelvic veins were opacified secondary to increased venous pressure (arrowhead).

right femoral artery. Under roadmap guidance, abdominal aorta was catheterized and a 0,035 inch 260 cm stiff guide wire was placed. A self-expanding Viabahn 13 mm in diameter and 50 mm long stent graft was deployed across the fistula. Control DSA after stent graft deployment confirmed the position of the stent and absence of opacification of the IVC during arterial phase. No post-procedural complications have occurred. Symptoms resolved within few days and liver function tests became normal. The patient remained asymptomatic at 2 years 3 months follow-up.

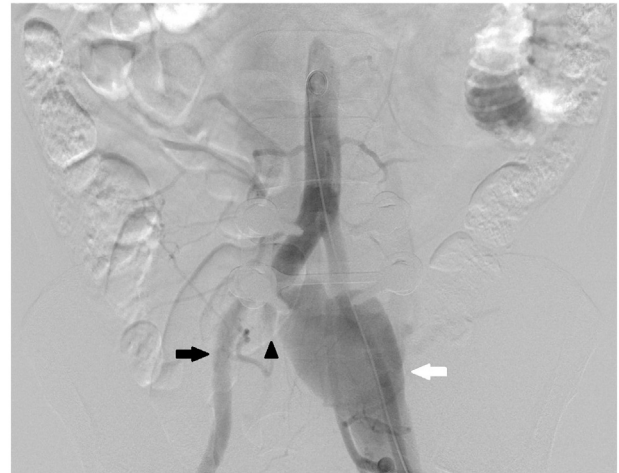### 3. Case presentation 2

A 40-year-old male presented with complaints of varices and progressive swelling in his left leg. He had a history of L4-L5 instrumentation surgery 20 months ago. Physical examination revealed no Homan's sign suggesting DVT.

Doppler US revealed arterialized flow within the bilateral common iliac, femoral and popliteal veins. The diameter of the left common iliac vein was 3 mm where it crosses right common iliac artery and 33 mm distally. Echocardiogram of the patient revealed no abnormality suggesting congestive heart failure.

CT angiography revealed early opacified bilateral common iliac veins and IVC, AVF between the right common iliac artery and the left common iliac vein, compression of left common iliac vein by the right common iliac artery and aneurysmatic dilatation of left common iliac vein, with multiple collaterals.

Abdominopelvic DSA, obtained via left femoral approach, revealed an AVF between right common iliac artery-left common iliac vein at the bifurcation of the iliac artery. The proximal part of the right internal iliac artery was also contributing to the fistula (Fig. 2). The right internal iliac artery was embolized with 8 mm Amplatzer Vascular Plug 4 for prevention of endoleak and retrograde flow to the fistula after stent graft implantation. A self-expanding Endurant II 16-10-93 mm stent graft deployed from common iliac artery to right external iliac artery. Control DSA after



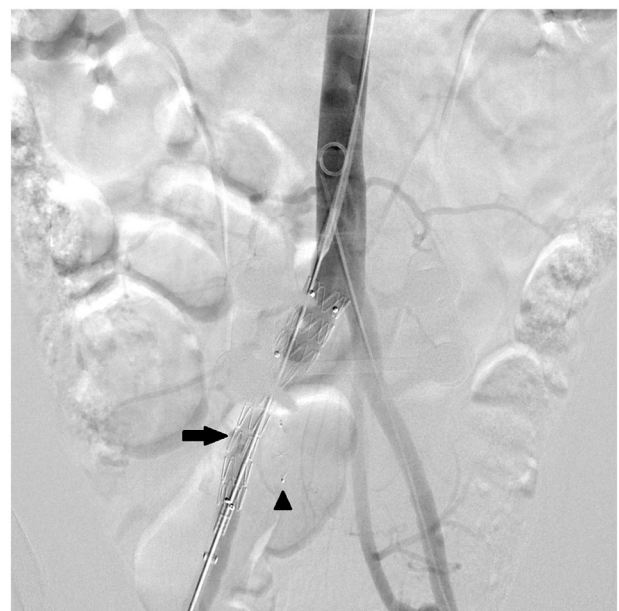
**Fig. 2.** DSA image reveals AVF between right common iliac artery (black arrow) and left common iliac vein (white arrow) at the bifurcation of iliac artery. Proximal right internal iliac artery also contributes to the AVF (arrowhead).

stent graft deployment confirmed the position of the stent with no opacification of the common iliac vein during arterial phase (Fig. 3). No post-procedural complications occurred and the patient was discharged two days after the procedure.

### 4. Discussion

AVFs are characterized by an abnormal communication between an artery and a vein. Acquired ilio-iliac AVFs can be resulted from lumbar disc surgery, penetrating trauma and aortic or iliac artery aneurysms.<sup>1,2</sup> AVFs can also occur secondary to connective tissue disorders such as Marfan syndrome, Ehlers-Danlos syndrome, neoplastic invasion of vascular structures and mycotic or syphilitic aneurysms.<sup>3</sup>

Since it was first described by Linton and White in 1945,<sup>4</sup> AVFs



**Fig. 3.** DSA image reveals Amplatzer vascular plug (arrowhead) in right internal iliac artery and stent graft (arrow) in right common iliac artery. IVC and common iliac veins are no longer opacified in early phase and right internal iliac artery is occluded.

secondary to lumbar spinal surgery were rarely encountered. Vascular injury in lumbar spinal surgery occurs secondary to penetration of surgical instruments beyond the anterior longitudinal ligament.<sup>5</sup> Vascular complications of lumbar disc surgery occur at the levels of L4-L5 and L5-S1 since aortic and caval bifurcation lie just anterior to L4-L5 disc space. The injury typically involves the aorta, IVC, iliac arteries and veins because of the proximity of these vascular structures to the intervertebral disc space and their relative immobility. Vessel injury is associated with the level of surgery as well as the angle of instrumentation. The right common iliac artery and vein are more frequently injured vessels due to proximity of these vessels to the L4-L5 level where the lumbar disc surgery mostly performed.<sup>6</sup> In a study, AVF was reported as most frequently vascular complication after lumbar disc surgery consisting of 78 of 122 vascular complications.<sup>7</sup> In a single-center experience of 8099 cases, AVF was reported in 2 patients after lumbar disc surgery.<sup>8</sup>

Nonspecific symptoms in iliac AVF cause delayed diagnosis which may result in enlargement of AVF and heart failure. AVF usually presents with signs and symptoms of high output cardiac failure including fatigue, palpitation, dyspnea, edema and abdominal distention.

Lower limb swelling and varices which were encountered in our patients most frequently occur due to acute or chronic DVT in the young population. Older patients experience lower limb swelling most frequently secondary to congestive heart failure. Discrepancy of our patients' age with common age range of congestive heart failure and absence of ischemic heart disease history did not suggest congestive heart failure as cause of lower limb swelling. Presence of murmur at right groin in the first patient and absence of Homan's sign suggested DVT less likely. Mainstay feature in history of patients suggesting AVF was previous lumbar disc surgery.

Angiography remains the gold standard in the diagnosis of AVF, however, contrast enhanced CT and MR angiography can be used as alternative noninvasive imaging techniques to depict vascular injury and fistula. Early filling of the venous system on contrast-enhanced CT or MRI can be helpful in the diagnosis as well as planning the treatment of AVF by revealing localization of the fistula, diameters of vessels and fistula and distance of fistula from aortic bifurcation.

Surgical treatment in iliac AVF carries high mortality and morbidity rates due to dilated collaterals and deep location of iliac vessels. Minimally invasive endovascular techniques are now the preferred option due to low mortality and morbidity rates with shorter and painless recovery period. In our second case, aneurysmatic dilatation of left common iliac vein resulted from AVF and

compression of vein by the right internal iliac artery. Involvement of internal iliac artery increases the risk of surgical injury and favors the endovascular approach in treatment of iliac AVFs.

In the endovascular treatment of the second case, internal iliac artery was occluded with an Amplatzer vascular plug to prevent retrograde flow to the fistula. Internal iliac artery embolization for prevention of endoleak in abdominal aortic aneurysms is well known procedure. Endoleak is characterized by persistent blood flow to the aneurysm sac after stent graft deployment. Coil embolization or Amplatzer vascular plug can be used to prevent endoleak after stent deployment. Although there are no long term comparative studies at this point, multiple case reports have demonstrated high technical success and good midterm results.

In conclusion, iliac AVF resulting from lumbar spinal surgery may manifest with multiple vessel involvement. Diagnosis of AVF can be difficult if not suspected due to nonspecific presenting symptoms. History of lumbar disc, pelvic or inguinal surgery and a presence of murmur in the groin vessels should raise the suspicion of AVF. Color flow Doppler US, CT and MRI can be helpful in the diagnosis and mapping of AVF. Endovascular treatment is a safe and appropriate method for the treatment of iliac AVFs.

### Funding

None declared.

### Conflict of interest

No funding or conflict of interest.

### References

1. Jarstfer BS, Rich NM. The challenge of arteriovenous fistula formation following disk surgery: a collective review. *J Trauma*. 1976;16, 726–333.
2. Antoniou GA, Koutsias S, Karathanos C, et al. Endovascular stent-graft repair of major abdominal arteriovenous fistula: a systematic review. *J Endovasc Ther*. 2009;16:514–523.
3. Davidovic LB, Kostic DM, Cvetkovic SD, et al. Aorto-caval fistulas. *Cardiovasc Surg*. 2002;10:555–560.
4. Linton FF, White PD. Arteriovenous fistula between the right common iliac artery and the inferior vena cava. *Arch Surg*. 1945;60:6–13.
5. Quigley TM, Stoney RI. Arteriovenous fistulas following lumbar laminectomy: the anatomy defined. *J Vasc Surg*. 1985;2:828–833.
6. Cholenahalli NM, Prabhavathi, Kikkeri HS, et al. Iatrogenic iliac arteriovenous fistula following lumbar disc surgery. *Post Kardiol Interw*. 2008;(11):40–42, 4, 1.
7. Pillet JC, Pillet MC, Braesco J, et al. Vascular complications of lumbar disc surgery. Report of two cases and review of the literature on 122 cases (French). *J Mal Vasc*. 1995;20:219–223.
8. Szolar DH, Preidler W, Steiner H, et al. Vascular complications in lumbar disc surgery: report of four cases. *Neuroradiology*. 1996;38:521–525.