

## Short Communications

# Transient Cerebral Ischemic Attack and Left Atrial Free-Floating Thrombus: A Case Report

ADNAN ABACI, M.D., GIRAY KABAKCI, M.D., LALE TOKGÖZOĞLU, M.D., FACC, ÜNSAL ERSOY, M.D.,\* SIRRI KES, M.D.

Department of Cardiology and \*Department of Cardiovascular Surgery, Hacettepe University School of Medicine, Ankara, Turkey

**Summary:** A patient with rheumatic mitral stenosis was found to have a free-floating thrombus in the left atrium during echocardiography. Subsequently, the patient underwent surgical treatment. At surgery, a free thrombus was found within the left atrium. The postoperative course of the patient was satisfactory.

**Key words:** ischemic, attack, left atrium, thrombus, free-floating

### Introduction

Left atrial free-floating thrombus (LAFFT) is an unusual entity and is almost always found in rheumatic mitral valvulopathy,<sup>1</sup> although it has also been reported in patients with mitral prostheses,<sup>2</sup> myocardial pathology,<sup>3</sup> and orthotopic heart transplantation.<sup>4</sup> It is associated with possible episodes of systemic embolism and symptoms caused by obstruction of the left ventricular inflow tract (syncope, dyspnea, and hemodynamic collapse). We report a patient with mitral and tricuspid stenosis in whom an LAFFT was detected echocardiographically and subsequently confirmed by surgery.

### Case Report

A 34-year-old woman was admitted to our hospital because of dyspnea, orthopnea, paroxysmal nocturnal dyspnea, and

palpitations. She was known to have had rheumatic heart disease since July 1994 and had been maintained on therapy with digoxin and diuretics.

On admission, physical examination revealed a heart rate of 160/min, irregular; blood pressure of 110/90 mmHg; and respiratory rate of 24/min. On cardiac auscultation, an accentuated first heart sound with both a II/VI systolic murmur and an unchanging diastolic rumble was audible at the apex. Pulmonary examination revealed fine bibasilar rales. The jugular venous pressure was elevated, and pedal edema was noted along with hepatomegaly and ascites. An electrocardiogram (ECG) demonstrated atrial fibrillation with a right bundle-branch block pattern. Chest x-ray examination demonstrated an enlarged left atrium and prominent pulmonary conus with evidence of pulmonary venous congestion with minimal right pleural effusion. Complete blood count, erythrocyte sedimentation rate, and blood biochemistry were within normal limits, except for slightly elevated ALT and AST values.

A two-dimensional echocardiogram with color Doppler flow imaging was performed using a Toshiba SSH 160 A echo machine with a 2.5 MHz transducer. Severe mitral valve stenosis with second-degree regurgitation was detected. The mitral valve area and mean pressure gradient were 0.7 cm<sup>2</sup> and 16 mmHg, respectively. The left atrium was markedly dilated (6.0 cm) without any thrombus. Tricuspid valve stenosis with mean diastolic 5 mmHg gradient was also present. Second-degree tricuspid regurgitation was detected and pulmonary artery systolic pressure of 50 mmHg was measured. There was also a small amount of pericardial fluid.

Five days after admission, the patient suffered aphasia with face weakness lasting 6 h and the diagnosis of transient cerebral ischemic attack was made. On repeat echocardiogram, a spherical, homogeneous echodensity was seen within the left atrial cavity (Fig. 1). The echogenic tissue was floating freely within the left atrial cavity. There was periodic diastolic impaction of the mass against the mitral valve orifice, with abrupt rebound back into the left atrial cavity toward the pulmonary vein orifices with the onset of ventricular systole. These findings suggested that the thrombus was not attached to the left atrial wall or to the mitral valve. The diameters of thrombus were measured as 20 × 26 mm.

The patient was taken to the operating room the next morning. At open-heart surgery, a smooth-surfaced thrombus

---

Address for reprints:

Adnan Abaci  
Meyvali Sokak  
13/21 Etlik  
Ankara, Turkey

Received: March 25, 1997

Accepted with revision: December 22, 1997

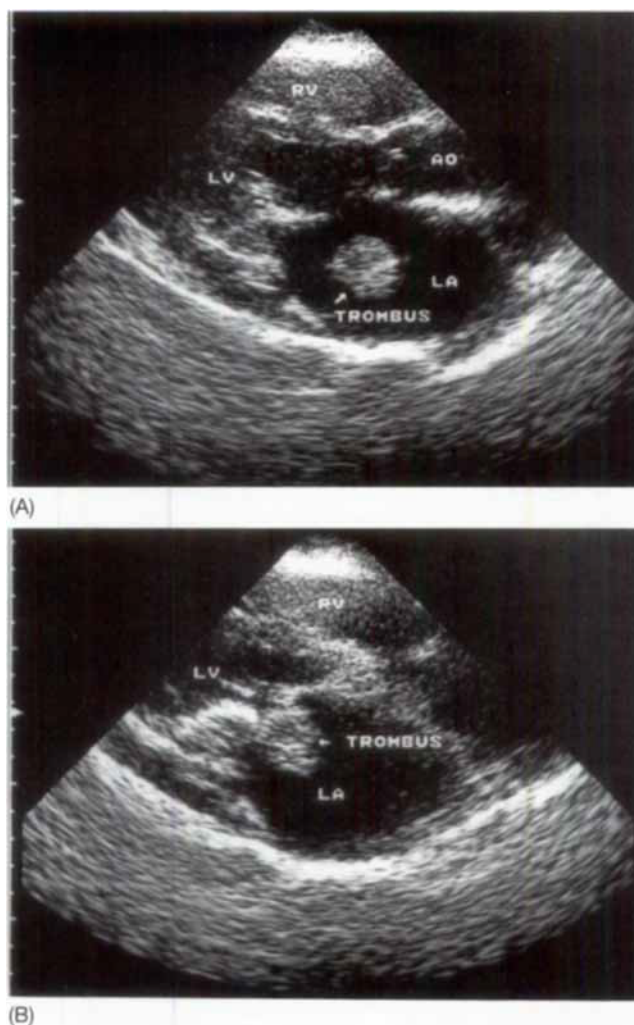


FIG. 1 Parasternal long-axis view of the left atrium demonstrating different locations of the free-floating thrombus.

measuring  $30 \times 20$  mm was found to lie freely within the left atrium and was successfully removed. The left and right atrial appendages were filled with thrombus. Thrombus was also present in the origin of the pulmonary veins. These were removed and right and left atrial appendages were tied off. The mitral valve was very thick and hardened, and the leaflets were fused. The mitral valve was replaced by a Björk-Shiley mitral prosthesis and tricuspid annuloplasty was carried out. The postoperative period was normal. Seven days post surgery, echocardiographic study was repeated and showed normal prosthesis function. No thrombus was seen in the left atrium. Two months post surgery, the patient was asymptomatic and receiving adequate anticoagulant treatment.

## Discussion

Left atrial free-floating thrombus is an infrequent clinical syndrome that can have a catastrophic outcome but can be

successfully treated if recognized. It is usually a complication of long-standing rheumatic mitral stenosis.

The origin of LAFFT's can only be surmised. They most likely arise from thrombi which previously have been attached to the atrial wall. The potential for either obstructive or embolic catastrophe due to a free-floating thrombus has been reported.

If the thrombus fragments from repeated collisions within the left atrium, peripheral embolization may occur,<sup>1</sup> as was the case in our patient. The most dramatic consequence of free-floating thrombus is sudden hemodynamic deterioration due to left ventricular inflow obstruction, the so-called "ball valve" or "hole-in-one" effect.<sup>5</sup> Such pathophysiologic mechanism has been implicated in causing episodic dyspnea and syncope,<sup>5</sup> has been documented to result in hemodynamic collapse immediately prior to mitral valve replacement,<sup>6</sup> and has been seen on two-dimensional echocardiography to lodge intermittently in the mitral orifice.<sup>7</sup> In our case it was thought that the size of the thrombus was such that it did not obstruct the left ventricular inflow tract.

It is well known that patients with mitral stenosis are at risk for thrombus formation because this condition is associated with abnormal flow within the left atrium. The standard treatment for fixed left atrial thrombi is anticoagulation with heparin and/or warfarin. However, because of the relative infrequency of LAFFT, no clinical trial exists that might direct the choice of treatment. The role of anticoagulants is uncertain in the management of this disorder, because LAFFTs have developed after the initiation of anticoagulant therapy.<sup>8</sup> Furthermore, anticoagulant therapy in one patient dislodged a pedunculated atrial thrombus, suggesting that anticoagulation may initiate the formation of LAFFT.<sup>9</sup> Thrombolytic therapy has been attempted in other forms of intracardiac thrombosis, but embolic events after the thrombolytic therapy have been reported.<sup>10, 11</sup> To our knowledge, there is no attempt to treat LAFFT with thrombolytic therapy.

The results of anticoagulation and thrombolysis are unpredictable and potentially as harmful as no treatment at all. Therefore, the presence of a free-floating left atrial thrombus would appear to justify the performance of urgent surgery for clot evacuation, usually in conjunction with mitral valve repair or replacement, based on echocardiographic findings alone.<sup>8</sup>

## References

1. Wrisley D, Giambartolomei A, Lee I, Brownlee W: Left atrial ball thrombus: Review of clinical and echocardiographic manifestations with suggestions for management. *Am Heart J* 1991;121:1784-1790
2. Gonzalez-Alujas T, Evangelista-Masip A, Garcia Del Castillo H, Tornos-Mas P, Soler-Soler J: Recurring free-floating thrombus in the left atrium in a patient with mitral prosthesis. *Chest* 1994;106:303-304
3. Hamada M, Matsubara W, Tomita N, Miyauchi Y, Kokubu T: Left atrial mobile thrombus in hypertrophic cardiomyopathy. *Am J Cardiol* 1985;56:812-814
4. Fernandez de Soria R, Garcia de Andoain JM, Lopez JR, Vera A, Cobos MA, Fernandez G, Alvarez JM, Alonso F: Left atrial free-floating thrombus with multiple systemic emboli in orthotopic heart transplantation. *Am Heart J* 1992;124:1090-1093
5. Szkopiec RL, Torstveit JR, Prakash NS, Desser KB, Benchimol A: Non-invasive diagnosis of a free-floating left atrial thrombus with emphasis on two-dimensional echocardiographic features. *Angiology* 1983;34:102-110
6. Tabak SW, Maurer G: Echocardiographic detection of free-floating left atrial thrombus. *Am J Cardiol* 1984;53:374-375
7. Gottdiener JS, Temeck BK, Patterson RH, Fletcher RD: Transient ("hole-in-one") occlusion of the mitral valve orifice by a free-floating left atrial ball thrombus: Identification by two-dimensional echocardiography. *Am J Cardiol* 1984;53:1730
8. Wrisley D, Giambartolomei A, Levy I, Brownlee W, Lee I, Erickson J: Left atrial ball thrombus: Apparent detachment following initiation of anticoagulant therapy. *Am Heart J* 1988;116:1351-1352
9. Tsuda Y, Satoh K, Matsuo H: Formation of left atrial ball thrombus during anticoagulation in a case of cerebral embolism. *Stroke* 1990;21:1375-1376
10. Blazer D, Degroat T, Kotler MN: Peripheral embolization during thrombolytic therapy for left atrial thrombus. *Am J Cardiol* 1986;58:554-555
11. Grunewald RA, Smith PLC, Nihoyannopoulos P: Right ventricular pacing wire thrombus presenting as pyrexia of unknown origin. *Clin Cardiol* 1989;12:106-108