

Case Reports

Left Ventricular Thrombosis Due to Acquired Protein C Deficiency Diagnosed by Two-Dimensional Echocardiography

Süheyla ÖZKUTLU, M.D.,* Nazan ÖZBARLAS, M.D.,**
Muhsin SARAÇLAR, M.D.,* and Funda ÖZTUNÇ, M.D.**

SUMMARY

We present a patient with left ventricular thrombus diagnosed by two-dimensional echocardiography. Thrombosis was due to acquired transient protein C deficiency which was caused by impaired liver function due to hepatitis, sepsis and heart failure. With proper treatment the thrombus disappeared on the fourth day. Eighteen weeks later the protein C level returned to normal. We recommend echocardiographic evaluation and follow-up of suspected cases for intracardiac thrombus. The measurement of protein C level in such cases is proposed. This is the first case with left-sided cardiac thrombus associated with protein C deficiency in the medical literature.

Key Words:

Protein C Thrombus Two-dimensional echocardiography
Heart failure Sepsis

IN the pediatric age group, thrombi are generally localized in the right side of the heart, while a thrombus on the left side is quite rare. Various events have been cited as possible etiologic factors. Recently, with the description of tricuspid valve noninfective endocarditis due to congenital protein C deficiency, a new possible etiologic factor has been added to our knowledge about intracardiac thrombosis.¹⁾

Protein C is a hepatic vitamin K dependent zymogen with anticoagulant and fibrinolytic properties in its activated form.²⁾ Patients with decreased concentrations of protein C appear to be at risk of venous thrombosis and embolism. However a few cases of arterial thrombosis have been reported.²⁾⁻⁴⁾ In this case study we present an intracardiac thrombus lo-

From the Department of Cardiology, Hacettepe University, Institute of Child Health, Ankara, Turkey.

* Professor of Pediatrics and Pediatric Cardiologist.

** Pediatric Cardiologist.

Mailing address: Süheyla Özkutlu, M.D., Department of Pediatric Cardiology, Hacettepe University, Ankara, Turkey.

Received for publication May 13, 1991.

Accepted October 17, 1991.

calized in the left ventricle due to acquired transient protein C deficiency. To our knowledge, this is the first such case in the medical literature.

CASE REPORT

A 28-day-old newborn was brought to the hospital with tachypnea and poor feeding. He was born at term with a birth weight of 3,200 g following an uncomplicated pregnancy and normal delivery. The first 20 days of life were uneventful. Both parents were healthy and no consanguinity was present.

At admission, the infant was extremely ill, lethargic and tachypneic. The heart rate was 220/min and rectal temperature was 38°C. Perioral and peripheric cyanosis, and cutis marmoratus were present. The liver was palpable 3 cm below the right costal margin. No significant cardiac murmur was heard.

Laboratory studies revealed the following values: Hb 16.5 g/dl, WBC 14,600/mm³ with 80% segmented neutrophils and 50% toxic granulation. Platelets were decreased on peripheral blood smear. Blood biochemical profile showed significant impairment of liver function (GOT 2,571 units, GPT 978 units, direct bilirubin 3.4 mg/dl, indirect bilirubin 1.2 mg/dl). *Escherichia coli* bacillus was cultured from the blood. Diagnostic markers of intrauterine infection and hepatitis B and A viruses were negative. X-ray showed moderate cardiomegaly and supraventricular tachycardia was noted on the electrocardiogram. Two-dimensional and M-mode echocardiography showed a dense echo image 8×6 mm in size in the left ventricular apex (Fig. 1). Left ventricular functions were normal (ejection fraction 60%, shortening fraction 31%).

The coagulation profile showed a platelet count of 60,000/mm³, PT (prothrombin time) of 45 sec and PTT (partial thromboplastin time) of 69 sec. Fibrin degradation products were over 40 units. The functional measurement of protein C level by the coagulation method (Diagnostica Stago, Asnieres-Sur-Seine, France) was 15%. The established normal levels in our laboratory are between 70% and 140%. The patient's anti-thrombin III and protein S were both within normal ranges. Both parents had normal levels of protein C.

The neonate was diagnosed as having sepsis and treatment with intravenous penicillin G and cefotaxime was started. Supraventricular tachycardia was treated with intravenous digitalization and sinus rhythm was restored. Anticonvulsant therapy was initiated after left focal convulsions had occurred. The patient was given 100 units/kg of heparin sodium every

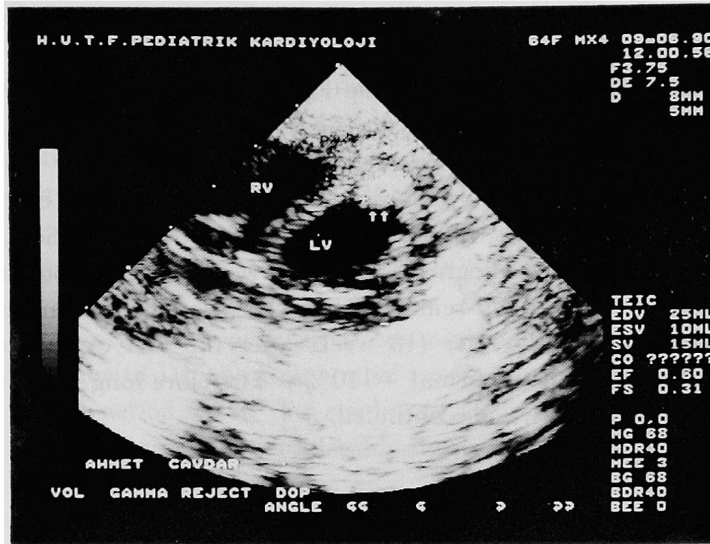


Fig. 1. Two-dimensional echocardiogram. Arrows indicate the thrombotic mass in the left ventricular apex. RV=right ventricle; LV=left ventricle.

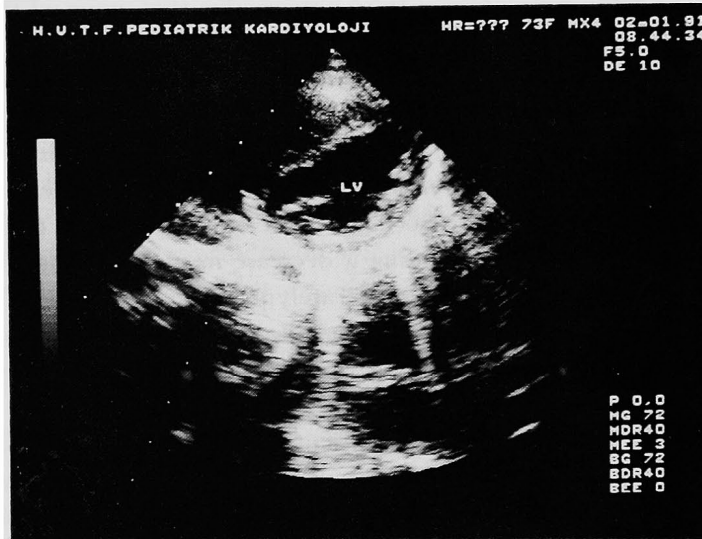


Fig. 2. Two-dimensional echocardiogram. Disappearance of the left ventricular thrombus is seen. LV=left ventricle.

4 hours and 10 ml/kg of fresh frozen plasma every 8 hours, intravenously. On the second day the platelet count was 180,000/mm³; PT and PTT returned to normal levels. Repeat echocardiography on the fourth day revealed the disappearance of the dense echo image in the left ventricle (Fig.

2). Ultrasound of the cranium showed a subdural effusion on the right parietooccipital region.

The patient was discharged on the 11 day in a good clinical condition. Treatment with 80 mg/day acetylsalicylic acid, digoxin and phenobarbital was recommended. Twenty days later computerized brain tomography showed infarcts in the right parietooccipital region and subdural effusion.

One month later, the patient was symptom free. Physical, electrocardiographic and echocardiographic findings were normal. But protein C level was still low (11%) and remained low (12%) at the next measurement 4 weeks later. Six weeks later (18 weeks after the first examination) the protein C level returned to normal —110%. Therefore long term treatment with acetylsalicylic acid was discontinued.

DISCUSSION

In the newborn period, intracardiac thrombi are generally localized on the right side of the heart and are related to usage of central venous catheters, polycythemia, congenital cardiac defects, respiratory distress syndrome, and persistent fetal circulation. It is noteworthy that none of the above-mentioned conditions was present in this case.

Clinically, purpura fulminans in neonates, venous thromboembolism and arterial thrombosis, albeit rarely, are known to occur due to protein C deficiency.²⁾⁻⁴⁾ During purpura fulminans or thrombotic episodes in neonates and thromboembolic attacks in adults with protein C deficiency, the laboratory results have been associated with a compensated disseminated intravascular coagulopathy, including a decrease in platelets and fibrinogen, increased fibrin split products and moderately prolonged PT and PTT.^{2),5)}

Protein C deficiency may be congenital or acquired. Acquired deficiencies occur in association with liver disease, adult respiratory distress syndrome, surgical procedures and disseminated intravascular coagulopathy.³⁾ Griffin et al showed that patients with intravascular coagulation of various etiologies had decreased protein C levels and they concluded that extensive activation of the coagulation system in vivo causes a significant consumption of protein C.⁶⁾ Additionally McDonald et al reported 2 cases with nonhereditary neonatal protein C deficiency in association with cardiac failure in the neonatal period (when liver function is poor and vitamin K deficiency may coexist) could impair hepatic production of protein C with consequent risk of thrombotic complications.³⁾

In the case presented, we think that liver function may have been impaired mainly due to hepatitis during septicemia although heart failure

resulting from supraventricular tachycardia may have played a role to some extent. This leads to acquired protein C deficiency through low production. However it is difficult to differentiate coagulopathy associated with protein C deficiency from DIC by evaluating the coagulation profile of our patient. Nevertheless, the coagulation profile in our patient, taking into account decreases in platelet count, slightly prolonged PT, PTT and the absence of extensive hemorrhage, is in better agreement with the compensated DIC syndrome, rather than extensive activation of the coagulation system.

In the literature, in two different postmortem studies, a different coagulopathy syndrome of DIC and vegetative cardiac thrombus has been defined in the neonatal period.⁷⁾ In this condition, while the decrease in coagulation factors was minimal, a considerable decrease in platelet count was observed. In our view, the coagulopathy different from DIC and intracardiac thrombosis in these cases, could be due to protein C deficiency as in our case.

We think that infarcts, shown by computerized brain tomography, may be due to cerebral venous or arterial thrombosis often seen in protein C deficiency, as well as to arterial thromboembolism due to thrombus in the left ventricle.⁴⁾

The therapeutic effect of fresh frozen plasma infusion (replacement of protein C) is well known.²⁾ On the other hand there is controversy regarding the usefulness of heparin treatment during thrombotic attacks.

In conclusion, we believe that plasma protein C deficiency should be investigated in all cases of intracardiac thrombi, and two-dimensional echocardiography should be applied in all those patients with protein C deficiency because of the possibility of intracardiac thrombosis. A prospective study of such cases is under way at our unit.

REFERENCES

1. Özkutlu S, Saraçlar M, Atalay S, Demircin M, Ruacan S: Two-dimensional echocardiographic diagnosis of tricuspid valve noninfective endocarditis due to protein C deficiency. *Jpn Heart J* **32**: 139, 1991
2. Marlar RA, Montgomery RR, Broekmans AW and the Working Party: Diagnosis and treatment of homozygous protein C deficiency. Report of the Working Party on homozygous protein C deficiency of the subcommittee on protein S, International Committee on Thrombosis and Haemostasis. *J Pediatr* **114**: 528, 1989
3. McDonald PD, Walker ID, Galez P, Alroomi LG: Acquired transient protein C deficiency in neonatal cardiac failure. *Arch Dis Child* **65**: 158, 1990
4. Dusser A, Boyer-Neumann D, Wolf M: Temporary protein C deficiency associated with cerebral arterial thrombosis in childhood. *J Pediatr* **113**: 849, 1988
5. Melissari E, Kakkar VV: Congenital severe protein C deficiency in adults. *Br J Haem* **72**: 222, 1989

6. Griffin JH, Mosher DF, Zimmerman TS, Kleiss AJ: Protein C and antithrombotic protein is reduced in hospitalized patients with intravascular coagulation. *Blood* **60**: 261, 1982
7. Favara BE, Franciosi RA, Butterfield J: Disseminated intravascular coagulation and cardiac thrombosis of the neonate. *Am J Dis Child* **127**: 197, 1974