

Development of Calciphylaxis after Long-term Steroid and Methotrexate Use in a Patient with Rheumatoid Arthritis

Zeynep OZBALKAN, Meral CALGUNERI, A. Mesut ONAT and M. Akif OZTURK

Abstract

Calciphylaxis may be considered a small vessel vasculopathy which is generally associated with end-stage renal disease and hyperparathyroidism. The precise pathogenesis of the disease is not known. It needs sensitizers and challengers to occur. Steroids and immunosuppressive drugs including methotrexate are among those challenger agents. Calciphylaxis in collagen vascular diseases is rare. Only one case in rheumatoid arthritis was recently reported. Here we describe a case of calciphylaxis associated with active rheumatoid arthritis. This patient had active disease despite treatment of steroids and methotrexate for a long time. She died shortly after the diagnosis of calciphylaxis due to sepsis. (Internal Medicine 44: 1178–1181, 2005)

Key words: calciphylaxis, rheumatoid arthritis, methotrexate, steroid

Introduction

Calciphylaxis has been described as tissue sensitivity to calcification (1). It is a rare and often fatal complication of progressive cutaneous necrosis secondary to calcification of small- and medium-sized vessels (2). Although it has been seen almost exclusively in patients with end stage renal diseases and hyperparathyroidism, some patients without renal and parathyroid dysfunction develop calciphylaxis (3). It is characterized by skin lesions, subcutaneous nodules, skin necrosis, ulceration, and eschar formation (4). Its histology reveals medial calcification and intimal hyperplasia of dermal and subcutaneous small arteries often accompanied by microthrombosis (5). The etiopathogenesis of calciphylaxis is still uncertain. However, several factors have been proposed as triggers of calciphylaxis (6, 7). Steroid therapy and immunosuppressive agents such as methotrexate and cyclo-

phosphamide are among those factors (8, 9). There are anecdotal reports demonstrating association of calciphylaxis and systemic lupus erythematosus with end-stage renal failure. Only one case of calciphylaxis was reported to develop in a patient with rheumatoid arthritis (8). We report another case of calciphylaxis associated with rheumatoid arthritis.

Case Report

A 22-year-old young woman was admitted to our department with the complaints of pain and swelling in proximal interphalangeal, metacarpophalangeal, wrist, elbow and metatarsophalangeal joints, bilateral breast masses and diplopia in April 2001. Because of her complaints of symmetric polyarthritis of small joints in both hands and feet together with morning stiffness and the positive result of rheumatoid factor, she had been diagnosed as rheumatoid arthritis in 1996 according to the American College of Rheumatology (ACR) (10) criteria and treated with 7.5 mg/week oral methotrexate and 20 mg/day oral prednisolone for 4 years in another center. She had developed nut-shaped subcutaneous nodules over the abdomen and extremities, bilateral breast masses and fever (as high as 40°C) since 2000. On physical examination her general condition was poor, arterial blood pressure was 110/80 mmHg, heart rate was 110/min, and body temperature was 38.7°C. There was symmetric polyarthritis in the proximal interphalangeal and metacarpophalangeal joints of the hand, wrist, and elbow and in the metatarsophalangeal joints; the breast tissue was nodular and atrophic, and there were multiple irregular subcutaneous nodules over the abdomen, thighs, and the extremities. Muscle weakness was noted in both lower extremities. Laboratory tests were as follows: erythrocyte sedimentation rate 112 mm/h, serum CRP 34 mg/dl (N: 0–5 mg/dl), hemoglobin (Hb) 6.5 g/dl, white blood cell count (WBC) 18,900/mm³, platelets 340,000/mm³. Bacteriologic evaluation failed to demonstrate presence of an infectious agent. The elevation of acute phase response was attributed to ongoing active rheumatoid arthritis. Liver and renal functions tests

From Hacettepe University Faculty of Medicine, Internal Medicine Department, Section of Rheumatology, Ankara, Turkey

Received for publication November 24, 2004; Accepted for publication April 21, 2005

Reprint requests should be addressed to Dr. Zeynep Ozbalkan, Sehit Cetin Gorgu Sok., Ugur Apt. 17/3, 06570 Maltepe, Ankara, Turkey

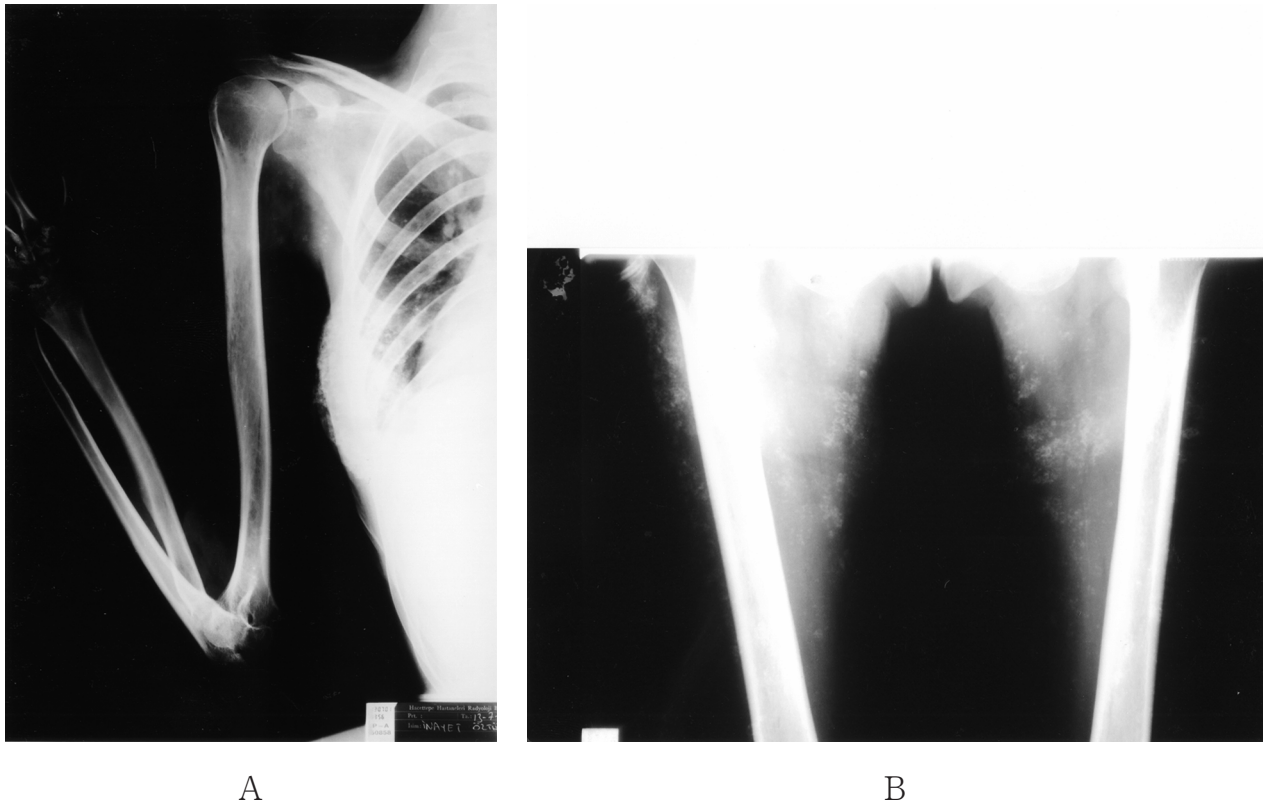


Figure 1. A and B: X-rays of the upper and the lower extremities demonstrating numerous of nodular calcifications along to the vascular structures in the soft tissue.

and electrolytes were within normal limits. Serum total calcium was 8.4 mg/dl (N: 9–11 mg/dl) and serum phosphorus level was 2.9 mg/dl (N: 4–6mg/dl). Serum BUN was 6.7 mg/dl; serum creatinine was 1.0 mg/dl and glomerular filtration rate was 90 ml/min. Serum albumin and total protein levels were 3.1 gm/dl (N: 4–5.5 gr/dl) and 6.8 gm/dl (N: 6–8 gr/dl) respectively. Parathyroid hormone was 40 pg/ml (N: 12–72 pg/ml) and calcitonin was 10.3 pg/ml (N: 0–30 pg/ml). Immunological tests including anti-nuclear antigen (ANA), anti-ds-DNA, extractable nuclear antigens (ENA) including anti-scl 70 and anti-centromer were negative. Rheumatoid factor was 490 IU/ml (N <20 IU/ml). A possible association with malign conditions was investigated. CA15-3 was 47.7 ng/ml (N: 0–30 ng/ml). CEA, alfa-feto protein, CA19-9, CA125 were within normal limits. Skin test for tuberculosis was negative. The X-rays of the hands and the feet demonstrated periarticular osteoporosis, subcondral sclerosis, degenerative cystic changes and sublaxations on the proximal interphalangeal, metacarpophalangeal, wrist and ankle joints. X-ray of the legs showed linear calcifications along the vessels and punctat calcifications in the subcutis. There were calcific nodules at the axilla and breasts at chest X-rays (Fig. 1). Bone survey X-rays, thoracic computed tomography and cranial magnetic resonance imagining to examine for metastasis and vasculitis were normal except for calcifications. Electromyography revealed remarkable mixed

subacute polyneuropathy in the lower extremities. Since she had bilateral atrophic, nodullary, and hard breasts and CA 15-3 level was elevated, excisional breast biopsy was performed. Histopathological examination of the breast tissue demonstrated normal glandular structures, and calcifications in the stroma and around the vascular tissue, without any evidence of inflammation within the vessels walls or microthrombus in the lumen (Fig. 2), that was diagnosed as the calciphylaxis with active rheumatoid arthritis. One month after the hospitalization she had the complication of *Pseudomonas aeroginosa* sepsis, and despite antimicrobial treatment she died.

Discussion

Calciphylaxis may be considered a small vessel vasculopathy which is associated with intimal proliferation and fibrosis and the process refers to local or generalized tissue deposition of calcium together with inflammation and sclerosis (1). Little is known about the pathophysiology. It requires sensitization of the tissue by PTH, vitamin D, phosphate, calcium salts or renal failure. Also it needs additional challenging factors, such as iron salts, steroids and immunosuppressive drugs such as methotrexate, cylophosphamide, flouourasil (5, 11, 12). Steroids as challengers of calcinosis, have also been observed in renal failure patients. Fader and

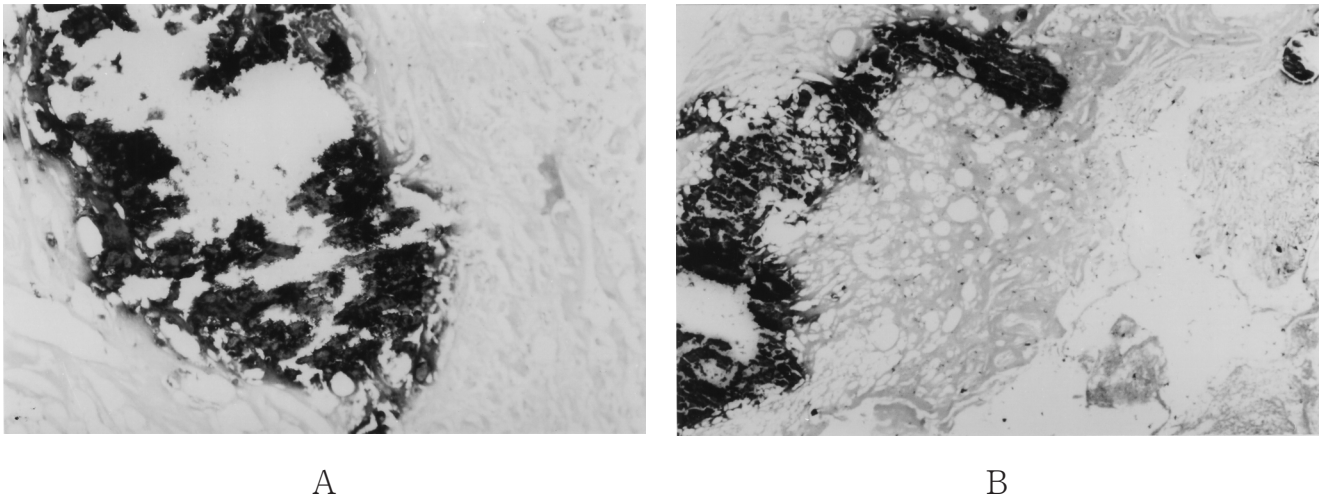


Figure 2. A and B: Microscopic view of the small arteries from the breast tissue. Irregular shaped depositions of calcification on the left-hand side around the vessels and on the stroma and ischemic necrosis and fibrosis all around. No vasculitic or thrombotic findings were observed at the vessel wall or lumen (Hematoxylin-eosin $\times 200$).

Kang reported a case of calciphylaxis independent of renal failure caused by albumine infusion due to liver failure and treatment with prednisolone therapy for presumed vasculitis (13). The present patient had active rheumatoid arthritis on the hospitalization and was ineffectively treated with methotrexate and prednisolone therapy for a long time. She did not have chronic renal insufficiency. The mortality rates of patients with calciphylaxis are high, and the main reason for death is sepsis. It is not clear how long this interval is leading death after the development of calciphylaxis (4, 11). Likewise, the present patient died secondary to sepsis after one month of hospitalization.

It has also been reported in other conditions including malignancies and collagen vascular disorders. Recently, Korkmaz et al reported a patient with rheumatoid arthritis who developed calciphylaxis without renal failure and hyperparathyroidism. They proposed that, long-term steroid use and protein S deficiency might contribute to calcium deposition in tissue (8). The present patient had evidences of neither thrombi nor coagulation abnormalities. Also the biopsy specimen did not show any microthrombus in the vessel lumen. So, we did not investigate the coagulation parameters or the levels of protein C or S.

To our knowledge, to date there is no reported case of RA treated with methotrexate and steroids, associated with calciphylaxis. Here, we represent the development of calciphylaxis in a patient with active rheumatoid arthritis who was unsuccessfully treated with long-term steroids and methotrexate. Because calciphylaxis is one of the mimickers of vasculitis, it should be considered in the differential diagnosis of rheumatoid vasculitis. In this patient we tried to find the evidence of vasculitis and tumors that may cause the diplopia and muscle weakness in the lower extremities. Both clinical findings and laboratory results were relevant from the vasculitis, demyelination and tumors, and calciphylaxis

itself may cause diplopia in this patient. This consideration, calciphylaxis may develop in rheumatoid arthritis patients using steroid and methotrexate for a long period. It will be necessary to investigate why a great majority of patients treated with long-term steroid do not develop calciphylaxis and whether underlying systemic inflammatory disorders like rheumatoid arthritis serve as sensitizers for calciphylaxis.

References

- 1) Selye H. Calciphylaxis. University of Chicago Press, Chicago, 1962.
- 2) Streit M, Parade BE, Russefer S. Typical features of calciphylaxis in a patient with end-stage renal failure, diabetes mellitus, and oral anticoagulation. *Dermatology* **200**: 356–359, 2000.
- 3) Pollock B, Cunliffe WJ, Merchant WJ. Calciphylaxis in the absence of renal failure. *Clin Dermatol* **25**: 389–392, 2000.
- 4) Mazhar AR, Johnson RJ, Gillen D, et al. Risk factors and mortality associated with calciphylaxis in end-stage renal disease. *Kidney Int* **60**: 324–332, 2001.
- 5) Goyal S, Huhn KM, Provost TT. Calciphylaxis in a patient without renal failure or elevated parathyroid hormone. Possible etiological role of chemotherapy. *Br J Dermatol* **433**: 1087–1090, 2000.
- 6) Zacharias JM, Fontaine B, Fine A. Calcium use increases risk of calciphylaxis a case-control study. *Perit Dial Int* **19**: 248–252, 1999.
- 7) Ledbetter LS, Khoshnevis MR, Hsu S. Calciphylaxis. *Cutis* **66**: 49–51, 2000.
- 8) Korkmaz C, Dündar E, Zubaroglu I. Calciphylaxis in a patient with rheumatoid arthritis without renal failure and hyperparathyroidism: The possible role of long-term steroid use and protein S deficiency. *Clin Rheumatol* **21**: 66–69, 2002.
- 9) Janigan DT, Hirsch DJ, Klassen GA, MacDonald AS. Calcified subcutaneous arterioles with infarcts of the subcutis and skin (“calciphylaxis”) in chronic renal failure. *Am J Kidney Dis* **35**: 588–597, 2000.
- 10) Arnett FC, Edworthy SM, Bloch DA, et al. The American Rheumatism Association 1987 revised criteria for the classification of rheumatoid arthritis. *Arthritis Rheum* **31**: 315–324, 1988.
- 11) Rella C, Coviello M, Giotta F, et al. A prothrombotic state in breast cancer patients treated with adjuvant chemotherapy. *Breast Cancer Res*

Development of Calciphylaxis after Long-term Steroid

- Treat **40**: 151–159, 1996.
- 12) Feffer SE, Carmosino LS, Fox R. Acquired protein C deficiency in patients with breast cancer receiving cyclophosphamide, methotrexate, and 5-fluorouracil. *Cancer* **63**: 1303–1307, 1989.
- 13) Fader DJ, Kang S. Calciphylaxis without renal failure. *Arch Dermatol* **132**: 837–838, 1996.
-