

## Acute lymphoblastic leukaemia presenting with arthritis in an adult patient

Celalettin Usalan, Ersan Özarslan, Nurullah Zengin, Yahya Büyükaýk, Ýbrahim H Güllü

### Summary

**The earliest manifestations of leukaemia often include rheumatic signs and symptoms. Arthritis is a well recognised complication of leukaemia in children, but acute and chronic leukaemia may also cause arthritis in adults. Leukaemic arthritis may occur at any time during the course of leukaemia and may be the presenting manifestation. It should therefore be considered in the differential diagnosis of both childhood and adult rheumatic disease. We present an adult patient presenting with arthritis due to acute leukaemia.**

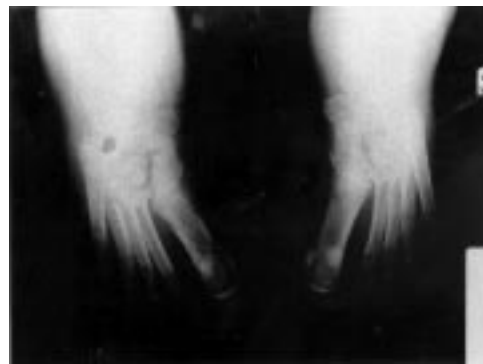**Keywords:** arthritis; leukaemia; synovial fluid analysis

A significant number of patients with leukaemia have bone or joint symptoms as a part of their disease.<sup>1</sup> However, arthritis as an initial manifestation of leukaemia is extremely rare.<sup>2</sup> Leukaemic arthritis (LA) may be defined as joint pain and swelling in association with peripheral blood or bone marrow leukaemia after other causes of arthritis have been excluded.<sup>3</sup> Early in the course of the disease there may be difficulty in arriving at the correct diagnosis when studies of peripheral blood are not diagnostic.

We report an adult patient presenting with arthritis whose peripheral smear was normal. However, examination of synovial fluid and bone marrow revealed LA and acute lymphoblastic leukaemia (ALL).

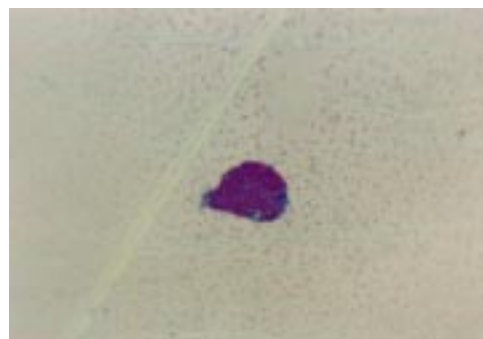
### Case report

A 22-year-old man was referred to our hospital with complaints of pain and swelling of his ankles for the last 3 months. On initial evaluation, he was conscious and fully oriented. Body temperature, blood pressure, pulse rate were 38.3°C, 130/80 mmHg, and 86 beats/min, respectively. On physical examination there was diffuse swelling and tenderness with erythema and discharge in both ankles. Other physical findings were within the normal range. Haematological studies revealed a haemoglobin level of 9.6 g/dl, leukocytes  $10.3 \times 10^9/l$  (55% neutrophils, 22% lymphocytes, 19% monocytes, 4% eosinophils), platelets  $310 \times 10^9/l$ , with an erythrocyte sedimentation rate of 103 mm/h. Blood biochemical values were normal. Serum uric acid was 5.4 mg/dl (normal range 3.5–8.5 mg/dl). Antinuclear antibody, rheuma-



**Figure 1** Ankle radiographs showing soft tissue swelling and joint effusion

toid factor, and serological tests for hepatitis B were negative. Anti-DNA and serum complement level were within normal limits. Radiographs of the ankles showed soft tissue swelling and joint effusion (figure 1). The synovial fluid could not be aspirated during the first arthroscopy. The patient was prescribed indomethacin and colchicum for the pain, but during the following 2 weeks there was no benefit and the patient's symptoms increased, with complaints of pain and swelling of knees. Arthroscopy was repeated and cytologic examination revealed immature blastic cells (figure 2). Flow cytometric analysis of synovial fluid revealed CD19 58%, CD20 70%, and HLA-DR 91%. A bone marrow aspiration and biopsy was performed. Infiltration of leukaemic cells was seen on bone marrow aspiration (figure 3), and a diagnosis of ALL (L2, B-cell origin) was made. Mitoxantrone, vincristine and prednisolone were



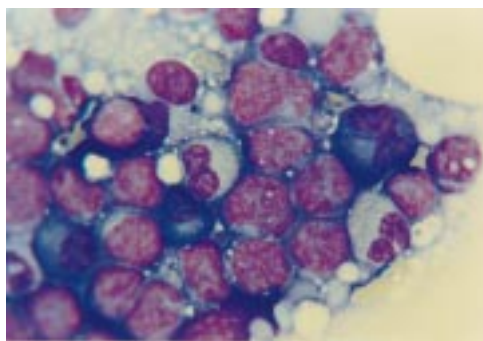
**Figure 2** Synovial fluid examination revealing immature blast cells

Hacettepe University  
School of Medicine,  
Ankara, Turkey  
Department of  
Internal Medicine  
C Usalan  
E Özarslan  
Y Büyükaýk  
Institute of Oncology  
N Zengin  
Ý H Güllü

Correspondence to  
Dr Celalettin Usalan, Sinan  
Caddesi, No 49/12, 06450  
Dikmen, Ankara, Turkey

Accepted 17 December 1998

**Figure 3** Bone marrow aspiration showing infiltration by leukaemic cells (large, nonuniform sizes with irregular nuclear shape)



started immediately. However, his overall condition deteriorated and he died of neutropenia and sepsis on the seventh day of chemotherapy.

### Discussion

The leukaemias are a heterogeneous group of neoplasms arising from the malignant transformation of haematopoietic cells. Leukaemic cells proliferate primarily in the bone marrow and lymphoid tissues where they interfere with normal haematopoiesis and immunity. Leukaemias are classified according to the cell types primarily involved (myeloid or lymphoid) and as acute or chronic based upon the natural history of the disease. Acute leukaemia can be identified and classified on the basis of morphology, immunologic phenotype, and cytochemistry (table). It is critical to distinguish ALL from acute myeloid leukaemia (AML) since these two diseases differ considerably in their clinical behaviour, prognosis, and response to therapy.<sup>4</sup>

In addition to suppressing normal marrow function, leukaemic cells can infiltrate normal organs. In general, this occurs more commonly in ALL than AML.<sup>4</sup> LA, an uncommon complication of acute leukaemias, develops due to infiltration of synovial membrane by leukaemic cells. Childhood leukaemias (especially ALL) are complicated by arthritis more frequently than adult leukaemias. It has been

**Table** Classification of acute leukaemias

FAB subtype	Morphology variant	% cases
<b>AML</b>		
M0	minimally differentiated leukaemia	2–3
M1	myeloblastic leukaemia without maturation	20
M2	myeloblastic leukaemia with maturation	25–30
M3	hypergranular promyelocytic leukaemia	8–15
M4	myelomonocytic leukaemia	20–25
M5	monocytic leukaemia	20–25
M6	erythroleukaemia (Di Guglielmo's disease)	5
M7	megakaryoblastic leukaemia	1–2
<b>ALL</b>		
L1	small; uniform (pre-B cell, T cell)	75
L2	large; nonuniform (pre-B cell, T cell)	20
L3	large; uniform; vacuola (B cell, Burkitt's)	5

1 Spilberg I, Meyer GJ. The arthritis of leukemia. *Arthritis Rheum* 1972;15:630–5.

### Summary points

- leukaemia must be remembered in the differential diagnosis of arthritis of unknown aetiology which is resistant to palliative therapy
- cytologic examination of synovial fluid and bone marrow examination can confirm the diagnosis in such patients

reported that LA occurs in 12% of cases of childhood leukaemia,<sup>5</sup> but leukaemia presenting with arthritis in an adult patient has been reported only in occasional case reports.<sup>6</sup>

Arthritis can occur at any time during the course of leukaemia and may rarely be the initial manifestation of the disease.<sup>7</sup> Proposed pathogenic mechanisms for arthritis in leukaemia include infiltration of leukaemic cells into synovial tissue, haemorrhage into the joint from thrombocytopenia, synovial reaction to periosteal or capsular infiltration, and immune-complex-induced synovitis. However, synovial infiltration appears to be the predominant mechanism.<sup>7–8</sup> In acute leukaemias, arthritis usually presents early in the course of disease, whereas in chronic leukaemias it presents later and more symmetrically. Large joints, most commonly the knees, are usually affected, although involvement of the ankle, wrist, elbow, shoulder, and hip have been described.<sup>7–9</sup>

Involved joints are usually warm, swollen, and tender on palpation. Effusions, if present, are small; most swelling is due to synovial hypertrophy. Fever may accompany joint swelling.<sup>7–9</sup> The diagnosis of LA may be difficult as it can mimic other rheumatic diseases, especially juvenile arthritis.<sup>10</sup> In some cases of LA, the peripheral blood smear and complete blood count show nonspecific findings such as anaemia or mild leukocytosis, and bone marrow aspirate or biopsy is necessary to make the diagnosis. One method of diagnosing LA is direct pathological demonstration of synovial membrane infiltration by leukaemic cells. Leukaemic blasts may be present in specimens of synovial fluid, as in our patient.

In conclusion, arthritis is a well recognised complication of leukaemia in children, but acute and chronic leukaemia may also cause arthritis in adults. LA may present before, after, or at the same time as the underlying disease. Because the leukaemia may not be obvious, another cause of the arthritis may be considered. As early diagnosis is one of the most important prognostic factors in leukaemia, this possibility must be remembered in the differential diagnosis of arthritis of unknown aetiology which is also resistant to palliative therapies. In such patients, cytologic examination of synovial fluid and bone marrow examination can be important diagnostic procedures.

2 Thomas LB, Forkner CE, Frei E. The skeletal lesions of acute leukemia. *Cancer* 1961;14:608–21.

- 3 Luzar MJ, Sharma HM. Leukemia and arthritis: including reports on light, immunofluorescent and electron microscopy of the synovium. *J Rheumatol* 1983;10:132-5.
- 4 Appelbaum FR. The acute leukemias. In: Wyngaarden JB, Smith LH, Bennett JC, eds, *Cecil Textbook of Medicine*, vol 1, 19th edn. WB Saunders Company, 1992; pp 944-9.
- 5 Fink CW. Arthritis as the presenting feature of childhood leukemia. *Arthritis Rheum* 1972;15:347-9.
- 6 Hindmarsh JR, Emslie-Smith D. Monocytic leukemia presenting as polyarthritis in an adult. *BMJ* 1953;1:593-4.
- 7 Silverstein MN, Kelly P. Leukemia with osteoarticular symptoms and signs. *Ann Intern Med* 1963;59:637-45.
- 8 Taillan B, Leyge JF. Knee arthritis revealing acute leukemia in a patient with rheumatoid arthritis. *Clin Rheumatol* 1991; 10:76-7.
- 9 Weinberger A, Schumacher R, Schimmer B. Arthritis in acute leukemia. *Arch Intern Med* 1981;141:1183-7.
- 10 Anon. Childhood leukemia mimicking arthritis. *J Am Board Fam Pract* 1996;9:56-60.

## Calcium phosphate stones during long-term acetazolamide treatment for epilepsy

K E Paisley, C R V Tomson

### Summary

**We report a case of recurrent renal calculi containing calcium phosphate associated with long-term acetazolamide treatment for epilepsy. Unfortunately, the cause of stone formation was not recognised for many years, by which time irreversible renal damage had occurred.**

**Keywords:** calcium phosphate renal calculi; renal failure; acetazolamide; adverse drug reaction

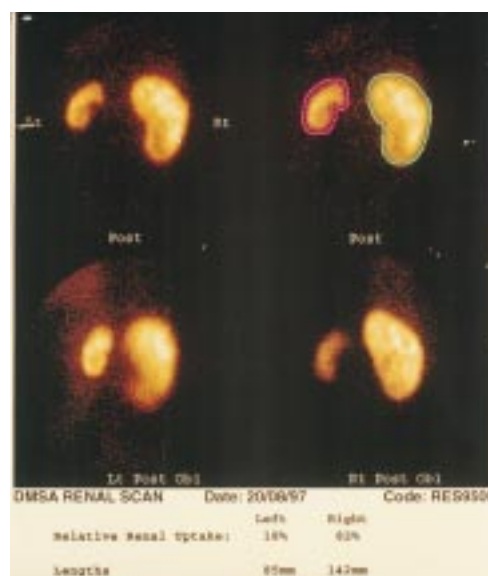
Patients with recurrent renal calculi may experience serious morbidity. It is important that such patients are adequately assessed in an attempt to identify an underlying cause. This is especially important if preliminary investigations produce unusual results.

Stones composed predominantly of calcium phosphate are uncommon; they accounted for 9.3% of 41 000 stones of renal origin in 11 series from five countries.<sup>1</sup> The majority of patients who form calcium phosphate stones have renal tubular acidosis.<sup>2</sup>

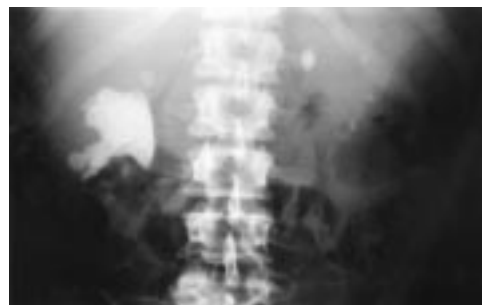We report a patient with recurrent calcium-phosphate-containing renal calculi in whom the cause of stone formation was not recognised for a considerable time, despite regular specialist urological review.

### Case report

A 32-year-old man was admitted for percutaneous nephrolithotomy (PCNL). He had required four previous PCNLs and numerous extracorporeal shock wave lithotripsy treatments and ureteroscopies since first passing a stone 11 years previously. Stone analysis performed seven years previously had shown calcium phosphate, but this had not been investigated further. The kidneys, initially anatomically normal, were now both scarred, with a small, poorly functioning left kidney (figure 1) and recurrent staghorn on the right (figure 2). Serum creatinine had been abnormal on occasions, probably reflecting episodes of partial obstruction.



**Figure 1** DMSA scan showing markedly reduced uptake and scarring on the left



**Figure 2** Plain abdominal radiograph showing large staghorn calculus on the right

He had been treated for epilepsy since the age of 11, initially with conventional anticonvulsants and then with the addition of acetazolamide for recurrent seizures. Current medication was acetazolamide 500 mg bid and carbamazepine 600 mg mane, 400 mg nocte.

**Richard Bright Renal Unit, Southmead Hospital, Bristol BS10 5NB, UK**  
K E Paisley  
C R V Tomson

Correspondence to  
Dr CRV Tomson

Accepted 4 January 1999