

Posterior deviation of left ventricular outflow tract septal components without ventricular septal defect

Süheyla Özkutlu, N Kürşat Tokel, Muhsin Saraçlar, Dursun Alehan, Yurdakul Yurdakul, Şevket Ruacan

Abstract

Objective—To describe 11 patients with narrowing of the left ventricular outflow tract caused by angular posterior deviation of both the outlet septum and the upper part of trabecular septum, which was diagnosed by cross sectional echocardiography in all and confirmed by angiocardiology in seven.

Results—Four patients had a subaortic systolic pressure gradient ranging from 23 to 70 mm Hg by Doppler echocardiography; cardiac catheterisation showed a significant (60 and 104 mm Hg) systolic pressure gradient in two. In four cases aortic regurgitation and two tricuspid pouches were shown by Doppler echocardiography, angiocardiology, or both. Four cases had a ridge at the angulation point on echocardiographic examination. Three patients were operated on for systolic pressure gradients of the left ventricular outflow tract and one for severe aortic regurgitation. There was proliferation of collagen-rich fibrous tissue in the subendocardial region on histopathological examination of the myectomy material. A ventricular septal defect had been diagnosed previously by contrast echocardiography in one patient; thus ventricular septal defects may close spontaneously over a period of time including fetal life. A subaortic ridge was detected in one patient at follow up.

Conclusions—Deviation of the outlet and trabecular septa should be considered as a cause of ventricular outflow tract obstruction even when no ventricular septal defect is present.

(Heart 1997;77:242-246)

Keywords: interventricular septum; subaortic stenosis; aortic regurgitation

Left ventricular outflow tract obstruction is generally caused by subvalvar membranous or fibromuscular stenosis (fixed subvalvar stenosis), hypertrophic cardiomyopathy, and, rarely, cardiac tumours.¹ In some cases with ventricular septal defect, associated fibrous obstruction or septal malalignment may lead to left ventricular outflow tract obstruction, and the obstruction may be more apparent following surgical closure of the ventricular septal defect.²⁻⁵ However, we have encountered some patients with angular narrowing of the left ventricular outflow tract caused by posterior deviation of both outlet and upper part of trabecular ventricular septa without ventricular septal defect.⁶ We therefore investigated these cases further.

Methods

Eleven patients who had angular posterior deviation of both outlet and upper trabecular ventricular septa, without ventricular septal defect, were examined between March 1992 and January 1996. Seven had isolated posterior deviation of outlet and trabecular septum, but two had pulmonary valvular stenosis, and two coarctation of the aorta in addition (tables 1 and 2).

Cross sectional and Doppler echocardiographic examination was performed using Toshiba SSH 60 A and Toshiba Sonolayer 160 A equipment with 2.5, 3.75, and 5.0 MHz transducers. The standard parasternal long axis, subcostal long and short axes, apical two- and four-chamber views, and suprasternal views were used for echocardiographic recordings.

The systolic pressure gradient of the left ventricular outflow tract was measured in all the patients. The severity of the left ventricular outflow tract obstruction was assessed echocardiographically by using the ratio of the diameters of the left ventricular outflow tract

Cardiology Unit,
Department of
Paediatrics, Hacettepe
University Faculty of
Medicine, Ankara,
Turkey

S Özkutlu
N K Tokel
M Saraçlar
D Alehan

Department of
Thoracic and
Cardiovascular
Surgery, Hacettepe
University Faculty of
Medicine, Ankara,
Turkey
Y Yurdakul

Department of
Pathology, Hacettepe
University Faculty of
Medicine, Ankara,
Turkey
Ş Ruacan

Correspondence to:
Dr Süheyla Özkutlu,
Department of Paediatric
Cardiology, Hacettepe
University Faculty of
Medicine, 06100
Sıhhiye/Ankara, Turkey.

Accepted for publication
11 November 1996

Table 1 Echocardiographic data of the patients with septal deviation

Case No	1	2	3	4	5	6	7	8	9	10	11
Aortic systolic gradient (mm Hg)	70	< 10	30	< 10	< 10	10	58	< 10	10	23	< 10
Aortic regurgitation	+	-	-	+	-	-	+	-	+	-	-
Formation of ridge	-	-	+	-	-	+	-	-	-	-	-
Width of IVS/BSA	N	N	I	N	N	I	I	N	N	N	N
Tricuspid pouch	-	-	-	-	-	+	-	-	-	-	-
Flutter of aortic valve	-	-	+	+	-	-	+	-	+	-	+
Additional anomalies	-	-	CoA	-	PS	PS	CoA	-	-	-	-
					AVP						

AVP, aortic valve prolapsus; BSA, body surface area; CoA, coarctation of aorta; I, increased; IVS, interventricular septum; PS, pulmonary stenosis.

Table 2 Catheterisation data of the patients with septal deviation

Case No	1	2*	3	4	5	6	7	8*	9	10*	11*
LV (mm Hg)	180			110	130	110	220		125		
Aorta (mm Hg)	120/64		90/70	110/63	130/88	100/60	116/63		125/63		
Aortic gradient (mm Hg)	60		?	0	0	10	104		0		
Aortic regurgitation	II°		No	III°	No	No	II°		II°		
Additional anomalies	No		CoA	No	PS	PS	CoA		No		
Tricuspid pouch	No		No	No	+	+	No		No		

*Catheterisation was not performed; AVP, aortic valve prolapse; CoA, coarctation of aorta; PS, pulmonary stenosis; LV, left ventricle.

and the ascending aorta (LVOT/AAo). Measurements of the diameters of the left ventricular outflow tract proximal to the aortic valve and of the ascending aorta distal to the aortic cusps were made from parasternal

echocardiographic long axis views during systole.⁷

Cardiac catheterisation was performed in seven patients (table 2). After obtaining haemodynamic and oxygen saturation data, angiograms were made in long axis (60° left anterior oblique view combined with 30° cranio-caudal angulation) and in the four-chamber views (45° left anterior oblique view combined with 30° cranio-caudal angulation).

Figure 1 Standard and modified parasternal long axis views. Echocardiograms during systole (above), diastole (middle), and schematic illustration of middle (below). Figure indicates posterior deviation of both outlet (dotted) and trabecular septa and trabecular septal crest (lower arrow). LV, left ventricle; RV, right ventricle; LA, left atrium; Ao, aorta; IVS, interventricular septum.

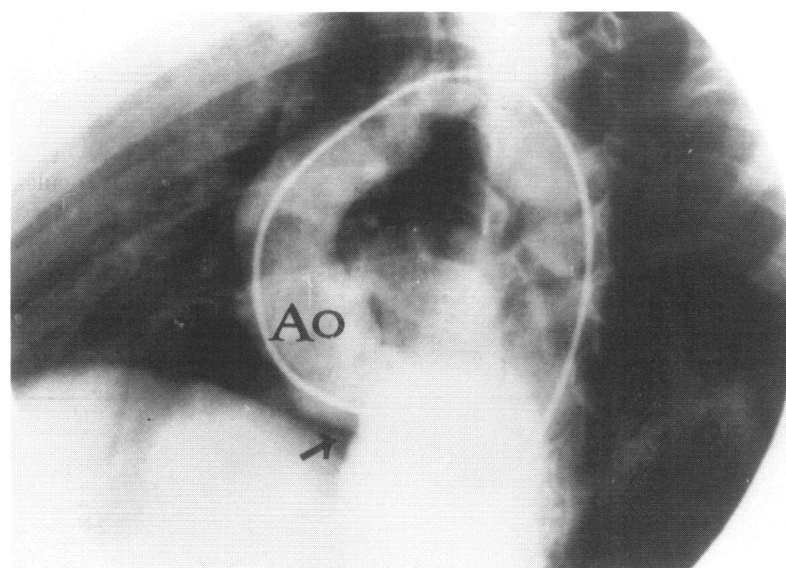
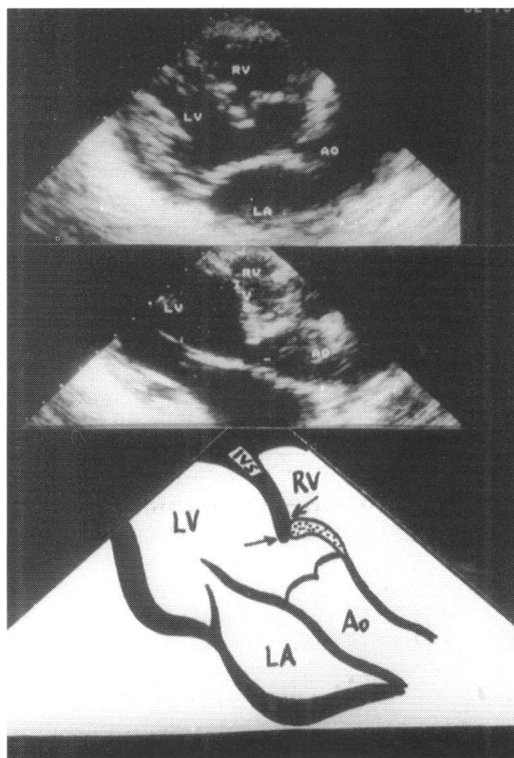


Figure 2 Left ventricular angiogram in the long axis view. Arrow indicates the angulation between outlet and trabecular septa. The portion between the arrow and aortic valve is the outlet septum. Ao, aorta.

Results

The age range of the patients was between 3 and 19 years (median 8 years) at the time septal deviation was diagnosed. Although four patients (cases 2, 5, 9, and 11) had no symptoms, chest pain and palpitation were the most common symptoms in the others. There were no murmurs in one patient (case 2) and electrocardiography was normal in seven. Four patients had left ventricular hypertrophy (cases 3, 7, 8, and 10) and one had strain pattern (case 3). Cardiomegaly was found in three patients on x ray examination (cases 4, 5, and 10).

On echocardiographic examination both outlet and upper trabecular septa were posteriorly deviated, and the outlet septum joined the trabecular septum on the right ventricular side of the septum in this entity. In most of the patients, the outlet septum did not join the trabecular septum at its crest, but inserted more apically on the right ventricular side (fig 1; cases 1, 3, 4, 5, 7, 9, and 11). This posterior deviation of outlet and upper trabecular septum creates an angle and the left ventricular outflow tract may be obstructed (figs 1, 2, and 3). This situation is best evaluated by echocardiography in parasternal (including modified parasternal) and subcostal long axis views (figs 1 and 3). The thickness of the interventricular septum in relation to body surface area was normal in eight patients, but abnormal in three (table 1). Four patients had systolic gradients ranging from 23 to 70 mm Hg, but the others did not have subaortic systolic pressure gradients. Four cases also had a subaortic ridge at the point of angulation. Other echocardiographic findings in the cases are shown in table 1.

Cardiac catheterisation showed significant (60 and 104 mm Hg) subaortic systolic pressure gradients in two patients (cases 1 and 7) as detected by Doppler echocardiography. In case 3, it was not possible to measure the left ventricular outflow tract gradient by catheter since the patients also had severe coarctation and the catheter did not pass through. Four

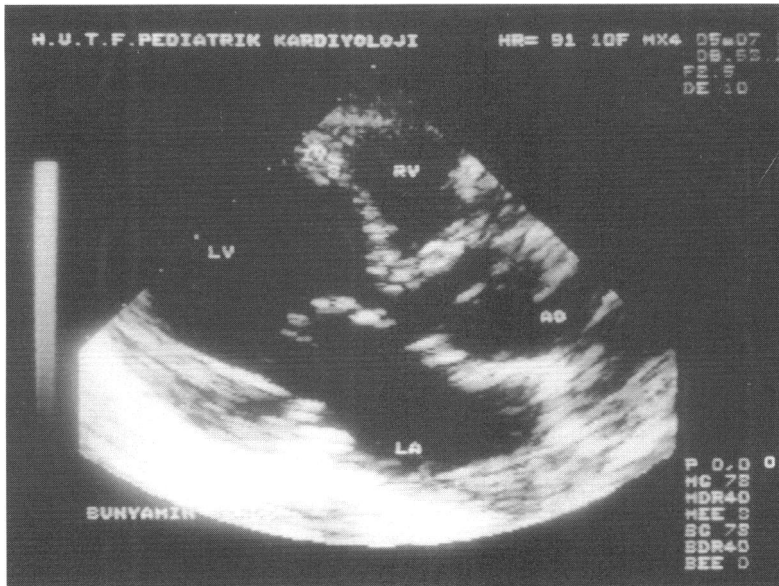

Figure 3 Parasternal long axis view of another case. Angular posterior deviation of both outlet and upper trabecular septa is clearly seen. LV, left ventricle; LA, left atrium; RV, right ventricle; Ao, aorta.

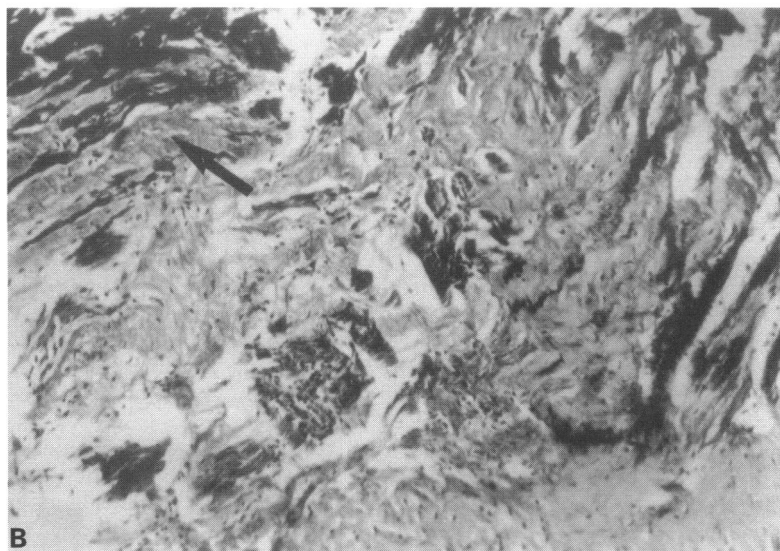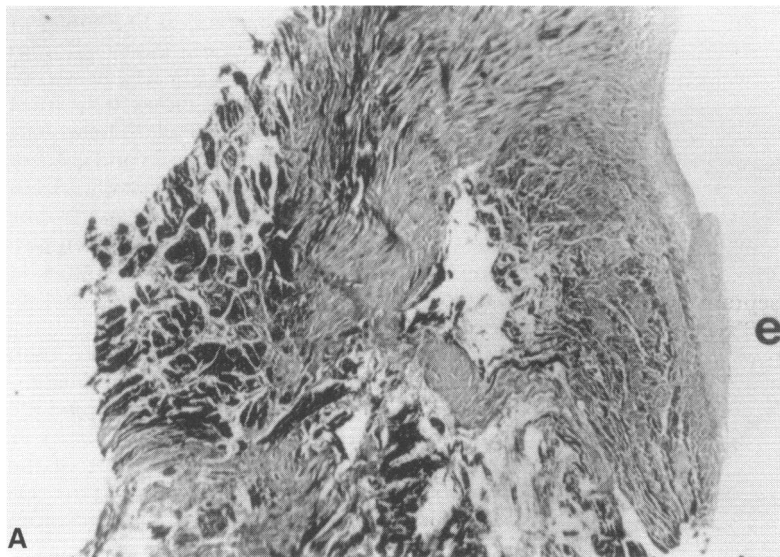


Figure 4 (A) Section of the biopsy specimen. Slightly thickened epicardium (e) and markedly distorted myocardial tissue replaced by irregular bands of fibrosis are observed (Masson's trichrome stain, $\times 109$). (B) Higher magnification shows scattered myocardial fibers (arrow) trapped in collagenous fibrous tissue (Masson's trichrome, $\times 435$).

patients had aortic regurgitation (cases 1, 4, 7, and 9) and two (cases 5 and 6) had a pouch of an accessory tricuspid valve (table 2).

Four of the patients (cases 1, 3, 4, and 7) were operated on.

In 1989, a subaortic ridge resection was done in case 1 because of a 60 mm Hg systolic gradient at the left ventricular outflow tract. Previously undetected posterior deviation of the outlet and trabecular septa was diagnosed by echocardiography postoperatively in March 1992. Left ventricular outflow tract pressure gradients of 70 and 60 mm Hg were obtained by Doppler echocardiography and cardiac catheterisation, respectively. Myectomy was performed at reoperation. Unfortunately after reoperation, obstruction of the left ventricular outflow increased gradually and again reached 70 mm Hg by Doppler echocardiography.

A successful myectomy and resection of coarctation were carried out in case 3. Doppler echocardiography did not show any left ventricular outflow tract obstruction.

Myectomy and coarctation resection were done in case 7. We detected a 60 mm Hg systolic pressure gradient in the left ventricular outflow tract by Doppler echocardiography nine months later.

A patient without systolic pressure gradient by Doppler echocardiography and cardiac catheterisation (case 4) was operated on because of severe aortic regurgitation (tables 1 and 2).

The remaining patients (cases 2, 5, 6, 8, 10, and 11) have been closely followed up. Echocardiographic development of a subaortic ridge without a pressure gradient in case 5 and a 15 mm Hg systolic pressure gradient at the left ventricular outflow tract in case 8 have been found during a three year follow up.

Microscopic examination of the tissue removed revealed slightly thickened and fibrotic endocardium (cases 4 and 7). There was proliferation of collagen-rich fibrous tissue in the subendocardial region, with scattered myocardial fibres remaining trapped within this irregular fibrous mass (fig 4).

Figure 5 shows the relation between LVOT/Ao ratio measured by echocardiography and the subaortic pressure gradient

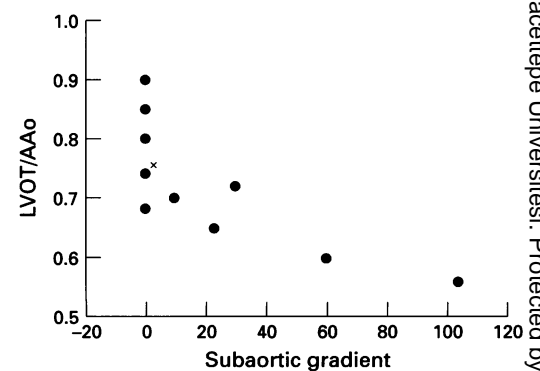


Figure 5 Relation between LVOT/Ao ratio and subaortic pressure gradient measured by catheterisation and/or Doppler echocardiography. LVOT, left ventricular outflow tract; Ao, ascending aorta. x, two patients have the same results.

assessed by echocardiographic and haemodynamic studies.

A ventricular septal defect had been diagnosed previously by physical examination and contrast echocardiography in one patient (case 6). We could not show a ventricular septal defect by angiocardiology three years after the contrast echocardiographic study. Two patients in whom no left to right shunt could be demonstrated haemodynamically and angiocardialographically (cases 5 and 6) had a pouch of an accessory tricuspid valve. One of these pouches was also demonstrated by echocardiography (case 6).

Discussion

A ventricular septal defect which appears to be caused by an abnormal displacement (deviation) of the outlet septum is called a ventricular septal defect of malalignment type. If the deviation is posterior, the left ventricular outflow tract may be narrowed. However, in the 11 cases presented by us and the four reported by Gewillig *et al*, a ventricular septal defect was absent.⁶ In the cases of Gewillig *et al* there was posterior malalignment between the membranous and muscular septum. According to their descriptions the membranous septum did not join the muscular septum at its crest, but inserted 15 to 26 mm more apically on the right ventricular side of the septum. However, in our patients there was an angular deviation of both the outlet and upper part of the trabecular septa. In fact, from the standpoint of posterior deviation of outlet septum our cases are more similar to the patient illustrated in figure 3 of the paper by Kitchiner *et al*.⁴ The outlet septum did not join the trabecular septum at its crest, but inserted more apically on the right ventricular side in most of our patients, as seen in fig 1. In some other cases we could not show the trabecular crest.

In the cases with abnormal alignment of ventricular septal fragments, the term "malalignment" is generally used. However, some choose the term "deviation" to describe the morphology. Kitchiner states that this term would allow a more precise description of the structures involved and is less contentious.⁴ Therefore instead of "malalignment" we preferred "deviation".

In the differential diagnosis, we excluded cases showing anterior deviation of the outlet septum, which creates overriding of the aorta, and those with an interventricular septal prominence towards the left ventricular outflow tract caused by aberrant bands.

According to general concepts agreed on so far, malalignment or deviation of interventricular septum is encountered in patients with ventricular septal defect. Contrary to this belief, our cases did not have ventricular septal defects, so we assume that ventricular septal defects may close spontaneously over a period of time, which includes fetal life.^{8,9} In fact, in two of our patients (cases 5 and 6), a tricuspid pouch was shown by echocardiography or angiocardiology, suggesting spontaneous closure. Furthermore in our sixth patient, a

ventricular septal defect had been documented by contrast echocardiographic examination a few years before we planned the present study. Another possibility may be that deviation develops directly by fusion of different fragments of the interventricular septum without producing a ventricular septal defect.

Posterior deviation of the outlet septum narrows the outflow tract of the left ventricle to some extent in patients with a ventricular septal defect. This may lead to an outflow systolic pressure gradient. However, the gradient may not be significant because of the left to right shunt through the ventricular septal defect when it is located beneath the outlet septum.¹⁰ Kitchiner *et al* reported that deviation of the outlet septum would create subaortic stenosis above the site of a surgically closed ventricular septal defect.⁴ Therefore during surgical intervention posterior deviation and related obstruction of the left ventricular outflow tract should be considered, and a proper outflow resection performed.^{4,5} Similar considerations should be applied to those patients without ventricular septal defect but with posterior deviation of outlet and trabecular septa causing significant left ventricular outflow tract obstruction.

We consider that this condition of posterior deviation of the ventricular septum is not very rare and is usually unnoticed. In fact figure 1 in the paper by Frommelt *et al* a good example of a sharply angulated interventricular septum and a ridge originating from the point of angulation is clearly seen, although only the subaortic fibrous ridge was mentioned in the text.¹¹ In addition, in one of our cases (case 1) and one of Gewillig's the deviation was not noticed previously.

Iwahara *et al* reported that ventricular outflow tract obstruction is critical when the LVOT/AAo diameter ratio is 0.6 or less.⁷ In two of our cases this ratio was 0.6 or less and their gradients were higher than in the others (cases 1 and 7) (fig 5). On the other hand, removal of the septal deviation may be impracticable due to the close relation to the conduction system.

In four of our patients, a fibrous ridge was seen at the junction of the outlet and trabecular septa. We could not correlate the presence of a ridge and a systolic pressure gradient (table 1). Gewillig *et al* speculated that the occurrence of this lesion results from a specific anatomical substrate giving rise to abnormal flow dynamics.^{6,12} This results in an excessive growth of fibrous tissue. Fibrous ridges have been associated with the presence of a longer outflow tract with increased aortic-mitral separation, a small outflow tract, malalignment type ventricular septal defect, the presence of a more apical septal fibrous ridge or apical muscular band, and doubly committed subarterial ventricular septal defect.^{4,6,12,13} In one of our patients a fibrous ridge developed during follow up (case 5). This finding supports the findings of Kitchiner *et al* and Zielinsky *et al*.^{4,5}

In two of our cases we found fibrotic changes in the myocardium at the region of deviation in histopathological examination of

myectomy material. These findings were different from the changes in hypertrophic cardiomyopathy (fig 4).

Four of our patients had aortic insufficiency. This anomaly disturbs blood flow and frequently causes turbulence in the left ventricular outflow tract. Due to turbulence and increased flow rate, aortic regurgitation develops.¹⁴⁻¹⁸ Vries *et al* found an increase in the incidence of aortic regurgitation during a follow up study in 57 patients with subaortic stenosis.¹⁴ The incidence of aortic regurgitation in subaortic stenosis was 32% in the initial examination, but it increased to 54% at the end of four years follow up. Aortic regurgitation was related to subaortic pressure gradient in their study. However, we did not find any relation between the degree of aortic regurgitation and the subaortic pressure gradient. We believe that the progressive damage to the aortic valve is caused by the high velocity jet in the left ventricular outflow tract.

In conclusion, deviation of the outlet and trabecular septa should be considered as a cause of ventricular outflow tract obstruction even when no ventricular septal defect is present.

- 1 Bristow JD. Recognition of the left ventricular outflow tract obstruction. *Circulation* 1973;31:600-11.
- 2 Shore DF, Smalhorn J, Stark J, Lincoln C, De Leval MR. Left ventricular outflow tract obstruction coexisting with ventricular septal defect. *Br Heart J* 1982;48:421-7.
- 3 Vogel M, Freedom RM, Brand A, Trusler GA, Williams GW, Rowe RD. Ventricular septal defect and subaortic stenosis: analysis of 41 patients. *Am J Cardiol* 1983; 52:1258-63.
- 4 Kitchiner D, Jackson M, Malaiya N, Walsh K, Peart I, Arnold R, *et al*. Morphology of left ventricular outflow tract structures in patients with subaortic stenosis and a ventricular septal defect. *Br Heart J* 1994;72:251-60.
- 5 Zielinsky P, Rossi M, Haertel JC, Vitola D, Lucchese FA, Rodrigues R. Subaortic fibrous ridge and ventricular septal defect: role of septal "malalignment". *Circulation* 1987;75:1124-9.
- 6 Gewillig M, Daenen W, Dumoulin M, Hauwaert LVD. Rheologic genesis of discrete subvalvular aortic stenosis: a Doppler echocardiographic study. *J Am Coll Cardiol* 1992;19:818-24.
- 7 Iwahara M, Ino T, Nishimoto K, Park I, Akimato K, Shimozaki S, *et al*. Clinical features of aortic arch anomaly with "malalignment" ventricular septal defect. *Ann Thorac Surg* 1989;48:693-6.
- 8 Nir A, Driscoll DJ, Edwards WD. Intrauterine closure of membranous ventricular septal defects: mechanism of closure in two autopsy specimens. *Pediatr Cardiol* 1994; 15:33-7.
- 9 Hiraishi S, Agata Y, Nowatari M, Oguchi K, Misawa H, Hirota H, *et al*. Incidence and natural course of trabecular ventricular septal defect: two-dimensional echocardiography and color Doppler flow imaging study. *J Pediatr* 1992;120:409-15.
- 10 Vogel M, Smallhorn JF, Freedom RM, Coles J, Williams GW, Trusler GA. An echocardiographic study of the association of ventricular septal defect and right ventricular muscle bundles with a fixed subaortic abnormality. *Am J Cardiol* 1988;61:857-60.
- 11 Frommelt MA, Snider AR, Bove FEL, Lupinetti FM. Echocardiographic assessment of subvalvular aortic stenosis before and after operation. *J Am Coll Cardiol* 1992;19:1018-23.
- 12 Mertens L, Gewillig M. The formation of a discrete subvalvular outflow tract obstruction—at the interface between rheology and morphology. *Eur Heart J* 1996; 17:809-10.
- 13 Özkutlu S, Saraçlar M, Alehan D, Yurdakul Y, Fırat P, Tokel K. Subpulmonary and subaortic ridges in doubly committed subarterial ventricular defect: an echocardiographic study. *Eur Heart J* 1996;17:935-9.
- 14 Vries AG, Hess J, Witsenburg M, Frohn-Muldep IME, Bogers ADJJC, Boss E. Management of fixed subaortic stenosis: a retrospective study of 57 cases. *J Am Coll Cardiol* 1992;19:1013-7.
- 15 Champspour G, Trusler GA, Mustard WT. Congenital discrete subvalvular aortic stenosis: surgical experience and long term follow-up. *Br Heart J* 1973;35:343-7.
- 16 Douville EC, Sade RM, Crawford FA, Wiles HB. Subvalvular aortic stenosis: timing of operation. *Ann Thorac Surg* 1990;50:29-34.
- 17 Jaumin P, Rubay J, Lintersmans J, Arena V, Matto A, Goenen M, *et al*. Surgical treatment of subvalvular aortic stenosis. Long term results. *J Cardiovasc Surg* 1990; 31:31-5.
- 18 Kitchiner D, Jackson M, Malaiya N, Walsh K, Peart I, Arnold R. Incidence and prognosis of obstruction of the left ventricular outflow tract in Liverpool (1960-1991). *Br Heart J* 1994;71:588-95.