

A molecular and clinical study of Larsen syndrome caused by mutations in *FLNB*

Louise S Bicknell, Claire Farrington-Rock, Yousef Shafeghati, Patrick Rump, Yasemin Alanay, Yves Alembik, Navid Al-Madani, Helen Firth, Mohammad Hassan Karimi-Nejad, Chong Ae Kim, Kathryn Leask, Melissa Maisenbacher, Ellen Moran, John G Pappas, Paolo Prontera, Thomy de Ravel, Jean-Pierre Fryns, Elizabeth Sweeney, Alan Fryer, Sheila Unger, L C Wilson, Ralph S Lachman, David L Rimoin, Daniel H Cohn, Deborah Krakow, Stephen P Robertson

J Med Genet 2007;44:89–98. doi: 10.1136/jmg.2006.043687

See end of article for authors' affiliations

Correspondence to: S P Robertson, Department of Paediatrics and Child Health, Dunedin School of Medicine, PO Box 913, Dunedin, New Zealand; stephen.robertson@stonebow.otago.ac.nz

Received 4 May 2006
Revised 25 May 2006
Accepted 29 May 2006
Published Online First
26 June 2006

Background: Larsen syndrome is an autosomal dominant osteochondrodysplasia characterised by large-joint dislocations and craniofacial anomalies. Recently, Larsen syndrome was shown to be caused by missense mutations or small inframe deletions in *FLNB*, encoding the cytoskeletal protein filamin B. To further delineate the molecular causes of Larsen syndrome, 20 probands with Larsen syndrome together with their affected relatives were evaluated for mutations in *FLNB* and their phenotypes studied.

Methods: Probands were screened for mutations in *FLNB* using a combination of denaturing high-performance liquid chromatography, direct sequencing and restriction endonuclease digestion. Clinical and radiographical features of the patients were evaluated.

Results and discussion: The clinical signs most frequently associated with a *FLNB* mutation are the presence of supernumerary carpal and tarsal bones and short, broad, spatulate distal phalanges, particularly of the thumb. All individuals with Larsen syndrome-associated *FLNB* mutations are heterozygous for either missense or small inframe deletions. Three mutations are recurrent, with one mutation, 5071G→A, observed in 6 of 20 subjects. The distribution of mutations within the *FLNB* gene is non-random, with clusters of mutations leading to substitutions in the actin-binding domain and filamin repeats 13–17 being the most common cause of Larsen syndrome. These findings collectively define autosomal dominant Larsen syndrome and demonstrate clustering of causative mutations in *FLNB*.

Larsen syndrome (Online Mendelian Inheritance in Man (OMIM) 150250) was first described as an entity comprising congenital large-joint dislocations and characteristic craniofacial abnormalities.¹ The cardinal features of the condition are dislocations of the hip, knee and elbow joints, with equinovarus or equinovagus foot deformities. Spatula-shaped fingers, most marked in the thumb, are also present. Craniofacial anomalies include hypertelorism, prominence of the forehead, a depressed nasal bridge and a flattened midface.^{1–4} Cleft palate and short stature are often associated characteristics.^{1, 3, 5, 6} Spinal anomalies include scoliosis and cervical kyphosis; cervical kyphosis can be associated with a myelopathy.^{6, 7} Hearing loss is a well-recognised complication^{8–10} often caused by malformations of the auditory ossicles.^{11, 12} Supernumerary carpal and tarsal bones (representing secondary ossification centres—for example, in the calcaneus)^{2, 13} are a useful diagnostic feature in early childhood. Intrafamilial variation in Larsen syndrome is a prominent feature of the disorder.^{14, 15}

There is clear evidence for an autosomal dominant form of Larsen syndrome, with multiple instances of male-to-male transmission being described^{2, 11, 16, 17} in addition to linkage data that defines a locus at 3p21.1–14.1.¹⁷ Instances of sibling recurrence to unaffected parents have been retrospectively explained by parental germline mosaicism on subsequent observation of vertical transmission of the phenotype.^{18–20} Other instances of sibling recurrence to unaffected parents may reflect the same underlying mechanism.¹³ Presentations consistent with somatic mosaicism have also been reported.^{9, 21}

Other conditions labelled as Larsen syndrome or Larsen-like entities have been described (OMIM 245650), many with a

more severe phenotype including additional extraskeletal features. Associated malformations include cardiac defects,^{22–28} laryngotracheomalacia,^{29–34} brain abnormalities (microcephaly, pachygyria, colpocephaly, corpus callosum agenesis)^{29, 30, 33–35} and inguinal herniae.^{25, 26, 29} Some of these phenotypes segregated in a fashion consistent with autosomal recessive inheritance, prompting some to recognise a recessive form of Larsen syndrome despite many cases having major phenotypic dissimilarities with the entity Larsen *et al*¹ initially described. Many have noted more severe skeletal and extraskeletal phenotypic features including perinatal lethality in presumptive recessively inherited cases, implying that it is possible to clinically distinguish these heterogeneous entities from autosomal dominant Larsen syndrome.^{26, 36} However, clear criteria that definitively delineate recessively inherited forms of Larsen syndrome from the dominantly inherited entity have not been established.^{13, 31}

Laville *et al*³⁶ and Bonaventure *et al*³⁷ described several large families, from La Réunion Island, which segregated a phenotype resembling Larsen syndrome, but with severe short stature, advanced skeletal maturation, diaphyseal bowing and lethality in childhood. Recurrence of the phenotype to unaffected parents in an isolated population firmly implicates an autosomal recessive mode of inheritance. Other similar cases have since been reported.²⁸ This clinical presentation has more similarities to Desbuquois dysplasia than to Larsen syndrome.³⁷

Abbreviations: *FLNA*, filamin A gene; *FLNB*, filamin B gene; MCP, metacarpophalangeal pattern; OMIM, on-line mendelian inheritance in man; OPD, otopalatodigital syndrome

Clinical similarities between Larsen syndrome and a group of lethal osteochondrodysplasias including atelosteogenesis types I (AOI, OMIM 108720) and III (AOIII, OMIM 108721), and boomerang dysplasia (OMIM 112310) suggested that they represent an allelic series of conditions.^{38–39} These more severe dysplasias are characterised by underossification of skeletal elements, hypoplastic or absent limb bones, joint dislocations and craniofacial abnormalities. These observations, with the phenotypic similarities between Larsen syndrome and otopaladigital syndrome type 1 (OPD1), an X-linked skeletal disorder caused by mutations in *FLNA*,⁴⁰ the gene encoding filamin A, led to the description of mutations in the paralogous gene filamin B gene (*FLNB*) underlying Larsen syndrome, AOI, AOIII and boomerang dysplasia.^{41–42} Mutations leading to AOI and AOIII were clustered in calponin homology domain 2 (CH2) and repeats 13–17.⁴³

Filamin B is a cytoskeletal protein that is important in modulation of the cellular cytoskeleton and signal transduction. It is composed of two calponin homology domains at the N-terminal forming an actin-binding domain, and 24 structurally homologous repeats, separated by two hinge regions located between repeats 15 and 16, and 23 and 24. Four missense mutations and one inframe deletion were identified associated with Larsen syndrome and localised to portions of the gene encoding the actin-binding domain and repeats 14 and 15. Mutations leading to AOI and AOIII were also clustered in *FLNB*, in contrast with nonsense and frameshift mutations leading to spondylocarpotarsal syndrome, which were more randomly located throughout the gene.⁴²

In vivo, filamins form dimers, with repeat 24 acting as a dimerisation domain. The hinge regions confer flexibility on the filamin dimer structure, enabling orthogonal actin cross-linking. Several proteins bind to the C-terminal portion of filamin B. The physiological relevance of filamin binding to many of these interacting proteins, including integrin β 1A and β 1D subunits, presenilins 1 and 2, glycoprotein Ib α , filamin-binding LIM protein 1 and epithin, is unclear,^{44–48} but emerging evidence supports a role for filamins in the integration of cell signalling and cytoskeletal remodelling.⁴⁹

In this paper a cohort of 20 unrelated families with Larsen syndrome is reported, comprising 52 affected individuals. We note the clinical features associated with the presence of a *FLNB* mutation and examined for genotype–phenotype correlations for this disorder. Mutations were non-randomly distributed and some were recurrently observed. In addition, a characteristic clinical phenotype for Larsen syndrome associated with mutations in *FLNB* was delineated.

METHODS

Patient ascertainment

Patients or families with a diagnosis of Larsen syndrome were ascertained by doctor-initiated referral. Informed consent was obtained from participants or their legal guardians. Patients and family members were examined by their doctor. Clinical photographs and a full skeletal radiographic survey were obtained where possible. For some patients, full radiographic and clinical details were not obtainable. Ethical approval for this study was obtained from the Otago Ethics Committee.

Molecular analysis

Genomic DNA from cases to be examined was extracted from whole blood using standard procedures. *FLNB* exons and exon–intron boundaries were amplified using polymerase chain reaction as described previously.⁴² Primers and polymerase chain reaction conditions are available on request. Amplified DNA was subject to denaturing high-performance liquid chromatography on a WAVE DNA fragment analysis system

(Transgenomic, Omaha, Nebraska, USA) according to the manufacturer's instructions. Amplicons showing anomalous traces were re-amplified and cycle-sequenced on an ABI 3100 sequencer. Where mutations were shown to have arisen *de novo*, declared relationships were verified by genotyping both parents and the patient at six microsatellite loci. Where parental samples were not available or the trait was familial, the mutation was shown to be absent in 100 control chromosomes.

Metacarpophalangeal pattern profiles

Metacarpophalangeal pattern (MCP) profile analyses were performed as described previously.⁵⁰ Bone lengths of the 19 individual bones of the hand were measured in millimetres, expressed in standard deviation (SD) units (z scores) relative to age-specific and gender-specific mean bone lengths, and corrected for age, gender and height using ANTRO software (V.4.83E).^{50–52} To quantify the altered structure of a hand, a pattern variability index (σ_z) was calculated,⁵³ which describes the variance of z scores of an MCP profile. The mean σ_z of the normal population is approximately 0.5. A σ_z value >0.8 (the 95th centile) is considered to be suggestive of a malformation syndrome.

RESULTS

Clinical presentation

Table 1 shows the clinical descriptions of patients with a *FLNB* mutation. There were 8 male and 12 female probands; 16 isolated cases and 4 familial cases. All probands had dislocations or subluxation of the large joints (65% with elbow, 80% with hip and 80% with knee dislocations). The most mildly affected proband (case 3) manifested subluxable shoulders as her only large-joint symptom. Clubfoot was present in 75%. Anterior thoracic wall deformities (pectus excavatum or pectus carinatum) were present in 55% of patients. Short stature was common (14/20 cases recording height below the 10th centile). Height less than the first centile was rare and some individuals were of above-average stature (case 13 was 179 cm; >97 th centile). The majority of individuals had the characteristic prominent forehead, hypertelorism, midface hypoplasia and depressed nasal bridge (fig 1), although exceptions were observed (case 13; fig 1D). All but one individual with mutations in *FLNB* had spatulate fingers, most specifically in the thumb (fig 2). Conductive deafness, often with noticeable malformation of the ossicular chain, was observed in 4 of 19 (21%) individuals.

Skeletal anomalies

Radiologically, apart from secondary abnormalities attributable to chronic joint dislocation, the metaphyses and diaphyses of the long bones were normal. A minority of patients (eg, case 6), with more pronounced short stature and craniofacial anomalies, exhibited distal humeral hypoplasia and thus exemplify an overlap phenotype between Larsen syndrome and AOIII.⁴³ In this cohort, supernumerary carpal and tarsal ossification centres were universally observed features in individuals for whom relevant radiographs were available (fig 3), although these signs may be absent in some individuals with the allelic condition atelosteogenesis III, suggesting that they may not be completely sensitive indicators for Larsen syndrome. Distal phalangeal abnormalities, most severely and consistently affecting the thumb, were similarly common (fig 3). Spinal abnormalities were observed in 16 of 19 (84%) individuals. Cervical kyphosis was noted in 50% of probands (fig 4), usually on the basis of subluxation or fusion of the C2–C3–C4 vertebral bodies. A common accompaniment was posterior vertebral arch dysraphism, dysplasia of the vertebral laminae and hypoplasia of the lateral processes of all cervical vertebrae. Clinical

Table 1 Phenotypic features of Larsen syndrome due to mutations in *FLNB*

Case/ Family	Proband sex	Mutation	Protein	Protein domain	Diagnosis	Number affected	Familial/ sporadic	Consen- guinity	Stature <10th centile	Congenital joint dislocation							Scoliosis	Anterior thoracic wall deformity	Spitulate fingers	Cervical spinal anomalies			Myelo- pathy	Distal tapering of humerus	Accessory ossification centres	Cardiac defects	Neurode- generational delay				
										Cleft palate	Midface hypoplasia	Cliff palate	Deafness	Elbows	Hips	Knees				Clubfoot	Vertebral fusion	Vertebral dislocation						Posterior arch defects	Vertebral dislocation	Vertebral fusion	Vertebral dislocation
1	M	482T→G	F161C*	CH2	LS	2	f	-	+	-	-	-	-	-	-	-	-	-	-	-	-	-	-	-	-	-	-	-			
2	F	502G→A	G168S	CH2	LS	2	f	-	-	-	-	-	-	-	-	-	-	-	-	-	-	-	-	-	-	-	-	-			
3	F	700C→G	I234V	CH2	LS	1	s	-	-	-	-	-	-	-	-	-	-	-	-	-	-	-	-	-	-	-	-	-			
4	M	679G→A	E227K†	CH2	LS	1	s	-	-	-	-	-	-	-	-	-	-	-	-	-	-	-	-	-	-	-	-	-			
5	M	679G→A	E227K†	CH2	LS	30	f	-	-	-	-	-	-	-	-	-	-	-	-	-	-	-	-	-	-	-	-	-			
6	F	1081G→A	G561S*	Rpt 2	LS:ACIII	1	s	-	+	-	-	-	-	-	-	-	-	-	-	-	-	-	-	-	-	-	-	-			
7	F	1088G→A	G363E	Rpt 2	LS	1	s	-	-	-	-	-	-	-	-	-	-	-	-	-	-	-	-	-	-	-	-	-			
8	M	4292T→G	L1431R*	Rpt 1.3	LS	1	s	-	+	-	-	-	-	-	-	-	-	-	-	-	-	-	-	-	-	-	-	-			
9	F	4713delAA†	L571delN†	Rpt 1.4	LS	1	s	-	+	-	-	-	-	-	-	-	-	-	-	-	-	-	-	-	-	-	-	-			
10	M	4756G→A	G1586R†	Rpt 1.4	LS	1	s	-	+	-	-	-	-	-	-	-	-	-	-	-	-	-	-	-	-	-	-	-			
11	M	4775T→A	V1592D	Rpt 1.4	LS	2	f	-	+	-	-	-	-	-	-	-	-	-	-	-	-	-	-	-	-	-	-	-			
12	M	4808C→T	P1403L	Rpt 1.4	LS	1	s	-	+	-	-	-	-	-	-	-	-	-	-	-	-	-	-	-	-	-	-	-			
13	F	5071G→A	G1691S†	Rpt 1.5	LS	1	s	-	-	-	-	-	-	-	-	-	-	-	-	-	-	-	-	-	-	-	-	-			
14	F	5071G→A	G1691S*	Rpt 1.5	LS	1	s	-	-	-	-	-	-	-	-	-	-	-	-	-	-	-	-	-	-	-	-	-			
15	F	5071G→A	G1691S	Rpt 1.5	LS	1	s	-	+	-	-	-	-	-	-	-	-	-	-	-	-	-	-	-	-	-	-	-			
16	M	5071G→A	G1691S	Rpt 1.5	LS	1	s	-	+	-	-	-	-	-	-	-	-	-	-	-	-	-	-	-	-	-	-	-			
17	F	5071G→A	G1691S	Rpt 1.5	LS	1	s	+	+	-	-	-	-	-	-	-	-	-	-	-	-	-	-	-	-	-	-	-			
18	F	5071G→A	G1691S	Rpt 1.5	LS	1	s	-	+	-	-	-	-	-	-	-	-	-	-	-	-	-	-	-	-	-	-	-			
19	F	5500G→A	G1834R	Rpt 1.7	LS	1	s	-	+	-	-	-	-	-	-	-	-	-	-	-	-	-	-	-	-	-	-	-			
20	F	5500G→A	G1834R	Rpt 1.7	LS	1	s	+	+	-	-	-	-	-	-	-	-	-	-	-	-	-	-	-	-	-	-	-			
Proportion of total patients									70	19/20	1.5	21	65	80	80	80	75	15/20	12/20	11/20	17/18	8/16	3/16	10/16	3/20	3/16	19	15/16	5	1/20	3/20
Percentage									70	95	1.5	21	65	80	80	75	15/20	12/20	11/20	17/18	8/16	3/16	10/16	3/20	3/16	19	94	5	1.5	1.5	

ACIII, atelosteogenesis type III; CH2, cartolin homology domain 2; F, female; LS, Larsen syndrome; M, male; NA, not assessed; Rpt, filament repeat; +, present; -, absent. Phenotypes listed in familial cases are cumulative for all affected members, not solely the proband. *Mutation proved de novo by examination of parental samples. †Mutation previously reported.²²

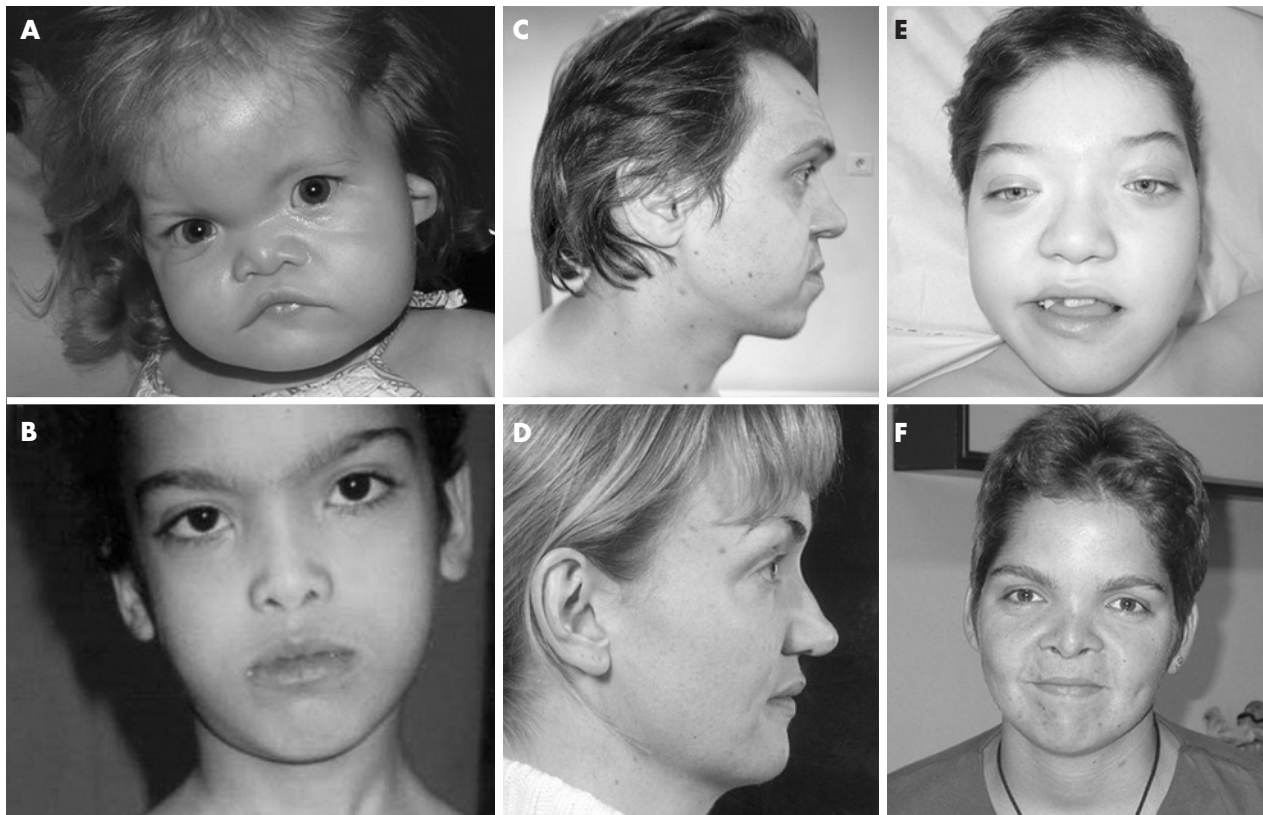

Figure 1 Facial characteristics from patients with filamin B gene mutations and diagnoses of (A) Larsen syndrome/atelosteogenesis III or (B–F) Larsen syndrome. (A) Case 6; (B) case 5; (C) affected father of case 11; (D) case 13; (E) case 11; (F) case 20. Informed consent was obtained for publication of this figure.

myelopathy, complicated by secondary ischaemic encephalopathy, was observed in 3 of 20 individuals (fig 4). Thoracolumbar scoliosis was noted in 60%, but was not attributable to underlying vertebral anomalies on radiographs.

Molecular analysis

Heterozygotic mutations in *FLNB* were found in 20 probands (table 1). Ten had arisen *de novo* and four segregated within families. Most mutations were missense; there was one small inframe deletion, 4711_4713delAAT (1571delN). Three mutations were recurrent, leading to the substitutions E227K (n = 2), G1691S (n = 6) and G1834R (n = 2). ClustalW alignment showed that the predicted amino acid substitutions in Larsen syndrome occurred at sites that are highly conserved in paralogous and orthologous forms of the protein (fig 5).

Mutations were non-randomly distributed throughout the gene. Two clusters of mutations were evident, those in exons 2–4 encoding CH2, and those in exons 25–33 encoding filamin repeats 13–17 (fig 6). Two patients had mutations in a region

outside these hotspots, predicting the substitutions G361S and G363E in filamin repeat 2. One of these patients presented with a phenotype intermediate between AOIII and Larsen syndrome (case 6; figs 1A and 3G). There were no phenotypic differences between patients with mutations located in the 5' compared with the 3' hotspot of *FLNB*.

Intrafamilial variation for the Larsen syndrome phenotype was studied in a large kindred segregating the recurrent mutation 679G→A, leading to the substitution E227K, in 30 individuals over three generations (case 5). Table 2 shows the clinical manifestations present in each member examined in this family. Numerous clinical symptoms and signs seen in Larsen syndrome were variable in this family. The most remarkable example of this is III2, who has no large-joint dislocations, yet all her children are affected to different degrees. All affected members in the pedigree show the typical facies, with hypertelorism absent in a minority. Cleft palate (8%) is relatively rare in this family. Typical features such as spatulate fingers and supernumerary carpal bones are present in the majority of the

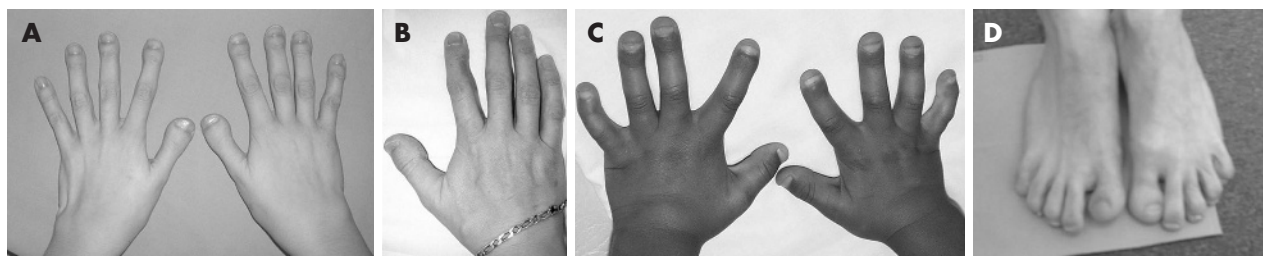


Figure 2 Clinical images from individuals with Larsen syndrome showing spatulate digits of (A–C) hands and (D) feet. (A) Case 15; (B) father of case 11; (C) case 12; (D) case 8. Informed consent was obtained from all patients/guardians for publication of this figure.

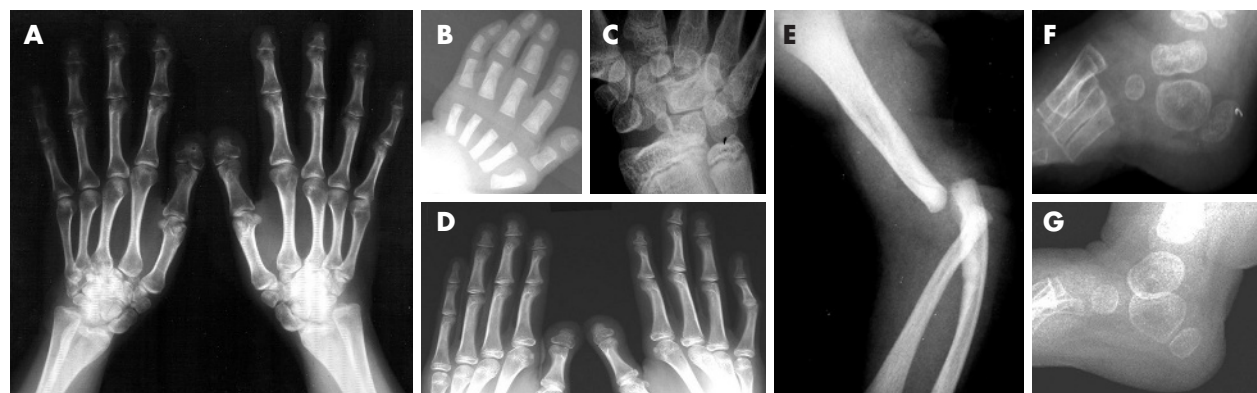


Figure 3 Radiographic features of Larsen syndrome. (A,B) Shortening and broadening of the distal phalanges, most notable in the thumb. Supernumerary carpal bones and a bifid calcaneal ossification centre are commonly observed. Individuals with an overlap of Larsen syndrome and atelosteogenesis type III show more severe skeletal malformations, such as a distally tapering humerus (E). (A) Case 15, (B,E,F) case 20 (aged 1 year), (C,D) case 20 (aged 14 years), (G) case 6.

affected family members. However, the first metacarpal and first metatarsal are disproportionately broad in some subjects (figs 7D,G,H). Some metacarpals and phalanges of affected individuals are overtubulated (Fig 7C,D,G,H).

MCCP analysis was performed for eight members in family 5 and also for case 15 (fig 8). The MCCP profiles generated were similar to the profiles reported previously for patients with Larsen syndrome.^{54 55} The pattern is characterised by short metacarpals (especially the second to fifth metacarpals) and short distal phalanges (especially the first, third and fourth). The mean pattern variability index (σ_z) was 1.36 for males and 1.35 for females (range 1.09–1.81) from family 5. A value >0.8 is indicative of a malformation syndrome.

DISCUSSION

Larsen syndrome, as originally described, comprises multiple large-joint dislocations, midface hypoplasia and spatulate fingers.¹ Variable features included cleft palate and vertebral

defects, especially in the cervical region. Since then the diagnosis has been applied to a wide spectrum of phenotypes characterised by joint dislocations, including some with severe extraskelatal manifestations and perinatal lethality. The description of mutations in *FLNB* underlying autosomal dominant Larsen syndrome, in addition to the allelic entities spondylcarpotarsal syndrome, AOI, AOIII and boomerang dysplasia, facilitates the study of this heterogeneous category afresh and offers an opportunity to re-define the phenotype.

Some phenotypic features are consistently present in *FLNB*-related, dominantly inherited, Larsen syndrome. Although multiple joint dislocations, digit and craniofacial abnormalities have previously been considered to be the defining features of autosomal dominant Larsen syndrome,^{1-4 6 13 15} the presence of other manifestations such as short stature, anterior thoracic wall deformity (either pectus excavatum or pectus carinatum) and spatulate fingers (most notable in the thumb) collectively improve the diagnostic specificity for dominant

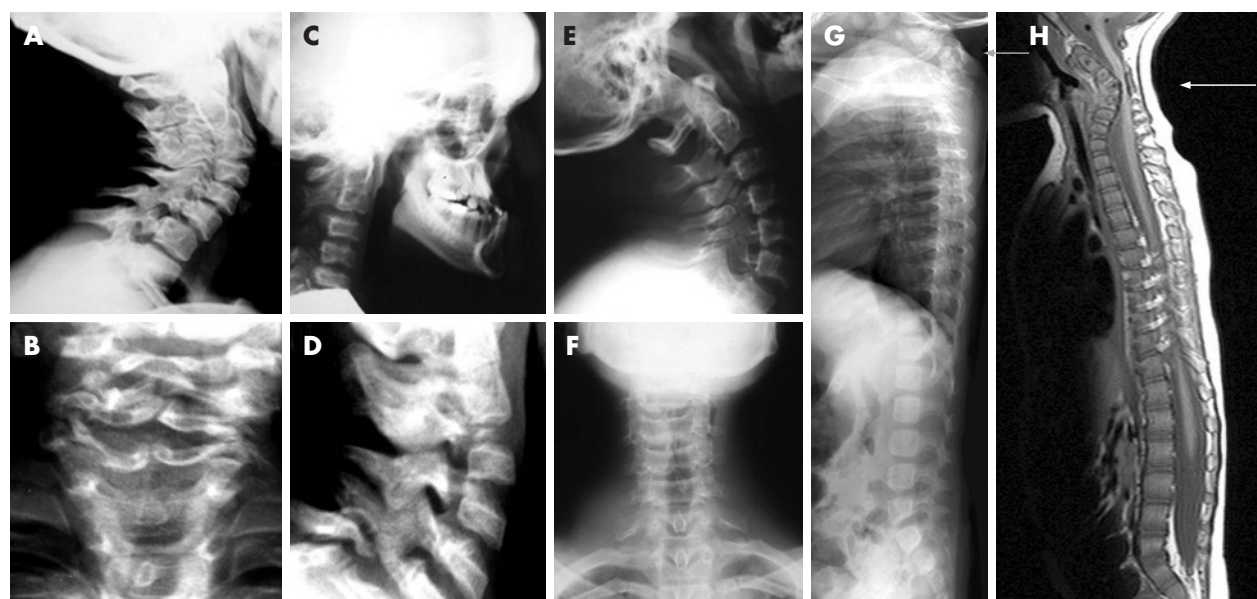

Figure 4 Anomalies of the cervical spine in Larsen syndrome. (A) Cervical kyphosis; (B,D) vertebral fusion and failure of fusion of the posterior neural arch are depicted. Family 5, case IV20 demonstrating (E) multiple accessory ossification centres of the vertebral laminae; (F) deficiency of elements of the posterior vertebral arches. Case 16 (G,H) showing cervical kyphosis complicated by cord compression and myelopathy (arrows). (A) Case 15; (B,D) case 20; (C) case 8; (E,F) family 5, case IV20; (G,H) case 16.

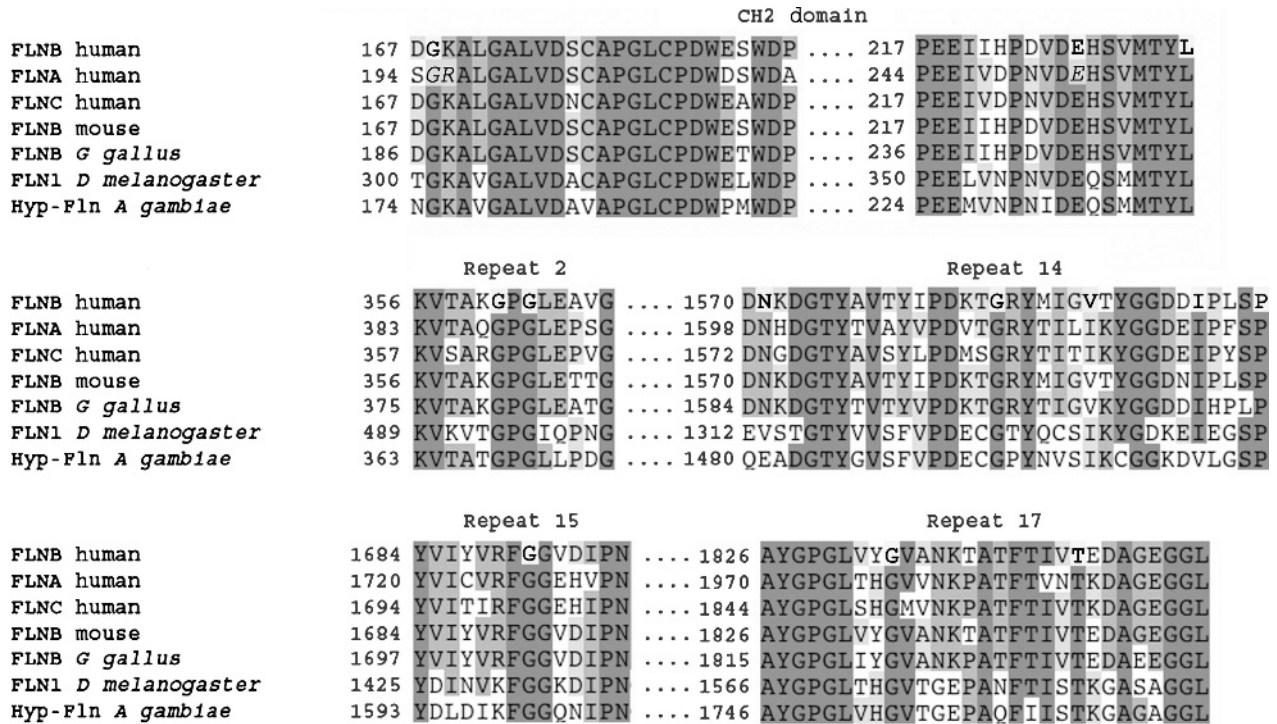


Figure 5 ClustalW alignment of homologous filamins from human, mouse, *Gallus gallus*, *Drosophila melanogaster* and *Anopheles gambiae*. Residues predicted to be substituted in Larsen syndrome in filamin B (bold) and otopalatodigital syndrome spectrum disorders in filamin A (italic) are indicated. Hyp-Fln, hypothetical filamin.

Larsen syndrome caused by mutations in *FLNB*. In this series, the only invariant feature observed in all cases of Larsen syndrome assessed at a sufficiently advanced age was the presence of accessory ossification centres in the carpus or tarsus or both. Individuals who carried a pathogenic mutation in *FLNB* but did not manifest one or more features previously thought to be obligatory for the diagnosis—large-joint dislocations (case 3, family 5, cases III2 and IV9), spatulate fingers (family 5, cases III2, IV3, IV7 and III8), midface hypoplasia (case 12) and stature below the 10th centile (cases 3, 4, 7 and 13)—were identified (table 1). Intrafamilial variability in severity of phenotypic expression reiterates previous observations in other reported cases of Larsen syndrome.^{11 14 15 56}

MCPD analysis indicates that autosomal dominant Larsen syndrome is characterised by a distinctive acral patterning defect. The mean MCPD profile for Larsen syndrome is similar to the mean MCPD profile of males with otopalatodigital syndrome type 1 (OPD1), a condition caused by mutations in the paralogous gene, *FLNA*.⁵⁵ This similarity is most pronounced

in the distal phalanges and suggests that such clinical relatedness between these two conditions reflects commonalities in their aetiopathogenesis.

Cervical spine anomalies, often leading to cervical kyphosis, have long been recognised complications of Larsen syndrome, but their true incidence and associated risk of myelopathy have not been quantified. In this study, 10 of 16 individuals had cervical vertebral anomalies, most typically fusion of C2 and C3 sometimes accompanied by subluxation of C3 on C4, and posterior arch defects within the cervical spine. Occasionally, anomalies can be considerably more extensive than this (fig 4). In this series, 3 of 20 probands (15%) manifested a myelopathy. The pronounced morbidity associated with myelopathy warrants spinal investigation on all individuals diagnosed with Larsen syndrome.

In the light of the above observations, does a recessive form of Larsen syndrome exist? These data support Mostello *et al.*³¹ who stated that no clinical, radiographic or histological marker separates several reports compatible with a recessively

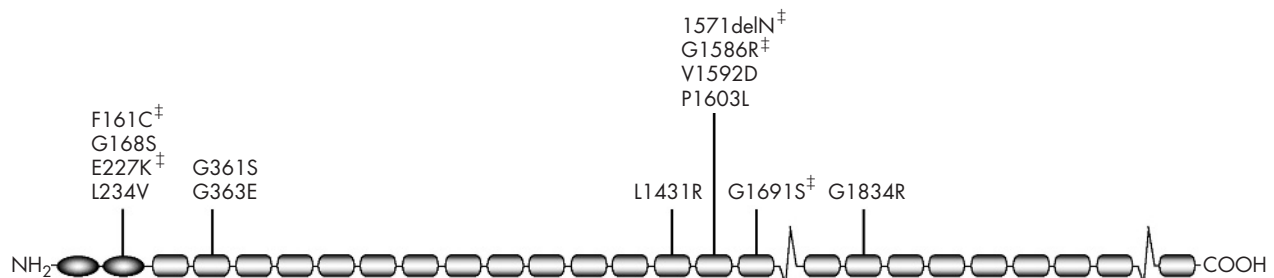


Figure 6 Location of predicted Larsen syndrome substitutions in filamin B. Schematic of filamin B, with two N-terminal calponin homology domains, and repeats 1–24 with hinge regions interposed between repeats 15 and 16, and 23 and 24. Above each domain is the predicted amino acid substitutions found in patients with Larsen syndrome. †Substitutions previously reported by Krakow *et al.*⁴²

Table 2 Phenotypic characteristics of family 5 segregating Larsen syndrome

ID	Age (in years)	Sex	Affected parent	Short stature	Prominent forehead	Frontal bossing	Hypertelorism	Depressed nasal bridge		Flat midface	Cleft palate	Deafness	Congenital joint dislocation			Clubfoot	Joint laxity	Spinal anomalies	Spatulate thumbs	Long/cylindrical fingers	Spatulate 1st toes	Developmental delay
								Elbows	Hips				Knees									
III 2	37	F	II 1	+	+	+	+	+	+	+	+	+	-	+	+	-	-	-	-	-	-	-
IV 1	15	M	III 2	-	+	+	+	+	+	+	+	+	+	+	+	+	+	+	+	+	+	-
IV 2	6	M	III 2	NA	+	+	+	+	+	+	+	+	+	+	+	+	+	+	+	+	+	-
IV 3	2	F	III 2	+	+	+	+	+	+	+	+	+	+	+	+	+	+	+	+	+	+	-
III 3	39	M	II 1	+	+	+	-	+	+	+	-	-	-	-	-	-	-	-	-	-	-	-
III 4	37	M	III 1	+	+	+	+	+	+	+	+	+	+	+	+	+	+	+	+	+	+	-
IV 7	14	F	III 4	-	+	+	-	+	+	+	-	-	-	-	-	-	-	-	-	-	-	-
IV 8	19	F	III 4	+	+	+	-	+	+	+	-	-	-	-	-	-	-	-	-	-	-	-
IV 9	8	M	III 4	-	+	+	-	+	+	+	-	-	-	-	-	-	-	-	-	-	-	-
III 8	40	F	II 2	+	+	+	+	+	+	+	+	+	+	+	+	+	+	+	+	+	+	-
IV 18	20	F	III 8	+	+	+	+	+	+	+	+	+	+	+	+	+	+	+	+	+	+	-
IV 20	17	M	III 8	-	+	+	+	+	+	+	+	+	+	+	+	+	+	+	+	+	+	-
IV 21	14	F	III 8	-	+	+	+	+	+	+	+	+	+	+	+	+	+	+	+	+	+	-
Proportion of cases				7/12	13/13	12/13	9/13	13/13	13/13	13/13	1/13	3/13	4/13	6/13	11/13	7/12	6/13	4/12	9/13	6/13	7/13	0/13
Percentage				58	100	92	69	100	100	100	8	23	31	46	85	58	46	34	69	46	54	0

F, female; M, male; +, present; -, absent; NA, not assessed.

inherited entity^{13 26 31} from those that describe the dominantly transmitted phenotype, now known to be caused by mutations in *FLNB*. These putative recessive entities may represent further instances of parental germline mosaicism for a heterozygotic *FLNB* mutation.¹⁸⁻²⁰ The entity described in the La Réunion Island isolate^{57 58} is clearly phenotypically discrete (stature -5 SD, polydactyly, advanced skeletal maturation, radioulnar synostosis, diaphyseal bowing, metacarpophalangeal and interphalangeal dislocations, lack of accessory carpal and tarsal bones), clearly distinguishing this phenotype from autosomal dominant Larsen syndrome due to *FLNB* mutations. Nevertheless, on the basis of current evidence, a recessive form of Larsen syndrome cannot be ruled out.^{5 20 26 28}

Clinical and radiological analysis can distinguish *bona fide* Larsen syndrome from other joint dislocation syndromes. Desbuquois syndrome shows autosomal recessive inheritance, advanced carpal ossification and prominent deformities of the hands.^{37 59} Accessory ossification centres are associated with the metacarpals and phalanges as opposed to the carpus. Pseudodiastrophic dysplasia is similar to Larsen syndrome with midface hypoplasia and clubfoot, but patients can be distinguished by the presence of rhizomelia, prominent dislocations of the interphalangeal joints and most often perinatal lethality.⁶⁰ Ehlers-Danlos syndromes (arthrochalasia types; formerly termed Ehlers-Danlos types VIIA and VIIB) are characterised by large-joint dislocations, but are radiographically distinct from Larsen syndrome.⁶¹ Importantly, a principal phenotypic feature in these conditions is that of hyperelastic skin, a feature not found in Larsen syndrome.

This series reports 20 patients who were heterozygous for mutations in *FLNB*. All mutations were either missense or produced small inframe deletions.⁴² The predicted substitutions/deletions were clustered, one cluster comprising exons 2-4 encoding CH2 and the other comprising exons 25-33 encoding filamin repeats 13-17 (fig 6). The interfamilial phenotypic variation between patients with recurring mutations was wide.

The most recurrent mutation, predicting the substitution G1691S, was noted in six unrelated patients, with variable consequences. These ranged from a mild phenotype comprising dislocated knee joints, flat facies, stature >97th centile and no cervical spine abnormalities (case 13), to severe cases with myelopathy (case 16). Farrington-Rock *et al*⁴³ described another infant with this mutation and a distally tapering humerus, cervical kyphosis and multiple joint dislocations indicating overlap with AOIII. The phenotypic relatedness between Larsen syndrome and AOIII is reinforced by reports of survival in individuals with the AOIII entity,⁶² although a diagnosis of AOIII is still appropriate in instances where incomplete ossification of skeletal elements (such as the phalanges) or long-bone modelling defects such as distally tapering humeri are prominent features.

A second recurrent mutation leading to the substitution E227K is similarly associated with variable expression. Study of a family segregating this mutation over four generations and having 30 affected members demonstrated that very few phenotypic components are obligatory requirements for the diagnosis (table 2). An unrelated case (case 4) has also been identified as having the same 679G→A mutation. His phenotype is comparatively mild, comprising elbow dislocations, an anterior thoracic wall deformity, supernumerary ossification centres and spatulate fingers.

There are many phenotypic and genetic similarities between the *FLNB*-related conditions and the OPD spectrum disorders, which are caused by mutations in the X-linked gene, *FLNA*. The *FLNA*-related entity bearing the most similarity to Larsen syndrome is OPD. Multiple large-joint dislocations have not been described in this entity, and therefore differential

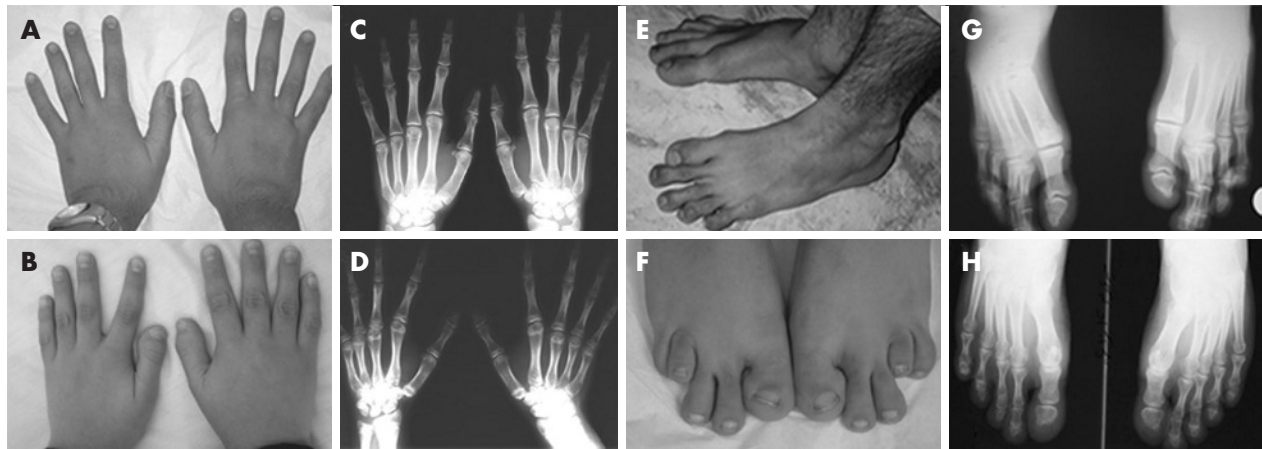


Figure 7 Intrafamilial phenotypic variability in Larsen syndrome. Clinical and radiographic images of hands and feet from different members of family 5. Variation in the degree of hypoplasia of the distal phalanx of the thumb (compare A and C with B and D). (A,C) IV20, (B,D,F) IV21, (E,G) IV1, (H) III3. Informed consent was obtained from all patients/guardians for publication of this figure.

diagnosis should be problematic only in males with Larsen syndrome who do not have this feature. The observation that mutations cluster in *FLNB* in a distribution similar to that observed in *FLNA* suggests parallels in the pathogenesis of these conditions and a functional relationship between these two filamin proteins. Some of the mutations reported to lead to the *FLNA* and *FLNB* groups of conditions occur at exactly homologous residues and produce identical amino acid substitutions (fig 5). The observation that filamin A and filamin B may heterodimerise in neuronal cells⁶³ and are co-expressed in the hypertrophic zone of the growth plate⁶² lends weight to this hypothesis, but evidence exists that conflicts with these data.⁶⁴

Despite the observation of intense clustering of mutations causative of Larsen syndrome, the pathogenic mechanism leading to this disorder remains unclear. Mutations in CH2 in the actin-binding domain may alter the regulation of the binding of filamin to actin. However, the substitutions identified in the filamin repeat domains do not correlate with binding sites of known filamin B protein interactants. All proteins known to interact with the repeat domains of filamin B bind to the region extending from hinge 1 to the C terminus. Whether the mutations disrupt protein interactions or facilitate novel interactions with filamin B is unclear. Over 30 proteins bind to filamin A⁶⁵ and a similar diversity of binding partners

may exist for filamin B, some possibly participating in the secretion of matrix components. Histological studies of the joint capsule and tracheal cartilage of an infant with Larsen syndrome who died of tracheobronchomalacia showed paucity of capsular collagen and cartilage that was thinned, hypocellular and contained shortened, "dysmature" collagen fibrils. In another patient histology of the epiphyseal growth plate showed disorganisation of the chondrocyte columns.³¹ Additionally, presenilins 1 and 2, components of the Notch signalling pathway that is critical for somite segmentation and the formation of the vertebrae,⁶⁶ interact with filamin B.⁴⁵ Disruption of presenilin–filamin B binding might be one mechanism that leads to the vertebral anomalies observed in Larsen syndrome (table 1, fig 4).

This work has defined autosomal dominant Larsen syndrome as a clinically and radiographically characteristic condition with pronounced intrafamilial and interfamilial variability. The identification of the basis of its aetiopathogenesis as clustered missense mutations in the cytoskeletal protein *FLNB* provides a valuable adjunct to the diagnosis of this clinically highly variable disorder.

ACKNOWLEDGEMENTS

We are grateful to the families for their participation in this study.

Authors' affiliations

L S Bicknell, S P Robertson, Department of Paediatrics and Child Health, University of Otago, Dunedin, New Zealand
C Farrington-Rock, R S Lachman, D L Rimoin, D H Cohn, D Krakow, Medical Genetics Institute, David Geffen School of Medicine at UCLA, Los Angeles, California, USA
Y Shafeghati, Genetics Research Centre, University of Welfare Science & Rehabilitation, Evin, Tehran, Iran
P Rump, Department of Clinical Genetics, University Medical Centre, Groningen, The Netherlands
Y Alanay, Clinical Genetics Unit, Department of Pediatrics, Faculty of Medicine, Hacettepe University, Ankara, Turkey
Y Alembik, Department of Clinical Genetics, CHRU de Strasbourg, Strasbourg, France
N Al-Madani, M H Karimi-Nejad, Karimi-Nejad Najmabadi Genetics Centre, Shahrake Gharb, Tehran, Iran
H Firth, Department of Medical Genetics, Addenbrookes Hospital, Cambridge, UK
C A Kim, Pediatria-Genética, Hospital das Clínicas da Faculdade de Medicina, Universidade de São Paulo, São Paulo, Brazil
K Leask, Department of Clinical Genetics, St Mary's Hospital, Manchester, UK

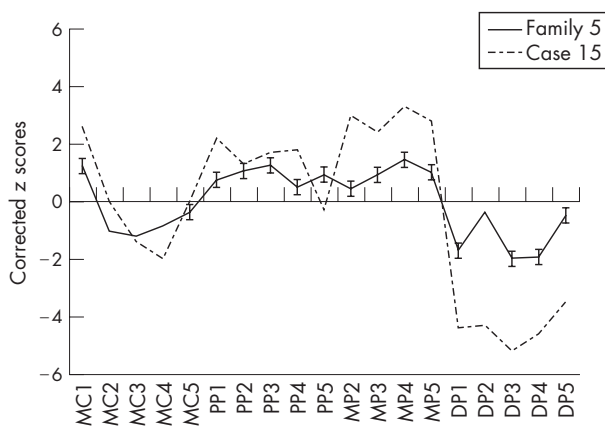


Figure 8 Metacarpophalangeal pattern profiles from family 5 and case 15. The mean (SEM) is shown for family 5.

M Maisenbacher, Department of Pediatrics, University of Florida, Florida, USA

E Moran, Department of Genetics, NYU-Hospital for Joint Diseases, New York, New York, USA

J G Pappas, Human Genetics Program, New York University School of Medicine, New York, New York, USA

P Prontera, Università degli Studi di Ferrara, Genetica Medica, Ferrara, Italy

T de Ravel, J-P Fryns, Department of Clinical Genetics, University Medical Center, Leuven, Belgium

E Sweeney, A Fryer, Alder Hey Children's Hospital, Liverpool, UK

S Unger, Institute for Human Genetics, University of Freiburg, Freiburg, Germany

L C Wilson, Clinical Genetics Unit, Great Ormond Street Hospital and Institute of Child Health, London, UK

Funding: SPR is supported by the Child Health Research Foundation of New Zealand and the Health Research Council of New Zealand.

Competing interests: None declared.

REFERENCES

- Larsen LJ, Schottstaedt ER, Bost FC. Multiple congenital dislocations associated with characteristic facial abnormality. *J Pediatr* 1950;**37**(4):574-81.
- Laïta RJ, Graham CB, Aase J, Scham SM, Smith DW. Larsen's syndrome: a skeletal dysplasia with multiple joint dislocations and unusual facies. *J Pediatr* 1971;**78**(2):291-8.
- Silverman FN. [Larsen's syndrome: congenital dislocation of the knees and other joints, distinctive facies, and, frequently, cleft palate]. *Ann Radiol (Paris)* 1972;**15**(3):297-328.
- Harris R, Cullen CH. Autosomal dominant inheritance in Larsen's syndrome. *Clin Genet* 1971;**2**(2):87-90.
- Oki T, Terashima Y, Murachi S, Nogami H. Clinical features and treatment of joint dislocations in Larsen's syndrome. Report of three cases in one family. *Clin Orthop Relat Res* 1976;**119**:206-10.
- Micheli LJ, Hall JE, Watts HG. Spinal instability in Larsen's syndrome: report of three cases. *J Bone Joint Surg Am* 1976;**58**(4):562-5.
- Johnston CE, 2nd, Birch JG, Daniels JL. Cervical kyphosis in patients who have Larsen syndrome. *J Bone Joint Surg Am* 1996;**78**(4):538-45.
- Stanley CS, Thelin JW, Miles JH. Mixed hearing loss in Larsen syndrome. *Clin Genet* 1988;**33**(5):395-8.
- Frints SG, De Smet L, Fabry G, Fryns JP. A young female with asymmetric manifestations of Larsen syndrome: another example of unilateral somatic cell-line mosaicism. *Clin Dysmorphol* 2000;**9**(4):273-6.
- Maack RW, Muntz HR. Ossicular abnormality in Larsen's syndrome: a case report. *Am J Otolaryngol* 1991;**12**(1):51-3.
- Alembik Y, Stoll C, Messer J. On the phenotypic overlap between "severe" otopalatal digital type II syndrome and Larsen syndrome. Variable manifestation of a single autosomal dominant gene. *Genet Couns* 1997;**8**(2):133-7.
- Herrmann HC, Kelly JH, Fried MP, Strome M. The association of a hearing deficit with Larsen's syndrome. *J Otolaryngol* 1981;**10**(1):45-8.
- Steel HH, Kohl EJ. Multiple congenital dislocations associated with other skeletal anomalies (Larsen's syndrome) in three siblings. *J Bone Joint Surg Am* 1972;**54**(1):75-82.
- Becker R, Wegner RD, Kunze J, Runkel S, Vogel M, Entezami M. Clinical variability of Larsen syndrome: diagnosis in a father after sonographic detection of a severely affected fetus. *Clin Genet* 2000;**57**(2):148-50.
- Habermann ET, Sterling A, Dennis RI. Larsen's syndrome: a heritable disorder. *J Bone Joint Surg Am* 1976;**58**(4):558-61.
- Stanley D, Seymour N. The Larsen syndrome occurring in four generations of one family. *Int Orthop* 1985;**8**(4):267-72.
- Vujic M, Hallstenson K, Wahlstrom J, Lundberg A, Langmaack C, Martinson T. Localization of a gene for autosomal dominant Larsen syndrome to chromosome region 3p21.1-14.1 in the proximity of, but distinct from, the COL7A1 locus. *Am J Hum Genet* 1995;**57**(5):1104-13.
- Bloch C, Peck HM. Radiological notes. *J Mt Sinai Hosp N Y* 1965;**32**(5):607-14.
- Petrella R, Rabinowitz JG, Steinmann B, Hirschhorn K. Long-term follow-up of two sibs with Larsen syndrome possibly due to parental germ-line mosaicism. *Am J Med Genet* 1993;**47**(2):187-97.
- Rochelson B, Petrikovsky B, Shmoys S. Prenatal diagnosis and obstetric management of Larsen syndrome. *Obstet Gynecol* 1993;**81**(5 Pt 2):845-7.
- Debeer P, De Borre L, De Smet L, Fryns JP. Asymmetrical Larsen syndrome in a young girl: a second example of somatic mosaicism in this syndrome. *Genet Couns* 2003;**14**(1):95-100.
- Bitoun P. Glaucoma with a Larsen-like syndrome. *Ophthalmic Genet* 1994;**15**(3-4):133-40.
- Kiel EA, Frias JL, Victorica BE. Cardiovascular manifestations in the Larsen syndrome. *Pediatrics* 1983;**71**(6):942-6.
- Liang CD, Hang CL. Elongation of the aorta and multiple cardiovascular abnormalities associated with Larsen syndrome. *Pediatr Cardiol* 2001;**22**(3):245-6.
- Morishima T, Sobue K, Tanaka S, So M, Arima H, Ando H, Katsuya H. Sevoflurane for general anaesthetic management in a patient with Larsen syndrome. *Paediatr Anaesth* 2004;**14**(2):194-5.
- Strisciuglio P, Sebastio G, Andria G, Maione S, Raia V. Severe cardiac anomalies in sibs with Larsen syndrome. *J Med Genet* 1983;**20**(6):422-4.
- Swensson RE, Linnebur AC, Paster SB. Striking aortic root dilatation in a patient with the Larsen syndrome. *J Pediatr* 1975;**86**(6):914-5.
- Topley JM, Varady E, Lestringant GG. Larsen syndrome in siblings with consanguineous parents. *Clin Dysmorphol* 1994;**3**(3):263-5.
- Critchley LA, Chan L. General anaesthesia in a child with Larsen syndrome. *Anaesth Intensive Care* 2003;**31**(2):217-20.
- Chen H, Chang CH, Perrin E, Perrin J. A lethal, Larsen-like multiple joint dislocation syndrome. *Am J Med Genet* 1982;**13**(2):149-61.
- Mostello D, Hoehstetter L, Bendon RW, Dignan PS, Oestreich AE, Siddiqi TA. Prenatal diagnosis of recurrent Larsen syndrome: further definition of a lethal variant. *Prenat Diagn* 1991;**11**(4):215-25.
- Hoeve HJ, Joosten KF, Bogers AJ, Hazebroek FW, Pfenninger J, van der Voort E, Leijala M. Malformation and stenosis of the cricoid cartilage in association with Larsen's syndrome. *Laryngoscope* 1997;**107**(6):792-4.
- Yamaguchi K, Ogawa Y, Handa T. Brain dysplasia associated with Larsen-like syndrome. *Pediatr Neurol* 1996;**14**(1):75-9.
- Shih JC, Peng SS, Hsiao SM, Wang JH, Shyu MK, Lee CN, Hsieh FJ. Three-dimensional ultrasound diagnosis of Larsen syndrome with further characterization of neurological sequelae. *Ultrasound Obstet Gynecol* 2004;**24**(1):89-93.
- Clayton-Smith J, Donnai D. A further patient with the lethal type of Larsen syndrome. *J Med Genet* 1988;**25**(7):499-500.
- Cetta G, Lenzi L, Ruggeri A, Tenni R, Boni M. Biochemical and structural abnormalities of the connective tissue in Larsen's syndrome. *Int Orthop* 1979;**3**(1):47-53.
- Beemer FA, Kramer PP, van der Harten HJ, Gerards LJ. A new syndrome of dwarfism, neonatal death, narrow chest, spondylometaphyseal abnormalities, and advanced bone age. *Am J Med Genet* 1985;**20**(3):555-8.
- Hunter AG, Carpenter BF. Atelosteogenesis I and boomerang dysplasia: a question of nosology. *Clin Genet* 1991;**39**(6):471-80.
- Sillence D, Worthington S, Dixon J, Osborn R, Kozlowski K. Atelosteogenesis syndromes: a review, with comments on their pathogenesis. *Pediatr Radiol* 1997;**27**(5):388-96.
- Robertson SP, Twigg SR, Sutherland-Smith AJ, Biancalana V, Gorlin RJ, Horn D, Kenwick SJ, Kim CA, Morava E, Newbury-Ecob R, Orstavik KH, Quarrell OW, Schwartz CE, Shears DJ, Suri M, Kendrick-Jones J, Wilkie AO. Localized mutations in the gene encoding the cytoskeletal protein filamin A cause diverse malformations in humans. *Nat Genet* 2003;**33**(4):487-91.
- Bicknell LS, Morgan T, Bonafe L, Wessels MW, Bialer MG, Willems PJ, Cohn DH, Krakow D, Robertson SP. Mutations in FLNB cause boomerang dysplasia. *J Med Genet* 2005;**42**(7):e43.
- Krakow D, Robertson SP, King LM, Morgan T, Sebald ET, Bertolotto C, Wachsmann-Hogiu S, Acuna D, Shapiro SS, Takafuta T, Alfimos S, Kim CA, Firth H, Steiner CE, Cormier-Daire V, Superfi-Furga A, Bonafe L, Graham JM, Jr., Grix A, Bacino CA, Allanson J, Bialer MG, Lachman RS, Rimoin DL, Cohn DH. Mutations in the gene encoding filamin B disrupt vertebral segmentation, joint formation and skeletogenesis. *Nat Genet* 2004;**36**(4):405-10.
- Farrington-Rock C, Firestein MH, Bicknell LS, Superfi-Furga A, Bacino CA, Cormier-Daire V, Le Merrer M, Baumann C, Roume J, Rump P, Verheij JBG, Sweeney E, Rimoin DL, Lachman RS, Robertson SP, Cohn DH, Krakow D. Mutations in Two Regions of FLNB Result in the Atelosteogenesis I and III. *Human Mutation*, 2006; in press.
- van der Flier A, Kuikman I, Kramer D, Geerts D, Kreft M, Takafuta T, Shapiro SS, Sonnenberg A. Different splice variants of filamin-B affect myogenesis, subcellular distribution, and determine binding to integrin [beta] subunits. *J Cell Biol* 2002;**156**(2):361-76.
- Zhang W, Han SW, McKeel DW, Goate A, Wu JY. Interaction of presenilins with the filamin family of actin-binding proteins. *J Neurosci* 1998;**18**(3):914-22.
- Xu W, Xie Z, Chung DW, Davie EW. A novel human actin-binding protein homologue that binds to platelet glycoprotein Ibalph. *Blood* 1998;**92**(4):1268-76.
- Takafuta T, Saeki M, Fujimoto TT, Fujimura K, Shapiro SS. A new member of the LM protein family binds to filamin B and localizes at stress fibers. *J Biol Chem* 2003;**278**(14):12175-81.
- Kim C, Cho Y, Kang CH, Kim MG, Lee H, Cho EG, Park D. Filamin is essential for shedding of the transmembrane serine protease, epithin. *EMBO Rep* 2005;**6**(11):1045-51.
- Stossel TP, Condeelis J, Cooley L, Hartwig JH, Noegel A, Schleicher M, Shapiro SS. Filamins as integrators of cell mechanics and signalling. *Nat Rev Mol Cell Biol* 2001;**2**(2):138-45.
- Poznanski AK, Garn SM, Nagy JM, Gall JC, Jr. Metacarpophalangeal pattern profiles in the evaluation of skeletal malformations. *Radiology* 1972;**104**(1):1-11.
- Garn SM, Hertzog KP, Poznanski AK, Nagy JM. Metacarpophalangeal length in the evaluation of skeletal malformation. *Radiology* 1972;**105**(2):375-81.
- Hosenfeld D, Hosenfeld F, Schaefer E, Grote W. IBM-PC compatible software for establishing metacarpophalangeal pattern profiles. *Clin Genet* 1991;**39**(5):396-400.
- Garn SM, Leonard WR, Poznanski AK. Applications of the pattern variability index (sigma z) to the quantification of dysmorphogenesis in the hand. *Am J Med Genet* 1987;**27**(1):143-52.
- De Smet L, Legius E, Fabry G, Fryns JP. The Larsen syndrome. The diagnostic contribution of the analysis of the metacarpophalangeal pattern profile. *Genet Couns* 1993;**4**(2):157-64.
- Poznanski AK. The hand in radiologic diagnosis. Philadelphia: Saunders, 1974.

- 56 **Al-Kaissi A**, Ammar C, Ben Ghachem MB, Hammou A, Chehida FB. Facial features and skeletal abnormalities in Larsen syndrome--a study of three generations of a Tunisian family. *Swiss Med Wkly* 2003;**133**(45-46):625-8.
- 57 **Bonaventure J**, Lasselín C, Mellier J, Cohen-Salal L, Maroteaux P. Linkage studies of four fibrillar collagen genes in three pedigrees with Larsen-like syndrome. *J Med Genet* 1992;**29**(7):465-70.
- 58 **Laville JM**, Lakermance P, Limouzy F. Larsen's syndrome: review of the literature and analysis of thirty-eight cases. *J Pediatr Orthop* 1994;**14**(1):63-73.
- 59 **Meinecke P**, Spranger J, Schaefer E, Maroteaux P. Micromelic dwarfism with vertebral and metaphyseal abnormalities and advanced carpotarsal ossification: another observation. *Am J Med Genet* 1989;**32**(3):432-4.
- 60 **Canki-Klain N**, Stanescu V, Bebler P, Maroteaux P. Pseudodiastrophic dysplasia evolution with age and management. Report of two new cases and review of the literature. *Ann Genet* 1990;**33**(3):129-36.
- 61 **Beighton P**, De Paepe A, Steinmann B, Tsipouras P, Wenstrup RJ. Ehlers-Danlos syndromes: revised nosology, Villefranche, 1997. Ehlers-Danlos National Foundation (USA) and Ehlers-Danlos Support Group (UK). *Am J Med Genet* 1998;**77**(1):31-7.
- 62 **Schultz C**, Langer LO, Laxova R, Pauli RM. Atelosteogenesis type III: long term survival, prenatal diagnosis, and evidence for dominant transmission. *Am J Med Genet* 1999;**83**(1):28-42.
- 63 **Sheen VL**, Feng Y, Graham D, Takafuta T, Shapiro SS, Walsh CA. Filamin A and Filamin B are co-expressed within neurons during periods of neuronal migration and can physically interact. *Hum Mol Genet* 2002;**11**(23):2845-54.
- 64 **Himmel M**, Van Der Ven PF, Stocklein W, Furst DO. The limits of promiscuity: isoform-specific dimerization of filamins. *Biochemistry* 2003;**42**(2):430-9.
- 65 **Feng Y**, Walsh CA. The many faces of filamin: a versatile molecular scaffold for cell motility and signalling. *Nat Cell Biol* 2004;**6**(11):1034-8.
- 66 **Dunwoodie SL**, Clements M, Sparrow DB, Sa X, Conlon RA, Beddington RS. Axial skeletal defects caused by mutation in the spondylocostal dysplasia/pudgy gene *Dll3* are associated with disruption of the segmentation clock within the presomitic mesoderm. *Development* 2002;**129**(7):1795-806.
- 67 **Alanay Y**, Utine GE, Lachman RS, Krakow D, Tuncbilek E. Terminal phalangeal accessory ossification center of the thumb: an additional radiographic finding in Larsen syndrome. *Pediatr Radiol* 2006;**36**(9):970-3.

Clinical Evidence—Call for contributors

Clinical Evidence is a regularly updated evidence-based journal available worldwide both as a paper version and on the internet. *Clinical Evidence* needs to recruit a number of new contributors. Contributors are healthcare professionals or epidemiologists with experience in evidence-based medicine and the ability to write in a concise and structured way.

Areas for which we are currently seeking contributors:

- Pregnancy and childbirth
- Endocrine disorders
- Palliative care
- Tropical diseases

We are also looking for contributors for existing topics. For full details on what these topics are please visit www.clinicalevidence.com/ceweb/contribute/index.jsp. However, we are always looking for others, so do not let this list discourage you.

Being a contributor involves:

- Selecting from a validated, screened search (performed by in-house Information Specialists) epidemiologically sound studies for inclusion.
- Documenting your decisions about which studies to include on an inclusion and exclusion form, which we keep on file.
- Writing the text to a highly structured template (about 1500-3000 words), using evidence from the final studies chosen, within 8-10 weeks of receiving the literature search.
- Working with *Clinical Evidence* editors to ensure that the final text meets epidemiological and style standards.
- Updating the text every 12 months using any new, sound evidence that becomes available. The *Clinical Evidence* in-house team will conduct the searches for contributors; your task is simply to filter out high quality studies and incorporate them in the existing text.

If you would like to become a contributor for *Clinical Evidence* or require more information about what this involves please send your contact details and a copy of your CV, clearly stating the clinical area you are interested in, to CECommissioning@bmjgroup.com.

Call for peer reviewers

Clinical Evidence also needs to recruit a number of new peer reviewers specifically with an interest in the clinical areas stated above, and also others related to general practice. Peer reviewers are healthcare professionals or epidemiologists with experience in evidence-based medicine. As a peer reviewer you would be asked for your views on the clinical relevance, validity, and accessibility of specific topics within the journal, and their usefulness to the intended audience (international generalists and healthcare professionals, possibly with limited statistical knowledge). Topics are usually 1500-3000 words in length and we would ask you to review between 2-5 topics per year. The peer review process takes place throughout the year, and out turnaround time for each review is ideally 10-14 days.

If you are interested in becoming a peer reviewer for *Clinical Evidence*, please complete the peer review questionnaire at www.clinicalevidence.com/ceweb/contribute/peerreviewer.jsp