

## **Endomyocardial Biopsy in Children Usefulness in Various Myocardial Disorders**

Alpay ÇELIKER, M.D.,\* Süheyla ÖZKUTLU, M.D.,\*\*  
Sema ÖZER, M.D.,\* Şencan ÖZME, M.D.,\*\*  
Funda ÖZTUNÇ, M.D.,\*\*\* Türkan KÜÇÜKALİ, M.D.,†  
Melda ÇAĞLAR, M.D.,† and Gülsev KALE, M.D.††

### **SUMMARY**

Endomyocardial biopsy studies in adults have demonstrated the usefulness of this method. It is possible that studies will be more productive in determining the etiology and clinical status in patients with clinically diagnosed myocardial diseases. A prospective study conducted over 16 months included 17 children, aged 14 months to 18 years, with the diagnosis of dilated, restrictive cardiomyopathy and myocarditis. In 16 patients right, and in 1 patient left heart endomyocardial biopsies were performed. The specimens were evaluated by light and electron microscopy. There were no serious complications after the procedure. In 1 of 17 children histology showed no myocardial tissue. Electron microscopy evaluations were currently available in 9 patients. Endomyocardial biopsy findings were found to be diagnostic in 41.2%, helpful in 29.4% and of no help in 29.4% of patients. In conclusion, endomyocardial biopsy technique is highly sensitive in children with myocardial disorders. In future it will be the major diagnostic tool for invasive but safe detection of myocardial disease.

### **Additional Indexing Words:**

Endomyocardial biopsy    Children    Myocardial disorders

**C**ARDIOMYOPATHY in childhood is a poorly understood disease process and is associated with cardiomegaly, progressive heart failure and death. The value of endomyocardial biopsy (EMB) for diagnosis of this clinical entity remains controversial.<sup>1)-5)</sup> Recent reports emphasize that

---

From the Departments of Pediatric Cardiology, Pathology and Pediatric Pathology, Hacettepe University, Ankara, Turkey.

\* Associate Professor of Pediatrics, Pediatric Cardiology, Hacettepe University.

\*\* Professor of Pediatrics, Pediatric Cardiology, Hacettepe University.

\*\*\* Resident in Pediatric Cardiology.

† Professor of Pathology, Hacettepe University.

†† Professor of Pediatrics, Pediatric Pathology, Hacettepe University.

Address for reprints: Şencan Özme, M.D., Department of Pediatric Cardiology, Hacettepe University, Ankara, Turkey.

Received for publication June 22, 1990.

Accepted July 27, 1990.

this technique has been useful in the diagnosis of myocardial diseases, including myocarditis and secondary involvement of the myocardium.<sup>1),4),6)–9)</sup>

This paper reports the results of a prospective study in children presenting with a clinical diagnosis of cardiomyopathy, myocarditis or cardiac involvement of systemic diseases, and assesses the value of EMB in the diagnosis of these patients.

#### MATERIALS AND METHODS

A prospective study conducted over 10 months included 17 evaluated children with a diagnosis of dilated, restrictive cardiomyopathy, myocarditis or cardiac findings secondary to systemic diseases. A history was obtained and physical examination, chest roentgenogram, ECG and echocardiogram were performed. Laboratory studies included the following: white blood count with differential and erythrocyte sedimentation rate. Viral studies and screening for carnitine deficiency could not be performed. In some patients blood selenium levels were determined.

Sixteen patients underwent right and 1 patient left heart cardiac catheterization for hemodynamic assessment and EMB. A long sheath and an open-ended catheter within the sheath were inserted into the right femoral vein. The catheter was positioned in the right ventricular septal wall. The long sheath was advanced over the catheter until a dampened ventricular pressure tracing was obtained. The catheter was withdrawn and a similar sized Cordis disposable biptome was advanced until the jaw mechanism extended just beyond the end of the sheath at the distal right ventricular septum. The sheath-biptome combination was withdrawn slightly and rotated clockwise to direct the biptome towards the distal septum. The biptome was opened and pressed against the right ventricular septum. The jaws were closed and a gentle tug was exerted to detach the specimens.

The specimens were fixed immediately. Before each specimen was obtained, care was taken to clean the biptome in heparinized saline solution, to aspirate the long sheath and to reposition the long sheath more proximally onto different ventricular positions. No significant complications occurred in our series.

Three to 5 (mean 4) specimens were immersed in buffered 10% formalin for light microscopy. One to 2 specimens were immersed in 2% buffered glutaraldehyde for electron microscopy. Paraffin sections were stained with various stains. Myocarditis and cardiomyopathy criteria were in accordance with previous reports.<sup>10)</sup>

The usefulness of EMB was evaluated as diagnostic when pathologic

findings allowed a precise diagnosis, as helpful when pathologic findings were nondiagnostic but excluded other diseases, and of no help when pathologic findings contained nothing to aid the diagnosis.

## RESULTS

In 1 of 17 patients histological examination of the specimens showed no myocardial but only lipid tissue, giving a success rate of 94.1%. For the presentation of our results we divided our patients into 4 groups (Table I). Electron microscopic examination has been done in 8 patients to date.

*Group 1:* The largest group comprised 7 children with echocardiographic findings of a dilated left ventricle, reduced cardiac function and clinical signs of congestive heart failure. The attempt failed in 1 patient with dilated cardiomyopathy secondary to nonparoxysmal supraventricular tachycardia. In 4 patients with dilated cardiomyopathy, histology revealed chronic myocardial changes consistent with dilated cardiomyopathy (Figs. 1A, B). In 1 patient with a dilated right ventricle and atrial septal defect, pathologic examination showed minimal hypertrophy, and surgical repair, in addition to permanent pacemaker implantation which was indicated for sick sinus syndrome, resolved the symptoms. In 1 case with dilated right and left ventricles, histology revealed nondiagnostic findings. In this patient electron microscopy showed glycogen deposits in the sarcolemma (Figs. 2A, B). In the other 2 patients in whom electron microscopy was available, histology was consistent with cardiomyopathic changes.

*Group 2:* The second group consisted of 4 patients with restrictive physiopathology. Histology revealed noncharacteristic myocardial changes. One patient improved with anti-tuberculous treatment which was instituted on the basis of lung findings and a positive skin test. In 1 patient with severe left sided but mild right sided endomyocardial fibrosis, biopsy interpretation revealed mild endocardial thickening and nonspecific myocardial changes. In this group electron microscopy showed some ultrastructural findings which were not diagnostic for restrictive cardiomyopathy (Figs. 3A, B).

*Group 3:* The third group involved 2 patients with Duchenne muscular dystrophy and 1 with fascio-scapulo-humeral dystrophy. All patients had normal echocardiographic findings. Histology revealed edema in 1 patient, nonspecific but highly suggestive of cardiomyopathy, and definite cardiomyopathy in 2 patients. In 1 patient with Duchenne muscular dystrophy electron microscopy showed myocardial abnormalities.

*Group 4:* This group consisted of 3 patients with different myocardial diseases. In 1 patient with indefinite resolving myocarditis, pathologic

Table I. Clinical Diagnoses and

| Patient  | Sex | Age at biopsy | Symptom duration | Previous diagnosis                      |
|--|-----|---------------|------------------|---|
| Clinical diagnosis: Dilated cardiomyopathy     |     |               |                  |   |
| 1  | M   | 7 yr          | ?                | Cardiomyopathy due to SVT               |
| 2  | M   | 7 yr          | 3 yr             | DCM                                     |
| 3  | F   | 11 yr         | 2 mo             | DCM?                                    |
| 4  | M   | 8 yr          | 3 yr             | DCM?, ASD, SSS                          |
| 5  | M   | 14/12 mo      | 6 mo             | DCM                                     |
| 6  | M   | 4 yr          | 1 yr             | DCM                                     |
| 7  | M   | 13 yr         | 3 yr             | DCM                                     |
| Clinical diagnosis: Restrictive cardiomyopathy |     |               |                  |   |
| 8  | M   | 15 yr         | 3 mo             | Restrictive CM? Lung tuberculosis       |
| 9  | F   | 10 yr         | 2 yr             | Restrictive CM?                         |
| 10   | F   | 2 yr          | 8 mo             | Restrictive CM?                         |
| 11   | M   | 1.5 yr        | 6 mo             | Endomyocardial fibrosis                 |
| Clinical diagnosis: Systemic muscle disease    |     |               |                  |   |
| 12   | M   | 10 yr         | ?                | Duchenne muscular dystrophy             |
| 13   | M   | 9 yr          | ?                | Duchenne muscular dystrophy             |
| 14   | M   | 15 yr         | ?                | Fascio-scapulo-humeral dystrophy        |
| Clinical diagnosis: Various                    |     |               |                  |   |
| 15   | M   | 15 yr         | 20 mo            | Drug-resistant ventricular ectopy       |
| 16   | M   | 13 yr         | 8 mo             | Resolving myocarditis?                  |
| 17   | M   | 17 yr         | 5 yr             | Nonobstructive hypertrophic CM (Noonan) |

DCM=dilated cardiomyopathy; EPS=electrophysiologic study; ASD=atrial septal defect;

examination revealed focal hypertrophy. In the second patient with drug refractory ventricular ectopy, histology showed normal findings. The last patient with nonobstructive hypertrophic cardiomyopathy associated with

Biopsy Correlations in Patients

| Light microscopy   | Electron microscopy   | Other laboratory tests   |
|--|---|--|
| Unsuccessful<br>DCM, chronic<br><br>DCM, chronic<br>Minimal hypertrophy<br>Myofibrillary hypertrophy,<br>minimal fibrosis<br><br>DCM, chronic<br>DCM, chronic  | Myofibrillary attenuation, mito-<br>chondrial degeneration, ectasia<br>in sarcoplasmic reticulum<br><br>Myofibrillary attenuation, gly-<br>cogen deposits in sarcolemma,<br>mitochondrial aggregation<br><br>Myofibrillolysis, mitochondrial<br>degenerations, myofilament frag-<br>mentation | EPS, Holter-monitorization   |
| Myofibrillary hypertrophy,<br>interstitial edema<br><br>Interstitial edema, focal<br>bleeding<br><br>Myofibrillary hypertrophy,<br>interstitial fibrosis<br><br>Mild thickening of endo-<br>cardium, hypertrophy in<br>some muscle fibers, edema<br>in connective tissue | Ectasia in sarcoplasmic reticu-<br>lum myofibrillolysis, interstitial<br>fibrosis<br><br>Myofibrillolysis, mitochondrial<br>degeneration, fibrosis<br><br>Myofibrillary attenuation, disar-<br>rangement of sarcomere, in-<br>creased fibrous tissue  |  |
| Edema<br><br>Cardiomyopathic changes<br>Cardiomyopathy   | Mitochondrial degeneration, in-<br>terstitial fibrosis, myofilament<br>fragmentation  | Skeletal muscle biopsy<br><br>Skeletal muscle biopsy<br>Skeletal muscle biopsy |
| Normal findings<br><br>Focal hypertrophy<br>Hypertrophic cardiomyo-<br>pathy   | Mitochondrial degeneration, in-<br>terstitial fibrosis, ectasia in sar-<br>coplasmic reticulum  | Holter monitorization, an-<br>giocardiography                                  |

SSS=sick sinus syndrome; CM=cardiomyopathy; SVT=supraventricular tachycardia.

Noonan syndrome, showed cardiomyopathic changes (Figs. 4A, B).

In the 17 patients studied EMB findings were considered to be "diag-  
 nostic" in 7, "helpful" in 5 and "no help" in 5 patients (Table II).

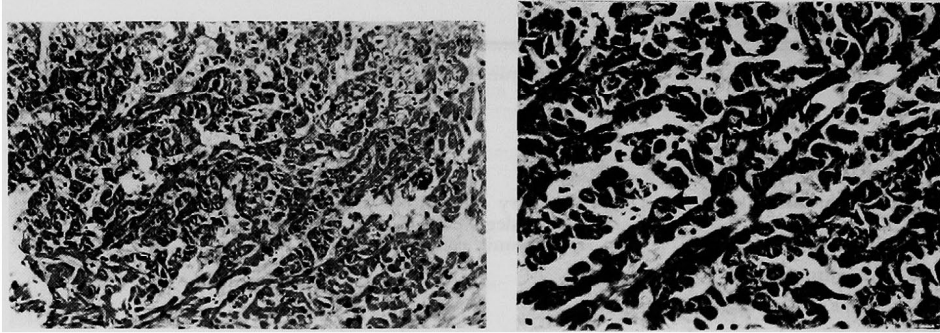


Fig. 1A (left). The myocardium with dilated cardiomyopathy showing long runs of attenuated degenerate muscle fibers with some nuclei large and hyperchromatic. Mild vacuolation (myocytolysis) of the center of some degenerate fibers. Hematoxylin and eosin, original magnification  $\times 230$ .

Fig. 1B (right). Occasional fibers are hypertrophic. Mild vacuolation is also present (black arrow) in some hypertrophic fibers. Hematoxylin and eosin, original magnification  $\times 460$ .

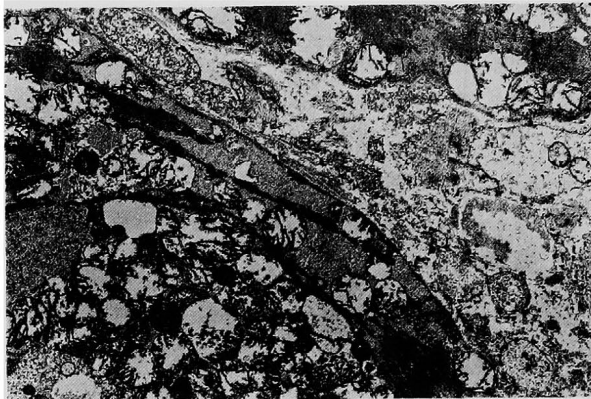


Fig. 2A. Dilated cardiomyopathy. Glycogen deposits beneath the sarcolemma and intermyofibrillary space, mitochondrial swelling, increased collagen in the interstitium. Electron micrograph, original magnification  $\times 5,000$ .

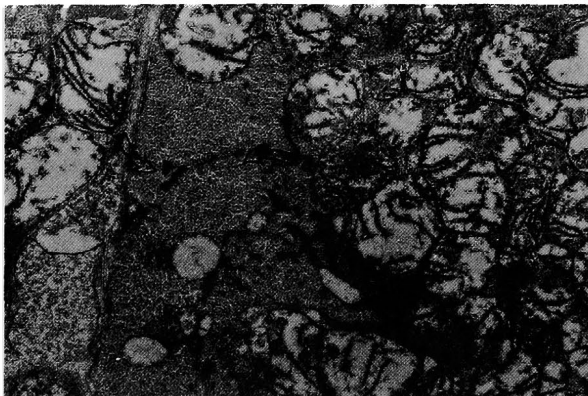


Fig. 2B. Abnormal glycogen deposits (arrow) beneath the sarcolemma. Electron micrograph, original magnification  $\times 15,000$ .

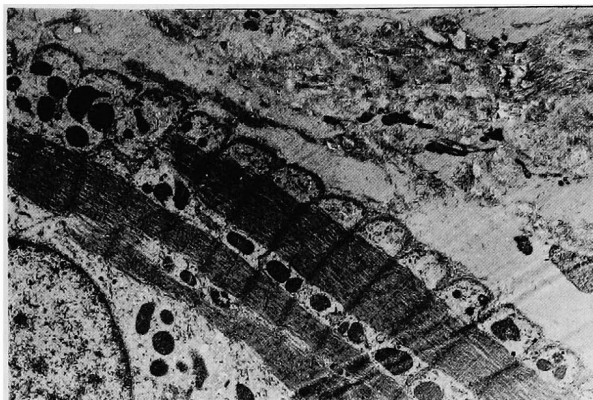


Fig. 3A. Restrictive cardiomyopathy. Irregularity of sarcomere, myofibrillosis and increased collagen in the interstitium. Electron micrograph, original micrograph, original magnification  $\times 5,000$ .

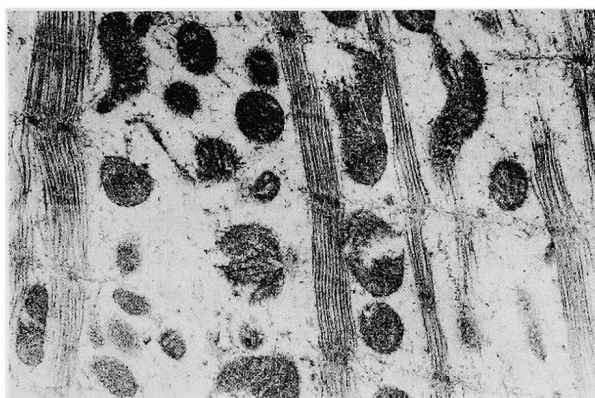

Fig. 3B. Myofibrillosis, mitochondrial abnormalities. Electron micrograph, original magnification  $\times 15,000$ .

#### DISCUSSION

Endomyocardial biopsy studies in adults have demonstrated the usefulness of this method.<sup>11)-16)</sup> It is possible that studies in children will be more productive in determining the etiology and clinical prognosis in patients with a clinical diagnosis of myocardial diseases. In the past there have been few, especially descriptive, reports of children with cardiomyopathy or myocarditis.<sup>17)-20)</sup>

In our study, EMB was done as part of a prospective study of infants, children and adolescents with clinical diagnoses of myocardial diseases of various etiologies. The endomyocardial biopsy technique was performed successfully and safely on the 17 subjects in this study. In various centers

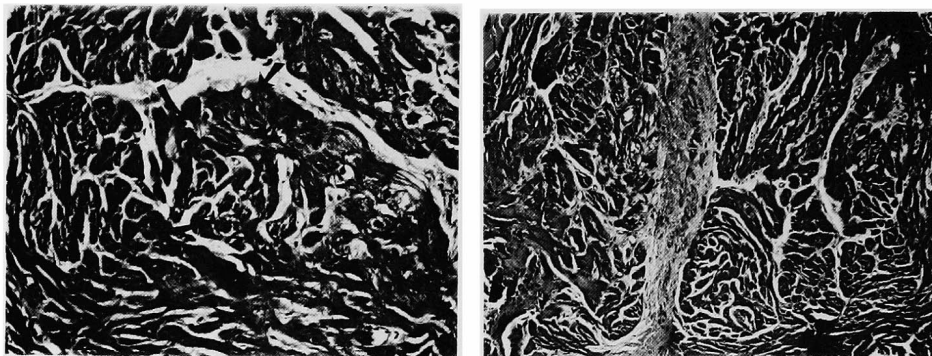


Fig. 4A (left). Myocardium of a heart with hypertrophic cardiomyopathy showing disordered interlacing hypertrophic fibers, but with some variability in size of fibers. Another characteristic is that the fibers show a swirling or whorled pattern (black arrows). Hematoxylin and eosin, original magnification  $\times 230$ .

Fig. 4B (right). Close up of short hypertrophic interlacing fibers with bizarre, prominent nuclei. The figure shows a swirling or whorled pattern. Interstitial and focal areas of fibrosis may also be present. Hematoxylin and eosin, original magnification  $\times 115$ .

Table II. Indications for Endomyocardial Biopsy and Results

| Indications                 | Diagnosis                                  | No. of patients | Findings   |           |           |
|-----------------------------|--|-----------------|------------|-----------|-----------|
|                             |  |                 | Diagnostic | Helpful   | No help   |
| Dilated cardiomyopathy      | DCM  | 7               | 4          | 1         | 2         |
| Restrictive physiopathology | Restrictive CM                             | 3               | —          | 1         | 2         |
|                             | Endomyocardial fibrosis                    | 1               | —          | 1         | —         |
| Systemic muscle disease     | Duchenne                                   | 2               | 1          | —         | 1         |
|                             | FSH dystrophy                              | 1               | 1          | —         | —         |
| Various                     | Arrhythmogenic right ventricular dysplasia | 1               | —          | 1         | —         |
|                             | Resolving myocarditis                      | 1               | —          | 1         | —         |
|                             | Nonobstructive HCM                         | 1               | 1          | —         | —         |
|                             | Total                                      | 17              | 7 (41.2%)  | 5 (29.4%) | 5 (29.4%) |

DCM=dilated cardiomyopathy; CM=cardiomyopathy; FSH=fascio-scapulo-humeral; HCM=hypertrophic cardiomyopathy.

the complication rate has been  $<1\%$  in adults.<sup>21)</sup> There was no serious complication except for mild ventricular ectopy and femoral hematoma, which developed in 1 patient when left EMB was done.

Pathology studies showed that this method could be efficient when an average of 5 or more specimens were used to determine the pathologic changes



and define the diagnosis.<sup>1),6),8),21)</sup> Thus the rate of false negative biopsy diagnosis is low. Postmortem examination has not been done and we were thus unable to prove the biopsy diagnoses.

Primary dilated cardiomyopathy can be diagnosed histopathologically only by exclusion of other diseases and causes.<sup>1)-5)</sup> Myofiber hypertrophy, moderate interstitial fibrosis and the above described changes are the non-typical findings of this myocardial abnormality at the ultrastructural level.<sup>1)-5)</sup> In the study of Lewis et al the pathologic changes involved interstitial fibrosis, myofiber hypertrophy, degeneration and necrosis.<sup>2)</sup> Also the myocarditis-cardiomyopathy relation was discussed in detail.<sup>2)-5),13),14)</sup> In our study the aim of EMB in the dilated cardiomyopathy group was to differentiate it from chronic myocarditis. The results were consistent with cardiomyopathy-related changes in the majority of patients, and not the myocarditic features described by other studies.<sup>4),7),9),11),12),16)</sup> In 1 case with a dilated right ventricle due to an atrial septal defect and sick sinus syndrome (slow rate atrial fibrillation) the pathology showed minimal myofiber hypertrophy, excluding cardiomyopathy.

Restrictive cardiomyopathy and pericarditis are distinct diseases which occur with various etiologies. The diagnosis can be made noninvasively by echocardiography.<sup>21)</sup> However in some patients definite diagnosis can be troublesome. Some authors have described the usefulness of the technique to determine the endomyocardial changes that occurred in restrictive cardiomyopathy.<sup>22)</sup> In our study group histology showed noncharacteristic changes in 3 patients. In 1 patient with apparent left sided endomyocardial fibrosis, endomyocardial biopsy was performed from the right ventricle and pathologic examination revealed mild endocardial thickening and noncharacteristic myocardial changes. This result reflects the changing pattern of restrictive cardiomyopathy.<sup>22)</sup> In future, characteristic findings will be described for this clinical entity.

Clinically detectable cardiomyopathy is very frequent in various systemic muscle diseases.<sup>23)</sup> In Duchenne muscular dystrophy cardiac involvement develops after 10 years of age.<sup>23)</sup> Also some other muscular dystrophies show myocardial changes.<sup>23),24)</sup> The diagnosis can be made by noninvasive methods.<sup>23)-25)</sup> There have been no reports about the use of the EMB technique in this group. Necropsy studies determined the pathologic changes.<sup>23)</sup> In 1 patient, with fascio-scapulo-humeral dystrophy and normal echocardiographic findings, histology showed cardiomyopathy findings. Edema and highly definitive histologic changes were found subsequently in 2 patients with Duchenne muscular dystrophy. The results emphasize the sensitivity of the endomyocardial disease. Because the fatal nature of this disease was not

changed by detecting the cardiac involvement with this technique, we do not recommend this invasive procedure in systemic muscle diseases, except for investigative purposes.

Myocarditis is a very strange disorder that leads to dilated cardiomyopathy.<sup>4),5),7)</sup> During this period of change histology may show chronic myocarditic features and some authors have demonstrated that immunosuppressive therapy prevented the cardiomyopathy.<sup>4),7),11),16)</sup> In 1 patient in our study group with findings of resolving myocarditis, histology was normal. Right ventricular dysplasia is a cardiac anomaly characterized by replacement of variable amounts of right ventricular myocardium by adipose and fibrous tissue.<sup>26)</sup> Ventricular arrhythmias are the major manifestations.<sup>26)</sup> The diagnosis depends on echocardiographic and angiocardiographic findings.<sup>26)</sup> Some reports described the effectiveness of the EMB technique together with noninvasive methods.<sup>27),28)</sup> The histology revealed normal findings in 1 patient with drug-resistant high grade ventricular ectopy and normal echocardiography and angiocardiography. Some authors detected nonobstructive hypertrophic cardiomyopathy in Noonan's syndrome,<sup>29),30)</sup> however, no pathologic research was conducted in these patients.<sup>29),30)</sup> Histology showed cardiomyopathic features in 1 patient with this syndrome. The results illustrated the sensitivity of the technique in this group of patients with various myocardial diseases.

In conclusion, the EMB technique is highly sensitive in children with myocardial disorders. In the future it will be the major diagnostic tool for invasive but safe detection of myocardial abnormalities.

#### REFERENCES

1. Leatherbury L, Chandra RS, Shapiro SR, Perry LW: Value of endomyocardial biopsy in infants, children and adolescents with dilated or hypertrophic cardiomyopathy and myocarditis. *J Am Coll Cardiol* **12**: 1547, 1988
2. Lewis AB, Neustein HB, Takahashi M, Lurie PR: Findings on endomyocardial biopsy in infants and children with dilated cardiomyopathy. *Am J Cardiol* **55**: 143, 1985
3. Fujita M, Neustein HB, Lurie PR: Transvascular endomyocardial biopsy in infants and small children. Myocardial findings in 10 cases of cardiomyopathy. *Hum Pathol* **10**: 15, 1979
4. Latham RD, Mulrow JP, Virmani R, Robinowitz M, Moody JM: Recently diagnosed idiopathic dilated cardiomyopathy: Incidence of myocarditis and efficacy of prednisone therapy. *Am Heart J* **117**: 876, 1989
5. Zee-Cheng CS, Tsai CC, Palmer DC, Codd JE, Pennington DG, Williams GA: High incidence of myocarditis by endomyocardial biopsy in patients with idiopathic congestive cardiomyopathy. *J Am Coll Cardiol* **3**: 63, 1984
6. Yoshizato T, Edwards WD, Alboliras ET, Hagler DJ, Driscoll DJ: Safety and utility of endomyocardial biopsy in infants, children and adolescents: A review of 66 procedures in 53 patients. *J Am Coll Cardiol* **15**: 436, 1990

7. Dec GW, Fallon JT, Southern JF, Palacios I: "Borderline" myocarditis: An indication for repeat endomyocardial biopsy. *J Am Coll Cardiol* **15**: 283, 1990
8. Schmaltz AA, Apitz J, Hort W, Maisch B: Endomyocardial biopsy in infants and children: experience in 60 patients. *Pediatr Cardiol* **11**: 15, 1990
9. Chow LH, Radio SJ, Sears TD, McManus BM: Insensitivity of right ventricular endomyocardial biopsy in the diagnosis of myocarditis. *J Am Coll Cardiol* **14**: 915, 1989
10. Aretz HT: Myocarditis: The Dallas criteria. *Hum Pathol* **18**: 619, 1987
11. Mason JW, Billingham ME, Ricci DR: Treatment of acute inflammatory myocarditis assisted by endomyocardial biopsy. *Am J Cardiol* **45**: 1037, 1980
12. Fenoglio JJ, Ursell PC, Kellogg CF, Drusin RE, Weiss MB: Diagnosis and classification of myocarditis by endomyocardial biopsy. *N Engl J Med* **308**: 12, 1983
13. Chow LC, Dittrich HC, Shabetai R: Endomyocardial biopsy in patients with unexplained congestive heart failure. *Ann Int Med* **109**: 535, 1988
14. De Scheerder I, Draet M, Cuvelier C, De Buyzere M, Clement DL: Right ventricular endomyocardial biopsy: Clinicopathologic correlates in 64 consecutive patients. *Acta Cardiologica* **17**: 11, 1987
15. Fenoglio JJ, Marboe CC: Endomyocardial biopsy: An overview. *Hum Pathol* **18**: 609, 1987
16. Daly K, Richardson PJ, Olsen EGJ, Morgan-Capner D, McSorley C, Jackson H, Jewitt DE: Acute myocarditis. Role of histological and virological examination in the diagnosis and assessment of immunosuppressive treatment. *Br Heart J* **51**: 30, 1984
17. MacKay EH, Pickering D, Littler WA: Cardiac biopsy in childhood. *Arch Dis Child* **52**: 785, 1977
18. Lurie PR, Fujita M, Neustein HB: Transvascular endomyocardial biopsy in infants and small children: Description of a new technique. *Am J Cardiol* **42**: 453, 1978
19. Schmaltz AA, Apitz J, Hort W: Endomyocardial biopsy in infants and children: Technique, indications and results. *Eur J Pediatr* **138**: 211, 1982
20. Mortensen SA, Baandrup U, Wennevold A: Endomyocardial biopsy in children with cardiac hypertrophy. *Acta Paediatr Scand* **75**: 81, 1986
21. Fowles RE, Mason JW: Role of cardiac biopsy in the diagnosis and management of cardiac disease. *Prog Cardiovasc Dis* **27**: 153, 1984
22. Toussaint M, Planche C, Villain E, Kachaner J: Restrictive cardiomyopathy in children: Ultrastructural findings. *Virchows Arch (A)* **412**: 27, 1987
23. Nigro G, Comil I, Politano L, Bain RJI: The incidence and evolution of cardiomyopathy in Duchenne muscular dystrophy. *Int J Cardiol* **26**: 271, 1990
24. Griggs RC: Hypertrophy and cardiomyopathy in the neuromuscular diseases. *Circ Res* **35**: 145, 1974
25. Voit T, Krogmann O, Lenard HG: Emery-Dreifuss muscular dystrophy: Disease spectrum and differential diagnosis. *Neuropediatrics* **19**: 62, 1988
26. Rossi PA: Arrhythmogenic right ventricular dysplasia: Clinical features. *Eur Heart J* **10** (suppl): 7, 1989
27. Strain J: Adipose dysplasia of the right ventricle: Is endomyocardial biopsy useful? *Eur Heart J* **10** (suppl): 84, 1989
28. Strain JE, Grose RM, Factor SM, Fisher JD: Results of endomyocardial biopsy in patients with spontaneous ventricular tachycardia but without apparent structural heart disease. *Circulation* **68**: 1171, 1983
29. Ehlers KH, Engle MA, Levin AR, Deelly WJ: Eccentric ventricular hypertrophy in familial and sporadic instances of 46 XX, XY Turner phenotype. *Circulation* **45**: 639, 1972
30. Nghiem QX, Toledo JR, Schreiber MH, Harris LC, Lockhart LL, Tyson KRT: Congenital idiopathic hypertrophic subaortic stenosis associated with a phenotypic Turner's syndrome. *Am J Cardiol* **30**: 683, 1972