

Cerebral Infarct Associated With Factor V Leiden Mutation in a Boy With Hemophilia A

Lale Olcay,¹ Aytemiz Gürgey,^{1*} Haluk Topaloğlu,² Sedat Altay,¹ Hülya Parlak,¹ and Murat Fırat³

¹Department of Pediatric Hematology, Hacettepe University İhsan Doğramacı Children's Hospital, Ankara, Turkey

²Department of Pediatric Neurology, Hacettepe University İhsan Doğramacı Children's Hospital, Ankara, Turkey

³Department of Radiology, Hacettepe University İhsan Doğramacı Children's Hospital, Ankara, Turkey

An 11-year-old boy with mild hemophilia A was admitted to our hospital because of focal convulsions. Magnetic resonance imaging showed an old occipital infarct. Protein C, S, antithrombin III, anticardiolipin antibodies and fibrinogen were normal. Heterozygosity for factor V Leiden mutation was detected. We suggest that factor V Leiden mutation should be studied in hemophiliacs with thrombosis. *Am. J. Hematol.* 56:189–190, 1997.

© 1997 Wiley-Liss, Inc.

Key words: factor V Leiden mutation; hemophilia A; thrombosis

INTRODUCTION

Arterial or venous thrombotic complications in patients with hemophilia A are quite uncommon. In the reported few cases with thrombosis and hemophilia A, thrombosis was attributed to cryoprecipitate or a less pure factor VIII concentrate, which was used as replacement [1–3]. On the other hand, factor V (FV) Leiden mutation was shown to be a risk factor for thrombosis, which has been demonstrated in 50% of patients with thrombophilia and has a prevalence of 7.1% in the general population in our country [4,5]. Activated protein C (APC) resistance is a recently described inherited pathogenetic risk factor of venous thrombosis. In the majority of cases, APC resistance is caused by a single point mutation in the FV gene [6]. Here were present an 11-year-old boy with hemophilia A, who developed cerebral infarct associated with FV Leiden mutation.

CASE REPORT

This boy was originally diagnosed with hemophilia A in our hospital at age 2 years. He was an isolated case of his family. The parents were unconsanguineous; one paternal uncle suffered from Behçet's disease and thrombophlebitis, and the mother's aunt and grandmother and the father's mother had had heart attacks. His prothrombin time was 13 sec, activated partial thromboplastin time 127 sec, bleeding time 7 min, factor VIII level 8%, and von Willebrand factor 78%.

Until 11 years of age, the patient was admitted four times because of posttraumatic intramuscular bleeding in

the left gastrocnemius muscle and nasal bleeding. He was treated with fresh frozen plasma. When he was 11 years old, he was admitted with fluttering of the right eyelids and twitching of the right perioral muscles with head dropping to the right and falling down. Fluttering of the eyelids lasting 10–15 sec and at intervals of 2–3 months was present 2 years prior to the latest event. He received his last plasma at age 7. His physical examination was unremarkable and did not show any lateralising signs. Blood sugar, electrolytes, calcium, cardiac examination, and echocardiography were normal. An electroencephalography recording revealed active paroxysmal activity originating from the left posterior region. Magnetic resonance imaging showed an old left occipital infarct (Fig. 1a,b). Protein C, 5 antithrombin III, anticardiolipin antibodies, and fibrinogen were normal. Heterozygosity for FV Leiden mutation was detected by amplification of the FV gene by polymerase chain reaction and digestion of the fragment with Mnl I as previously described [6].

DISCUSSION

Thrombotic complications in patients with hemophilia A are quite uncommon. Although there are cases with

Contract grant sponsor: Foundation of Inherited Blood Disorders, Ankara, Turkey.

*Correspondence to: Aytemiz Gürgey, M.D., Hacettepe University İhsan Doğramacı Children's Hospital, 06100, Ankara, Turkey.

Received for publication 28 May 1997; Accepted 11 June 1997

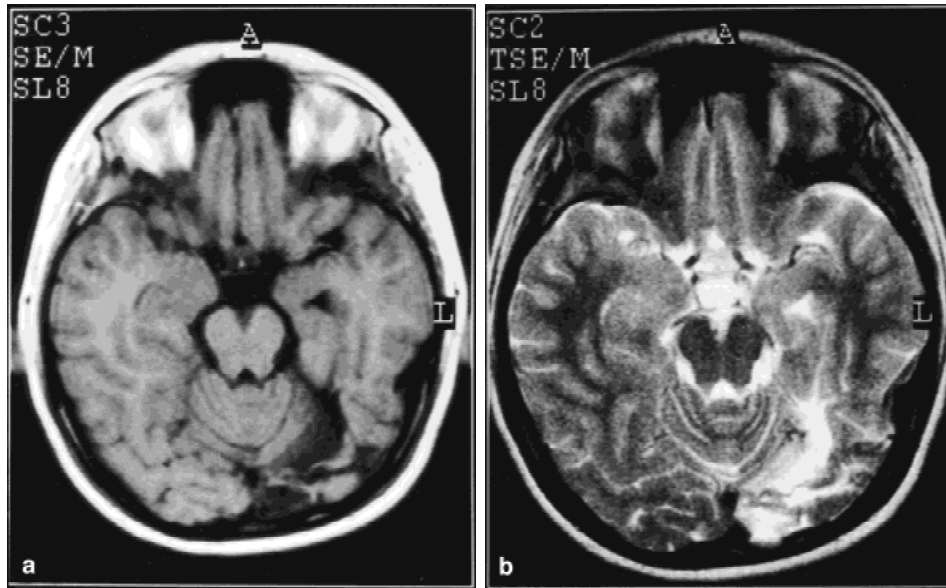


Fig. 1. Magnetic resonance imaging of the patient. T1-weighted image (a) shows secondary focal dilatation in the left lateral ventricle and focal cortical and subcortical matter loss in the left posterior occipital area, pointing to an old infarct. The lesion is hyperintense in the T2-weighted image (b).

arterial and venous occlusions, they are few [1–3]. On the other hand, the presence and role of FV Leiden mutation, which essentially is the most common cause of hereditary thrombophilia, have recently been of interest in hemophiliacs. Arruda et al. [7] detected that 3 out of 90 hemophilia A patients in their cohort were heterozygote for FV Leiden mutation. All of them had severe hemophilia A and did not display any symptoms of thrombophilia. As far as we know our case is the first symptomatic case of FV Leiden mutation and hemophilia A. It is also the first case of “mild” hemophilia A with FV Leiden mutation.

Our patient whose cerebral infarct was probably due to factor V mutation, is interesting for several reasons. All cases in the literature were receiving cryoprecipitate or a less pure preparation of factor VIII concentrate when the occlusions took place [1–3]. However, our patient had not had any factor concentrate or cryoprecipitate when thrombosis took place. Indeed, he received his last plasma at 7 years, i.e., 2 years before the onset of fluttering of the eyelids. The thrombosis in these patients was attributed to cryoprecipitate or a less pure solution for factor VIII. However, as mutation of FV Leiden was not studied, the role of these solutions in the etiology is debatable. None of the patients in the literature displayed any symptoms of thrombophilia [7]. However, our patient was symptomatic.

The number of admissions of our patient with bleeding were few. It can not be predicted precisely whether factor V Leiden contributed to the symptoms in a positive way because he already had mild hemophilia. Arruda et al. [7]

detected no alleviatory effect of FV Leiden mutation on bleeding tendency of their patients, all of whom had severe hemophilia A.

We suggest that FV Leiden mutation should be studied in patients with hemophilia A who developed thrombosis after receiving F VIII concentrates or cryoprecipitates or with a family history of thrombosis.

ACKNOWLEDGMENTS

This study was supported by the Foundation of Inherited Blood Disorders, Ankara, Turkey.

REFERENCES

1. Ritchie B, Woodman RC, Poon M: Deep venous thrombosis in hemophilia A. *Am J Med* 93:699–700, 1992.
2. Kopitsky RG, Geltman EM: Unstable angina associated with factor VIII concentrate therapy for hemophilia A. *Ann Intern Med* 105:215–216, 1986.
3. Ichinose A, Maruyama Y, Yoshida Y, Igata A: Cerebral thrombosis in a haemophiliac. *Thromb Haemost* 45:190, 1981.
4. Gürgey A, Mesci L, Renda Y, Olcay L, Koçak N, Erdem G: Factor V Q 506 mutation in children with thrombosis. *Am J Hematol* 53:37–39, 1996.
5. Gürgey A, Mesci L: The prevalence of Factor V Leiden (1691 G-A) mutation in Turkey. *Turk J Pediatr* 39:313–315, 1997.
6. Bertina RM, Koeleman BPC, Koster T, Rosendaal FR, Dirven RJ, Ronde H, van der Velden PA, Reitsma PH: Mutation in blood coagulation factor V associated with resistance to activated protein C. *Nature* 369:64–67, 1994.
7. Arruda VR, Annichino-Bizzacchi JM, Antunes SV, Costa FF: Association of severe haemophilia A and factor V Leiden: report of three cases. *Hemophilia* 2:51–53, 1996.