



# Reconstruction and Implant-Supported Rehabilitation of an Iatrogenically Caused Maxillary Alveolar Defect

Hakan Hıfzı Tüz, DDS, PhD,\* Onur Koç, DDS, PhD,† Salih Eren Meral, DDS,‡ and Azime Sibel El, DDS, PhD§

**B**one quality and quantity are the main requirements for proper dental implant placement and long-term survival of an implant-borne prosthesis. Insufficient alveolar bone volume or density may compromise the support and stabilization of the implant resulting in the failure of the osseointegration as well as the functional prosthesis.<sup>1,2</sup>

Periodontitis is known as the main etiological factor for alveolar bone loss. Trauma, tumors, resorption after tooth extraction, osteomyelitis, medication-related osteonecrosis of the jaws, and medication-induced tissue damage are the other factors that may cause defective alveolar bone structure, which can later be needed for dental implant restoration. Devitalizing endodontic agents are also rarely reported to be responsible for the destruction of periapical tissues because of leaking out from root canal apices.<sup>3,4</sup>

Various methods are used to repair alveolar defects including autogenous, allogenic, xenogeneic, alloplastic graft materials, and guided bone regeneration.<sup>5</sup> Among these, autogenous bone

*Defects of the oral and maxillofacial region may arise from several reasons such as trauma, infection, cyst, tumor, medication related osteonecrosis of the jaw, and misuse of some irritant agents. For reconstruction, autogenous grafts remain the gold standard among the alternatives. In our case, a 42-year-old woman referred to our clinic for implant-supported fixed bridge rehabilitation of her edentulous and defected left 2nd premolar and 1st molar region. In examinations, devitalizing agent-dependent large defect was observed. Anterior iliac crest*

*(AIC) grafting technique was preferred for reconstruction. Consecutively, 16-week bone healing and 3-month implant osseointegration periods were uneventful. After fabrication of the implant-supported fixed bridge, the patient was followed up for 2.5 years with no signs of bone resorption, gingival inflammation, and pain. AIC grafting and implant-borne fixed bridges seem stable and satisfactory methods for large maxillofacial defects. (Implant Dent 2019;28:510–513)*

**Key Words:** devitalizing leakage, iliac, implant

grafts are considered the gold standard for bone grafting.<sup>6</sup>

Extraoral (iliac, calvarium, costae, and tibia) and intraoral (ramus, chin, tuber, and zygomatic buttress) donor sites can be chosen for autogenous graft reconstruction according to defect character and size.<sup>2,6</sup> Autogenous grafts induce bone regeneration by 3 different mechanisms: osteogenesis, osteoinduction, and osteoconduction. Cancellous grafts are usually considered to have greater potential to induce osteogenesis because of their high osteogenic cell content, whereas cortical grafts have a greater capacity of bone regeneration by osteoconduction.<sup>2</sup>

In this case report, reconstruction and implant-supported rehabilitation of a maxillary defect caused by a devitalizing agent

are presented, and outcomes are discussed in light of the literature.

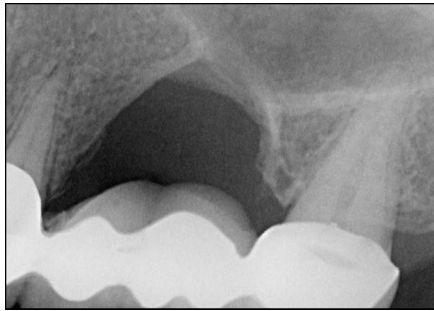
## CASE REPORT

A 42-year-old woman was referred to Hacettepe University Department of Oral and Maxillofacial Surgery for a dental implant-supported fixed crown restoration of her missing maxillary left 2nd premolar and 1st molar.

The patient reported that after the use of an endodontic devitalizing agent to treat her upper left 1st molar, she had persistent pain, which led to the loss of her tooth and an oroantral opening at the extraction site. Removal of the necrotic tissue residue, extraction of the 2nd premolar tooth, and repair of an oroantral fistula (OAF) has been completed with subsequent operations. Missing

\*Professor, Department of Oral and Maxillofacial Surgery, Faculty of Dentistry, University of Hacettepe, Ankara, Turkey.  
†Doctor, Department of Oral and Maxillofacial Surgery, Faculty of Dentistry, University of Hacettepe, Ankara, Turkey.  
‡Research Assistant, Department of Oral and Maxillofacial Surgery, Faculty of Dentistry, University of Hacettepe, Ankara, Turkey.  
§Doctor, Tepebaşı Oral Health Hospital, Ankara, Turkey.

**Reprint requests and correspondence to:** Onur Koç, DDS, PhD, Oral and Maxillofacial Surgery Department, Hacettepe University, Faculty of Dentistry, Sıhhiye, 06410 Ankara, Turkey, Phone: +90535 437 0626, Fax: +90312 310 4440, E-mail: onurkoc101@gmail.com

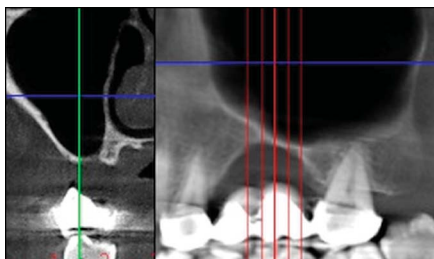


**Fig. 1.** Teeth-supported fixed dental bridge was fabricated before referral of the patient in an external center. The OAF closure operation-dependent excessive vertical defect can be seen. The huge space between the pontic and alveolar bone troubles the patient because of heavy food impaction.

teeth have been rehabilitated with tooth-supported fixed dental bridges after the closure of the OAF before the referral of the patient to our clinic (Fig. 1). Because the patient was not satisfied with her prosthesis and she finds it uncomfortable and unattractive, 2 years later, she was referred to our department with the expectation of dental implant-supported fixed prosthesis rehabilitation instead of bridge restoration.

Her clinical examination along with radiologic evaluation was consistent with the patient's previous statement. A fixed bridge restoration with long crown length had to be fabricated because of the vertical loss of alveolar bone, and poor hygiene around the restoration was observed as a result of non-anatomical hardware.

Her radiological evaluation showed loss of vertical and horizontal volume of the alveolar bone and a thin



**Fig. 2.** In the computed tomography section, the thin cortical bone formation can be seen after OAF closure. The presence of inadequate cortical bone before the referral of the patient makes healing of the bone graft more complicated.

cortical bone layer as a result of previous interventions (Fig. 2). Cone-beam computerized tomography image measurements revealed  $18 \times 10 \times 6$  mm bone loss at the defective area.

The patient was operated under general anesthesia. The recipient site was exposed to observe the defective area. Block bone grafting was decided as the choice of treatment primarily to maintain enough bone volume for 2 implant insertions in the 1st molar and 2nd premolar locations. The anterior iliac crest (AIC) was preferred as a choice of autogenous bone. A corticocancellous bone block was harvested from the medial aspect of the AIC. The graft was remodeled for optimal adaptation to the recipient site and stabilized with 3 miniscrews. A tension-free soft-tissue closure was achieved with 3.0 nonresorbable sutures.

The patient was reoperated after 16 weeks of a trouble-free healing period. During this intervention, adequate bone volume for dental implant placement (Fig. 3) was observed, and 2 dental implants (Roxolid; Straumann Standard Plus, Basel, Switzerland) were placed without any complications after removal of the fixation screws. After the 3-month period of osseointegration, the patient was referred to the prosthodontist for fabrication of the implant-supported fixed prosthesis. After prosthetic rehabilitation, trouble-free maintenance of the rehabilitation site was observed during the follow-up period of 2.5 years with no patient discomfort (Fig. 4).

## DISCUSSION

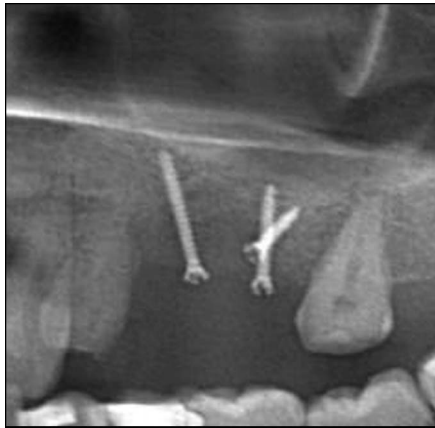Bone quality is one of the most important factors for implant success and maintenance. The "quality of bone" refers to more than one parameter such as bone mineral density, bone height, width, 3-dimensional orientation, and architecture.<sup>7</sup> Bone volume is a key factor for wider implant insertion, which plays a vital role in long-term implant stability and less bone resorption. Several studies pointed out that less bone density causes more stress in periimplant bone tissue and results in early bone loss adjacent to dental implants.<sup>8,9</sup> Bone density also affects primary stabilization, which is essential for successful osseointegration.<sup>8</sup>

The posterior maxillary region is one of the sites where the most reconstruction is needed because of both alveolar bone resorption and excessive maxillary sinus enlargement. Defects in the posterior maxillary region may arise from long-term untreated periodontal disease, periapical cysts, traumas that result in bone loss, osteomyelitis, tumors that originated in hard (bone) or soft (minor salivary gland) tissues, and traumatic extractions of posterior maxillary teeth.<sup>4,10</sup> Oroantral openings may occur and transform into OAFs if these defects are not treated properly. In our case, the reason for the maxillary defect was a rarely seen situation, which was expressed as devitalizing agent leakage at the upper left first molar with sinus opening.

Devitalizing agent-related bone resorption may cause alveolar defects depending on both the location and size of the bone loss. Osteomyelitis, gingival necrosis, neural disturbances such as paresthesia, and OAF may arise after the use of devitalizing agents in the maxillary molar region.<sup>11</sup> Management of these fistulas is aimed to provide closure. Different surgical techniques including advancing or rotating intraoral soft-tissue flaps from buccal or palatal mucosa, buccal fat pad, and submucosal connective tissue or lingual flaps or the use of alloplastic materials such as metallic foil, gold foil, and titanium were demonstrated to close OAFs.<sup>10,12,13</sup> In the present case, the OAF on the left maxillary region had been closed using intraoral soft-tissue flaps before referral of the patient to our department.

Despite the development of new graft materials, autologous bone grafts remain the gold standard because of their osteoinductive, osteoconductive, and nonimmunogenic features.<sup>6</sup> Autologous bone grafts can be harvested from both extraoral and intraoral donor sites. The choice of donor sites is usually based on the amount, geometry, and type of bone required for reconstruction.<sup>14</sup>

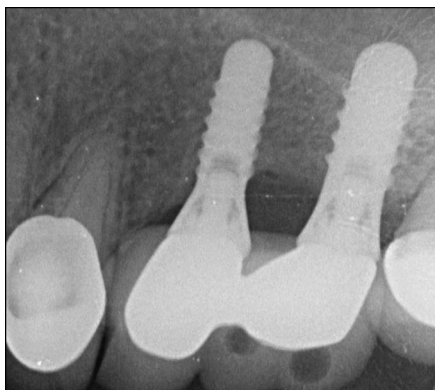
The bone in the maxillary tuberosity is usually cancellous and used in fenestrations and sinus lifting procedures, whereas the mandibular ramus is primarily cortical with little cancellous



**Fig. 3.** After a 16-week healing period of the AIC grafting procedure in the left maxillary posterior region, the healing of the block graft seems uneventful. The minimum bone resorption after the block grafting procedure enhances success of the implant-borne fixed bridge rehabilitation.

content and is used as inlay/onlay grafts. The symphysis also provides a reasonable volume of corticocancellous bone and is used as both onlay and inlay grafts.<sup>15</sup> Both symphysis and ramus grafts have demonstrated to be successful for the reconstruction of maxillary anterior horizontal defects with low resorption rates at 1-year follow-up, although ramus grafts are considered to have less postoperative donor site complications.<sup>16</sup>

Extraoral donor sites including tibia, fibula, ileum, calvarium, and costae should be considered when more



**Fig. 4.** A 2.5-year follow-up radiograph of the implant-supported fixed bridge rehabilitation: Reasonable cervical bone resorption was observed around the implants. The implant-borne fixed bridge seems trouble-free without any patient discomfort, gingival erythema, and inflammation signs.

bone volume is required. The AIC is one of the most preferred sites for it lies just beneath the subcutaneous layer of the skin and has a natural curve that is suitable for remodeling the curvature of alveolar bone. It has also ample cancellous bone, which provides better healing, with enough cortical component.<sup>17</sup> Complications such as a hematoma, edema, pain, penetration of the abdomen, rupture of the lateral femoral cutaneous nerve, and difficulty walking are rare.<sup>18</sup> It provides corticocancellous bone in large quantities with low morbidity.<sup>15,17</sup>

Patients having bone defects due to recurrent implant failures of the posterior maxillary region were shown to be reconstructed successfully with an AIC autogenous graft in the literature.<sup>18</sup> Some studies demonstrated that the AIC was also a safe site for the alveolar cleft, neoplasm excision, and osteoradionecrosis sequestrectomy reconstructions in the head and neck region.<sup>19,20</sup> One of the major disadvantages of grafts of the extraoral origin other than those of the calvarium is the fast resorption tendency due to their endochondral origin. This difference is probably because more cortical characteristics of the calvarial bone, which develops through intramembranous ossification, provide greater resistance to resorption.<sup>21</sup> However, Dreiseidler et al<sup>22</sup> pointed out that iliac crest grafting provides reasonable bone resorption until the implant placement stage.

Considering that there was a large amount of bone loss and the cancellous nature of the recipient site, the alveolar defect in our case was decided to be reconstructed by the anterior iliac autogenous graft based on both clinical and radiographic examinations. No complications were observed after the reconstruction procedure, and 2.5 years of follow-up controls revealed problem-free loading of implants.

## CONCLUSION

Dental implants have significant benefits over conventional fixed dental prostheses. Dental implant-supported fixed restorations do not need preparation of the adjacent teeth when compared with conventional fixed

prostheses.<sup>23</sup> Moreover, dental implants are believed to provide an interface for the functional force transmission to the bone, which stimulates bone regeneration, preventing it from resorption. Autogenous grafting remains the gold standard for reconstructing dentoalveolar defects. In addition, an AIC of both appropriate quality and quantity may be considered as a good alternative as the donor site.

## DISCLOSURE

The authors claim to have no financial interest, either directly or indirectly, in the products or information listed in the paper.

## ROLES/CONTRIBUTIONS BY AUTHORS

H. H. Tüz: Manager surgeon of the operation and co-writer. O. Koç: Assistant surgeon of the operation and co-writer. E. S. Meral: Assistant surgeon of the operation and co-writer. S. A. El: Assistant surgeon of the operation and co-writer.

## ACKNOWLEDGMENTS

No external funding was provided for this study.

## REFERENCES

1. Hirsch JM, Brånemark PI. Fixture stability and nerve function after transposition and lateralization of the inferior alveolar nerve and fixture installation. *Br J Oral Maxillofac Sur.* 1995;33:276–281.
2. Draenert F, Huetzen D, Neff A, et al. Vertical bone augmentation procedures: Basics and techniques in dental implantology. *J Biomed Mater Res A.* 2014;102:1605–1613.
3. Bataineh A, Al-Omari M, Owais A. Arsenical necrosis of the jaws. *Int Endod J.* 1997;30:283–287.
4. Yalçın S, Aybar B, Haznedaroğlu F, et al. Bilateral oroantral fistulas following devitalization of teeth by arsenic trioxide: A case report. *J Endod.* 2003;29:205–207.
5. Khojasteh A, Soheilifar S, Mohajerani H, et al. The effectiveness of barrier membranes on bone regeneration in localized bony defects: A systematic review. *Int J Oral Maxillofac Implants.* 2013;28:1076–1089.



6. Pistilli R, Felice P, Piatelli M, et al. Blocks of autogenous bone versus xenografts for the rehabilitation of atrophic jaws with dental implants: Preliminary data from a pilot randomized controlled trial. *Eur J Oral Implantol*. 2014;7:153–171.
7. Lindh C, Oliveira GHC, Leles CR, et al. Bone quality assessment in routine dental implant treatment among Brazilian and Swedish specialists. *Clin Oral Impl Res*. 2014;25:1004–1009.
8. Faverani LP, Barão VAR, Ramalho-Ferreira G, et al. The influence of bone quality on the biomechanical behavior of full-arch implant-supported fixed prostheses. *Mater Sci Eng C Mater Biol Appl*. 2014;37:164–170.
9. de Almeida EO, Rocha EP, Freitas AC Jr, et al. Finite element stress analysis of edentulous mandibles with different bone types supporting multiple-implant superstructures. *Int J Oral Maxillofac Implants*. 2010;25:1108–1114.
10. Haas R, Watzak G, Baron M, et al. A preliminary study of monocortical bone grafts for oroantral fistula closure. *Oral Surg Oral Med Oral Pathol Oral Radiol Endod*. 2003;96:263–266.
11. Lu PC, Wu JH, Chen CM, et al. Arsenic trioxide-induced mandibular osteomyelitis. *J Oral Maxillofac Surg*. 2015;73:1761–1765.
12. Mainous EG, Hammer DD. Surgical closure of oroantral fistula using the gold foil technique. *J Oral Surg*. 1974;32:528–530.
13. Abuabara A, Cortez AL, Passeri LA, et al. Evaluation of different treatments for oroantral/oronasal communications: Experience of 112 cases. *Int J Oral Maxillofac Surg*. 2006;35:155–158.
14. Sakkas A, Ioannis K, Winter K, et al. Clinical results of autologous bone augmentation harvested from the mandibular ramus prior to implant placement. An analysis of 104 cases. *GMS Interdiscip Plast Reconstr Surg DGPW*. 2016;5:Doc21.
15. Faverani LP, Ramalho-Ferreira G, Santos PHD, et al. Surgical techniques for maxillary bone grafting—literature review. *Rev Col Bras Cir*. 2014;41:61–67.
16. Ersanli S, Arisan V, Bedeloğlu E. Evaluation of the autogenous bone block transfer for dental implant placement: Symphyseal or ramus harvesting? *BMC Oral Health*. 2016;16:4.
17. Harbon S, Chartouni M, Ricbourg B. Morbidity of iliac bone grafts. A study apropos of 100 consecutive cases. *Ann Chir Plast Esthet*. 1991;36:45–50.
18. Sjöström M, Sennerby L, Nilson H, et al. Reconstruction of the atrophic edentulous maxilla with free iliac crest grafts and implants: A 3-year report of a prospective clinical study. *Clin Implant Dent Relat Res*. 2007;9:46–59.
19. Vu DD, Schmidt BL. Quality of life evaluation for patients receiving vascularized versus nonvascularized bone graft reconstruction of segmental mandibular defects. *J Oral Maxillofac Surg*. 2008;66:1856–1863.
20. Francis CS, Mobin SSN, Lypka MA, et al. rhBMP-2 with a demineralized bone matrix scaffold versus autologous iliac crest bone graft for alveolar cleft reconstruction. *Plast Recon Surg*. 2013;131:1107–1115.
21. Dado DV, Izquierdo R. Absorption of onlay bone grafts in immature rabbits: Membranous versus enchondral bone and bone struts versus paste. *Ann Plast Surg*. 1989;23:39–48.
22. Dreiseidler T, Kaunisaho V, Neugebauer J, et al. Changes in volume during the four months' remodelling period of iliac crest grafts in reconstruction of the alveolar ridge. *Br J Oral Maxillofac Surg*. 2016;54:751–756.
23. Hebel K, Gajjar R, Hofstede T. Single-tooth replacement: Bridge vs. implant-supported restoration. *J Can Dent Assoc*. 2000;66:435–438.