

Pectoral nerve block as the sole anesthetic technique for a modified radical mastectomy in a comorbid patient

Sehend Debbag, MD, Fatma Sarıcaoğlu, MD.

ABSTRACT

يتم إجراء عمليات جراحة الثدي بشكل عام عن طريق التخدير العام. من أجل تقليل الألم بعد العملية الجراحية، عادة ما يتم الجمع بين التخدير الناحي والتخدير العام. كتل الأعصاب الصدرية هي تقنية جديدة لتوفير السيطرة على الألم المحيطة بالجراحة وبعد العملية الجراحية للمرضى الذين خضعوا لجراحة الثدي. أجرينا كتلة العصب الصدري الأول وكتلة العصب الصدري الثاني كتقنية مخدر وحيد مع التخدير بواسطة ديكسميديتوميدين من أجل استئصال الثدي المعدلة الجذري، لمریضة تبلغ من العمر ٧٥ عامًا مصابة بأمراض متعددة. يمكن أن تكون كتل الأعصاب الصدرية مع التخدير تقنية جيدة لجراحة الثدي من التخدير العام في المرضى المصابين بأمراض.

Breast surgery operations are generally performed by general anesthesia. In order to decrease postoperative pain, regional anesthesia is usually combined with general anesthesia. Pectoral nerve blocks is a novel technique to provide perioperative and postoperative pain control for patients underwent breast surgery. We performed pectoral nerve block I and pectoral nerve block II as a sole anesthetic technique with sedation by dexmedetomidine for modified radical mastectomy, for a 75-year-old female patient with multiple diseases. Pectoral nerve blocks with sedation could be a good technique for breast surgery than general anesthesia in comorbid patients.

Saudi Med J 2019; Vol. 40 (12): 1285-1289
doi:10.15537/smj.2019.12.24644

From the Department of Anesthesiology and Reanimation, Faculty of Medicine, Hacettepe University, Ankara, Turkey.

Received 11th September 2019. Accepted 13th October 2019.

Address correspondence and reprint request to: Dr. Sehend Debbag, Department of Anesthesiology and Reanimation, Faculty of Medicine, Hacettepe University, Ankara, Turkey.
E-mail: sehenddebbag@yahoo.co.uk
ORCID ID: orcid.org/0000-0002-0869-7397

Disclosure. Authors have no conflict of interests, and the work was not supported or funded by any drug company.

An increase in the world's population has led to a rise in the incidence of breast cancer, the most common type of cancer in women. Furthermore, improvements in the health care system have increased the number of elderly patients who often suffer with comorbid diseases. These factors are a challenge for anesthetists to be able to perform safe anesthesia and provide good postoperative pain control. General anesthesia (GA) is frequently associated with postoperative vomiting and nausea, which may occur in up to 50% of cases. Regional or local anesthesia is an alternative to GA and results in fewer postoperative complications, a shorter hospital stay, and better perioperative pain control.¹ Regional anesthesia (RA) techniques have less intraoperative, respiratory, and postoperative complications than GA.² In breast cancer surgery operations, pectoral nerve blocks (PECs) I and II have been performed in combination with GA to reduce perioperative and postoperative pain.³ An ultrasound guiding PECs blocks is straightforward and provides analgesia for the chest wall. In this case, we administered PECs I and PECs II block on a 75-year-old patient who underwent a modified radical mastectomy, as the sole anesthesia technique to prevent complications related to GA.

Case Report. A 75-year-old female (height 160 cm, weight 102 kg and American Society of Anesthesiologists [ASA] was III) diagnosed with invasive ductal carcinoma was due to undergo a right side modified radical mastectomy with axillary lymph node dissection at the Hacettepe University Medical Faculty Hospital, Ankara, Turkey. She had type II diabetes mellitus, hypertension, atrial fibrillation, coronary artery disease, congestive heart failure with an ejection fraction (EF) of 40%, and moderate chronic obstructive pulmonary disease. She also had a cardiac resynchronization therapy defibrillator (CRT-D) device implanted when she was 66 years old.

Clinical findings. Monitoring with pulse oximetry, electrocardiography, and non-invasive blood pressure tests revealed that she had a baseline heart rate of 96 beats/min, blood pressure of 140/85 mmHg, and an

oxygen saturation of 89% upon arrival to the operating theatre (Table 1).

As she had various comorbidities, we were reluctant to administer GA and decided to instead administer PECs I and II blocks combined with sedation.

Diagnostic assessment. In this case; to identify the muscle groups, ribs, and to visualize the needle placement and the local anesthetic spread an ultrasound has been used.

Therapeutic intervention. Supplemental oxygen was administered by nasal oxygen at 4 l/min following

a premedication of 1.5 mg of intravenous midazolam was given. We subsequently induced a loading dose of dexmedetomidine (1µg/kg over 10 minutes), followed by 0.2 µg/kg/hour as a maintenance dose for sedation.

When a score of 5 had been achieved on the Ramsey sedation scale, the right chest wall and the right axillary region were cleaned using iodine. A high frequency (4-12 MHz) linear probe (GE Healthcare, USA) was placed inferior to the right clavicle to identify the pectoral muscles with axillary vessels; the probe was moved caudally to identify the 3rd and 4th ribs and

Table 1 - Timeline of medical history, vital signs, evaluations and interventions.

Dates	Medical history		
2000	Diagnosed as hypertension, diabetic mellitus and coronary artery disease		
2010	VVI pacemaker implantation		
2015	Congestive heart failure		
	CRT-D device placement (left chest wall)		
August 2018	Diagnosed as moderate chronic obstructive pulmonary disease, discharged with home type oxygen concentrator		
	Right breast mass		
	Tru cut biopsy		
September 2018	Invasive ductal carcinoma grade 3		
	FDG-PET CT: Metastasis in abdominal and sacral region		
October 2018	Neoadjuvant chemotherapy: Letrozole		
January 2019	Preparation for modified radical mastectomy		
Dates	Summaries from initial and follow up visits	Diagnostic testing and vital signs	Interventions
31/1/2019	Preoperation for surgery	CBC, CXR, ECHO, ECG, biochemistry panel	
1/2/2019 (08:30-08:40 a.m.)	Preparation and monitoring the patient for operation in operation theatre	BP=140/85, Spo2=89, HR=96	- nasal oxygen 4 l/min - 1.5 IV midazolam - loading dose dexmedetomidine 1µg/kg
1/2/2019 (08:50 am)	Preparation for Pecs I and II Blocks. Right chest wall and axillary region cleaned by iodine	BP=130/85, Spo2=91, HR=84	- maintenance dose dexmedetomidine 0.2µg/kg/h
1/2/2019 (08:50-09:00 a.m.)	Screening the right chest wall by ultrasound	BP=124/82, Spo2=90, HR=81	
1/2/2019 (09:01 a.m.)	Identification the 3rd and 4th rib		Skin infiltration by 1 ml (20% prilocaine)
1/02/2019 (09:03 a.m.)	Pecs II performed	BP=144/86, Spo2=90, HR=89	Injecting 20 ml (5% bupivacaine)
1/2/2019 (09:04 a.m.)	Pecs I performed		Injecting 10 ml (5% bupivacaine)
1/2/2019 (09:25 a.m.)	Evaluation sensory block by cold test	BP=124/83, Spo2=90, HR=78	
1/2/2019 (09:35 a.m.)	Surgery started	BP=145/88, Spo2=91, HR=87	
1/2/2019 (11:00 a.m.)	Patient felt pain by the placement of the drains	BP=156/91, Spo2=92, HR=97	5 ml (20% prilocaine performed)
1/2/2019 (11:25 a.m.)	The surgery was completed	BP=121/80, Spo2=91, HR=81	
1/2/2019 (11:35 a.m.)	The patient had no PONV, VAS was 2	BP=136/88, Spo2=92 HR=86	
1/2/2019 (12:30 p.m.)	Transferred to PACU		
1/2/2019 (12:40 p.m.)	VAS was 2,vital signs were stabil	BP=133/84, Spo2=90, HR=78	
1/2/2019 (02:35 p.m.)	VAS was 6	BP=158/91, Spo2=91 HR=102	30 mg IV pethidine and 1000 mg IV paracetamol performed
2/2/2019	Transferred to ward	BP=142/85, Spo2=89, HR=91	
5/2/2019		Discharged from hospital	

CRT-D - cardiac resynchronization therapy defibrillator, FDG-PET CT - Positron Emission tomography, CBC - complete blood count, ECHO - echocardiogram, CXR - chest xray, ECG - electrocardiogram, BP - non invasive blood pressure, HR - heart rate, SpO2 - peripheral capillary oxygen saturation, PONV - post operative nausea and vomiting, VAS - visual analog scale, PACU - post-anesthesia care unit

after the oblique rotation of the probe, the skin was infiltrated with 2% prilocaine (Figure 1). Initially, the PECs II block was performed using a 10 mm 22G regional block (UniPlex, PAJUNK, Germany) needle, which was inserted using the in-plane technique into the tissue between the serratus anterior muscle and the pectoralis minor muscle. A total of 20 ml of a local anesthetic agent (bupivacaine 0.5%) was injected (Figure 2). To administer the PECs I block, the needle was withdrawn and subsequently inserted between the pectoralis major and minor muscles, and 10 ml of the local anesthetic (bupivacaine 0.5%) was injected between these 2 muscles (Figure 3). The whole procedure took approximately 10 minutes. Twenty minutes after performing the block, a cold test was used to evaluate the effectiveness of the sensory block. Surgery proceeded after a further 10 minutes. She was draped in the standard sterile manner. An elliptical incision was made, and the flaps were dissected laterally from the latissimus muscle superiorly to the clavicle. The breast was dissected from the pectoralis major muscle. The interpectoral lymph nodes and fat were removed along with the specimen.

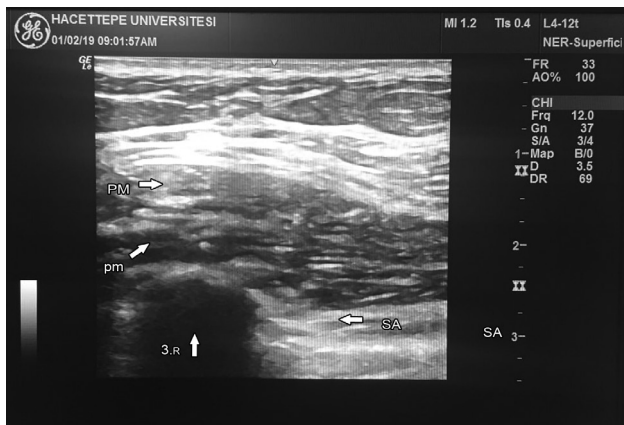


Figure 1 - The ultrasound vision of pectoral major, pectoral minor and serratus anterior muscles. PM - pectoral major muscle, pm - pectoral minor muscle, 3.R - the third rib, SA - serratus anterior muscle

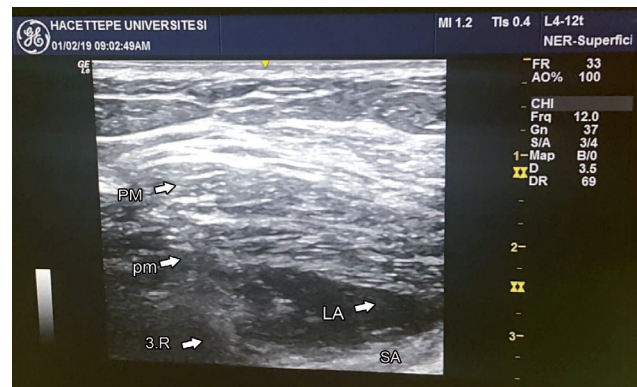


Figure 2 - PECs II block: The distribution of local anesthesia between pectoral minor and serratus anterior muscles. PECs II - pectoral nerve blocks II, PM - pectoral major muscle, pm - pectoral minor muscle, 3.R - the third rib, LA - local anesthesia, SA - serratus anterior muscle

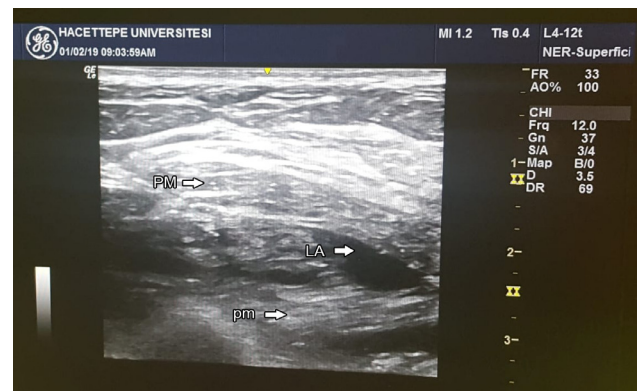


Figure 3 - PECs I block : The distribution of local anesthesia between pectoral major and pectoralis minor muscles. PECs I - pectoral nerve blocks I, PM - pectoral major muscle, pm - pectoral minor muscle, LA - local anesthesia

Following the axillary dissection, the en bloc resection technique was applied to remove the axillary lymph nodes and adipose tissue. The long thoracic and thoracodorsal nerves were identified and were carefully preserved. While the 2 surgical drains were being placed, she felt pain, and an additional 100 mg of prilocaine was administered to the site where the drains were located. The whole operating time was 110 minutes and 34 x 32 x 6 cm (2830 g) of breast tissue was excised. She was hemodynamically stable throughout the surgery.

Follow-up and outcomes. During the postoperative period, the vital signs were stable; there was no postoperative nausea and vomiting (PONV) with no additional need for analgesics. The visual analogue score (VAS) was 2. Analgesia was required for the first time 6 hours after the surgery had begun. She was discharged

Disclosure. The manuscript was presented as an oral presentation in the 16th National Regional Anesthesia Congress (Radkon 2019) in Izmir, Turkey, on 29 April 2019. The abstract was published in Radkon 2019 Book of abstract of the conference page 98.

<http://www.rad.org.tr/wpcontent/uploads/2019/05/Radkon2019-Bildiri-Kitab%C4%B1.pdf>

after 5 days without complications.

Discussion. Pectoral nerve blocks are a well known technique, similar to thoracic paravertebral and thoracic epidural blocks, that provide analgesia for patients undergoing breast cancer surgery.³ The thoracic paravertebral block is still recognized as the gold standard analgesic procedure for breast surgery. However, there can be consequential complications such as unintentional vascular injection, hypotension, intrathecal spread, epidural hematoma and nerve damage, which makes this procedure unsuitable for ambulatory breast surgery.^{3,4} Compared to other regional anesthetic techniques, the PECs blocks can be performed in the supine position, away from vital organs such as the spinal cord and pleura. If the patient is under GA, these blocks are easy, comfortable, and less complicated.

The medial and lateral branches of pectoral nerves are anesthetized by PECs I block that innervate these 2 muscles. The PECs I technique provides analgesia to pectoral muscles and is mainly used in breast expander and subpectoral breast prostheses operations. The PECs II block anesthetizes the thoracodorsal and long thoracic nerve, as well as the lateral branches of the intercostal nerves from T2-T6.⁵ In addition to the region under the pectoralis minor muscle, PECs II also provides analgesia to mammary glands and the skin from the T2-T6 dermatomes extending into the mid-axillary line by blocking the lateral intercostal nerves.⁴

Under extreme circumstances, a PECs block can be performed to provide postoperative analgesia under GA. In a recent study, GA without a PECs block and GA with a PECs block was compared.⁶ They found that the patients with a PECs block had less nausea, vomiting, and pain. Fewer patients have had PECs blocks as the sole anesthetic technique. Moon et al,⁴ reported on a successful breast surgery performed under PECs I and II blocks when a patient refused GA. Hong et al,⁷ reported on a pregnant woman who refused GA for breast surgery.

Campos et al,⁸ reported that a patient with several comorbidities and a high surgical risk, underwent a PECs II block as the exclusive anesthetic technique, similar to our patient. In the absence of visceral pain throughout the thoracic wall surgery, this block may be an effective and adequate option instead of GA. Our patient had an excellent anesthesia period; we only used local anesthesia for drain incision at the end of the procedure.

The main reason for selecting dexmedetomidine for sedation is that dexmedetomidine provides

sedation without respiratory depression. However, bradycardia and hypotension are common side effects of dexmedetomidine. During the procedure, the patient was hemodynamically stable without any bradycardia or hypotension. We started the induction of dexmedetomidine with a loading dose (1 µg/kg over 10 minutes), followed by 0.2 µg/kg/hour as a maintenance dose to maintain sedation without delayed recovery.

The potential benefits of RA and analgesia on long-term oncological outcomes are exciting. Regional anesthesia may reduce cancer progression by attenuating the surgical stress response, producing better analgesia, reducing opioid usage, and inhibiting cell migration.⁹ We need to have more robust and well conducted prospective randomized trials for studying the impact of RA on cancer recurrence and metastases in breast cancer surgeries.⁹

If adequate analgesia can be provided during breast surgery by RA, the occurrence of persistent breast cancer pain syndrome and phantom breast pain could be reduced. A meta-analysis and Cochrane review on persistent pain following breast surgery revealed that pre-operative regional blocks were effective at reducing subsequent chronic pain.¹⁰

Furthermore, high-quality studies are warranted to assess the impact of RA and analgesia on breast cancer surgery, not only on post-operative pain as the primary outcome, but also on other important outcomes such as chronic pain, phantom breast pain, nausea, and vomiting; this would potentially help in formulating plans for perioperative care of patients undergoing breast cancer surgeries. Ongoing randomized controlled trials to determine the impact of RA on oncological outcomes will provide definitive guidance in the future.

In conclusion, the use of a PECs block as the sole anesthetic in patients with multiple comorbidities may provide better analgesia, lesser side effects, reduced hemodynamic instability, and would be a safer option when compared to GA.

References

1. Cali CL, Biffoli F, Francesconi D, Petrella G, Buonomo O. Anesthesia and analgesia in breast surgery: the benefits of peripheral nerve block. *Eur Rev Med Pharmacol Sci* 2017; 21: 1341-1345.
2. Saied NN, Helwani MA, Weavind LM, Shi Y, Shotwell MS, Pandharipande PP. Effect of anaesthesia type on postoperative mortality and morbidities: a matched analysis of the NSQIP database. *Br J Anaesth* 2017; 118: 105-111.
3. Kulhari S, Bharti N, Bala I, Arora S, Singh G. Efficacy of pectoral nerve block versus thoracic paravertebral block for postoperative analgesia after radical mastectomy. *Br J Anaesth* 2016; 117: 382-386.

4. Moon EJ, Kim SB, Chung JY, Song JY, Yi JW. Pectoral nerve block (Pecs block) with sedation for breast conserving surgery without general anesthesia. *Ann Surg Treat Res* 2017; 9: 166-169.
5. Versyck B, Van Houwe P, Van Geffen GJ, Van de Velde M, Slappendel R. A qualitative systematic review of the pectoral nerves block type I and II. *Acta Anaesth Belg* 2017; 68: 49-62.
6. Bashandy GM, Abbas DN. Pectoral nerves I and II blocks in multimodal analgesia for breast cancer surgery: a randomized clinical trial. *Reg Anesth Pain Med* 2015; 40: 68-74.
7. Hong B, Yoon SH, Youn AM, Kim BJ, Song S, Yoon Y. Thoracic interfascial nerve block for breast surgery in a pregnant woman: a case report. *Korean J Anesthesiol*. 2017; 70: 209-212.
8. Campos M, Azevedo J, Mendes L, Rebelo H. Pectoral nerve block as a single anesthetic technique for breast surgery and sentinel lymph node investigation. *Rev Esp Anesthesiol Reanim* 2018; 65: 534-536.
9. Garg R. Regional anesthesia in breast cancer: Benefits beyond pain. *Indian J Anaesth* 2017; 61: 369-372.
10. Weinstein EJ, Levene JL, Cohen MS, Andreae DA, Chao JY, Johnson M et al. Local anaesthetics and regional anesthesia versus conventional analgesia for preventing persistent postoperative pain in adults and children. *Cochrane Database Syst Rev* 2018; 2018: CD007105.