

# Concurrent Tethered Cord Release and Growing-Rod Implantation—Is It Safe?

Jon E. Oda<sup>1,2</sup> Suken A. Shah<sup>2,3</sup> William G. Mackenzie<sup>2</sup> Behrooz A. Akbarnia<sup>3,4</sup> Muharrem Yazici<sup>3,5</sup>

<sup>1</sup>Department of Orthopaedic Surgery, Children's Hospital Central California, Madera, California

<sup>2</sup>Department of Orthopedics, Nemours/Alfred I. duPont Hospital for Children, Wilmington, Delaware

<sup>3</sup>Growing Spine Study Group, La Jolla, California

<sup>4</sup>San Diego Center for Spinal Disorders, La Jolla, California

<sup>5</sup>Department of Orthopaedic Surgery, Hacettepe University, Sıhhiye, Ankara, Turkey

**Address for correspondence and reprint requests** Suken A. Shah, MD, Nemours/Alfred I. duPont Hospital for Children, 1600 Rockland Road, Wilmington, DE 19899 (e-mail: sshah@nemours.org).

Global Spine J 2012;2:207–212.

## Abstract

**Study Design** Retrospective case series from one institution with a comparison control group.

**Objective** To evaluate the safety of concomitant tethered cord release and growing-rod insertion in individuals with early onset scoliosis.

**Methods** We retrospectively reviewed patients who underwent concurrent tethered cord release and growing-rod insertion. We compared our data to a comparison control group of eight patients who underwent staged tethered cord release and growing-rod insertion.

**Results** We identified three patients meeting criteria. There were no neurological complications in the three patients who underwent concomitant surgery. Average immediate postoperative curve correction was 43.3 degrees (47.6%). We identified seven patients who underwent staged surgery from a multicenter prospective database. No neurological complications were reported, and average immediate postoperative correction was 35.1 degrees (46.2%).

**Conclusion** We believe that concurrent tethered cord release and growing-rod insertion can be performed safely with the use of multimodality neurophysiological monitoring techniques.

## Keywords

- ▶ early onset scoliosis
- ▶ neurogenic scoliosis
- ▶ tethered cord
- ▶ spinal cord monitoring
- ▶ spinal growing rods

Individuals with early onset scoliosis (EOS) have been shown to have a high incidence of intraspinal abnormalities, including syringomyelia, Chiari malformation, diastematomyelia, and tethered cord.<sup>1–8</sup> Historically, patients with scoliosis associated with a tethered cord were treated in a staged fashion, with a tethered cord release first, followed by scoliosis correction 6 weeks to 6 months later, due to concerns of neurological injury.<sup>3,9–11</sup> Recent advances in neurophysiological monitoring techniques, however, have greatly increased the margin of safety for procedures with the potential for neurological injury.

Advantages of performing a tethered cord release concomitantly with growing-rod insertion include the following: single anesthetic exposure and single hospitalization, no surgical dissection through a traumatized area of the spine with a previous laminectomy, improved resource utilization and lower cost, and patient comfort and convenience. We have performed this combination of procedures on three patients with EOS and tethered cord; we found no neurological complications and found curve correction comparable to similar individuals undergoing staged procedures. It is our belief that,

received

May 24, 2012

accepted

October 15, 2012

published online

December 4, 2012

© 2012 Georg Thieme Verlag KG  
Stuttgart · New York

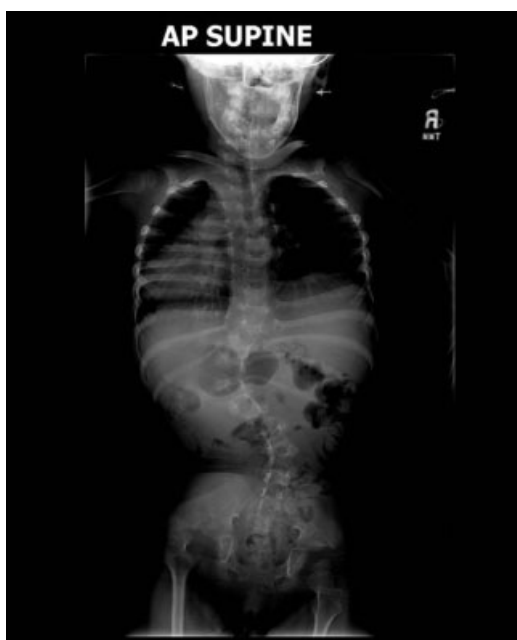DOI <http://dx.doi.org/10.1055/s-0032-1330941>.  
ISSN 2192-5682.

utilizing modern neuromonitoring techniques, tethered cord release and growing-rod insertion can be performed safely in individuals with EOS.

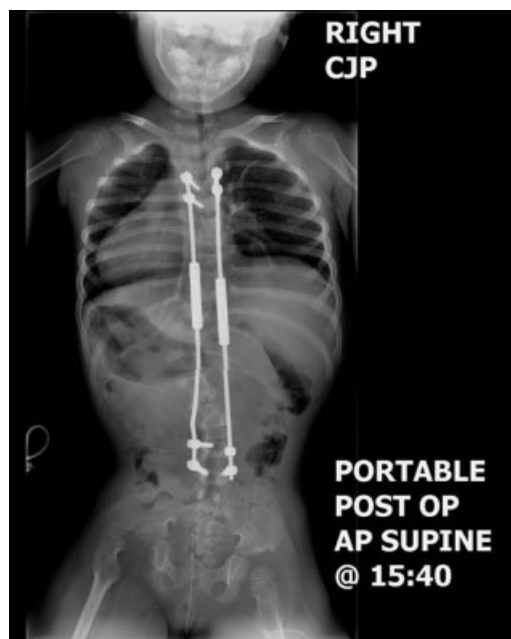
## Materials and Methods

This is a retrospective case series of all patients who underwent concomitant tethered cord release and growing-rod insertion with neurophysiological monitoring at our institution. Patients were included if they had a diagnosis of progressive EOS (congenital, infantile, juvenile) requiring either growing-rod or vertical expandable prosthetic titanium rib (VEPTR) treatment and a preoperative magnetic resonance imaging (MRI) scan documenting a tethered cord (→Figs. 1, 2). Exclusion criteria were multiple neural axis abnormalities (i.e., concomitant syringomyelia, Chiari malformation, diastematomyelia, or tumor) or the absence of distal neurological function (i.e., myelomeningocele). A tethered cord diagnosis was defined as the tip of the conus lying distal to the most caudal aspect of the second lumbar vertebra on preoperative MRI study. The surgical indication for tethered cord release in this series was based on radiographic criteria alone; clinical symptomatology was not a prerequisite. Given the clinical concern of lengthening the spinal column with growing-rod instrumentation, we believe that the spinal cord should be checked for a tether prior to lengthening in all EOS individuals with a low-lying conus.

Patients were positioned in the prone position on a radiolucent Jackson table over gel bolsters to allow the belly to hang freely. Neurophysiological monitoring modalities employed included somatosensory evoked potentials (SSEP), motor evoked potentials (MEP), and triggered electromyography (EMG) stimulation of neural elements and



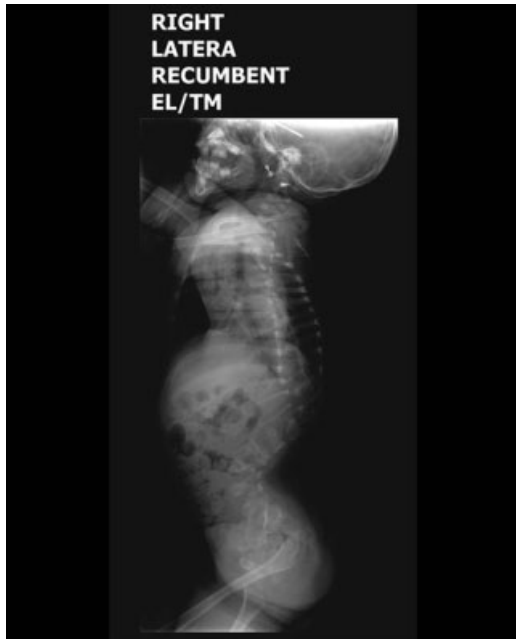**Fig. 1** Patient 2 preoperative supine anteroposterior view (90 degrees T11–L3). Abbreviation: AP, anteroposterior.



**Fig. 2** Patient 2 postoperative supine anteroposterior view (53 degrees T11–L3). Abbreviations: AP, anteroposterior; post op, postoperative.

pedicle screws. Fine needle electrodes were placed in bilateral upper- and lower-extremity musculature; anal sphincter fine needle leads also were placed to monitor sacral nerve root integrity. Patients were anesthetized only intravenously to avoid the use of inhaled halogenated anesthetic agents. Preoperative antibiotics were administered. Cord exploration and release were performed first by a pediatric neurosurgeon via an L5 or S1 laminectomy. Care was taken to minimize damage to the posterior vertebral structures, including the facet joints and interspinous ligament. The dura was opened, and the nerve roots and the thickened filum terminale were identified. To differentiate the fibrous cord tether from the surrounding nerve roots, we used triggered EMG via stimulating probe. In all cases, the spinal cord was noted to be under tension with a distinct fibrous tether. Once the fibrous cord was identified, it was cut, and the dura was closed. Dual submuscular growing-rod instrumentation was then placed by a pediatric orthopedic surgeon. Initial distraction of the growing-rod construct was performed gradually, over at least 10 minutes, under constant neurological surveillance. Distraction was not forceful, and we did not attempt maximal correction of the scoliosis. All patients were extubated immediately postoperatively and were admitted to the pediatric intensive care unit overnight for monitoring. All patients were allowed to be weight bearing as tolerated and encouraged to be out of bed as much as possible; the use of a postoperative brace was left to the operating surgeon's discretion (→Figs. 3, 4).

As a control comparison group, we queried the Growing Spine Study Group (GSSG; La Jolla, CA) for all patients with a tethered cord who had dual growing-rod instrumentation placed. The GSSG is a multicenter prospective database of patients with EOS undergoing surgical treatment of their

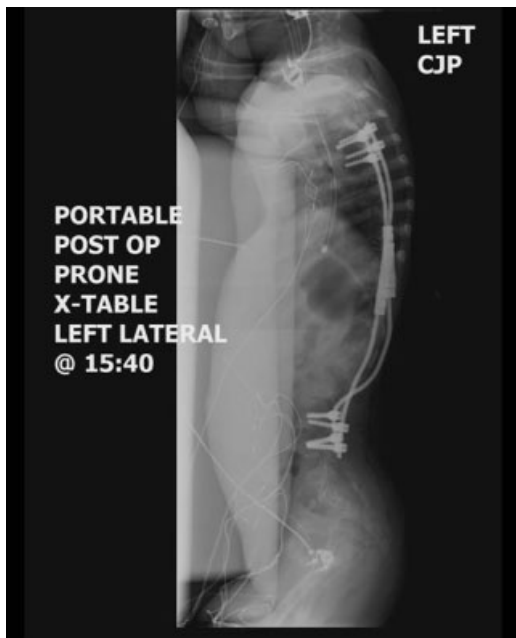

**Fig. 3** Patient 2 preoperative recumbent lateral view. Note thoracolumbar kyphosis.

scoliosis. Inclusion criteria were identical to the inclusion criteria of our study group.

**Results**

We identified three patients who met inclusion criteria for this study (►Table 1). All three patients had growing rods implanted; no patients with VEPTR instrumentation were



**Fig. 4** Patient 2 postoperative lateral view. Abbreviations: post op, postoperative.

**Table 1** Patient characteristics

Patient	Age at surgery (y)	Type of scoliosis	Comorbidities	Preoperative neurological baseline	Surgical procedures	Neuromonitoring	EBL	Preoperative curve magnitude	Immediate postoperative curve magnitude	Postoperative complications
1	7	Infantile	Partial sacral agenesis, VATER, TEF, developmental delay, hearing loss, GERD, asthma, short stature	Clinically no deficits	Tethered cord release via L5 laminectomy, PSF T3-T4 and L2-L3 with dual growing-rod insertion	Baseline SSEP with decreased posterior tibial nerve stimulation, normal baseline TcEMG, no change during procedures	80	90 T5-L2	36 T5-L2 (60% correction)	SIADH, resolved spontaneously
2	4	Infantile	Unknown skeletal dysplasia, cervical stenosis status post-C1 laminectomy	Neurogenic bladder, mildly increased tone left lower extremity	Tethered cord release via L5 laminectomy, PSF T3-T4 and L4-L5 with dual growing-rod insertion	Poor SSEPs but functioning bilateral TcMEP, no change during procedures	125	90 T11-L3	53 T11-L3 (41% correction)	None
3	6	Congenital, mixed type	Polycystic kidney, hip dysplasia treated previously in a Pavlik, restrictive lung disease, hemiatrophy	Clinically no deficits	Tethered cord release via S1 laminectomy, PSF T2-T3 and L3-L4 with dual growing-rod insertion	Baseline SSEP with decreased posterior tibial and ulnar nerve responses, normal TcMEP, no change during procedures	240	93 T7-L3	54 T7-L3 (42% correction)	None

Abbreviations: EBL, estimated blood loss; GERD, gastroesophageal reflux disease; PSF, posterior spinal fusion; SIADH, syndrome of inappropriate antidiuretic hormone; SSEP, somatosensory evoked potentials; TcEMG, transcranial electromyography; TcMEP, transcranial motor evoked potentials; TEF, tracheoesophageal fistula; VATER, vertebral anomalies, anal atresia, tracheoesophageal fistula, renal abnormalities.

identified that met the criteria. All surgeries were performed between 2006 and 2009. Patient characteristics are detailed in ► **Table 1**. All three patients were female, and they averaged 5.7 years of age. Two patients were classified as having infantile scoliosis, and one patient was classified as having congenital scoliosis; however, all three patients had multiple other comorbidities and would likely be considered as syndromic scoliosis. Only one of the three demonstrated preoperative neurological deficits. Of the two neurologically intact patients, both demonstrated subtle preoperative SSEP abnormalities, but neither had preoperative MEP abnormalities.

There were no intraoperative neurophysiological monitoring alerts, and there were no new postoperative neurological changes. Average estimated blood loss for both procedures was 148 mL. Postoperatively, patient 2 had improved bowel and bladder continence, according to the family. Preoperative curve magnitude averaged 91 degrees, and immediate postoperative curve magnitude averaged 47.7 degrees. We achieved an average of 43.3 degrees (47.6%) of correction with the dual growing-rod construct implantation.

Seven patients were identified from the GSSG who had both a tethered cord release and growing-rod instrumentation implanted. Multiple diagnoses were included, although myelodysplastic patients were excluded. All cases from the GSSG were performed in a staged fashion. No intraoperative or postoperative complications were reported. Average age at surgery was 6.1 years. Average immediate postoperative curve correction was 35.1 degrees (46.2% correction; average preoperative curve, 76.9 degrees; average postoperative curve, 41.7 degrees).

## Discussion

Treatment of EOS can be a challenging undertaking. Left untreated, progressive EOS curves have been associated with decreased thoracic volume, thoracic insufficiency syndrome, cor pulmonale, and mortality at a young age.<sup>12-20</sup> However, extensive spinal fusions at a young age, although generally successful at halting curve progression, impair vertebral column growth and can in themselves result in thoracic insufficiency and pulmonary complications in adulthood.<sup>21,22</sup> Winter<sup>23</sup> stated that the amount of spinal shortening from a spinal fusion in a growing child can be estimated by multiplying 0.7 mm × the number of fused segments × number of years of growth remaining. Studies have demonstrated that lung volume and number of alveoli continue to increase until age 8 years, and it has been recommended that spinal fusion be delayed until this age to optimize lung function.<sup>14</sup>

*Tethered cord syndrome* refers to the syndrome of motor and sensory dysfunction due to abnormally increased tension on the spinal cord. This can result from a variety of intraspinal pathologies, including spinal dysraphism, tumors, adhesions, scar formation, or a thickened and shortened filum terminale.<sup>24</sup> Clinical presentation is varied, but tethered cord syndrome should be suspected in children with midline cutaneous malformations, urologic disturbances, scoliosis, back pain, or motor/sensory disturbances. The study of choice

is MRI, which demonstrates both the nature and width of the filum terminale (> 2 mm is abnormal) as well as the level of the conus (L2 is the lower limit of normal). Treatment is surgical, consisting of release of the tethering component. Retethering is a common complication, requiring revision release.<sup>25</sup>

Patients with EOS have a high incidence of concurrent intraspinal abnormalities. Numerous studies have shown that 20 to 40% of children with either congenital,<sup>1-5</sup> infantile,<sup>6</sup> or juvenile<sup>7,8</sup> scoliosis have a spinal cord abnormality on preoperative MRI studies. Many of these will require neurosurgical intervention. In mild scoliotic deformities, correction of the neurosurgical abnormality may result in spontaneous curve correction,<sup>26</sup> but for those curves in the surgical range (> 40 degrees), spontaneous correction is rare.<sup>27-29</sup>

Multiple techniques have been attempted in an effort to control scoliosis curve progression while allowing continued spinal growth. Mehta,<sup>30,31</sup> Cotrel and Morel,<sup>32</sup> Risser,<sup>33</sup> and others<sup>34</sup> have advocated casting in a select population of infantile idiopathic scoliotic curves. Other techniques employed include the Milwaukee brace, Harrington rods, the Luque trolley, spinal hemiepiphysiodesis and stapling, the Shilla technique, and VEPTR. Recently, spinal growing-rod use has been advocated in multiple studies.<sup>35-38</sup> This involves proximal and distal short segment fusion and instrumentation with rods spanning the scoliotic segment. The rods are lengthened on a periodic (4- to 6-month) basis to accommodate for spinal growth. In a multicenter study, Akbarnia et al<sup>35</sup> reported a mean curve correction of 46 degrees with a mean 5-cm increase in spinal height. Thompson et al<sup>38</sup> reported good results with both single- and dual-rod constructs. The addition of a short apical fusion was associated with lesser curve correction and an increased complication rate.

Scoliosis correction with concomitant intraspinal abnormalities has historically been associated with a high risk of neurological injury<sup>9,39-42</sup>; thus, intraspinal abnormality correction and scoliosis correction have been performed in a staged fashion. In 1984, McMaster<sup>3</sup> stated unequivocally, "I strongly recommend . . . that all intraspinal abnormalities be treated surgically before any more effective method of correction of scoliosis, such as Harrington instrumentation, is applied" (p. 600). Cardoso and Keating<sup>10</sup> wrote in a recent review article, "It is recommended to wait at least 4 to 6 months after the intraspinal surgery before proceeding with spinal instrumentation" (p. 1780). Recommendations for staged procedures have been based on the theoretical concerns of cord stretching during correction maneuvers with distraction-based instrumentation and decreased spinal cord tolerance to injury due to a double insult.<sup>3,9,11</sup> The disadvantages of staged surgery, however, include multiple anesthetic exposures, increased infection risk, potential repeat surgical dissection in an area with a previous laminectomy, and patient discomfort and inconvenience.

Real-time monitoring of spinal cord integrity via SSEP and transcranial MEP confers the ability to immediately detect and potentially reverse any maneuvers that offend neurological structures. Neurophysiological monitoring has a very high sensitivity for spinal cord injury with regards to both

deformity correction<sup>43</sup> and tethered cord release.<sup>44–46</sup> Paradiso et al<sup>45</sup> reported a 100% sensitivity of continuous EMG in their analysis of 44 adult patients undergoing tethered cord release. Other authors have reported their experiences with concomitant neurosurgical and orthopedic procedures. Hamzaoglu et al<sup>47</sup> retrospectively reviewed 21 consecutive patients with congenital scoliosis or kyphosis and intraspinal abnormalities who underwent simultaneous neurosurgical correction of the intraspinal abnormality and posterior spinal fusion. Intraspinal pathologies, as well as the type of posterior surgery (short segment fusion, long fusion, hemivertebrae resection), were mixed. No subjects in their study sustained a neurological injury with simultaneous neurosurgical and orthopedic intervention, despite the lack of neurophysiological monitoring. Hedequist et al<sup>48</sup> similarly did not report any neurological complications in two patients undergoing simultaneous detethering and spinal instrumentation. Samdani et al<sup>49</sup> published their experience with one patient who successfully underwent tethered cord release and posterior spinal fusion from T2 to the pelvis for a 65-degree thoracic and 80-degree lumbar scoliosis. Sankar et al<sup>50</sup> recently reported on a GSSG survey of 569 growing-rod surgeries performed with neurophysiological monitoring (231 implantations, 116 implant exchanges, and 222 lengthenings). Four patients had intraoperative neuromonitoring changes with no permanent neurological injury.

We believe that simultaneous tethered cord release and EOS curve correction can be undertaken safely with the use of modern neuromonitoring techniques. To our knowledge, this is the first report of simultaneous tethered cord release and growing-rod insertion. We were able to perform this combination of procedures with a mean curve correction of 43 degrees (47%) and no adverse neurological events. The corrections that we were able to obtain are comparable to the results reported by Akbarnia et al<sup>35</sup> as well as a matched comparison control group identified from the GSSG. We theorize that, in addition to the benefits of one less-invasive surgical procedure (decreased anesthetic exposure, decreased risk of infection, decreased blood loss, improved resource utilization), combination surgery may decrease the incidence of retethering, the most common complication of tethered cord release; although, at this point, we have no data to substantiate this hypothesis. This is a retrospective study, with all its inherent weaknesses, and our numbers are small. Further studies with larger numbers are necessary to further define the efficacy and safety of simultaneous surgery. We recommend that combination neurosurgical/orthopedic procedures only be performed under multimodality neurophysiological monitoring and that the amount of distraction applied to the growing-rod construct be slow and modest. If neurological deterioration is noted at any point in the procedure, conversion to a staged procedure is recommended.

#### Acknowledgments

We would like to acknowledge the Growing Spine Study Group for providing the data on staged tethered cord release and growing-rod insertion.

#### Note

Study conducted at Nemours/Alfred I. duPont Hospital for Children, Department of Orthopedic Surgery. No sources of support were provided for this study from National Institutes of Health, Wellcome Trust, Howard Hughes Medical Institute, nor other(s). Institutional Review Board approval was granted for the retrospective review of medical charts.

#### Disclosures

Jon E. Oda, None

Suken A. Shah, Consulting: DePuy Synthes Spine; Royalties: DePuy Synthes Spine; Research Support: Growing Spine Foundation, Setting Scoliosis Straight Foundation; Stock/Options: Globus Medical, K Spine William G. Mackenzie, Consulting: Biomarin; Board of Directors: Pediatric Orthopaedic Society of North America Behrooz A. Akbarnia, None

Muharrem Yazici, Consulting: K2M, DePuy Synthes

#### References

- Belmont PJ Jr, Kuklo TR, Taylor KF, Freedman BA, Prahinski JR, Kruse RW. Intraspinal anomalies associated with isolated congenital hemivertebra: the role of routine magnetic resonance imaging. *J Bone Joint Surg Am* 2004;86-A:1704–1710
- Bradford DS, Heithoff KB, Cohen M. Intraspinal abnormalities and congenital spine deformities: a radiographic and MRI study. *J Pediatr Orthop* 1991;11:36–41
- McMaster MJ. Occult intraspinal anomalies and congenital scoliosis. *J Bone Joint Surg Am* 1984;66:588–601
- Prahinski JR, Polly DW Jr, McHale KA, Ellenbogen RG. Occult intraspinal anomalies in congenital scoliosis. *J Pediatr Orthop* 2000;20:59–63
- Suh SW, Sarwark JF, Vora A, Huang BK. Evaluating congenital spine deformities for intraspinal anomalies with magnetic resonance imaging. *J Pediatr Orthop* 2001;21:525–531
- Dobbs MB, Lenke LG, Szymanski DA, et al. Prevalence of neural axis abnormalities in patients with infantile idiopathic scoliosis. *J Bone Joint Surg Am* 2002;84-A:2230–2234
- Evans SC, Edgar MA, Hall-Craggs MA, Powell MP, Taylor BA, Noordeen HH. MRI of “idiopathic” juvenile scoliosis. A prospective study. *J Bone Joint Surg Br* 1996;78:314–317
- Gupta P, Lenke LG, Bridwell KH. Incidence of neural axis abnormalities in infantile and juvenile patients with spinal deformity. Is a magnetic resonance image screening necessary? *Spine* 1998; 23:206–210
- Winter RB. Neurologic safety in spinal deformity surgery. *Spine* 1997;22:1527–1533
- Cardoso M, Keating RF. Neurosurgical management of spinal dysraphism and neurogenic scoliosis. *Spine* 2009;34: 1775–1782
- Ayvaz M, Alanay A, Yazici M, Acaroglu E, Akalan N, Aksoy C. Safety and efficacy of posterior instrumentation for patients with congenital scoliosis and spinal dysraphism. *J Pediatr Orthop* 2007;27: 380–386
- Boffa P, Stovin P, Shneerson J. Lung developmental abnormalities in severe scoliosis. *Thorax* 1984;39:681–682
- Branthwaite MA. Cardiorespiratory consequences of unfused idiopathic scoliosis. *Br J Dis Chest* 1986;80:360–369
- Campbell RM Jr, Smith MD, Mayes TC, et al. The characteristics of thoracic insufficiency syndrome associated with fused ribs

- and congenital scoliosis. *J Bone Joint Surg Am* 2003;85-A:399-408
- 15 Charles YP, Dimeglio A, Marcoul M, Bourgin JF, Marcoul A, Bozonat MC. Volumetric thoracic growth in children with moderate and severe scoliosis compared to subjects without spinal deformity. *Stud Health Technol Inform* 2008;140:22-28
  - 16 Davies G, Reid L. Effect of scoliosis on growth of alveoli and pulmonary arteries and on right ventricle. *Arch Dis Child* 1971;46:623-632
  - 17 Muirhead A, Conner AN. The assessment of lung function in children with scoliosis. *J Bone Joint Surg Br* 1985;67:699-702
  - 18 Pehrsson K, Larsson S, Oden A, Nachemson A. Long-term follow-up of patients with untreated scoliosis. A study of mortality, causes of death, and symptoms. *Spine* 1992;17:1091-1096
  - 19 Scott JC, Morgan TH. The natural history and prognosis of infantile idiopathic scoliosis. *J Bone Joint Surg Br* 1955;37-B:400-413
  - 20 Swank SM, Winter RB, Moe JH. Scoliosis and cor pulmonale. *Spine* 1982;7:343-354
  - 21 Goldberg CJ, Gillic I, Connaughton O, et al. Respiratory function and cosmesis at maturity in infantile-onset scoliosis. *Spine* 2003;28:2397-2406
  - 22 Akbarnia BA. Management themes in early onset scoliosis. *J Bone Joint Surg Am* 2007;89(Suppl 1):42-54
  - 23 Winter RB. Scoliosis and spinal growth. *Orthop Rev* 1977;7:17
  - 24 Lew SM, Kothbauer KF. Tethered cord syndrome: an updated review. *Pediatr Neurosurg* 2007;43:236-248
  - 25 Archibeck MJ, Smith JT, Carroll KL, Davitt JS, Stevens PM. Surgical release of tethered spinal cord: survivorship analysis and orthopedic outcome. *J Pediatr Orthop* 1997;17:773-776
  - 26 Haberl H, Tallen G, Michael T, Hoffmann KT, Benndorf G, Brock M. Surgical aspects and outcome of delayed tethered cord release. *Zentralbl Neurochir* 2004;65:161-167
  - 27 Flynn JM, Sodha S, Lou JE, et al. Predictors of progression of scoliosis after decompression of an Arnold Chiari I malformation. *Spine* 2004;29:286-292
  - 28 McLone DG, Herman JM, Gabrieli AP, Dias L. Tethered cord as a cause of scoliosis in children with a myelomeningocele. *Pediatr Neurosurg* 1990-1991;16:8-13
  - 29 Pierz K, Banta J, Thomson J, Gahm N, Hartford J. The effect of tethered cord release on scoliosis in myelomeningocele. *J Pediatr Orthop* 2000;20:362-365
  - 30 Mehta MH. Growth as a corrective force in the early treatment of progressive infantile scoliosis. *J Bone Joint Surg Br* 2005;87:1237-1247
  - 31 Mehta MH. The rib-vertebra angle in the early diagnosis between resolving and progressive infantile scoliosis. *J Bone Joint Surg Br* 1972;54:230-243
  - 32 Cotrel Y, Morel G. [The elongation-derotation-flexion technic in the correction of scoliosis]. *Rev Chir Orthop Repar Appar Mot* 1964;50:59-75
  - 33 Risser JC. Scoliosis treated by cast correction and spine fusion. *Clin Orthop Relat Res* 1976;(116):86-94
  - 34 D'Astous JL, Sanders JO. Casting and traction treatment methods for scoliosis. *Orthop Clin North Am* 2007;38:477-484, v
  - 35 Akbarnia BA, Marks DS, Boachie-Adjei O, Thompson AG, Asher MA. Dual growing rod technique for the treatment of progressive early-onset scoliosis: a multicenter study. *Spine* 2005;30(17, Suppl):S46-S57
  - 36 Akbarnia BA, Breakwell LM, Marks DS, et al; Growing Spine Study Group. Dual growing rod technique followed for three to eleven years until final fusion: the effect of frequency of lengthening. *Spine* 2008;33:984-990
  - 37 Thompson GH, Akbarnia BA, Campbell RM Jr. Growing rod techniques in early-onset scoliosis. *J Pediatr Orthop* 2007;27:354-361
  - 38 Thompson GH, Akbarnia BA, Kostial P, et al. Comparison of single and dual growing rod techniques followed through definitive surgery: a preliminary study. *Spine* 2005;30:2039-2044
  - 39 Ozerdemoglu RA, Transfeldt EE, Denis F. Value of treating primary causes of syrinx in scoliosis associated with syringomyelia. *Spine* 2003;28:806-814
  - 40 Potenza V, Weinstein SL, Neyt JG. Dysfunction of the spinal cord during spinal arthrodesis for scoliosis: recommendations for early detection and treatment. A case report. *J Bone Joint Surg Am* 1998;80:1679-1683
  - 41 MacEwen GD, Bunnell WP, Sriram K. Acute neurological complications in the treatment of scoliosis. A report of the Scoliosis Research Society. *J Bone Joint Surg Am* 1975;57:404-408
  - 42 Acaroğlu E, Alanay A, Akalan N, Atilla B, Bulutçu E, Surat A. Risk factors associated with corrective surgery in congenital scoliosis with tethered cord. *Turk J Pediatr* 1997;39:373-378
  - 43 Schwartz DM, Auerbach JD, Dormans JP, et al. Neurophysiological detection of impending spinal cord injury during scoliosis surgery. *J Bone Joint Surg Am* 2007;89:2440-2449
  - 44 Lee GY, Paradiso G, Tator CH, Gentili F, Massicotte EM, Fehlings MG. Surgical management of tethered cord syndrome in adults: indications, techniques, and long-term outcomes in 60 patients. *J Neurosurg Spine* 2006;4:123-131
  - 45 Paradiso G, Lee GY, Sarjeant R, Hoang L, Massicotte EM, Fehlings MG. Multimodality intraoperative neurophysiologic monitoring findings during surgery for adult tethered cord syndrome: analysis of a series of 44 patients with long-term follow-up. *Spine* 2006;31:2095-2102
  - 46 Paradiso G, Lee GY, Sarjeant R, Fehlings MG. Multi-modality neurophysiological monitoring during surgery for adult tethered cord syndrome. *J Clin Neurosci* 2005;12:934-936
  - 47 Hamzaoglu A, Ozturk C, Tezer M, Aydogan M, Sarier M, Talu U. Simultaneous surgical treatment in congenital scoliosis and/or kyphosis associated with intraspinal abnormalities. *Spine* 2007;32:2880-2884
  - 48 Hedequist DJ, Hall JE, Emans JB. The safety and efficacy of spinal instrumentation in children with congenital spine deformities. *Spine* 2004;29:2081-2086; discussion 2087
  - 49 Samdani AF, Asghar J, Pahys J, D'Andrea L, Betz RR. Concurrent spinal cord untethering and scoliosis correction: case report. *Spine* 2007;32:E832-E836
  - 50 Sankar WN, Skaggs DL, Emans JB, et al. Neurologic risk in growing rod spine surgery in early onset scoliosis: is neuromonitoring necessary for all cases? *Spine* 2009;34:1952-1955