

Comparative effects of methylprednisolone and tetracosactide (ACTH₁₋₂₄) on ischemia/reperfusion injury of the rabbit spinal cord

Hayri Kertmen¹, Erhan Celikoglu², Ozden Caglar Ozturk³, Bora Güner², Huseyin Bozkurt⁴, Mehmet Ali Kanat⁵, Ata Turker Arikok⁶, Berrin Imge Erguder⁷, Mustafa Fevzi Sargon⁸, Zeki Sekerci⁹

¹Neurosurgery Clinic, Diskapi Yildirim Beyazit Education and Research Hospital, Ministry of Health, Ankara, Turkey

²Neurosurgery Clinic, Fatih Sultan Mehmet Education and Research Hospital, Ministry of Health, Istanbul, Turkey

³Neurosurgery Clinic, Mardin Nusaybin State Hospital, Ministry of Health, Mardin, Turkey

⁴Department of Neurosurgery, Faculty of Medicine, Cumhuriyet University, Sivas, Turkey

⁵Refik Saydam National Public Health Agency, Ministry of Health, Ankara, Turkey

⁶Department of Pathology, Diskapi Yildirim Beyazit Education and Research Hospital, Ministry of Health, Ankara, Turkey

⁷Department of Biochemistry, Faculty of Medicine, Ankara University, Ankara, Turkey

⁸Department of Anatomy, Faculty of Medicine, Hacettepe University, Ankara, Turkey

⁹Neurosurgery Clinic, Diskapi Yildirim Beyazit Education and Research Hospital, Ministry of Health, Ankara, Turkey

Corresponding author:

Bora Güner MD
Neurosurgery Clinic
Fatih Sultan Mehmet
Education and
Research Hospital
Ministry of Health
06110 Ankara, Turkey
Phone: +90 5063164201
Fax: +90 3123186690
E-mail: boraguner@gmail.com

Submitted: 17 July 2016

Accepted: 17 September 2016

Arch Med Sci 2018; 14, 6: 1459–1470

DOI: <https://doi.org/10.5114/aoms.2017.65650>

Copyright © 2017 Termedia & Banach

Abstract

Introduction: Tetracosactide is an engineered peptide that applies the same biological impacts as the endogenous adrenocorticotrophic hormone. Previous studies indicated that tetracosactide has anti-inflammatory, antioxidant and neurotrophic activity. In this study, we hypothesized that tetracosactide may have protective effects in spinal cord ischemia-reperfusion injury.

Material and methods: Rabbits were randomized into the accompanying four groups of eight animals each: group 1 (control), group 2 (ischemia), group 3 (methylprednisolone) and group 4 (tetracosactide). In the control group, just a laparotomy was performed. In the various groups, the spinal cord ischemia model was made by the impediment of the aorta only caudal to the renal vein. Neurological assessment was conducted with the Tarlov scoring system. Levels of myeloperoxidase, malondialdehyde and catalase were analyzed, similar to the activities of xanthine oxidase and caspase-3. Histopathological and ultrastructural assessments were additionally performed.

Results: After ischemia-reperfusion injury, increments were found in the tissue myeloperoxidase levels ($p < 0.001$), malondialdehyde levels ($p < 0.001$), xanthine oxidase action ($p < 0.001$) and caspase-3 movement ($p < 0.001$). Conversely, both serum and tissue catalase levels were diminished ($p < 0.001$ for both). After the administration of tetracosactide, declines were seen in the tissue myeloperoxidase levels ($p < 0.001$), malondialdehyde levels ($p = 0.003$), xanthine oxidase action ($p < 0.001$) and caspase-3 movement ($p < 0.001$). Conversely, both the serum and tissue catalase levels were expanded ($p < 0.001$). Besides, tetracosactide treatment indicated enhanced results related to the histopathological scores ($p < 0.001$), the ultra-structural score ($p = 0.008$) and the Tarlov scores ($p < 0.001$).

Conclusions: The findings showed for the first time that tetracosactide shows significant neuroprotective activity against ischemia-reperfusion injury of the spinal cord.

Key words: adrenocorticotrophic hormone, ischemia-reperfusion, methylprednisolone, neuroprotection, spinal cord, tetracosactide.

Introduction

Following thoracoabdominal surgery, spinal cord ischemia/reperfusion (I/R) injury is one of the most catastrophic complications and can lead to paraplegia in up to 40% of patients [1]. The exact underlying mechanism of the spinal cord I/R injury remains uncertain; inflammation is known to play an important role [2–5]. Actuation of neutrophils and oxidative stress lead to the generation of reactive oxygen species (ROS), causing inflammation, lipid peroxidation and DNA injury [6, 7]. Optimal neuroprotection is the cornerstone for protecting the spinal cord from I/R injury, and a large portion of the past studies are in favor of utilization of mitigating medications to protect the spinal cord from I/R damage [3, 8, 9].

The most common pharmacologic treatment to prevent the spinal cord from I/R injury is the use of steroids [10]. Steroids, especially methylprednisolone (MP), have been broadly considered for spinal cord I/R injury in animal studies, and those studies support the use of MP to attenuate spinal cord I/R injury [2, 3, 9, 11].

Tetracosactide is a manufactured peptide that applies the same natural impacts as the endogenous adrenocorticotrophic hormone (ACTH) delivered by the anterior pituitary [12]. Like ACTH, tetracosactide prompts the combination of glucocorticoids, mineralocorticoids and, to a lesser degree, androgens by the adrenal gland. Previous studies indicated that tetracosactide has a peculiar anti-inflammatory activity [13–16]. In many experimental conditions, ACTH has been shown to inhibit inflammation, such as brain inflammation and ischemia, arthritis, and myocardial ischemia [13–15]. Furthermore, ACTH had been reported to prevent the burst of ROS generation during tissue reperfusion [13, 17].

There are have been no previous studies investigating the neuroprotective impacts of tetracosactide in spinal cord I/R damage. In light of these outcomes, the motivation behind this research was to assess whether tetracosactide treatment could shield the spinal cord from I/R damage and compare the outcomes with MP, which has been broadly considered for spinal cord I/R injury.

Material and methods

Experimental groups

Animal care and all investigations were conducted in accordance with the European Communities Council Directive of November 24, 1986 (86/609/EEC) concerning the assurance of protection of animals for exploratory use. Every trial system utilized as part of this study was investigated and endorsed by the moral board of trustees of the Ministry of Health Ankara Education and Research

Hospital Committee of Animal Ethics. Thirty-two adult male New Zealand white rabbits, weighing 2 550–3 300 g, were arbitrarily separated into the following four groups of eight rabbits each:

- Group 1: Control group ($n = 8$): laparotomy only. Rabbits underwent laminectomy, and non-ischemic spinal cord samples were obtained instantly after the surgery. No treatment was given to this group.
- Group 2: Ischemia group ($n = 8$). Rabbits underwent transient global spinal cord ischemia. The same volume of saline (0.9% NaCl) was infused intravenously instantly after the occlusion clamp was evacuated. The animals then underwent laminectomy, and spinal cord samples were evacuated 24 h post-ischemia.
- Group 3: Methylprednisolone (MP) group ($n = 8$). Treated like group 2, but the rabbits received a single intravenous dose of 30 mg/kg MP (Prednol, Mustafa Nevzat, Turkey) quickly after the occlusion clamp was evacuated. This dosage of the MP was chosen taking into account previous studies [2, 3, 11].
- Group 4: Tetracosactide (ACTH) group ($n = 8$). Treated in the same way as group 2, but the rabbits were just given one intravenous 0.5 mg/kg dose of tetracosactide (Synacthen Depot, Novartis, Switzerland) promptly after the occlusion clamp was uprooted. This dosage of tetracosactide was chosen keeping in mind previous research [13, 18, 19].

Anesthesia and surgical procedures

The animals were kept at an ideal room temperature (18–21°C), on a standard routine diet and kept under a 12-h light-dark cycle. Free access to sustenance and water was given. The animals were anesthetized by an intramuscular dose of 70 mg/kg ketamine (Ketalar, Parke Davis Eczacıbaşı, Turkey) and 5 mg/kg xylazine (Rompun, Bayer, Turkey) and permitted to inhale spontaneously. Body temperatures were measured using an anal thermometer (Digital Fever thermometer, Becton Dickinson, NJ, USA) and kept up at 37°C with a warming cushion. Animals were placed in the supine position for the surgery. After sterile arrangement, a 10-cm midline incision was made, and the abdominal aorta was approached through a transperitoneal route. Heparin (150 U/kg) was administered intravenously 5 min before clamping for anticoagulation. Around 1 cm beneath the renal artery, the aorta was clipped using an aneurysm clip with 70 g of closing force (Yasargil, FE721, Aesculap, Germany) under a surgical microscope. The cross clamping time was 20 min. At the end of the occlusion period, the clamps were removed and restoration of the blood stream was visually checked. The medications were adminis-

tered intravenously after the clamp was removed. The rabbit aortic cross-clamping technique, which was used as part of this study, is a valuable system for these strategies [2, 3, 11, 20, 21]. The 20 min ischemia period gave satisfactory damage [22]. The rabbits were permitted free access to food and water 2 hours after surgery. Crede's maneuver was performed on animals with a neurogenic bladder at least two times each day. The animals were sacrificed 24 h after the operation by infusion of high-dose pentobarbital (200 mg/kg). Spinal cord fragments between the L2 and L5 levels were precisely uprooted by laminectomy and used for the biochemical, histopathological and ultrastructural investigations. Blood (10 cc) was taken from the left ventricle for biochemical examination. The blood samples were centrifuged at 1000 g for 5 min, and the upper clear supernatants were used for analysis. All serum and tissue tests were stored at -80°C until studied. On the day of the analysis, the tissues were homogenized in physiologic saline solution and centrifuged at 1780 g for 20 min. The serum samples acquired as the upper clear supernatants of the centrifuged blood were used for the biochemical examinations. The study design is summarized in Figure 1.

Tissue myeloperoxidase (MPO) analysis

The MPO activity was measured using an ELISA kit (Cusabio, Hubei, China). The ELISA procedures were performed according to the manufacturer's instructions. This assay uses the competitive inhibition enzyme immunoassay technique. The microtiter plate provided in this kit was pre-covered with an antibody specific to MPO. Standards or samples were added to the appropriate microtiter plate wells with biotin-conjugated MPO. A competitive inhibition reaction was started between the MPO (from the standards or the samples) and the biotin-conjugated MPO with the pre-coated antibody specific for MPO. With greater amounts of MPO in the examples, lower amounts of antibodies are bound by the biotin-conjugated MPO. After washing, avidin-conjugated horseradish peroxidase was added to the wells. The substrate solution was then included, and the color developed to show the amount of MPO in the example. At the point when color development stopped, the intensity of the color was measured at 450 nm. The MPO concentrations were calculated by contrasting the absorbance estimations of the samples with those of standard MPO solutions. The results are presented in ng/ml.

Tissue malondialdehyde (MDA) analyses

Tissue MDA levels were determined using a strategy in light of reaction with thiobarbituric

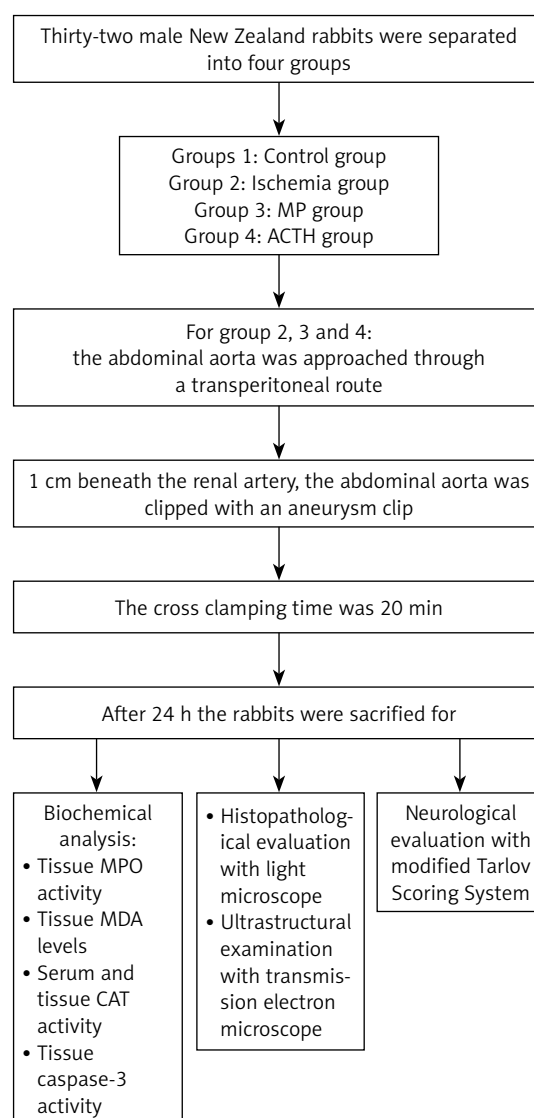


Figure 1. Flow diagram showing the study design

acid (TBA). Briefly, the specimens were blended with two volumes of cold saline liquid containing 0.001% butylated hydroxytoluene (BHT) and 0.07% sodium dodecyl sulfate (SDS). At that point, 1 ml of the samples was added to 500 μl of 0.01 μl NH_2SO_4 and 500 μl of the TBA reagent (0.67% TBA in half acidic corrosive) to precipitate protein. At that point, the specimens were warmed in boiling water for an hour. After cooling, an equivalent volume (2 ml) of n-butanol was added to each test tube and mixed. The mixture was centrifuged at 1780 g for 10 min at room temperature. The absorbance of the organic layer was read at 535 nm in a 1 ml cell (Molecular Devices Corporation, Sunnyvale, CA, USA). The MDA concentrations were determined by comparing the absorbance values of the samples with those of standard MDA solutions. The MDA concentrations are expressed in nmoles per gram of wet weight tissue.

Serum and tissue catalase (CAT) analyses

Catalase activity was determined by measuring the absorbance decrease rate of hydrogen peroxide (H₂O₂) at 240 nm. In the activity calculations, an extinction coefficient of H₂O₂ was used for CAT. The results are given in IU/ml.

Serum xanthine oxidase (XO) analyses

Serum XO activity was measured by the technique of Prajda and Weber [23], where activity is measured by the determination of the amount of uric acid formed from xanthine. Serum samples (100 µl) were incubated for 30 min at 37°C in 3 ml of the phosphate buffer (pH 7.5, 50 mM) containing xanthine (4 mM). The reaction was halted by the addition of 0.1 ml 100% (w/v) TCA, and the mixture was then centrifuged at 1780 g for 20 min. Uric acid level was determined in the supernatant by measuring the absorbance at 292 nm against a blank and presented as mIU/ml. A calibration curve was constructed using 10–50 mIU/ml concentrations of standard XO solutions (Sigma X-1875, Sigma-Aldrich, St. Louis, MO). One unit of activity was defined as 1 µmol of uric acid formed per minute at 37°C and pH 7.5.

Tissue caspase-3 activities

Caspase-3 activity was measured using an ELISA kit (Cusabio, Hubei, China). The ELISA procedures were performed in accordance with the producer's guidelines. This test uses the quantitative sandwich protein immunoassay procedure. Antibodies specific for caspase-3 had been pre-coated onto a microplate. Standards and samples were pipetted into the wells, and the immobilized antibody bound any caspase-3 present. After evacuation of any unbound substances, a biotin-conjugated antibody specific for caspase-3 was added to the wells. After washing, avidin-conjugated horseradish peroxidase was added to the wells. Any unbound substances had been evacuated by the three washes with washing buffer. After the washing procedure, the avidin-protein reagent was added to the wells. The color develops in extent to the measure of caspase-3 bound in the beginning step. At the point when the color improvement stopped, the intensity of the color was measured at 450 nm. Caspase-3 concentrations were ascertained by comparing the absorbance values of the samples with those of standard caspase-3 solutions. The results are expressed in ng/ml.

Histopathological procedures

The spinal cord samples obtained at 24 h post-injury were prepared for histological study. Each cord section was submerged in 4% para-

formaldehyde in 0.1 mol/l phosphate buffer and stored at 4°C. The examples were then embedded in paraffin, cut into 5 µm thick sections and stained with hematoxylin-eosin (H&E). The examples were inspected under a light microscope by a neuropathologist, who was blinded to the study plan. Five distinct fields of the gray matter of the spinal cord were assessed using a 40× objective.

A semi-quantitative scoring system, ranging between 0 and 3, was used to evaluate the histopathological changes in the spinal cord tissues of all examples. Six distinct parameters (hemorrhage, congestion, necrosis, edema, neuronal loss and inflammation) were evaluated histopathologically and were scored as: 0 = negligible, 1 = mild, 2 = moderate and 3 = common. The histopathology score for every spinal cord sample was ascertained by averaging the scores of these six parameters.

Furthermore, a more point-by-point appraisal of the level of ischemic neuronal injury was likewise performed. For this investigation, the quantity of typical motor neurons in the anterior horn of the spinal cord (anterior to a line drawn through the central canal perpendicular to the vertebral axis) was counted. For every animal, three areas were assessed using a 40× objective. An average normal motor neuron count for the areas from every animal was then decided. Neurons that contained Nissl substances in the cytoplasm, loose chromatin and prominent nucleoli were considered as normal viable neurons [24].

Ultrastructural examinations

Tissue samples were cleared of blood using a surgical blade, and the meninges were precisely removed. The tissue samples were then altered in 2.5% glutaraldehyde for 24 h, followed by washing in phosphate support (pH = 7.4). They were next post-fixed in 1% osmium tetroxide in phosphate buffer (pH = 7.4) for 2 h and were dehydrated with expanding concentrations of alcohol. At that point, the tissues were washed with propylene oxide and embedded in epoxy-resin embedding media. Semi-thin sections around 2 µm thick and ultra-thin sections approximately 60 nm thick were cut with a glass blade on an LKB-Nova ultra microtome (LKB-Produkter AB, Bromma, Sweden). The semi-thin sections were stained with methylene blue and analyzed with a Nikon Optiphot (Nikon Corporation, Tokyo, Japan) light microscope. Taken after this examination, the tissue blocks were trimmed, and ultra-thin sections were made using the same ultra microtome; these segments were stained with uranyl acetic acid and lead citrate. After staining, all of the ultra-thin sections were analyzed with a Jeol JEM 1200 EX (Jeol Ltd., Tokyo, Japan) transmission electron microscope. The elec-

tron micrographs were taken by the same transmission electron microscope at 5000× amplification. A total of 100 large myelinated axons, 100 medium-sized myelinated axons and 100 small myelinated axons were assessed for each example, scored from 0 to 3, and counted, and the data are exhibited as the mean values, as portrayed by Kaptanoğlu *et al.* [25].

The scoring system was as follows: 0: ultra-structurally normal myelinated axon, 1: separation in myelin configuration, 2: interruption in myelin configuration, 3: honeycomb appearance in myelin configuration.

Neurologic evaluations

The neurologic statuses of the animals were scored 24 h after the technique by evaluating hind-limb neurologic function using the modified Tarlov scoring system [2, 26]. A score of 0 to 5 was relegated to every animal: 0 = no voluntary hind-limb movement, 1 = movement of joints perceptible, 2 = active movement but not able to sit without help, 3 = able to sit but not able to hop, 4 = week hop and 5 = complete recovery of hind-limb function. A medical doctor blinded to the experimental groups performed the neurologic assessments.

Statistical analysis

Data analysis was performed using SPSS for Windows, variant 11.5 (SPSS Inc., Chicago, IL, United States). Whether the continuous variables were normally distributed was determined by the Shapiro-Wilk test. The Levene test was used for assessment of the homogeneity of the variances. Where applicable, the data are presented as the means \pm standard deviation or the medians (IQR). The mean differences among groups were analysed using one-way ANOVA. Otherwise, the Kruskal-Wallis test was applied for comparison of the median values. At the point when the *p*-value from the one-way ANOVA or the Kruskal-Wallis test was statistically significant, post hoc Tukey HSD or Conover's non-parametric comparison tests were used to assess the differences between the various groups. A *p*-value less than 0.05 was considered statistically significant.

Results

Tissue myeloperoxidase (MPO) analyses

Among the control and the ischemia groups, statistically significant difference was observed with regard to the mean tissue MPO levels ($p < 0.001$). These data revealed that I/R injury plainly elevated the tissue MPO levels. Treatment with

MP prompted a statistically significant reduction in the tissue MPO levels when compared to the ischemia group ($p < 0.001$). As in the MP group, the ACTH treatment significantly decreased the tissue MPO levels when compared to the ischemia group ($p < 0.001$). Furthermore, the ACTH group demonstrated a statistically significant decline in tissue MPO levels when compared with the MP group ($p = 0.028$).

Tissue malondialdehyde (MDA) analyses

A statistically significant difference was found between the control and the ischemia groups in their mean tissue MDA levels ($p < 0.001$). This suggested that after I/R damage, the tissue MDA levels were increased. When we considered the ischemia and the MP groups, there was a statistically significant difference between these groups ($p = 0.001$). As for the MP group, a comparison between the ACTH and the ischemia groups demonstrated a statistically significant difference in the MDA levels ($p = 0.003$). When the MP and the ACTH groups were compared, no statistically significant difference was found ($p = 0.991$). This demonstrated that both MP and ACTH medications prevent an increase in the MDA levels.

Serum and tissue catalase (CAT) analyses

There was a statistically significant difference between the control and the ischemia groups in the mean serum and tissue CAT levels ($p < 0.001$ for both); this suggested that after I/R injury both serum and tissue CAT levels were diminished. In the MP group, both serum and tissue CAT levels were significantly increased when compared to the ischemia group ($p < 0.001$ for both). Similar to MP group, furthermore, the ACTH group showed a statistically significant decline in tissue MPO levels when compared with the MP group (both in the serum and tissue; $p < 0.001$ and $p = 0.001$, respectively). There were no statistically significant differences between the MP and the ACTH groups for the serum and the tissue CAT levels ($p = 0.129$ and $p = 0.942$, respectively).

Serum xanthine oxidase (XO) analyses

Serum XO activity was associated with a statistically significant increase in the ischemia group compared with the control group ($p < 0.001$). In the MP group, serum XO activity was significantly decreased when compared to the ischemia group ($p < 0.001$). Like the MP group, the XO activity of the ACTH group demonstrated a statistically significant reduction when compared with the ischemia group ($p < 0.001$). There was no statistically significant difference between the MP and the ACTH groups ($p = 0.571$).

Table I. Biochemical results among the study groups

Variables	Control (n = 8)	Ischemia (n = 8)	MP (n = 8)	ACTH (n = 8)	P-value
Tissue MPO [ng/ml]	2.47 (0.81) ^{a,b}	4.83 (0.77) ^{a,c,e}	3.17 (1.50) ^{b,d,e}	2.63 (0.58) ^{c,d,f}	< 0.001
Tissue MDA [nmol/ml]	2.39 ±0.98 ^a	5.21 ±0.94 ^{a,c,e}	3.18 ±0.86 ^e	3.32 ±1.07 ^c	< 0.001
Serum CAT [IU/ml]	168.36 (77.99) ^{a,b}	53.55 (34.00) ^{a,c,e}	117.12 (29.28) ^{b,e}	135.42 (35.36) ^c	< 0.001
Tissue CAT [IU/ml]	161.43 ±34.71 ^a	70.95 ±22.10 ^{a,c,e}	144.94 ±34.23 ^e	136.13 ±32.58 ^c	< 0.001
Serum XO [mIU/ml]	0.04 ±0.03 ^a	0.40 ±0.09 ^{a,c,e}	0.11 ±0.03 ^e	0.08 ±0.04 ^c	< 0.001
Tissue caspase-3 [ng/ml]	0.50 ±0.26 ^{a,b}	2.07 ±0.33 ^{a,c,e}	1.20 ±0.40 ^{b,e}	0.88 ±0.26 ^c	< 0.001

^aControl vs. ischemia ($p < 0.001$), ^bcontrol vs. MP ($p < 0.05$), ^ccontrol vs. ACTH ($p < 0.05$), ^dischemia vs. ACTH ($p < 0.05$), ^eischemia vs. MP ($p < 0.01$), ^fMP vs. ACTH ($p < 0.05$). MP – methylprednisolone, ACTH – adrenocorticotrophic hormone, MPO – myeloperoxidase, MDA – malondialdehyde, CAT – catalase, XO – xanthine oxidase. The data are shown as the mean ± standard deviation or the median (IQR).

Tissue caspase-3 analyses

There was a statistically significant contrast between the control and the ischemia groups in their mean caspase-3 activity ($p < 0.001$). These data demonstrated that I/R injury clearly raised caspase-3 activity in the injured tissue. When the MP group was compared with the ischemia group, there was a statistically significant decrease in caspase-3 levels ($p < 0.001$). Like the MP group, the ACTH group additionally demonstrated a statistically significant decrease in caspase-3 activity

($p < 0.001$). Also, there was no statistically significant difference between the MP and the ACTH groups ($p = 0.205$).

The biochemical results of the study groups are summarized in Table I.

Histopathological procedures

Light microscopic examinations of the spinal cord samples from the control group were normal (Figure 2 A). In the ischemia group (Figure 2 B), diffuse hemorrhage and congestion in the gray

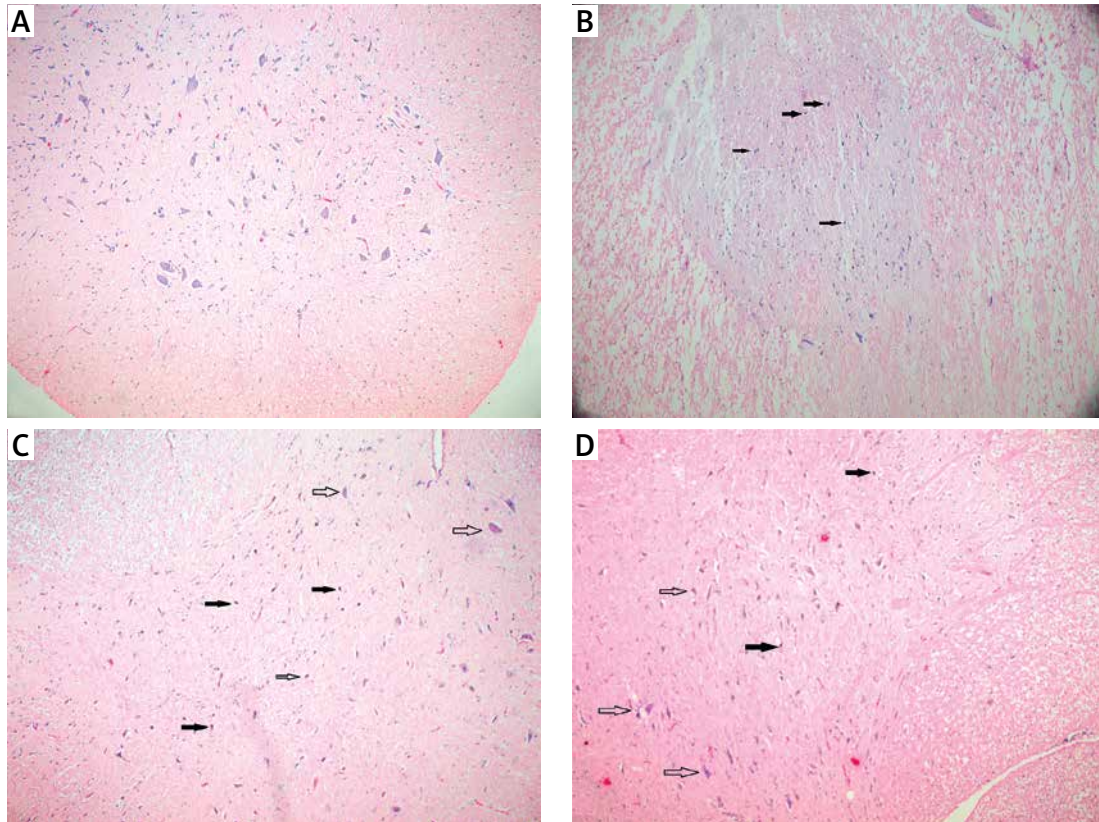


Figure 2. Photomicrographs of 5 µm spinal cord tissue sections from the different study groups (H&E, 10× obj.). **A** – Control group (n = 8), showing normal spinal cord parenchyma. **B** – Ischemia group (n = 8), showing degenerated neurons (filled arrows) in the edematous surface. **C** – MP group (n = 8), showing less degenerated neurons (filled arrows); note the normal neurons (hollow arrows). **D** – ACTH group (n = 8), showing less degenerated neurons (filled arrows), and more normal neurons (hollow arrows). The spinal cord tissues were protected from injury

matter were observed 24 h after the I/R damage. There was marked necrosis and significantly spread edema in both the white and gray matter. In the injured areas, there were invading polymorphonuclear leukocytes, lymphocytes, and plasma cells. Neuronal pyknosis, a loss of cytoplasmic elements and cytoplasmic eosinophilia were additionally seen in the ischemia group. In the MP group and the ACTH group, the cord tissues were protected from I/R damage (Figures 2 C, D).

When the histopathology scores were analyzed, the ischemia group demonstrated statistically significantly higher scores than the control group

($p < 0.001$). In the MP group, the histopathology score was statistically significantly lower than that for the ischemia group ($p = 0.003$). In the ACTH group, the histopathology scores were statistically significantly lower than the ischemia group ($p = 0.001$). The comparison between the MP and the ACTH groups was not statistically significant ($p = 0.778$) (Figure 3 A).

In the ischemia group the number of normal motor neurons in the anterior spinal cord was significantly lower than that in the control group ($p < 0.001$). In the MP group, the number of normal motor neurons in the anterior spinal cord was sig-

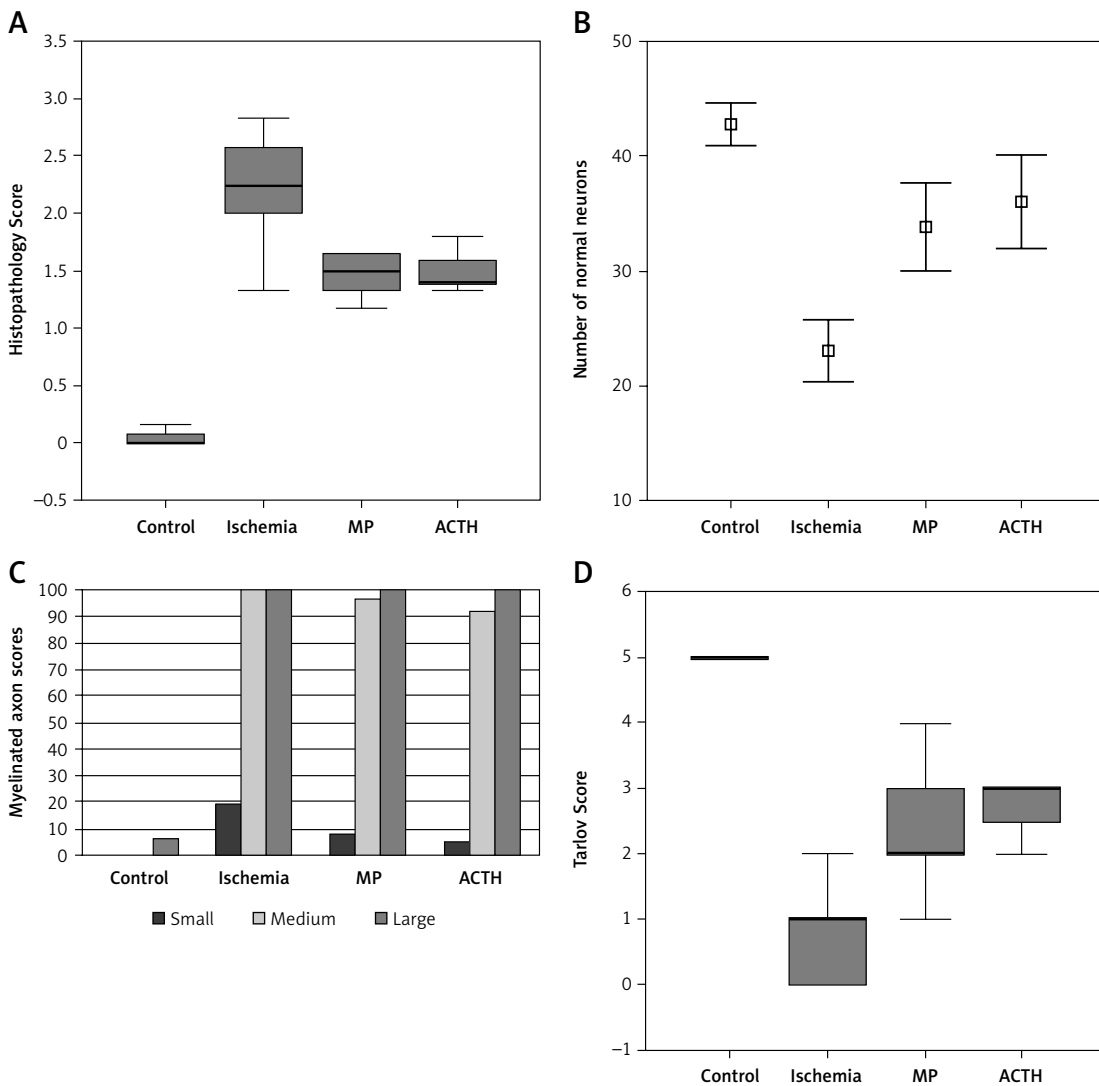


Figure 3. Graphs showing the histopathological (A, B), ultrastructural (C) and neurological examination results (D) of the groups ($n = 8$ for each group). **A** – Comparison of the histopathology scores among the groups. The horizontal lines in the middle of each box represent the median, while the top and bottom borders of the box represent the 25th and 75th percentiles, respectively. The whiskers above and underneath the box represent the highest and lowest levels observed. **B** – Correlation of the number of normal neurons in the anterior horn among the groups. The box in the middle of each whisker shows the arithmetic mean, while the whiskers above and below the box indicate the +1 SD and -1 SD levels, respectively. **C** – Bar graph demonstrating the after-effects of the ultrastructural investigation. **D** – Comparison of the Tarlov scores among the groups. The horizontal lines in the middle of each box represent the median, while the top and bottom borders of the box indicate the 25th and 75th percentiles, respectively. The whiskers above and below the box mark the maximum and minimum levels observed

MP – methylprednisolone, ACTH – adrenocorticotrophic hormone.

nificantly higher than that of the ischemia group ($p < 0.001$). Like the MP group, the ACTH group demonstrated a statistically significantly higher number of normal motor neurons when compared with the ischemia group ($p < 0.001$). The correlation between the MP and the ACTH groups did not demonstrate a statistically significant difference ($p = 0.558$). Histopathologically, both ACTH and MP protected the spinal cord from I/R injury (Figure 3 B).

Ultrastructural examinations

In the transmission electron microscopic examination of the tissue samples of the control group, no ultrastructural pathological changes were seen in the gray and white matter of the spinal cord. The neurons were ultrastructurally normal in appearance, and the intracellular organelles, nuclei, membranes and perineuronal tissues did not demonstrate any pathological changes. However, in a couple of the large-sized myelinated axons, mild separations were seen in a small part of the myelin sheath. This might be related to delayed fixation of the tissue. The rest of the large-sized

myelinated axons and the entire medium-and small-sized myelinated axons were observed to be ultrastructurally normal (Figure 4 A).

The transmission electron microscopic examination of the ischemia group indicated separations in the myelin configuration of small, medium-sized and large myelinated axons. When all the groups were compared, the ischemia group demonstrated the greatest ultrastructural injury in the myelinated axons (Figure 4 B).

In the MP group, separations were seen in the myelin configuration of the medium-sized and large myelinated axons. Moreover, in a couple of the small-sized myelinated axons, separations in the myelin configuration were observed (Figure 4 C).

In the ACTH group, separations were seen in the myelin configurations of the medium-sized and large myelinated axons. All of the small and the vast majority of the medium-sized myelinated axons of this group were ultrastructurally normal (Figure 4 D). The ultrastructural appearances of the myelinated axons of the ACTH group were similar to those of the MP group, which was likewise seen after the scoring.

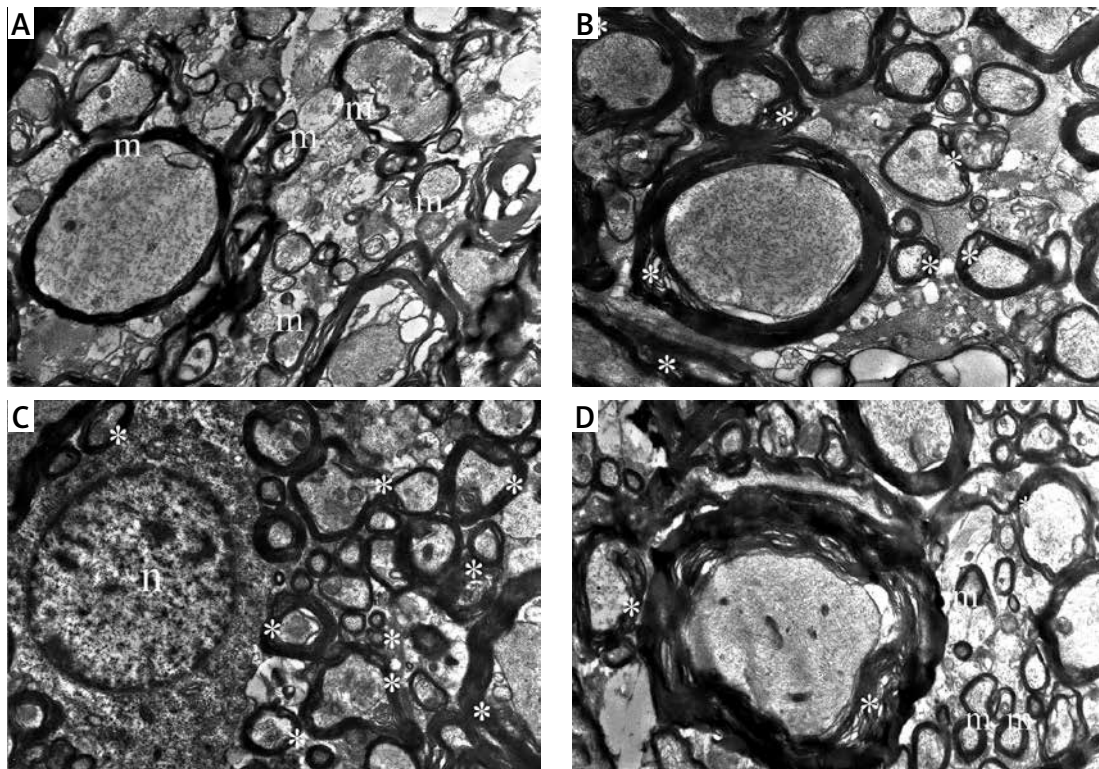


Figure 4. Transmission electron microscopy of the groups. **A** – Electron micrograph from the control group ($n = 8$) showing ultrastructurally normal myelinated axons (m) (original magnification 5000 \times , scale bar is 2 μ m long). **B** – Electron micrograph from the ischemia group ($n = 8$) showing the small, medium-sized, and large axons with separations in myelin configuration (*) (original magnification 5000 \times , scale bar is 2 μ m long). **C** – Electron micrograph from the MP group ($n = 8$) showing separations in myelin configurations (*) in small, medium-sized and large myelinated axons (original magnification 5000 \times , scale bar is 2 μ m long). n – nucleus of a neuron. **D** – Electron micrograph from the ACTH group ($n = 8$) indicating medium-sized myelinated axons with gentle division in myelin configuration (*) and ultrastructurally normal small and medium-sized myelinated axons (m) (original amplification 5000 \times , scale bar is 2 μ m long)

Compared with the control group, the ischemia group demonstrated more prominent disturbance in the small myelinated axons ($p = 0.008$). When compared with the ischemia group, both MP and ACTH protected the small-sized myelinated axons from interruption ($p = 0.008$ for both). When the ACTH group was compared with the MP group, the ACTH group revealed statistically significant improvements in terms of protecting small-sized myelinated axons ($p = 0.008$).

In the ischemia group, I/R injured the medium-sized myelinated axons when compared with the control group ($p = 0.008$). There was a significant difference between both the MP and the ACTH groups when compared with the ischemia group, in which both ACTH and MP medications protected the medium-sized axons from I/R injury ($p = 0.008$ for both). Furthermore, when the ACTH group was compared with the MP group, the ACTH group showed a statistically significant enhancement in securing medium-sized myelinated axons ($p = 0.032$). Also, large myelinated axons were more injured after the I/R damage in the ischemia group than the control group. Unfortunately, neither MP nor ACTH protected the large axons of the spinal cord from I/R damage (Figure 3 C).

Neurologic evaluations

The mean Tarlov score of the ischemia group was significantly lower than that of the control group ($p < 0.001$). In any case, the mean Tarlov score of the MP group was significantly higher than that of the ischemia group ($p = 0.002$). The mean Tarlov score of the ACTH group was likewise significantly higher than that of the ischemia group ($p < 0.001$). Furthermore, there was no significant difference in Tarlov scores between the MP and the ACTH groups ($p = 0.231$) (Figure 3D).

Discussion

After surgery involving the descending and thoracoabdominal aorta, spinal cord I/R injury as a post-surgical complication might bring about calamitous results, such as paraplegia. The fundamental cause of spinal cord injury is accepted to be ischemia due to hypoperfusion during aortic cross clamping. This damage is followed by a secondary injury brought on by the restoration of blood flow [27]. The “primary injury” of spinal cord I/R injury happens when the loss of supplements and oxygen initiates crushing biochemical cascades. These may include the formation of ROS, apoptosis, necrosis, lipid peroxidation, excessive excitatory amino acid release and inflammation [28]. After the primary injury, restoration of the blood flow, called reperfusion, starts extra spinal cord injury, which results in a decline of function termed the “secondary injury” [20, 27].

Inflammatory processes are a standout amongst the most critical mechanisms responsible for I/R damage of the spinal cord [28, 29]. Inflammatory cells, such as neutrophils, macrophages and monocytes, assume an essential part in the inflammatory response of the spinal cord to ischemic injury and cause the development of neuronal injury after reperfusion [30]. The occupant glial cells, particularly the microglia, additionally assume a part in secreting proinflammatory components that recruit peripheral immune cells into the spinal cord [31]. By creating various proinflammatory mediators, for example, cytokines and adhesion molecules, these cells initiate peripheral inflammatory cells into the spinal cord and bring on additional neuronal death [21, 29]. The significance of inflammation in spinal cord I/R damage has become better understood and techniques to lessen I/R injury of the spinal cord have concentrated on counteracting inflammation [8, 29, 30].

Tetracosactide is a synthetic analogue of ACTH, which was reproduced from the first 24 of 39 amino acids that compose ACTH [10]. Tetracosactide stimulates the release of corticosteroids, such as cortisol, from the adrenal gland, and is used for the ACTH stimulation test to assess adrenal gland function [32]. Furthermore, in clinical practice, tetracosactide is used for treatment of adrenal insufficiency, some forms of epilepsy and infantile spasm [33].

Previous studies concluded that ACTH has specific, adrenal-independent anti-inflammatory activity [14–16, 18, 34]. The anti-inflammatory effects of ACTH have been associated with reduced generation of proinflammatory cytokines, for example, interleukin-1 α , interleukin-1 β , interleukin-6 and tumor necrosis factor- α [13, 14, 35], and with increased production of anti-inflammatory interleukin-8 and interleukin-10 [35].

Moreover, tetracosactide has been shown to inhibit the overproduction of ROS in conditions of tissue hypoxia [13, 34, 36]. The mechanism by which this peptide prevents free radical formation could not be described by a direct radical scavenging activity; the underlying mechanism of this antioxidant effect remains unclear [17, 36].

Furthermore, ACTH has been demonstrated to have neurotrophic effects, enhancing recovery from damage of both the central and the peripheral nervous system [37, 38]. Also, ACTH and adrenal steroids have been reported to be important regulators of trophic processes operating in synaptic plasticity [39].

While those previous studies reported that ACTH has anti-inflammatory, antioxidant and neurotrophic effects, we hypothesized that tetracosactide, as an ACTH analogue, may have a neuroprotective effect in spinal cord I/R injury. Steroids, especially MP, have been used as a treatment option for acute spinal cord injury

for more than six decades [40–44]. Unfortunately, most of the previous studies demonstrated serious adverse events caused by the high-dose MP protocol, which outweighed the potential benefits [44]. However, when MP was administered within 8 h of injury, motor score improvement was achieved [43, 44]. Furthermore, current AOSpine guidelines suggest intravenous MP as a treatment option for patients within 8 h of injury [44]. Although the clinical use of MP for the treatment of spinal cord injury has been under debate in recent years, previous laboratory studies relevant to spinal cord I/R injury showed beneficial effects of this drug [2, 3, 9, 11]. For this reason, in this study, MP was used as a positive control for comparison with ACTH.

In the present study, spinal cord I/R damage created a huge increase in MPO activity in both serum and the spinal cord. Myeloperoxidase was found to be raised in both serum and tissue; this proves that spinal cord injury is associated with elevated serum levels of MPO. Myeloperoxidase activity is a dependable marker of neutrophil invasion into injured tissue [45]. Myeloperoxidase is available in vast amounts in the azurophilic granules of neutrophils and contributes to their oxygen-dependent bactericidal action [46]. Myeloperoxidase activity is associated with the quantity of neutrophils that invade the spinal cord and their activation [45]. Our discoveries demonstrated that both tetracosactide and MP were viable in decreasing MPO activity. Furthermore, the tetracosactide group had statistically significantly lower tissue MPO activity when compared to the MP group; this may be a weak manifestation of the better anti-inflammatory activity of tetracosactide. Accordingly, the noted reduction in MPO action because of tetracosactide demonstrates a decrease in the quantity of neutrophils at the site of injury. This additionally underpins the presence of anti-inflammatory activity for tetracosactide.

Neutrophils are additionally major sources of ROS in injured tissues. The central nervous system consists basically of lipids, which are easily injured by free-radical-induced lipid peroxidation [11]. After spinal cord ischemia and during reperfusion, lipid peroxidation occurs in cell membranes. Lipid peroxidation is one of the principle pathophysiological mechanisms included in secondary injury [47]. Malondialdehyde is a degeneration product of polyunsaturated fatty acids and serves as a reliable index for deciding the degree of peroxidation responses. Malondialdehyde levels increase after spinal cord I/R, exhibiting the inclusion of lipid peroxidation, accordingly supporting the vicinity of reperfusion injury [48]. This study demonstrated a critical increase in MDA levels from I/R injury; nonetheless, both tetracosactide and MP protected the spinal cord from lipid peroxidation by bringing down the MDA levels.

Reactive oxygen species play a key role in interceding secondary injury affront by reperfusion [49]. Neutrophil activation causes the generation of ROS and in this way brings about a lot of injury to the tissue [50]. The antioxidant enzyme CAT has the ability to scavenge ROS [21]. The antioxidant enzyme activities are reduced under exceedingly increased oxidative stress conditions in view of molecular damage [51]. The present study demonstrated that CAT levels diminished after I/R injury. After administration of either tetracosactide or MP, CAT levels increased significantly, thus demonstrating the impact of the antioxidant. XO is another important source of ROS [52]. In the present study, XO levels were observed to be increased after I/R injury. It was additionally shown that both tetracosactide and MP diminished XO levels significantly.

Spinal cord injury involves the apoptotic death of neurons after injury, which can be further exacerbated by inflammation [53]. Members of the cysteine protease family known as caspases actuate apoptosis. Caspase-3 is an interleukin-converting enzyme and has been proposed to be an important effector in the mammalian apoptotic and inflammatory pathways [54]. Past studies have shown that caspase-3 is a reliable marker to reflect apoptotic action in I/R injury [2, 3, 11]. In the present study, we found that caspase-3 activity was increased following I/R injury. Notably, tetracosactide treatment decreased the caspase-3 activity in the spinal cord, thus demonstrating its antiapoptotic activity. No previous study showed an antiapoptotic effect of tetracosactide.

Histopathological examination of the spinal cord samples revealed that I/R damage brought on diffuse hemorrhage, congestion, marked edema, and necrosis in both white and gray matter. In the injured segments of the spinal cord, invading polymorphonuclear leukocytes, lymphocytes and plasma cells were observed, demonstrating an inflammatory reaction. In the ischemia group, the number of normal motor neurons in the anterior horn of the spinal cord was significantly diminished. Both tetracosactide and MP indicated better morphological results and a higher number of the normal motor neurons when compared with the ischemia group.

Nonetheless, assessment of the neuroprotection using histopathological methods did not give completely sufficient results. In light of this, we likewise assessed the ultrastructural changes with a transmission electron microscope. The transmission electron microscope results revealed that I/R created critical interruption in small, medium and large-sized myelinated axons. Both the tetracosactide and MP treatments protected the small and medium-sized myelinated axons from I/R injury. Nevertheless, neither tetracosactide nor

MP provided significant protection of large myelinated axons.

The rabbit aortic cross-clamping method, which was used as part of this study, is a helpful technique for research [2, 3, 11, 20, 21]. The 20 min ischemia period was selected to cause adequate injury [22]. In our ischemia group, aortic cross clamping brought on paraplegia in all animals. Both tetracosactide and MP treatments, administered after I/R injury, ensured the spinal cord and enhanced neurological capacity, as dictated by the Tarlov scores.

All outcomes from this study recommend that tetracosactide and MP have beneficial effects to protect normal spinal cord morphology and ultrastructure by reducing inflammation, lipid peroxidation and oxidative stress and inhibiting apoptosis. Despite tissue MPO activity, tetracosactide treatment did not show statistically significant differences in biochemical analysis. On the other hand, tetracosactide treatment revealed statistically significantly better results in protecting small and medium-sized myelinated axons than MP treatment. However, no statistically significant differences were found between ACTH and MP groups relevant to histopathological examination and Tarlov scores. These results indicate that tetracosactide treatment may prevent spinal cord I/R injury at least as effectively as MP.

There were some limitations of this study. The number of rabbits in each group and the periods for functional, biochemical and histopathological evaluations ought to be increased. A more detailed examination of the dosage-dependence ought to be performed. As this study focused on the early changes occurring during the first 24 h following injury, hence not providing information regarding clinical outcome, a later biochemical and histopathological evaluation might yield more comprehensive results for further studies.

In conclusion, biochemical, histopathological, ultrastructural and neurological functional examination revealed that tetracosactide exhibits adequate neuroprotective action in I/R injury of the spinal cord. In addition, tetracosactide was found to be at least as effective as MP. Further studies in view of these discoveries might be useful for further assessing this promising drug for I/R damage of the spine.

Conflict of interest

The authors declare no conflict of interest.

References

- Crawford ES, Crawford JL, Safi HJ, et al. Thoracoabdominal aortic aneurysms: preoperative and intraoperative factors determining immediate and long-term results of operations in 605 patients. *J Vasc Surg* 1986; 3: 389-404.
- Gürer B, Kertmen H, Kasim E, et al. Neuroprotective effects of testosterone on ischemia/reperfusion injury of the rabbit spinal cord. *Injury* 2015; 46: 240-8.
- Kertmen H, Gürer B, Yılmaz ER, et al. The protective effect of low-dose methotrexate on ischemia-reperfusion injury of the rabbit spinal cord. *Eur J Pharmacol* 2013; 714: 148-56.
- Lu K, Cho CL, Liang CL, et al. Inhibition of the MEK/ERK pathway reduces microglial activation and interleukin-1-beta expression in spinal cord ischemia/reperfusion injury in rats. *J Thorac Cardiovasc Surg* 2007; 133: 934-41.
- Matsumoto S, Matsumoto M, Yamashita A, et al. The temporal profile of the reaction of microglia, astrocytes, and macrophages in the delayed onset paraplegia after transient spinal cord ischemia in rabbits. *Anesth Analg* 2003; 96: 1777-84.
- Agee JM, Flanagan T, Blackburne LH, Kron IL, Tribble CG. Reducing postischemic paraplegia using conjugated superoxide dismutase. *Ann Thorac Surg* 1991; 51: 911-4.
- Ueno T, Furukawa K, Katayama Y, Suda H, Itoh T. Spinal cord protection: development of a paraplegia-preventive solution. *Ann Thorac Surg* 1994; 58: 116-20.
- Cassada DC, Gangemi JJ, Rieger JM, et al. Systemic adenosine A2A agonist ameliorates ischemic reperfusion injury in the rabbit spinal cord. *Ann Thorac Surg* 2001; 72: 1245-50.
- Kanellopoulos GK, Kato H, Wu Y, et al. Neuronal cell death in the ischemic spinal cord: the effect of methylprednisolone. *Ann Thorac Surg* 1997; 64: 1279-85.
- Cassada DC, Tribble CG, Laubach VE, et al. An adenosine A2A agonist, ATL-146e, reduces paralysis and apoptosis during rabbit spinal cord reperfusion. *J Vasc Surg* 2001; 34: 482-8.
- Yılmaz ER, Kertmen H, Dolgun H, et al. Effects of darbepoetin-alpha in spinal cord ischemia-reperfusion injury in the rabbit. *Acta Neurochir* 2012; 154: 1037-43.
- Martin L, Chaabo A, Lasne F. Detection of tetracosactide in plasma by enzyme-linked immunosorbent assay (ELISA). *Drug Test Anal* 2015; 7: 531-4.
- Bazzani C, Guarini S, Botticelli AR, et al. Protective effect of melanocortin peptides in rat myocardial ischemia. *J Pharmacol Exp Ther* 2001; 297: 1082-7.
- Lipton JM, Catania A, Delgado R. Peptide modulation of inflammatory processes within the brain. *Neuroimmunomodulation* 1998; 5: 178-83.
- Lipton JM, Catania A. Anti-inflammatory actions of the neuroimmunomodulator alpha-MSH. *Immunol Today* 1997; 18: 140-5.
- Wikberg JES. Melanocortin receptors: perspectives for novel drugs. *Eur J Pharmacol* 1999; 375: 295-310.
- Guarini S, Bazzani C, Bini A, Cainazzo MM, Tomasi A, Bertolini A. Adrenocorticotropin counteracts the increase in free radical blood levels, detected by electron spin resonance spectrometry, in rats subjected to prolonged asphyxia. *Life Sci* 1998; 63: 97-104.
- Mioni C, Giuliani D, Cainazzo MM, et al. Further evidence that melanocortins prevent myocardial reperfusion injury by activating melanocortin MC3 receptors. *Eur J Pharmacol* 2003; 477: 227-34.
- Muller CA, McArthur N, Belyaev O, et al. The effect of synacthen on acute necrotizing pancreatitis in rats. *Pancreas* 2008; 37: 316-20.
- Lukáčová N, Halát G, Chavko M, Marsala J. Ischemia-reperfusion injury in the spinal cord of rabbits strongly enhances lipid peroxidation and modifies phospholipid profiles. *Neurochem Res* 1996; 21: 869-73.

21. Ilhan A, Yilmaz HR, Armutcu F, Gurel A, Akyol O. The protective effect of nebivolol on ischemia/reperfusion injury in rabbit spinal cord. *Prog Neuropsychopharmacol Biol Psychiatry* 2004; 28: 1153-60.
22. Zivin JA, DeGirolami U. Spinal cord infarction: a highly reproducible stroke model. *Stroke* 1980; 11: 200-2.
23. Prajda N, Weber G. Malignant transformation-linked imbalance: decreased xanthine oxidase activity in hepatomas. *FEBS Lett* 1975; 59: 245-9.
24. Umehara S, Goyagi T, Nishikawa T, Tobe Y, Masaki Y. Es-molol and landiolol, selective beta1-adrenoreceptor antagonists, provide neuroprotection against spinal cord ischemia and reperfusion in rats. *Anesth Analg* 2010; 110: 1133-7.
25. Kaptanoğlu E, Palaoglu S, Surucu HS, Hayran M, Beskonakli E. Ultrastructural scoring of graded acute spinal cord injury in the rat. *J Neurosurg* 2002; 97: 49-56.
26. Lee BY, Al-Waili N, Butler G. The effect of adrenergic beta(2) receptor agonist on paraplegia following clamping of abdominal aorta. *Arch Med Sci* 2011; 7: 597-603.
27. Dumont RJ, Okonkwo DO, Verma S, et al. Acute spinal cord injury, part I: pathophysiologic mechanisms. *Clin Neuropharmacol* 2001; 24: 254-64.
28. Hasturk A, Atalay B, Calisaneller T, Ozdemir O, Oruckaptan H, Altinors N. Analysis of serum pro-inflammatory cytokine levels after rat spinal cord ischemia/reperfusion injury and correlation with tissue damage. *Turk Neurosurg* 2009; 19: 353-9.
29. Fan L, Wang K, Shi Z, Die J, Wang C, Dang X. Tetramethylpyrazine protects spinal cord and reduces inflammation in a rat model of spinal cord ischemia-reperfusion injury. *J Vasc Surg* 2011; 54: 192-200.
30. Reece TB, Okonkwo DO, Ellman PI, et al. The evolution of ischemic spinal cord injury in function, cytoarchitecture, and inflammation and the effects of adenosine A2A receptor activation. *J Thorac Cardiovasc Surg* 2004; 128: 925-32.
31. Li C, Zhao R, Gao K, et al. Astrocytes: implications for neuroinflammatory pathogenesis of Alzheimer's disease. *Curr Alzheimer Res* 2011; 8: 67-80.
32. Brossaud J, Gatta B, Tabarin A, Corcuff JB. Different methods to estimate serum free cortisol: a comparison during cortisol tetracosactide testing. *Clin Chem Lab Med* 2015; 53: 1367-73.
33. Lux AL, Edwards SW, Hancock E, et al. The United Kingdom Infantile Spasms Study comparing vigabatrin with prednisolone or tetracosactide at 14 days: a multicentre, randomised controlled trial. *Lancet* 2004; 364: 1773-8.
34. Getting SJ. Melanocortin peptides and their receptors: new targets for anti-inflammatory therapy. *Trends Pharmacol Sci* 2002; 23: 447-9.
35. Luger TA, Scholzen T, Grabbe S. The role of alpha-melanocyte-stimulating hormone in cutaneous biology. *J Investig Dermatol Symp Proc* 1997; 2: 87-93.
36. Guarini S, Bazzani C, Mattera Ricigliano G, Bini A, Tomasi A, Bertolini A. Influence of ACTH-(1-24) on free radical levels in the blood of haemorrhage-shocked rats: direct ex vivo detection by electron spin resonance spectrometry. *Br J Pharmacol* 1996; 119: 29-34.
37. Darlington CL, Gilchrist DP, Smith PF. Melanocortins and lesion-induced plasticity in the CNS: a review. *Brain Res Brain Res Rev* 1996; 22: 245-57.
38. Kokubo M, Asai K, Yamamoto N, et al. ACTH(1-24) down-regulates expression of ciliary neurotrophic factor mRNA in cultured rat astrocyte. *Pediatr Res* 2002; 52: 950-7.
39. Mochetti I, Spiga G, Hayes VY, Isackson PJ, Colangelo A. Glucocorticoids differentially increase nerve growth factor and basic fibroblast growth factor expression in the rat brain. *J Neurosci* 1996; 16: 2141-8.
40. Chen HC, Fong TH, Lee AW, Chiu WT. Autophagy is activated in injured neurons and inhibited by methylprednisolone after experimental spinal cord injury. *Spine* 2012; 37: 470-5.
41. Kwon BK, Tetzlaff W, Grauer JN, Beiner J, Vaccaro AR. Pathophysiology and pharmacologic treatment of acute spinal cord injury. *Spine J* 2004; 4: 451-64.
42. Bracken MB. Steroids for acute spinal cord injury. *Cochrane Database Syst Rev* 2012; 1: CD001046.
43. Bracken MB, Shepard MJ, Holford TR, et al. Administration of methylprednisolone for 24 or 48 hours or tirilazad mesylate for 48 hours in the treatment of acute spinal cord injury. Results of the Third National Acute Spinal Cord Injury Randomized Controlled Trial. National Acute Spinal Cord Injury Study. *JAMA* 1997; 277: 1597-604.
44. Ahuja CS, Martin AR, Fehlings M. Recent advances in managing a spinal cord injury secondary to trauma. *F1000Res*. 2016; 5: pii: F1000 Faculty Rev-1017.
45. Taoka Y, Okajima K, Uchiba M, et al. Role of neutrophils in spinal cord injury in the rat. *Neuroscience* 1997; 79: 1177-82.
46. Sanli AM, Serbes G, Sargon MF, et al. Methothrexate attenuates early neutrophil infiltration and the associated lipid peroxidation in the injured spinal cord but does not induce neurotoxicity in the uninjured spinal cord in rats. *Acta Neurochir* 2012; 154: 1045-54.
47. Diaz-Ruiz A, Rios C, Duarte I, et al. Lipid peroxidation inhibition in spinal cord injury: cyclosporin-A vs methylprednisolone. *Neuroreport* 2000; 11: 1765-67.
48. Qian H, Liu D. The time course of malondialdehyde production following impact injury to rat spinal cord as measured by microdialysis and high pressure liquid chromatography. *Neurochem Res* 1997; 22: 1231-6.
49. Chan PH. Role of oxidants in ischemic brain damage. *Stroke* 1996; 27: 1124-29.
50. Krieglstein CF, Granger DN. Adhesion molecules and their role in vascular disease. *Am J Hypertens* 2001; 14: 44S-54S.
51. Ustün ME, Duman A, Oğun CO, Vatansev H, Ak A. Effects of nimodipine and magnesium sulfate on endogenous antioxidant levels in brain tissue after experimental head trauma. *J Neurosurg Anesthesiol* 2001; 13: 227-32.
52. Hille R, Nishino T. Flavoprotein structure and mechanism. 4. Xanthine oxidase and xanthine dehydrogenase. *FASEB J* 1995; 9: 995-1003.
53. Schwab ME, Bartholdi D. Degeneration and regeneration of axons in the lesioned spinal cord. *Physiol Rev* 1996; 76: 319-70.
54. Keane RW, Kraydieh S, Lotocki G, et al. Apoptotic and anti-apoptotic mechanisms following spinal cord injury. *J Neuropathol Exp Neurol* 2001; 60: 422-9.