

Hippocratic fingers in Behçet's disease

Mustafa Benekli, İbrahim Halil Güllü

Summary

Digital clubbing has been a well recognised feature of several distinct clinical conditions, including respiratory, cardiac, and gastrointestinal diseases since the Hippocratic era. However, clubbing associated with Behçet's disease has not been reported before. We describe a case of clubbing in a young man with Behçet's disease, in the absence of any other apparent aetiology and propose that clubbing might be an accompanying feature of Behçet's disease.

Keywords: Behçet's disease, digital clubbing

Clubbing of the digits has been recognised as an evidence of respiratory disorders since the fifth century when Hippocrates first described this abnormality in a patient with empyema.¹ Secondary clubbing can be encountered in a number of cardiopulmonary, gastrointestinal, hepatobiliary and infectious diseases. This report documents a case of clubbing in a patient with Behçet's disease. To the authors' knowledge, this is the first description of such an association in the literature.

Case report

In October 1987, Behçet's disease was diagnosed in a 32-year-old non-smoker man at the Behçet's Disease Research Center, Hacettepe University Faculty of Medicine. In his medical history, he had recurrent orogenital ulcerations and episodes of painful swelling in both knee joints. There was no history of hypertension, chronic respiratory disease, cirrhosis, renal insufficiency, inflammatory bowel disease, ischaemic or congenital cyanotic heart disease. His family history was also unremarkable for pulmonary disease and clubbing.

On physical examination, there were multiple acneiform rashes over the back and lower extremities. He had large, painful aphthous ulcers on the tongue, gingiva, hard palate and buccal mucosa, and a major ulceration on the scrotum. Ophthalmological examination disclosed posterior synechiae with normal fundi and normal visual acuity. The pathergy test was negative. There was no evidence of digital clubbing at that time and no vascular involvement was identified.

Haematological parameters, serum biochemistry profile, C3, C4 and immunoglobulins were in the normal ranges. The erythrocyte sedimentation rate was elevated at 108 mm/h and C-reactive protein was 2+. Anticardiolipin

antibodies, antinuclear antibodies, antidouble-stranded DNA, rheumatoid factor and cryoglobulin were negative. Chest X-ray was normal. Because of the minor ocular involvement, prednisolone 30 mg daily and colchicine 1 mg daily were started. Prednisolone was discontinued after two months, because of normal ocular findings. The patient developed erythema nodosum on the pretibial region of the right leg two months later.

He was then lost to follow-up for eight months until August 1988, when the finger clubbing was first noticed. Clinical examination was within normal limits, apart from a prominent clubbing of the fingers, but not of the toes. Lung fields were clear on auscultation, and laboratory findings were unremarkable. X-Rays of the hands, wrists and chest were normal, as were thoracic computed tomography and pulmonary function tests. Cytology of bronchial washings was negative for a malignant disease. Thyroid function tests were in normal ranges and hepatitis B, and C and HIV were negative. Faecal occult blood was negative three times. Abdominal ultrasonography and echocardiography were normal.

No apparent aetiology could be identified for clubbing, despite extensive clinical and laboratory investigation. Over the subsequent years, his clubbing remained unchanged. He is still being followed-up in remission and has not been taking any medications for two years.

Discussion

Behçet's disease is a multisystemic disorder (boxes 1 and 2).² Vasculitis, which involves arterial and venous vessels of all sizes, appears to be the underlying basis for the protean multisystemic manifestations of the disease.³ However, an extensive review of the literature (Medline), revealed no other case of Behçet's disease associated with digital clubbing.

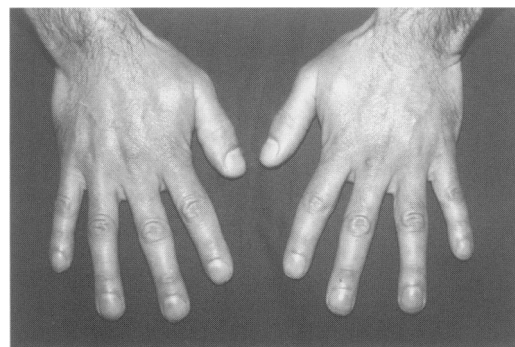


Figure Clubbing of the digits in Behçet's disease

Department of
Internal Medicine,
Hacettepe University
Faculty of Medicine,
Ankara, Turkey
M Benekli
İH Güllü

Correspondence to Dr
Mustafa Benekli, 14 Sokak
43/3, Bahçelievler, Ankara,
Turkey

Accepted 9 December 1996

International Study Group criteria for diagnosis of Behçet's disease²

Recurrent oral ulceration: aphthous ulcers at least three times in a 12-month period plus two of:

- *recurrent genital ulceration:* aphthous genital ulcers
- *eye lesions:* uveitis or cells in vitreous or retinal vasculitis
- *skin lesions:* erythema nodosum or papulopustular or acneiform nodules
- *positive pathergy test:* cutaneous hypersensitivity to needle prick after 24–48 h

Box 1

Minor manifestations of Behçet's disease²

- subcutaneous thrombophlebitis
- deep vein thrombosis
- epididymitis
- arterial occlusion and/or aneurysm
- central nervous system involvement
- arthralgia
- family history
- gastrointestinal features
- arthritis

Box 2

In 1973, a case of lupus erythematosus in association with clubbing was described by Mackie.⁴ The patient had significant clubbing involving all fingers with no radiologic evidence of hypertrophic osteoarthropathy. No other cardiopulmonary, inflammatory, or gastrointestinal condition was identified which could be responsible for the clubbing over a four-year period of follow-up. Abdul-Aziz⁵ reported a previously healthy young man who developed scleroderma and clubbing with no apparent clinical explanation. Hand X-rays were normal. Harris *et al*⁶ reported a 48-year-old man with the antiphospholipid antibody syndrome and finger and toe clubbing. Wrist X-rays were also normal. They could not demonstrate any aetiology for the development of digital clubbing and speculated that this may be a new feature of the antiphospholipid antibody syndrome.

The aetiology and pathogenesis of clubbing still remain obscure.¹ The condition is closely related to hypertrophic osteoarthropathy which is characterised by clubbed, or drumstick, fingers, proliferative periostitis of the long bones, arthritis, and synovitis, and occurs most frequently as a paraneoplastic symptom in association with bronchogenic carcinoma. While digital clubbing alone is usually painless, periostitis in hypertrophic osteoarthropathy causes a severe burning sensation in the extremities. Martinez-Lavin⁷ has suggested that clubbing illustrates the early manifestation of the evolving complete syndrome, but despite long-standing clubbing in our patient, hypertrophic osteoarthropathy did not develop during the eight-year follow-up period.

There are many theories on the mechanism of clubbing.¹ Tissue hypoxia, neural reflex

mechanisms, genetic factors, and circulating immune complexes have all been implicated. Most investigators have reported increased digital blood flow with increased vascularity and arteriovenous anastomoses in the nail bed of fingertips. Martinez-Lavin proposed⁷ that these peculiar skeletal changes occur as a response to a unique growth-promoting substance, either released from miscellaneous organs in certain diseases or normally present in the circulation and inactivated or filtered by the lungs. Miscellaneous circulating mediators have been investigated, but, none of them could precisely elucidate the pathogenesis of clubbing. The most plausible candidate for a growth-inducing factor appears to be platelet-derived growth factor (PDGF), first proposed by Dickinson and Martin in 1987.⁸ PDGF liberated from megakaryocytes and platelet clumps in the digital arteries, which are not filtered by the lungs in these patients, was implicated in the abnormal vascular proliferation.

Although the aetiology of Behçet's disease is unclear, it is now recognised that the vascular endothelium plays a key role in circulatory homeostasis through its ability to synthesize powerful vasodilators. Endothelial dysfunction may be a central pathophysiologic factor involved in causing abnormal constriction and a procoagulant luminal surface, with cell adherence and local thrombus production.³ The presence of vasculitis in digital small vessels may result in significant impairment of endothelial cell functions, which could enhance and alter thrombus formation and platelet aggregation in the vascular tree, with resultant clubbing.

1 Hansen-Flaschen J, Nordberg J. Clubbing and hypertrophic osteoarthropathy. *Clin Chest Med* 1987; **8**: 287–98.

2 International Study Group for Behçet's Disease: criteria for diagnosis of Behçet's disease. *Lancet* 1990; **335**: 1078–80.

3 Güllü H, Benekli M, Müderrisoğlu H, *et al*. Silent myocardial ischemia in Behçet's disease. *J Rheumatol* 1996; **23**: 323–7.

4 Mackie RM. Lupus erythematosus in association with finger-clubbing. *Br J Dermatol* 1973; **89**: 533–5.

5 Abdul-Aziz LAS. Scleroderma with rash and clubbing—a case report. *J R Army Med Corps* 1989; **135**: 141–3.

6 Harris AW, Harding TAC, Gaitonde MD, Maxwell JD. Is clubbing a feature of the anti-phospholipid syndrome? *Postgrad Med J* 1993; **69**: 748–50.

7 Martinez-Lavin M. Digital clubbing and hypertrophic osteoarthropathy: a unifying hypothesis. *J Rheumatol* 1987; **14**: 6–8.

8 Dickinson CJ, Martin JF. Megakaryocytes and platelet clumps as the cause of finger clubbing. *Lancet* 1987; **ii**: 1434–5.