





Cite this article as: Peker O, Aki FT, Kumbasar U, Guvener M, Yilmaz M, Dogan R *et al.* Surgical management of renovascular hypertension in children and young adults: a 13-year experience. *Interact CardioVasc Thorac Surg* 2019;29:746–52.

## Surgical management of renovascular hypertension in children and young adults: a 13-year experience

Oktay Peker <sup>a,\*</sup>, Fazil Tuncay Aki <sup>b</sup>, Ulas Kumbasar<sup>c</sup>, Murat Guvener <sup>a</sup>, Mustafa Yilmaz<sup>a</sup>, Riza Dogan <sup>a</sup>,  
Fatih Ozaltin <sup>d</sup>, Ali Duzova <sup>d</sup>, Rezan Topaloglu <sup>d</sup>, Bora Peynircioglu<sup>e</sup> and Metin Demircin <sup>a</sup>

<sup>a</sup> Department of Cardiovascular Surgery, Hacettepe University Hospital, Ankara, Turkey

<sup>b</sup> Department of Urology, Hacettepe University Hospital, Ankara, Turkey

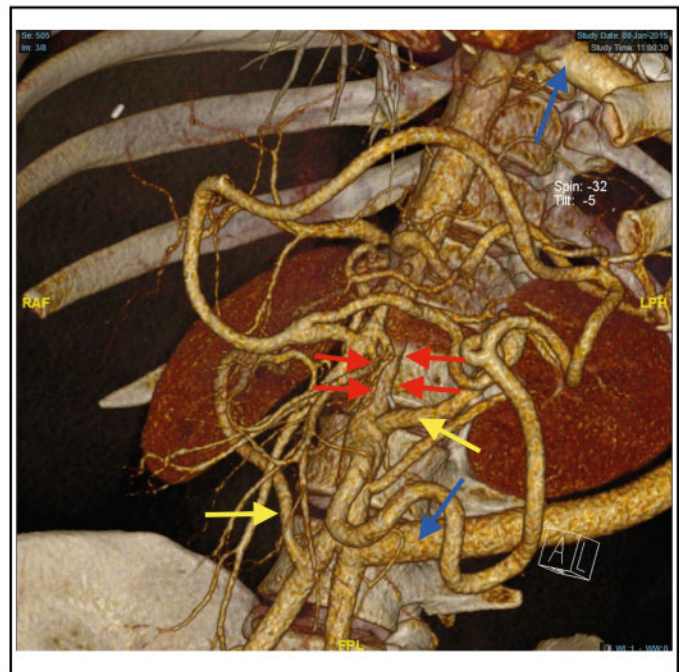
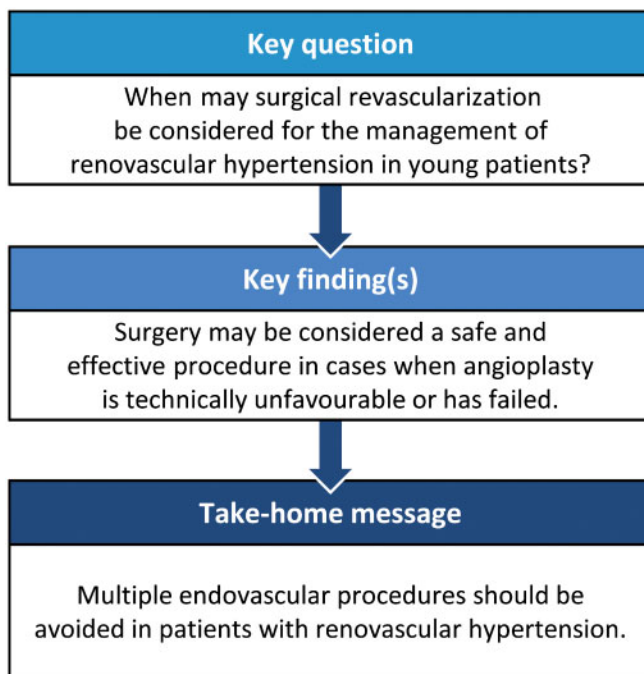
<sup>c</sup> Department of Cardiothoracic Surgery, Hacettepe University Hospital, Ankara, Turkey

<sup>d</sup> Department of Pediatric Nephrology, Hacettepe University Hospital, Ankara, Turkey

<sup>e</sup> Department of Radiology, Hacettepe University Hospital, Ankara, Turkey

\* Corresponding author. Department of Cardiovascular Surgery, Hacettepe University Hospital, Isci Blokları M. Budapeste C. No: 6/17, Cankaya, 06530 Ankara, Turkey. Tel: +90 505 5007960; fax: +03 123 100580; e-mail: ropeker@hacettepe.edu.tr (O. Peker).

Received 26 February 2019; received in revised form 28 May 2019; accepted 1 June 2019



### Abstract

**OBJECTIVES:** In this study, we aimed to evaluate the early and mid-term outcomes of surgery for renovascular hypertension (RVH) at our institution, within the last 13 years.

**METHODS:** We retrospectively reviewed 19 patients who underwent surgery for RVH, between 2005 and 2017. The age at operation, clinical characteristics, cause of arterial stenosis, diagnostic workup, surgical management and outcomes during the follow-up were analysed. The continuous variables were expressed as mean  $\pm$  standard deviation.

Presented at the 18th Turkish National Vascular and Endovascular Meeting, 9 November 2017.

**RESULTS:** Twelve female and 7 male patients underwent surgery for RVH. Their mean age was  $17.07 \pm 11.9$  years (range 4–42 years). Nine patients had renal arterial stenosis, and 10 patients had midaortic syndrome (MAS). Aortorenal bypass with the saphenous vein was performed in 6 patients with renal arterial stenosis and 1 patient with MAS. An isolated thoracic aorta-abdominal aortic bypass was performed in 1 patient with MAS, and thoracic aorta-abdominal aortic bypass combined with unilateral aortarenal bypass was performed in 9 patients with MAS. The other surgical procedures performed were 2 autotransplantations and 2 unilateral nephrectomies. Among the patients with MAS, 4 underwent reoperation. The mean follow-up duration was  $45.58 \pm 32.7$  months. Hypertension was cured in 3 patients and improved in 14 patients. The postoperative follow-up creatinine levels were similar to preoperative creatinine levels. All bypasses were patent on mid-term follow-up. One patient who underwent aortorenal bypass died 14 months postoperatively.

**CONCLUSIONS:** Surgical management is a suitable option for patients with RVH, who were unresponsive to medical and/or endovascular management. Surgical methods are safe and effective in children and young adults with RVH.

**Keywords:** Renovascular hypertension • Midaortic syndrome • Aortorenal bypass • Aorto-aortic bypass • Autotransplantation

## INTRODUCTION

Renovascular disease is a rare but significant cause of hypertension. It results from a lesion (or lesions) that reduces blood flow to the kidneys. Although its incidence is ~1% in the adult population, it accounts for 8–10% of all paediatric hypertension cases [1–5]. Headache, seizure, epistaxis, growth retardation, cognitive dysfunction, polyuria, palpitation and hemiplegia are mainly encountered complaints in symptomatic patients [2].

Antihypertensive (AH) drugs and endovascular procedures play important roles in the treatment of renovascular hypertension (RVH). Surgical revascularization usually has curative potential, preserves the renal tissues and prevents end organ damage [1, 6]. In this study, we aimed to evaluate the early and medium-term outcomes of surgery for refractory RVH, on the basis of our experience within the last 13 years.

## MATERIALS AND METHODS

### Patients

We retrospectively reviewed the medical records of 19 patients, who underwent surgery for RVH at Hacettepe University Hospital, between 2005 and 2017. The study was approved by the institutional review board of Hacettepe University Hospital (IRB number: 16969557-1795). Written informed consent was obtained from all patients or parents. Data obtained from the medical records during the initial and final follow-up clinic visits were used. We analysed the age at operation, clinical characteristics, cause of arterial stenosis, diagnostic workup, endovascular and surgical management and outcomes during follow-up. We conducted telephone interviews with patients who were lost to follow-up. The decision to perform surgery was made by a multidisciplinary team including nephrologists, interventional radiologists, urologists and vascular surgeons. After clinical evaluation and laboratory workup, AH drugs were used to achieve optimal blood pressure levels. In patients who were unresponsive to medication, we conducted imaging evaluations to identify the mechanical causes of RVH. We also checked for the presence of active inflammation before performing invasive procedures in patients who were eligible for surgical treatment. The appropriate medical therapy was administered to control the active state of the disease. For patients in whom endovascular management could not be performed or failed, surgical revascularization was

considered to maintain adequate renal perfusion and to treat RVH.

### Surgical approach

The thoracic aorto-abdominal aortic bypass was conducted through a left anterolateral thoracotomy incision in the 5th inter-space for the inflow from the distal thoracic aorta, and another incision was made below the umbilicus along the 11th and 12th ribs for the distal anastomosis. A graft was tunnelled through the posterolateral part of the left hemidiaphragm. The aortorenal bypass was conducted through a subcostal incision with a transperitoneal approach.

### Surgical procedures

The aortorenal bypass was performed in 6 patients with renal arterial stenosis (RAS) and in 1 patient with midaortic syndrome (MAS). A reversed proximal saphenous vein was anastomosed after the administration of heparin (100 units/kg) and mannitol. We used mannitol because it is an osmotic diuretic with antioxidant and renovascular effects that could preserve renal function. Both anastomoses were performed in an end-to-side manner with fine prolene sutures. Grafts were trimmed and positioned carefully to avoid kinking or twisting due to excessive length or poor positioning (Fig. 1). Autotransplantation was performed in 2 patients with RAS. Nephrectomy was performed in 2 patients with non-functional kidneys. The isolated thoracic aorto-abdominal aortic bypass was performed in 1 patient with MAS. Thoracic aorto-abdominal aortic bypass combined with unilateral aortarenal bypass was performed in 9 patients with MAS. The preferred conduit for aorto-aortic bypass was the knitted Dacron graft (Jotec<sup>®</sup>; GmbH, Hechingen, Germany).

### Clinical outcomes

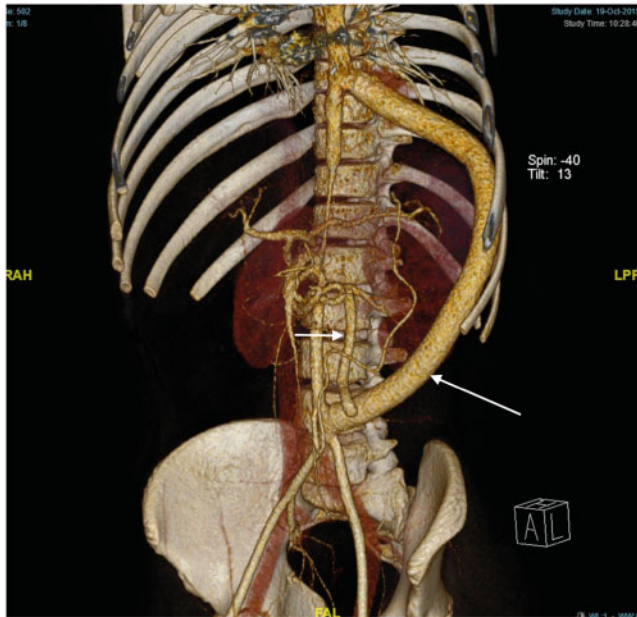
Surgical outcomes were evaluated on the basis of blood pressure measurements and the requirement for AH medication. Hypertension was defined as average systolic and/or diastolic blood pressure greater than or equal to the 95th percentile for sex, age and height [7]. Blood pressure response was assessed according to the modified 1987 Renal Working Group guidelines [8], as follows: (i) cure: normal blood pressure was achieved, eliminating the need for AH medications; (ii) improvement: normal blood pressure was achieved but the same or reduced

medications were still required; and (iii) failure: hypertension persisted or >3 medications were still required.

Renal function was evaluated by assessing the estimated glomerular filtration rate, which was calculated using the Modification of Diet in Renal Disease study equation.

## Statistical analysis

All data were analysed using the Statistical Package for Social Sciences (SPSS 16.0; SPSS Inc., Chicago, IL, USA). Categorical variables were presented as a number and compared using either the Pearson  $\chi^2$  test or the Fisher's exact test, in case the minimum expected number in each cell is <5. Continuous data were expressed as mean  $\pm$  standard deviation, 95% confidence interval



**Figure 1:** A 13-year-old male patient with the mid-aortic syndrome and left renal artery stenosis due to abdominal aortic coarctation presented to the clinic with a severe headache and recurrent hypertension with blood pressure reaching up to 190/120 mmHg despite taking 3 antihypertensive drugs. The computed tomographic angiographic image of a patent aorto-aortic bypass (big arrow) and prothiesiorenal interposition of the greater saphenous vein (small arrow) at the 2-year follow-up is shown. The patient's blood pressure decreased to 125/85 mmHg under medical treatment with a single beta-blocker.

(CI) and range. Continuous data were tested for normal distribution using the Shapiro-Wilk test and graphical methods (histogram, Q-Q plots). Between-group comparisons were performed using either the Student's *t*-test or the Mann-Whitney *U*-test for normal and non-normal distributed data, respectively. Paired *t*-test was used to compare the repetitive measurements of the creatinine values that fit the normal distribution.

## RESULTS

### Patient characteristics

Twelve female and 7 male patients who underwent surgical treatment for RVH were enrolled in this study. Their mean age was  $17.07 \pm 11.9$  years (95% CI 11.32–22.82). The mean duration of symptoms, preoperatively, was  $30.97 \pm 40.2$  months (95% CI 10.3–51.6). According to chronic kidney disease staging, 18 patients had stage I disease and 1 patient had stage IV disease. The mean sedimentation rate was  $6.6 \pm 2.4$  mm/h (95% CI 3.61–9.59) in patients with RAS and  $10.5 \pm 6.7$  mm/h (95% CI 3.42–17.58) in patients with MAS. The mean follow-up duration was  $45.58 \pm 32.7$  months (95% CI 28.75–62.42) (Table 1).

Nine patients had isolated RAS, and 10 patients had MAS (Tables 2 and 3). The associated diagnoses were Takayasu arteritis (TA), fibromuscular dysplasia and neurofibromatosis (NF) type 1 in 7, 4 and 2 patients, respectively. In patients with MAS, computed tomographic angiography (CTA) revealed stenosis of the middle aorta and the renal and visceral arteries [9, 10].

TA, characterized by non-specific chronic inflammation of the aorta and its branches, is a major cause of RVH in the young population, especially in Asian countries [5]. The diagnosis of TA was confirmed using the American College of Rheumatology-outlined criteria according to the characteristic clinical and radiological findings [11]. Fibromuscular dysplasia was defined as an idiopathic, segmental renal arterial occlusive disease with medial or perimedial hyperplasia [12].

### Clinical presentation

Uncontrolled hypertension was the major clinical finding in all patients. Each patient was initially treated with at least 3 AH medications. The main symptoms were a headache, abdominal pain, chest pain, vomiting and failure to thrive. Two patients were

**Table 1:** Clinical manifestations and patient characteristics

	All patients (n = 19)	RAS (n = 9)	MAS (n = 10)	P-value
Age (years), mean $\pm$ SD	17.07 $\pm$ 11.9	19.81 $\pm$ 15.9	14.6 $\pm$ 6.8	0.382
Gender (n) (female/male)	12/7	6/3	6/4	0.764
Duration of symptoms (months), mean $\pm$ SD	30.97 $\pm$ 40.2	35 $\pm$ 42.7	27.39 $\pm$ 40.1	0.606
CKD (n) Stage I/Stage IV	18/1	8/1	10/0	0.212
Associated diagnosis (n) TA/FMD/NF1	7/4/2	2/4/0	5/0/2	0.065
ESR (mm/h), mean $\pm$ SD	8.73 $\pm$ 5.4	6.60 $\pm$ 2.4	10.5 $\pm$ 6.7	0.253
Creatinine (preoperatively) (mg/dl), mean $\pm$ SD	0.62 $\pm$ 0.3	0.62 $\pm$ 0.38	0.61 $\pm$ 0.23	0.943
Creatinine (FU) (mg/dl), mean $\pm$ SD	0.61 $\pm$ 0.3	0.61 $\pm$ 0.46	0.61 $\pm$ 0.17	0.990
FU duration (months), mean $\pm$ SD	45.58 $\pm$ 32.7	27 $\pm$ 20.1	62.11 $\pm$ 33.3	0.022

CKD: chronic kidney disease; ESR: erythrocyte sedimentation rate; FMD: fibromuscular dysplasia; FU: follow-up; MAS: mid-aortic syndrome; NF1: neurofibromatosis type 1; RAS: renal artery stenosis; TA: Takayasu arteritis.

**Table 2:** Characteristics of the patients with renal artery stenosis

No	Age (years)	Gender	Number of interventional procedures before surgery	Operation	Creatinin (preoperative/FU) (mg/dl)	Graft patency
1	42	Female	1 (failed)	Right aortorenal bypass	0.75/0.6	Patent
2	24	Female	1	Left aortorenal bypass	0.95/0.78	Patent
3	5	Female	1	Left aortorenal bypass	0.39/0.3	Patent
4	4	Male		Right aortorenal bypass	0.36/0.37	Patent
5	33	Female	2	Autotransplantation	0.64/0.68	Patent
6	4.5	Male	1 (failed)	Right aortorenal bypass	0.52/0.38	Patent
7	34	Female	5	Autotransplantation	1.45/1.73	Patent
8	1.8	Female	1 (failed)	Left aortorenal bypass	0.3/0.24	Patent
9	4	Male		Nephrectomy	0.26/0.42	

FU: follow-up.

**Table 3:** Characteristics of the patients with midaortic syndrome

No	Age (years)	Gender	Site of aortic stenosis (suprarenal/renal)	Number of interventional procedures before surgery	Operation	Reoperation	Creatinine (preoperative/FU) (mg/dl)	Graft patency
1	15	Male	Renal		Aorto-aortic bypass + left aortorenal bypass		0.56/0.65	Patent
2	22	Female	Suprarenal		Aorto-aortic bypass		0.68/0.55	Patent
3	27	Male	Renal		Aorto-aortic bypass + left aortorenal bypass	Right iliorenal bypass	0.98/0.91	Patent
4	12	Female	Renal	3	Aorto-aortic bypass + left aortorenal bypass	Right iliorenal bypass	0.62/0.52	Patent
5	18	Female	Renal		Aorto-aortic bypass + left aortorenal bypass	Right iliorenal bypass	0.87/0.76	Patent
6	15	Male	Renal	2	Aorto-aortic bypass + left aortorenal bypass		0.58/0.63	Patent
7	4	Female	Renal		Left aortorenal bypass	Aorto-aortic bypass + left aortorenal bypass	0.24/0.44	Patent
8	14	Female	Renal	2	Aorto-aortic bypass + left aortorenal bypass		0.6/0.59	Patent
9	13	Male	Renal		Aorto-aortic bypass + left aortorenal bypass		0.72/0.73	Patent
10	6	Female	Renal	1	Nephrectomy	Aorto-aortic bypass + right aortorenal bypass	0.29/0.31	Patent

FU: follow-up.

asymptomatic, and RVH was incidentally diagnosed on routine physical examination.

### Endorgan function

The initial diagnostic workflow of patients included physical examination with fundoscopy, serum biochemical analysis, electrocardiography, echocardiography and renal Doppler ultrasonography. Sixteen patients had left ventricular hypertrophy on echocardiographic examination, and 1 patient had severe retinal vasculature changes. There was no dialysis-dependent patient in the study group.

### Anatomical characteristics

The most common MAS type was intrarenal, which was observed in 9 patients, followed by the suprarenal type, which was seen in

1 patient. None of our patients had infrarenal MAS. Coexisting abdominal aortic stenosis was detected in the coeliac artery, hepatoduodenal artery or superior mesenteric artery. The inferior mesenteric artery showed compensatory enlargement in those patients; therefore, they were asymptomatic and did not require any treatment. One patient with MAS had stenosis of the left pulmonary artery, and 1 patient with RAS had anterior mitral cleft with mild insufficiency.

### Preoperative imaging

The renal artery and aorta and its major branches were assessed using CTA in 13 patients. Digital subtraction renal angiography was performed in 11 patients who were candidates for endovascular intervention. Magnetic resonance angiography was performed in 2 patients.

## Percutaneous interventions

Preoperatively, 16 percutaneous renal artery interventions were performed in 7 patients; however, all of these cases necessitated surgical procedures during follow-up. In 3 patients, the percutaneous interventions were unsuccessful owing to technical reasons. Left renal artery embolization was performed before nephrectomy in 1 patient (Table 3; MAS group, patient no. 10). A repeat percutaneous transluminal renal angioplasty (PTRA) for right renal artery stenosis was performed (Table 3, MAS group, patient no. 4) in 1 patient with MAS at the 2-year follow-up.

## Histological examination

A pathological specimen of the thoracic aorta was obtained in 2 of the 19 patients. Marked intimal thickening, granulomatous inflammation and lymphocytic infiltration compatible with TA were observed on microscopic examination.

## Postoperative follow-up

Blood pressure levels were checked and creatinine levels were measured at each visit. Echocardiographic examinations were performed postoperatively, at the 6-month and 1-year follow-up. The postoperative follow-up creatinine levels were similar to preoperative creatinine levels in both groups (In RAS group 95% CI of the difference -0.104 to 0.131 and in MAS group 95% CI of the difference -0.68 to 0.78). The patency of the surgical bypasses was assessed using CTA, magnetic resonance imaging or duplex ultrasonography. CTA was scheduled at 1 and 12 months, postoperatively. Lifelong aspirin therapy was routinely prescribed in the postoperative period ( $5 \text{ mg kg}^{-1} \text{ day}^{-1}$  in children and 100 mg in adults). Patients who had active inflammation were prescribed steroids or immunosuppressive agents.

During the follow-up, AH drugs were discontinued in 3 patients who were identified to be normotensive. Fourteen patients were normotensive and required less AH drugs than the ones, which were used previously. However, in 2 patients in the MAS group, blood pressure was not controlled despite surgery (Table 3; patient nos. 7 and 10).

## Early and medium-term outcomes

None of the patients died in the early perioperative period and during the follow-up. The mean follow-up time was  $47.4 \pm 31.5$  months. All aortic and aortorenal bypasses were found to be patent in the imaging evaluation performed during the last follow-up. A 13-year-old male patient with MAS and left renal artery stenosis, in whom an aorto-aortic Dacron bypass and prothiorenal interposition of the greater saphenous vein were performed, had patent grafts during the 2-year follow-up CTA (Table 3; patient no. 9) (Fig. 1).

A 15-year-old male patient with MAS developed hydronephrosis at 7 days postoperatively, which was treated with a J stent (Table 3; patient no. 6). Another 15-year-old male patient with MAS (Table 3; patient no. 1) developed pleuropericarditis postoperatively at 1 month, which was treated with a pleuropericardial window.

A 34-year-old female patient with RAS and associated TA had stage IV chronic kidney disease and a history of right

nephrectomy (Table 2; patient no. 7). She was taking cyclophosphamide and uromitexan. Stenting and balloon angioplasty were performed once in her nephrectomized right kidney and 4 times in her left kidney. Because neither attempt was able to maintain adequate blood flow, she underwent autotransplantation for acute renal failure, which was successful. At 4 weeks postoperatively, she developed perirenal collection and was treated with percutaneous drainage. Her kidney was functioning well at the 11-month follow-up.

Reoperation was performed in 5 patients in the MAS group because of uncontrolled hypertension or progression of arteritis. During our initial experience in the early years in this study group, we performed reoperation in a 4-year-old girl with MAS and TA, who had high B-type natriuretic peptide levels, showed progression of TA in the abdominal aorta and had concurrent saphenous graft aneurysm at 1 year after the aortorenal bypass procedure (Table 3; patient no. 7). We resected the aneurysmatic graft sac, recreated an aortorenal bypass with a saphenous vein and reconstructed an aorto-aortic bypass with a 10-mm Dacron graft thereafter. Unfortunately, she had poor blood pressure control despite having patent grafts, which were confirmed on CTA performed 40 months postoperatively. Another patient, a 6-year-old girl with NF and MAS, first underwent unilateral nephrectomy and then aorto-aortic and right aortorenal bypass 20 months thereafter for hypertension control; however, her blood pressure was still poorly controlled (Table 3; patient no. 10). Owing to the poor blood pressure control in 3 patients with MAS, right iliorenal bypasses with an autologous saphenous vein were performed after the initial procedure, which achieved a successful blood pressure response during the follow-up.

A 42-year-old female patient with a solitary kidney (Table 2; patient no. 1) died of a cerebrovascular accident at 14 months postoperatively.

## DISCUSSION

The current study reviewed the surgical management of RVH in children and young adults with lesions isolated in the renal artery or coexisting lesions in the abdominal aorta and its branches. Surgical treatment is necessary for patients who are refractory to AH drug therapy with target-organ damage or in those who are unresponsive to endovascular interventions. The aetiological factors for RVH were TA, fibromuscular dysplasia, NF and MAS in this study. We observed a high incidence of TA, which is common in Asian countries. Surgical and endovascular procedures in patients with vasculitis have to be performed once the active phase of the disease is controlled with appropriate medical therapy.

The diagnostic methods include duplex ultrasonography, CTA, contrast-enhanced magnetic resonance angiography, selective or non-selective contrast angiography and central vein renin sampling [13]. At our centre, we prefer CTA, as we consider it a useful diagnostic and follow-up method that could be used to check disease progression, bypass graft patency and restenosis after PTRA.

Pre- and postoperative plasma renin activity and aldosterone levels might have provided objective evidence to be discussed if we had; however, as this is a retrospective study and checking these lab parameters were not a routine procedure given the fact that its sensitivity and specificity are low in RVH, these lab measurements were not available in our study cohort [14].

Even after interventional or surgical treatment, patients with RVH may still have uncontrolled hypertension despite the use of multiple AH drugs. Therefore, aggressive medical therapy should be an integral part of the treatment. The timing of revascularization is also important. The clinical criteria for revascularization in the presence of a significant RVH include poor blood pressure control despite the use of multiple AH drugs, evidence of end-organ damage and renal function deterioration resulting in decreased renal size and loss of renal mass [5]. Moreover, poor compliance with medications is one of the relative indications for surgery in these patients [15].

Currently, PTRAs are often preferred to the more invasive surgical interventions for renovascular lesions, and surgical repair is delayed in infants [6]. It is reasonable to delay surgery in younger children, as it is known that surgical procedures can be successfully performed after the age of 3 years [16]. In children, developmentally abnormal vessels are likely to be resistant to balloon dilation even with stenting because of their hypoplastic and fibrotic nature [17]. We observed procedural angioplasty failure and restenosis in 3 and 4 paediatric patients, respectively. Accordingly, in cases of uncontrolled (especially symptomatic) RVH, renal artery lesions should be repaired regardless of age. At our centre, a 22-month-old girl who had severe and symptomatic hypertension despite medical therapy, due to left renal artery stenosis, underwent an aortorenal bypass with an autologous saphenous vein after a failed balloon angioplasty attempt. Therefore, personalization of the treatment strategy may be required according to each patient's clinical situation and the severity of the clinical problem.

At our medical centre for RVH during the last 13 years, medical treatment and PTRAs were the primary approaches. Surgical treatment was reserved for long-segment and complex renal artery stenosis, abdominal aorta or branch renal artery involvement, failed angioplasty and procedural complications [5].

RVH could be treated surgically using a variety of techniques including arterial reconstruction with autologous or synthetic grafts, renal artery reimplantation, autotransplantation and nephrectomy [18, 19].

Renal autotransplantation should be the final approach for preventing kidney loss in renovascular diseases and when conventional methods have failed [20]. Autotransplantation was performed in 2 patients with RAS. One patient had a renal artery aneurysm that was not suitable for reconstruction, and the other patient had an evolving acute renal failure secondary to stent restenosis and failed angioplasty. The last patient had stent restenosis and underwent a total of 5 procedural interventions. Thus, multiple percutaneous interventions should be avoided owing to the risk of endothelial damage and intimal proliferation.

Most studies have reported a high incidence of aneurysmal dilatation after renal revascularization procedures with saphenous vein grafts [21, 22]. Destruction of the elastic component of the media occurring before fibrosis of the adventitia may cause aneurysm [23]. The internal iliac, splenic, hepatic and gastroduodenal arteries were reported in the literature as the conduits of choice for aortorenal bypass in children [18, 24]. Excellent results of direct renal artery implantation were reported by Stanley *et al.* [16] in 97 children with RVH.

Feng *et al.* [25] reported that aortorenal bypass with an autologous saphenous vein graft is a safe, effective and durable method for TA-induced RAS, leading to marked improvements in blood

pressure control and renal and cardiac function. We also used an autologous saphenous vein and observed a significant graft aneurysm in only 1 patient.

An anastomotic aneurysm is another common surgical complication. Although the present study results seem favourable, as there were no cases of anastomotic aneurysms, regular imaging follow-up for arterial complications is necessary.

RAS and coarctation of the thoracic aorta are the most common surgical causes of hypertension in infants. The aetiology of MAS is unknown. However, its association with NF and William's and Alagille's syndromes has been described [26, 27]. Mesenteric vascular stenosis (coeliac and/or superior mesenteric artery) is usually silent. Additional mesenteric or iliac reconstructions are rarely necessary. Dacron or Goretex prosthetic grafts are used for aorto-aortic bypass. The long-term patency is good with a single antiplatelet agent (acetylsalicylic acid), and anticoagulation is not required [22].

Favourable long-term hypertension outcomes with no perioperative deaths were reported in the literature, and >90% of patients have benefited from surgical treatment [28, 29]. There may be some exceptions, and some patients will need reoperations because of progression of the disease or growth of the patient. Surgery offers a cure or at least a marked improvement in RVH in these age groups [6].

We presented our surgical experience in 19 children and young adults with RVH. We preferred aortorenal bypass with a free graft of autogenous saphenous vein and aorto-aortic bypass with a Dacron graft. Autotransplantation and nephrectomy, as the last treatment options, were the other options in our patient group.

## Limitations

This study has several limitations. First, it is a retrospective case series with a limited number of patients. Second, given the size of our study population, the results of the surgical bypass with respect to the autogenous vein grafts have to be clarified in studies with a larger number of patients.

## CONCLUSION

In conclusion, surgery is a relatively safe but secondary treatment option for patients with severe RVH. Although interventional procedures are the initial treatment options for RVH, multiple interventional procedures should be avoided in patients who can tolerate surgical management. The role of percutaneous intervention is very limited in MAS, and we primarily prefer surgical management in this subgroup of patients.

## Funding

The authors received no financial support for the research, authorship, and/or publication of this article.

**Conflict of interest:** none declared.

## REFERENCES

- [1] Shroff R, Roebuck DJ, Gordon I, Davies R, Stephens S, Marks S. Angioplasty for renovascular hypertension in children: 20-year experience. *Pediatrics* 2006;118:268–75.
- [2] Bayazit AK, Yalcinkaya F, Cakar N, Duzova A, Bircan Z, Bakkaloglu A. Reno-vascular hypertension in childhood: a nationwide survey. *Pediatr Nephrol* 2007;22:1327–33.
- [3] Novick AC, Benjamin S, Straffon RA. Stenosing renal artery disease in children: clinicopathologic correlation and results of surgical treatment. *Nephron* 1978;22:182–95.
- [4] Lawson JD, Boerth R, Foster JH, Dean RH. Diagnosis and management of renovascular hypertension in children. *Arch Surg* 1977;112:1307.
- [5] Tullus K, Brennan E, Hamilton G, Lord R, McLaren CA, Marks SD *et al.* Renovascular hypertension in children. *Lancet* 2008;371:1453–63.
- [6] Sandmann W, Dueppers P, Pourhassan S, Voiculescu A, Klee D, Balzer KM. Early and long-term results after reconstructive surgery in 42 children and two young adults with renovascular hypertension due to fibromuscular dysplasia and middle aortic syndrome. *Eur J Vasc Endovasc Surg* 2014;47:509–16.
- [7] National High Blood Pressure Education Program Working Group on High Blood Pressure in Children and Adolescents. The fourth report on the diagnosis, evaluation, and treatment of high blood pressure in children and adolescents. *Pediatrics* 2004;114:555–76.
- [8] Kimura H, Sato O, Deguchi JO, Miyata T. Surgical treatment and long-term outcome of renovascular hypertension in children and adolescents. *Eur J Vasc Endovasc Surg* 2010;39:731–7.
- [9] O'Neill JA, Berkowitz H, Fellows KJ, Harmon CM. Midaortic syndrome and hypertension in childhood. *J Pediatr Surg* 1995;30:164–72.
- [10] Lewis VD, Meranze SG, Mclean GK, O'Neill JA Jr, Berkowitz HD, Burke DR. The midaortic syndrome: diagnosis and treatment. *Radiology* 1988; 167:111–13.
- [11] Arend WP, Michel BA, Bloch DA, Hunder GG, Calabrese LH, Edworthy SM *et al.* The American College of Rheumatology 1990 criteria for the classification of Takayasu arteritis. *Arthritis Rheum* 1990;33:1129–34.
- [12] Plouin PF, Perdu J, Batide-Alanore AL, Boutouyrie P, Gimenez-Roqueplo AP, Jeunemaitre X. Fibromuscular dysplasia. *Orphanet J Rare Dis* 2007;2: 28.
- [13] Safian RD, Textor SC. Renal-artery stenosis. *N Engl J Med* 2001;344: 431–42.
- [14] Wilcox CS. Use of angiotensin-converting-enzyme inhibitors for diagnosing renovascular hypertension. *Kidney Int* 1993;44:1379.
- [15] Chalmers R, Dhadwal A, Deal J, Sever PS, Wolfe JH. The surgical management of renovascular hypertension in children and young adults. *Eur J Vasc Endovasc Surg* 2000;19:400–5.
- [16] Stanley JC, Criado E, Upchurch GR, Brophy PD, Cho KJ, Rectenwald JE *et al.* Pediatric renovascular hypertension: 132 primary and 30 secondary operations in 97 children. *J Vasc Surg* 2006;44:1219–28.
- [17] Eliason JL, Coleman DM, Criado E, Kershaw DB, Blatt NB, Williams DM *et al.* Remedial operations for failed endovascular therapy of 32 renal artery stenoses in 24 children. *Pediatr Nephrol* 2016;31:809–17.
- [18] Lillehei CW, Shamberger RC. Staged reconstruction for middle aortic syndrome. *J Pediatr Surg* 2001;36:1252–4.
- [19] Deal JE, Snell MF, Barrat TM, Dillon MJ. Renovascular disease in childhood. *J Pediatr* 1992;121:378–84.
- [20] Azhar B, Patel S, Chadha P, Hakim N. Indications for renal autotransplant: an overview. *Exp Clin Transplant* 2015;13:109–14.
- [21] Stanley JC, Ernst CB, Fry WJ. Fate of 100 aortorenal vein grafts: characteristics of late graft expansion, aneurysmal dilatation, and stenosis. *Surgery* 1973;74:931–44.
- [22] Stadermann MB, Montini G, Hamilton G, Roebuck DJ, McLaren CA, Dillon MJ *et al.* Results of surgical treatment for renovascular hypertension in children: 30 year single centre experience. *Nephrol Dial Transplant* 2010;25:807–13.
- [23] Kim S, Jung I, Han A, Min SI, Lee T, Ha J *et al.* Surgical treatment of middle aortic syndrome with Takayasu arteritis or midaortic dysplastic syndrome. *Eur J Vasc Endovasc Surg* 2015;50:206–12.
- [24] Stanley JC, Zelenock GB, Messina LM, Wakefield TW. Pediatric renovascular hypertension: a thirty-year experience of operative treatment. *J Vasc Surg* 1995;21:212–26.
- [25] Feng R, Wei X, Zhao Z, Bao J, Feng X, Qu L *et al.* Aortorenal bypass with autologous saphenous vein in Takayasu arteritis-induced renal artery stenosis. *Eur J Vasc Endovasc Surg* 2011;42:47–53.
- [26] Panayiotopoulos YP, Tyrrell MR, Koffman G, Reidy JF, Haycock GB, Taylor PR. Mid-aortic syndrome presenting in childhood. *Br J Surg* 1996; 83:235–40.
- [27] Shefler AG, Chan MKH, Ostman-Smith I. Middle aortic syndrome in a boy with arteriohepatic dysplasia (Alagille syndrome). *Pediatr Cardiol* 1997;18:232–4.
- [28] Piercy KT, Hundley JC, Stafford JM, Craven TE, Nagaraj SK, Dean RH *et al.* Renovascular disease in children and adolescents. *J Vasc Surg* 2005; 41:973–82.
- [29] Lacombe M. Surgical treatment of renal artery lesions in children. *Chirurgie* 1999;124:264–71.