



Management of bone disease in cystinosis: Statement from an international conference

Katharina Hohenfellner¹ | Frank Rauch² | Gema Ariceta³ | Atif Awan⁴ | Justine Bacchetta⁵ | Carsten Bergmann⁶ | Susanne Bechtold⁷ | Noelle Cassidy⁸ | Geroges Deschenes⁹ | Ewa Elenberg¹⁰ | William A. Gahl¹¹ | Oliver Greil¹² | Erik Harms¹³ | Nadine Herzig¹⁴ | Bernd Hoppe¹⁵ | Christian Koepl¹⁶ | Malcolm A. Lewis⁴ | Elena Levchenko¹⁷ | Galina Nesterova¹⁸ | Fernando Santos¹⁹ | Karl P. Schlingmann²⁰ | Aude Servais²¹ | Neveen A. Soliman²² | Guenther Steidle¹⁶ | Clodagh Sweeney⁴ | Ulrike Treikuskas²³ | Rezan Topaloglu²⁴ | Alexey Tsygin²⁵ | Koenraad Veys¹⁷ | Rodo v. Vigier²⁶ | Jozef Zustin²⁷ | Dieter Haffner²⁸

¹Ro Med Kliniken, Pediatric Nephrology, Rosenheim, Germany

²Shriners Hospital for Children, McGill University, Montreal, Canada

³Service of Pediatric Nephrology, University Hospital Vall d' Hebron, Barcelona, Spain

⁴Department of Nephrology, Children's University Hospital, Dublin, Ireland

⁵Référence Center for Rare Renal Diseases, Hôpital Femme-Mère-Enfant, Bron, France

⁶Department of Medicine, University Hospital Freiburg, Freiburg, Germany

⁷Division of Pediatric Endocrinology, Children's Hospital and Polyclinic iSPZ, Dr. v. Haunerschen Kinderspital, University Hospital Munich, Munich, Germany

⁸Department of Orthopaedic Surgery, Children's University Hospital, Dublin, Ireland

⁹Department of Pediatric Nephrology, Hôpital Robert-Debré and University of Paris Diderot, Paris, France

¹⁰Department of Pediatrics, Baylor College of Medicine and Texas Children's Hospital, Houston, Texas

¹¹National Human Genome Research Institute, National Institutes of Health Undiagnosed Diseases Program, Bethesda, Maryland

¹²Department of Diagnostic and Interventional Radiology, Klinikum Traunstein, Traunstein, Germany

¹³Children's University Hospital Muenster, Muenster, Germany

¹⁴Schoen Clinic Munich Harlaching, Specialist Centre for Paediatric and Neuro-Orthopaedics, Munich, Germany

¹⁵Division of Pediatric Nephrology, University Children's Hospital, Bonn, Germany

¹⁶Kliniken Südostbayern AG, Sozialpädiatrisches Zentrum, Traunstein, Germany

¹⁷Department of Pediatrics & Development and Regeneration, University Hospitals Leuven & Katholieke Universiteit Leuven, Leuven, Belgium

¹⁸National Institutes of Health, National Human Genome Research Institute (NHGRI), Bethesda, Maryland

¹⁹Hospital Universitario Central de Asturias, Pediatría, Oviedo, Spain

²⁰Department of General Pediatrics, University Children's Hospital Münster, Münster, Germany

²¹Reference Center of Inherited Metabolic Diseases, Nephrology Unit, Hospital Necker Enfants Malades, APHP, University Paris Descartes, Paris, France

²²Department of Pediatrics, Center of Pediatric Nephrology and Transplantation (CPNT), Kasr Al Ainy Faculty of Medicine, Cairo University, Cairo, Egypt

²³Department of Pediatrics, Department of Pediatric Nephrology, Ro-Med Kliniken, Rosenheim, Germany

²⁴Department of Pediatric Nephrology, Hacettepe University Faculty of Medicine, Ankara, Turkey

²⁵Department of Nephrology, National Medical and Research Center for Children's Health, Moscow, Russia

This is an open access article under the terms of the Creative Commons Attribution-NonCommercial-NoDerivs License, which permits use and distribution in any medium, provided the original work is properly cited, the use is non-commercial and no modifications or adaptations are made.

© 2019 The Authors. *Journal of Inherited Metabolic Disease* published by John Wiley & Sons Ltd on behalf of SSEIM

²⁶Pediatric Clinic, Wildermeth Children's Hospital, Biel-Bienne, Switzerland

²⁷Institute of Osteology and Biomechanics, University Medical Center Hamburg-Eppendorf, University of Hamburg, Hamburg, Germany

²⁸Department of Pediatric Kidney, Liver and Metabolic Diseases, Hannover Medical School, Hannover, Germany

Correspondence

Katharina Hohenfellner, Abt.
Kinderneurologie, Klinik für Kinder und
Jugendheilkunde, Pettenkoferstrasse
10, 83022 Rosenheim, Germany.

Email: katharina.hohenfellner@ro-med.de

Communicating Editor: Gregory M. Pastores

Funding information

Cystinosis Foundation Germany ; Cystinosis
Foundation

Abstract

Cystinosis is an autosomal recessive storage disease due to impaired transport of cystine out of lysosomes. Since the accumulation of intracellular cystine affects all organs and tissues, the management of cystinosis requires a specialized multidisciplinary team consisting of pediatricians, nephrologists, nutritionists, ophthalmologists, endocrinologists, neurologists' geneticists, and orthopedic surgeons. Treatment with cysteamine can delay or prevent most clinical manifestations of cystinosis, except the renal Fanconi syndrome. Virtually all individuals with classical, nephropathic cystinosis suffer from cystinosis metabolic bone disease (CMBD), related to the renal Fanconi syndrome in infancy and progressive chronic kidney disease (CKD) later in life. Manifestations of CMBD include hypophosphatemic rickets in infancy, and renal osteodystrophy associated with CKD resulting in bone deformities, osteomalacia, osteoporosis, fractures, and short stature. Assessment of CMBD involves monitoring growth, leg deformities, blood levels of phosphate, electrolytes, bicarbonate, calcium, and alkaline phosphatase, periodically obtaining bone radiographs, determining levels of critical hormones and vitamins, such as thyroid hormone, parathyroid hormone, 25(OH) vitamin D, and testosterone in males, and surveillance for nonrenal complications of cystinosis such as myopathy. Treatment includes replacement of urinary losses, cystine depletion with oral cysteamine, vitamin D, hormone replacement, physical therapy, and corrective orthopedic surgery. The recommendations in this article came from an expert meeting on CMBD that took place in Salzburg, Austria, in December 2016.

KEYWORDS

chronic kidney disease, CKD-MBD, cystinosis, cystinosis metabolic bone disease, Fanconi syndrome, hypophosphatemic rickets, transplantation

1 | INTRODUCTION

Cystinosis is an autosomal recessive lysosomal storage disorder caused by mutations in the *CTNS* gene.^{1,2} *CTNS* encodes the lysosomal cystine transporter cystinosin, whose deficiency results in the accumulation of cystine in all organs and tissues. In the most common nephropathic form of cystinosis, infants present with Fanconi syndrome, a generalized dysfunction of the proximal tubule characterized by urinary wasting of water, electrolytes, minerals, bicarbonate, glucose, amino acids, and other molecules. The metabolic consequences include hypophosphatemic rickets and growth failure. Later in life, individuals with cystinosis also suffer from mineral and bone disorders related to chronic kidney disease (CKD-MBD), including renal osteodystrophy,

resulting in a complex bone phenotype termed cystinosis metabolic bone disease (CMBD).³⁻⁵ The treatment of cystinosis involves replacement of renal losses, symptomatic management of nonrenal complications and, most critically, cystine-depleting therapy with oral cysteamine.^{6,7} Both the early Fanconi syndrome and later CKD contribute to the bone changes of CMBD. In addition, a primary osteoblast and osteoclastic defect, abnormal thyroid metabolism, glucocorticoid treatment after renal transplantation and, rarely, cysteamine toxicity may further complicate CMBD.⁸ Nevertheless, there exists a paucity of specific recommendations for diagnosis and management of CMBD.

Here, we review the clinical features of cystinosis related to CMBD and present recommendations for management, developed during a meeting in Salzburg, Austria, in

December 2016. They are aimed at nephrologists, metabolic physicians, and general practitioners who care for patients with cystinosis.

2 | CYSTINOSIS BACKGROUND

Infants with nephropathic cystinosis appear normal at birth. However, failure to grow generally occurs at 6 to 9 months of age, when renal Fanconi syndrome develops.⁵ Early diagnosis is critical because cystinosis is treatable. Diagnosis is primarily based on detection of elevated cystine concentration in polymorphonuclear leukocytes at any age, and identification of cystine crystals in the cornea on slit lamp examination in older children (age >2 years). If available, diagnosis should be confirmed by identification of biallelic pathogenic variants in CTNS on molecular genetic testing. In case of a positive family history increased cystine content in cultured fibroblasts or in the placenta at the time of birth are also proving.

The Fanconi syndrome in cystinosis causes severe polyuria (2-10 L/d), polydipsia, dehydration (sometimes with fever), hypophosphatemia, hypokalemia, and hypochloremic metabolic acidosis.⁵ Treatment involves replacement of tubular losses of water, electrolytes, bicarbonate, phosphate, vitamin D, and other nutrients.⁵ Children should have free access to water, and intravenous delivery may be required in cases of dehydration. Potassium is typically supplemented 3 to 4 times per day as the citrate, bicarbonate, or chloride salts, and high doses (6-10 mEq/kg/d) may only achieve a serum level of 3.0 mEq/mL. Most patients receive sufficient sodium from their diet and medications. Early gastric tube placement may be required to deliver nutrition or medications.

Indomethacin, which can decrease polyuria by 30% to 70% and improve weight gain in young patients,⁹ may decrease renal perfusion due to its suppressive effects on local production of prostaglandins, which are mandatory to maintain renal perfusion in states of dehydration. Therefore, indomethacin should be discontinued if a patient becomes dehydrated, hypotensive, or develops advanced CKD (>stage 3).

Without cysteamine treatment, renal glomerular damage progresses inexorably, culminating in end-stage kidney disease (ESKD) by approximately 10 years of age and requiring dialysis or kidney transplantation; patients with cystinosis do well following renal transplantation. Oral cysteamine therapy drastically lowers intracellular cystine and, while it does not ameliorate the Fanconi syndrome, slows the progression of CKD,^{6,7} delays the need for renal replacement therapy,¹⁰⁻¹² enhances growth, and prevents late complications of the disease.¹³ The recommended dosage is 60 to 90 mg/kg/d or 1.3-1.95 g/m²/d, intended to achieve a leukocyte cystine level <1.0 nmol half-cystine/mg of protein. Oral cysteamine has an unpleasant taste and smell, and induces nausea and other digestive complaints, so only one third of

patients strictly comply with the dosage regimen, particularly in adolescence.^{11,14} Patients with gastric side effects of cysteamine therapy can benefit from medications such as omeprazole or ranitidine.¹⁵

Other tissue and organ damage occur in cystinosis due to the accumulation of intracellular cystine. Corneal crystals are visible by 16 months of age and can be dissolved with topical cysteamine eyedrops, that is, Cystaran¹⁶ or Cystadrops.¹⁷ Hypothyroidism results from direct damage to the thyroid gland, the first sign usually being elevated thyroid-stimulating hormone (TSH). Growth retardation represents a major problem in cystinosis. Typically, infants are at the third percentile for height at 1 year of age, and without adequate treatment, have low growth velocity.⁴ While nutrition, phosphate supplementation, and oral cysteamine therapy can achieve a normal growth rate, the addition of growth hormone (GH) therapy can provide catch-up growth, particularly when used in children prior to dialysis.¹⁸

Gonadal dysfunction, that is, hypergonadotropic hypogonadism, largely affects males, often results in delayed puberty, and is characterized by low levels of testosterone and very high levels of luteinizing hormone (LH) and follicle-stimulating hormone (FSH). Testosterone supplementation can be used to manage gonadal dysfunction. Since adult males with cystinosis are infertile but show viable epididymal sperm,¹⁹ sperm preservation can be considered. Puberty is generally delayed by 1 to 2 years in males and some females with cystinosis, but ovarian function is preserved and several women with cystinosis have delivered healthy babies.²⁰

Other complications of cystinosis include a distal vacuolar myopathy (Figure 1), exocrine and endocrine pancreatic dysfunction, benign intracranial hypertension, and retinal

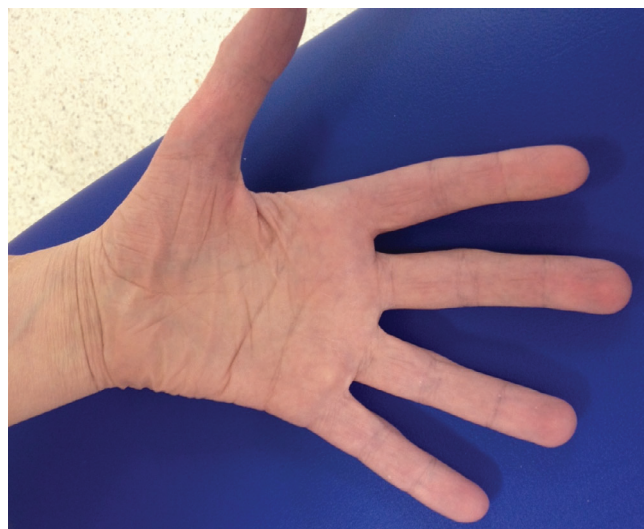

FIGURE 1 Distal myopathy of cystinosis, with atrophy of the thenar and hypothenar eminences

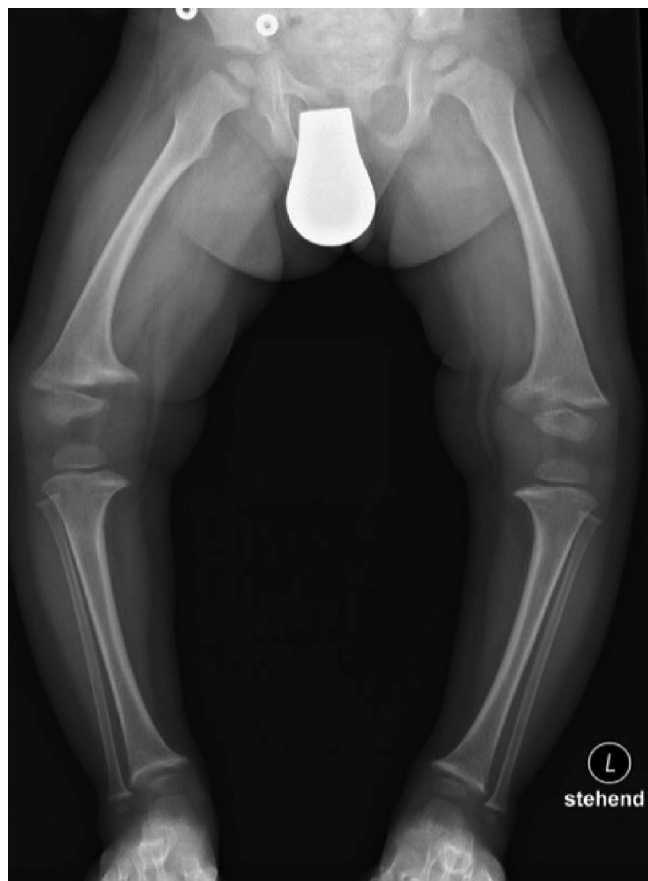

FIGURE 2 Active rachitic bone disease on X-ray of both legs. Note reduced bone density, widening of the metaphyses, and fraying of the epiphyses

blindness,²¹ often causing restrictive lung disease and/or swallowing difficulty.²² Most complications can be prevented with early and lifelong cystine-depleting therapy.

3 | CYSTINOSIS METABOLIC BONE DISEASE

3.1 | Clinical characteristics

CMBD can manifest as rickets (Figure 2) and renal osteodystrophy, including growth failure, bone pain,

deformations, osteomalacia, and osteoporosis. Patients may have short stature spontaneous fractures (Table 1). In infants and young children, rickets causes bone deformities, including genu valgum (Figure 3) and genu varus, making walking painful enough to delay ambulation.^{5,23} Clinical signs of rickets typically include widening of the forearm at the wrist and thickening of the costochondral junctions. In addition, a rachitic rosary and Harrison's groove may also develop. Another radiographic sign of rickets is increased thickness of the growth plates of the long bones, with irregular, hazy appearance at the diaphyseal line.

As children with cystinosis lose glomerular function, CKD-MBD becomes prominent.^{24,25} CKD-MBD is a systemic disorder of mineral and bone metabolism manifested by one or a combination of the following: (a) abnormalities of calcium, phosphorus, intact serum parathyroid hormone (PTH), or vitamin D metabolism; (b) abnormalities in bone turnover, mineralization, volume, linear growth, or strength (renal osteodystrophy); and (c) vascular or other soft-tissue calcification.^{24,25}

3.2 | Pathogenesis of CMBD

Many factors contribute to the bone disease of cystinosis (Figure 4). Perhaps the most devastating is early-onset Fanconi syndrome, with its renal losses of phosphate, calcium, and bicarbonate and diminished synthesis of active vitamin D causing hypophosphatemia, acidosis, and sometimes hypocalcemia, leading to rickets and osteomalacia.^{26,27} Acidosis due to tubular losses of bicarbonate impairs bone mineralization, and caloric and protein malnutrition due to ingestion of excess fluids lacking calories, along with CKD, may further contribute to poor bone health. Later in childhood, progressive loss of glomerular function results in CKD-MBD, as observed in patients with other causes of CKD.

In CMBD, interactions among bone, joints, and muscle are critical. Muscle and bone form a functional unit, with mechanical stimulation through muscle activity driving bone development.²⁸ Consequently, impaired muscle function,

TABLE 1 Pathological conditions of CMBD

	Pathophysiology	Histology	Radiography	Clinical picture
Osteomalacia	Deficit of mineralization of bone matrix: <ul style="list-style-type: none"> • Normal amount of bone matrix • Low ratio of mineral in bone matrix 	<ul style="list-style-type: none"> • Excess of unmineralized bone (osteoid) 	<ul style="list-style-type: none"> • Growth plates appear wide with fuzzy borders 	<ul style="list-style-type: none"> • Rickets in infancy • Genu valgum • Delayed ambulation
Osteoporosis	<ul style="list-style-type: none"> • Low amount of bone matrix • Normal ratio of mineral to bone matrix 	<ul style="list-style-type: none"> • Reduced bone matrix (osteoblasts) • Increased bone resorption (osteoclasts) 	<ul style="list-style-type: none"> • Transparency of bone • Reduced cortical bone 	<ul style="list-style-type: none"> • Increased disposition towards fractures

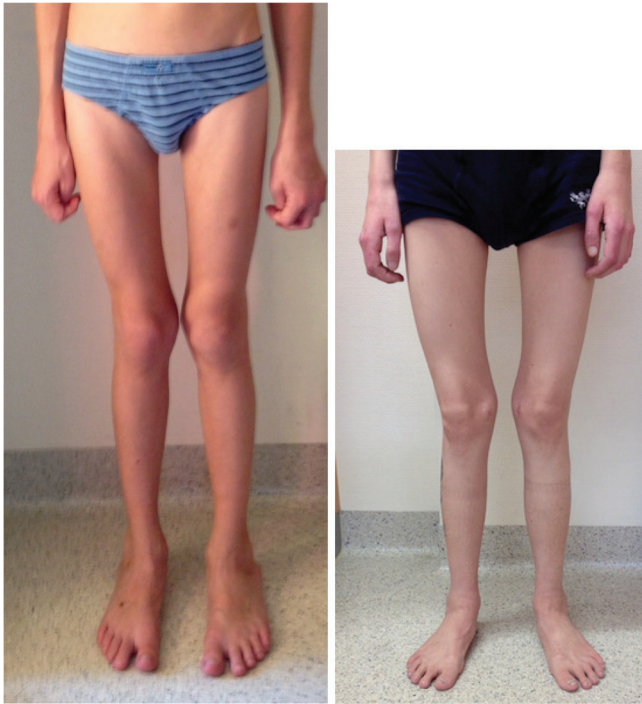


FIGURE 3 Muscular atrophy and bone deformation, that is, genu valgum

which is often observed in cystinosis, leads to disturbances of bone development. Furthermore, reduced plasma and muscle levels of carnitine in pretransplant patients with cystinosis²⁹ may impair the functionality of the muscle/bone unit.²¹

GH, LH, FSH, androgens/estrogens, insulin-like growth factor (IGF)-1, insulin, amylin, and TSH/thyroxine all contribute to maintaining normal bone metabolism. This balance is disrupted in cystinosis. Cystine accumulation in thyroid follicular cells causes fibrosis and atrophy.⁹ Moreover, decreased thyroglobulin synthesis due to endoplasmic reticulum stress/unfolded protein response and impaired lysosomal processing has been demonstrated in a mouse model of cystinosis.³⁰ Consequently, hypothyroidism often appears in the first decade of life and can contribute to growth retardation.¹⁵ In addition, poor nutrition may result in reduced IGF-1 serum levels and, in advanced CKD, lack of sensitivity to endogenous GH and IGF-1 can further impede growth.^{31,32} Cystine crystals in bone may also impair growth. Finally, treatment with glucocorticoids limits catch-up growth after renal transplantation and may cause osteoporosis with increased fracture risk, as seen in other patients with renal allografts.⁸

Interestingly, knockout of *Ctns* in mice did not result in full-blown Fanconi syndrome, yet these animals showed osteopenia with decreased mineralization and cortical thickness (long bones and vertebrae), raising the hypothesis of a specific underlying bone defect in cystinosis.³³ Indeed, pre-clinical studies suggest that mutations in *CTNS* may reduce the ability of osteoblast precursor cells to transform into mature osteoblasts capable of synthesizing osteoid, further contributing to defective mineralization and rickets.³⁴ Moreover, low doses of cysteamine in vitro stimulate osteoblastic

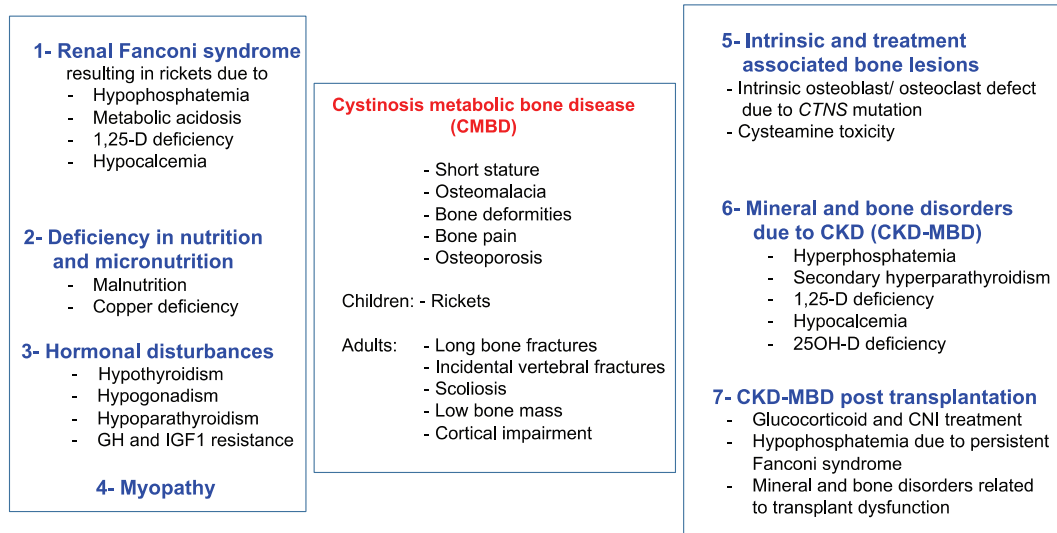


FIGURE 4 Current understanding of the abnormalities leading to cystinosis metabolic bone disease (CMBD). Virtually all individuals with classical, nephropathic cystinosis suffer from CMBD, related to the renal Fanconi syndrome in infancy and progressive chronic kidney disease (CKD) later in life inducing CKD-associated mineral and bone disorders (CKD-MBD). Malnutrition and copper deficiency, but also hormonal disturbances, myopathy, and transplantation may worsen the clinical picture. The cystinosis defect also induces intrinsic bone defects such as osteoblastic and osteoclastic dysfunction. The impact of cysteamine on bone deserves further studies, but high doses of cysteamine may contribute to CMBD. Taken together, all these mechanisms can lead to bone deformities and pains, osteoporosis, fractures, cortical impairment, and short stature in teenagers and young adults

differentiation and mineralization, with an inhibitory effect at higher doses, possibly explaining the bone toxicity observed in patients receiving high doses of cysteamine. Cystinosin may also be required for proper osteoclastic and osteoblastic activity.^{35,36}

3.3 | Assessing CMBD

Serum mineral and enzyme values provide measures of bone health in both children and adults with cystinosis (Table 2). In children with hypophosphatemic rickets, serum phosphate, bicarbonate, and potassium reflect renal losses and the efficacy of replacement therapy, and alkaline phosphatase (ALP) is a biomarker of rickets and osteomalacia.³⁷ Elevated ALP also indicates increased bone turnover as a feature of CKD-MBD. Measurement of serum PTH, calcium, 25(OH) vitamin D, and phosphate also serve as the mainstays of monitoring for CKD-MBD.³⁸ Nevertheless, infants and adolescents with cystinosis may develop bone disease despite largely “normal” blood levels of phosphate, calcium and ALP; normal blood levels have a wide standard range and daily fluctuations, are not always biochemically evident, and may have a large cumulative effect upon bone metabolism. Therefore, urine losses for calcium and phosphate should be monitored as well.

New biomarkers may better reflect bone cell activity in CMBD,³⁹ and pediatric reference values are available.⁴⁰ Bone ALP, an osteoblast enzyme, is a sensitive and specific marker of bone formation and remodeling during periods of rapid longitudinal growth and in cases of rickets.^{24,38} TRAP5b is considered a specific marker of late osteoclast differentiation,³⁸ and sclerostin is an osteocyte-derived inhibitor of bone formation.^{38,41,42} Fibroblast growth factor 23 (FGF23), released by osteocytes and osteoblasts, helps maintain mineral and vitamin D homeostasis, and is the earliest detectable abnormality in bone mineral metabolism in CKD patients.^{38,43} However, FGF23 levels are typically normal in patients with cystinosis prior to dialysis, possibly due to hypophosphatemia.⁴⁴

Radiographic imaging plays an important role in assessing CMBD. Although dual-energy X-ray absorptiometry (DXA) allows quantification of bone mineral density,⁴⁵ it cannot distinguish the different stages of CKD.⁴⁶ DXA studies are not recommended in the clinical management of cystinosis, since the results are influenced by bone size and body height, do not distinguish between a mineralization defect (osteomalacia) and loss of bone tissue (osteoporosis),⁴⁷ and have poor predictive value for fractures (eg, in stage 3-5 CKD). In fact, bone mineral density is often normal in pediatric CKD patients, when data are corrected for reduced height.^{48,49}

TABLE 2 Recommended tests for CMBD

Assessment	Methods and frequency
Growth	<ul style="list-style-type: none"> • Calculate genetic target height based on parental height • Plot height/length and weight on growth charts in infants (monthly) and preschool children (3 monthly) and older children (6 monthly) • Calculate annual height velocity • Measure head circumference every 3 months in infants and small children
Bone metabolism	<ul style="list-style-type: none"> • Measure serum iPTH, calcium, phosphate, ALP, and bicarbonate levels every 1 to 6 months depending on the clinical status and CKD stage • Consider iliac crest bone biopsies, with tetracycline labeling in cases of unclear severe bone disorder
Bone deformities	<ul style="list-style-type: none"> • Check for rickets and scoliosis by physical examination and/or radiographs (eg, X-ray of the knees and/or the wrist), with regular follow-up
Growth hormone	<ul style="list-style-type: none"> • Evaluate IGF-1 serum levels prior to starting treatment with GH to rule out GH deficiency • Obtain X-ray of the left wrist in children aged >5 years to assess bone age and prove growth potential (ie, open epiphyses) prior to initiation of GH treatment
Thyroid function	<ul style="list-style-type: none"> • Check TSH and thyroxine levels annually, more frequently if following treatment • Perform ultrasound of the thyroid to exclude other thyroid disease
Gonadal function	<ul style="list-style-type: none"> • For male patients at pubertal age: monitor levels of FSH, LH, testosterone, inhibin B, and prolactin annually after age 14 years • For female patients at pubertal age (14 years): determine first menstrual cycle and monitor levels of FSH, LH, estradiol, anti-mullerian hormone, and prolactin annually
Muscle function	<ul style="list-style-type: none"> • Obtain mechanographic testing, for example, grip strength
Other	<ul style="list-style-type: none"> • WBC cystine levels to assess disease control

Abbreviations: ALP, alkaline phosphatase; CKD, chronic kidney disease; FSH, follicle-stimulating hormone; GH, growth hormone; IGF-1, Insulin-like growth factor 1; iPTH, intact serum parathyroid hormone; LH, luteinizing hormone; TSH, thyroid-stimulating hormone.

Quantitative computed tomography (QCT) and peripheral QCT (pQCT) provide separate measures of cortical and trabecular bone in the central and peripheral skeleton and true volumetric density, without being confounded by body size.⁵⁰ High-resolution pQCT can assess trabecular microarchitecture and bone biomechanical properties (finite element analysis). However, there are limited reference data in young children,⁴⁵ the measurement requires children to sit still for 2 to 3 minutes, and the results only provide a “window” into the bone at a single time point.⁵¹

Iliac crest bone biopsies can help establish a diagnosis in an individual with an unclear bone disorder.⁵² Biopsies provide dynamic histomorphometric measures, such as mineralizing surface, bone formation rate, and mineral apposition rate. Standardized nomenclature,⁵³ along with normative data for iliac bone histomorphometry,⁵⁴ allow comparison with patient data. However, bone biopsy is invasive, cannot be repeated frequently, and requires prior tetracycline labeling for optimal evaluation.⁵⁵

3.4 | Management of CMBD

The treatment of Fanconi syndrome largely involves oral replacement of urinary losses plus nutrition that provides the recommended daily requirements of protein and calories (Table 3). Phosphate repletion aims to resolve rickets and normalize ALP activity and serum phosphate levels, which are measured immediately prior to dosing. A typical starting dose is 30 to 40 mg/kg/d based on elemental phosphorus in 3 to 5 doses equally spaced throughout the day and administered at the same times daily. However, treatment should be increased (up to 80 mg/kg/d) to treat acute rickets or lowered to avoid abdominal discomfort and diarrhea. For small children, phosphate tablets can be crushed and dissolved in tea or water, and intravenous phosphate solutions can be given orally. Phosphate should not be administered at the same time as calcium, since this can lead to precipitation, although providing phosphate with milk products is acceptable. Phosphate administration can contribute to nephrocalcinosis, but is still required. Oral phosphate supplements may be reduced in patients with advanced CKD.

Calcitriol or alfacalcidol, can treat and prevent deficiency of active vitamin D and hypocalcemia. In addition, both agents improve phosphate reabsorption from the gut and prevent phosphate-driven secondary hyperparathyroidism. Initially, a calcitriol or alfacalcidol dose of 0.1 to 1 µg is used to cure rickets, but this can be reduced at a later stage, when laboratory, radiological and clinical findings are normalized. High doses of active vitamin D may increase hypercalciuria and nephrocalcinosis, and can promote extraskelatal (vascular) calcifications as reported in other patients with advanced CKD.⁵⁶ Supplementation of native vitamin D (eg,

cholecalciferol) should be titrated to achieve normal values.⁵⁷ For most patients, calcium requirements can be met by adequate nutrition and vitamin D administration, but calcium supplementation can serve as “insurance” against imperceptible daily losses of calcium that eventually lower bone density. However, calcium supplements may contribute to the development of ectopic (vascular) calcifications in patients with advanced CKD and cumulative calcium intake should be within the recommended daily allowance as recommended for other patients with CKD.⁵⁸

Left wrist and/or knee once a year radiographs will gauge the presence/recurrence/resolution of rickets (based on increased thickness of the growth plates of the long bones, with irregular, hazy appearance at the diaphyseal line). Bone biopsies appear justified only when obtained during corrective orthopedic surgery or to determine the etiology and treatment of longstanding refractory bone deformities.

Orthopedic surgery (temporary hemiepiphyodesis or osteotomy) can correct persistent leg bowing. Surgery during puberty is preferred, with metabolic control optimized prior to surgery to prevent recurrence of leg bowing. Active vitamin D may be paused during prolonged immobilization to prevent hypercalcemia.

Initiation of GH treatment may be considered at any stage of CKD in the presence of persistent short stature (<3rd percentile) and low height velocity (<25th percentile), despite adequate nutritional intake, metabolic control, and cysteamine treatment. Before starting treatment, bone age (X-ray of the left hand) should be assessed in children aged >5 years to confirm open epiphyses and to determine bone age. IGF-1 and thyroid hormone levels should be obtained to rule out GH deficiency and hypothyroidism.^{59,60} During treatment, calcium, phosphate, HbA1c, fasting glucose, PTH, and thyroid hormone levels should be monitored, and the presence of rickets and scoliosis should be evaluated. Persistent headaches or visual acuity loss should prompt an ophthalmological examination to rule out intracranial hypertension. GH treatment should be discontinued if progressive scoliosis or intracranial hypertension occurs.

For patients with cystinosis and CKD stage 1 to 2, we suggest keeping PTH levels within the normal range. However, such patients may have suppressed PTH levels caused by treatment with active vitamin D. Therefore, PTH levels should be checked at least every 6 to 12 months. In patients with CKD stages 3 to 5, PTH levels should be maintained in the target range recommended for other renal diseases, using dietary measures, active/native vitamin D, calcimimetics, and/or oral phosphate binders.^{24,58,61,62} As CKD progresses, phosphate supplements should be reduced or even stopped. Some patients with cystinosis and ESKD may only require a low dose of oral phosphate binders, if any, due to the ongoing renal phosphate wasting.

TABLE 3 Treatment of CMBD

Treatment	Dosing
Phosphate	<ul style="list-style-type: none"> Starting dose of 30–40 mg/kg/d based on elemental phosphorus in 3 to 5 doses equally spaced throughout the day Treatment needs to be individualized in order to control rickets and a wider range of 20–80 mg/kg/d may be used. Minimal effective dosage should be used Dosage should be adjusted to the stage of CKD
Citrate/bicarbonate	<ul style="list-style-type: none"> Treat acidosis with alkali (citrate or bicarbonate) administered 3–4 times daily Aim to return bicarbonate levels to normal levels (22–25 mEq/L); levels >20 mEq/L may not be achieved in all patients
Calcium/active and native vitamin D	<ul style="list-style-type: none"> Starting dose of calcitriol or alfacalcidol 0.1 to 0.75 µg depending on patient size and severity of rickets Maintain at lowest possible dose to successfully treat rickets and keep PTH in the CKD stage-dependent target range (see below) Supplementation with native vitamin D (eg, cholecalciferol) if 25 OH vitamin-D levels are reduced Oral calcium supplements in case of persistent hypocalcemia based on albumin corrected calcium levels
GH	<ul style="list-style-type: none"> Indication: height below the 3rd percentile and height velocity below the 25th percentile in the presence of open epiphyses Dosage: 0.045 to 0.05 mg/kg body weight per day by subcutaneous injections in the evening Calcium, phosphorus, PTH, fasting glucose, and HbA1c levels should be monitored. GH treatment should generally be stopped after kidney transplantation and may be reinstated in case of persistent growth failure at least 12 months after transplantation.
Parathyroid levels	<ul style="list-style-type: none"> For CKD stages 1 to 2, maintain PTH levels within the normal range For CKD stages 3 to 5, maintain PTH levels as recommended for other renal diseases by dietary measures, active/native vitamin D, calcimimetics, and/or oral phosphate binders
Sex hormone replacement therapy	<ul style="list-style-type: none"> Per pediatric endocrinologist, for <i>pubertas tarda</i> and hypergonadotropic hypogonadism Testosterone patch or intramuscular
L-Thyroxine	<ul style="list-style-type: none"> In case of hypothyroidism to normalize free T₄ and TSH
Cysteamine	<ul style="list-style-type: none"> Ensure optimal dose adjustment and control of cystinosis

Abbreviations: CKD, chronic kidney disease; GH, growth hormone; HbA1c, glycated hemoglobin; PTH, parathyroid hormone; TSH, thyroid-stimulating hormone.

In patients on renal replacement therapy, persistent Fanconi syndrome may impair bone health,⁶³ and native kidney nephrectomy might be considered. Minimal glucocorticoid exposure should be considered to permit attainment of a normal adult height.^{64,65} Preservation of transplant function and optimizing metabolic control can further improve growth.⁶⁴ GH may be started in case of persistent short stature (>12 months after transplantation). In addition, early and diligent physical and rehabilitation therapy, including muscle strengthening and targeted exercise, can prevent and/or improve skeletal deformities, and possibly eliminate the need for extensive orthopedic surgeries.

4 | SUMMARY

For any patient with an established diagnosis of nephropathic cystinosis, regular assessments of growth, skeletal status, bone deformities, and walking difficulties should be performed. Rickets should be treated with phosphate,

bicarbonate/citrate, and vitamin D replacement. Treatment with cysteamine helps to minimize possible metabolic bone disease related to CKD by slowing deterioration of renal function. Management of bone disease should be undertaken by a multidisciplinary team including a nephrologist, dietitian, physiotherapist, and experienced orthopedic surgeon. Future studies should focus on the mechanisms of cystinosis bone disease, specifically the functional interactions among bone, muscle, and joints.

CONTRIBUTING PATIENT SUPPORT GROUPS

Asociación Cistinosis, Barcelona, España, Cystinosis Group Netherlands, Amstelveen, Netherlands, Cystinosis Foundation UK, Leyland Lancashire, England, Cystinosis Research Network US, Lake Forest, USA, Cystinosis Foundation, Moraga, CA, USA, Cystinosis Foundation Ireland, Cavendish Row, Ireland, Cystinose-Selbsthilfe e.V., Enningerlohe, Germany, Cystinosis Network Europe, Ratingen, Germany.

ACKNOWLEDGMENTS

We highly appreciate the help of Vanessa Schneider in organizing the meeting and coordinating the paper. The expert meeting on CMBD took place in Salzburg, Austria, in December 2016, and was organized by Cystinosis Foundation Germany. The content of the article has not been influenced by any sponsors.

CONFLICT OF INTEREST

Atif Awan, Justine Bacchetta, Frank Rauch, Erik Harms, Bernd Hoppe, Nadine Herzig, Bernd Hoppe, Ewa Elenberg, William A. Gahl, Christian Koepl, Elena Levchenko, Malcolm Lewis, Galina Nesterova, Fernando Santos, Karl P. Schlingmann, Aude Servais, Neveen A. Soliman, Guentehr Steidle, Rezan Topaloglu, Ulrike Treikauskas, Alexey Tsygin, Koenraad Veys, Josef Zustin, Rodo v. Vigier have no conflict of interest. Gema Ariceta received speaker honorarium from Chiesi, Orphan and Horizon and consulting fee from Chiesi. Susanne Bechtold received speaker honorarium from Sandoz and consulting fee from Alexion. Carsten Bergmann received speaker honorarium from Alexion. George Deschenes received consulting honorarium from Chiesi. Dieter Haffner received speaker honorarium from Horizon, Chiesi and Orphan. Katharina Hohenfellner received speaker fee from Orphan and consulting honorarium from Leadiant. This article does not contain any studies with human or animal subjects performed by the any of the authors.

ORCID

Katharina Hohenfellner  <https://orcid.org/0000-0003-0978-8087>

REFERENCES

- Gahl WA, Bashan N, Tietze F, Bernardini I, Schulman JD. Lysosomal cystine transport is defective in cystinosis. *Science*. 1982; 217:1263-1265.
- Town M, Jean G, Cherqui S, et al. A novel gene encoding an integral membrane protein is mutated in nephropathic cystinosis. *Nat Genet*. 1998;18:319-324.
- Cherqui S, Courtoy PJ. The renal Fanconi syndrome in cystinosis: pathogenic insights and therapeutic perspectives. *Nat Rev Nephrol*. 2017;13:115-131.
- Elmonem MA, Veys KR, Soliman NA, van Dyck M, van den Heuvel LP, Levchenko E. Cystinosis: a review. *Orphanet J Rare Dis*. 2016;11:47.
- Nesterova G, Gahl WA. In: Pagon RA, Adam MP, Ardinger HH, et al., eds. *GeneReviews*[®] [Internet]. Seattle (WA): University of Washington, Seattle; 2001:1993-2017.
- Gahl WA, Reed GF, Thoene JG, et al. Cysteamine therapy for children with nephropathic cystinosis. *N Engl J Med*. 1987;316: 971-977.
- Markello TC, Bernardini IM, Gahl WA. Improved renal function in children with cystinosis treated with cysteamine. *N Engl J Med*. 1993;328:1157-1162.
- Zimakas PJ, Sharma AK, Rodd CJ. Osteopenia and fractures in cystinotic children post renal transplantation. *Pediatr Nephrol*. 2003;18:384-390.
- Emma F, Nesterova G, Langman C, et al. Nephropathic cystinosis: an international consensus document. *Nephrol Dial Transplant*. 2014;29(suppl 4):iv87-iv94.
- Brodin-Sartorius A, Tête M-J, Niaudet P, et al. Cysteamine therapy delays the progression of nephropathic cystinosis in late adolescents and adults. *Kidney Int*. 2012;81:179-189.
- Kleta R, Bernardini I, Ueda M, et al. Long-term follow-up of well treated nephropathic cystinosis patients. *J Pediatr*. 2004;145: 555-560.
- Nesterova G, Williams C, Bernardini I, Gahl WA. Cystinosis: renal glomerular and renal tubular function in relation to compliance with cystine-depleting therapy. *Pediatr Nephrol*. 2015;30(6): 945-951.
- Gahl WA, Balog JZ, Kleta R. Nephropathic cystinosis in adults: natural history and effects of oral cysteamine therapy. *Ann Intern Med*. 2007;147:242-250.
- Ariceta G, Lara E, Camacho JA, et al. Cysteamine (Cystagon[®]) adherence in patients with cystinosis in Spain: successful in children and a challenge in adolescents and adults. *Nephrol Dial Transplant*. 2015;30(3):475-480.
- Nesterova G, Gahl WA. Cystinosis: the evolution of a treatable disease. *Pediatr Nephrol*. 2013;28:51-59.
- Kaiser-Kupfer MI, Fujikawa L, Kuwabara T, Gahl WA. Removal of corneal crystals by topical cysteamine in nephropathic cystinosis. *N Engl J Med*. 1987;316:775-779.
- Labbe A, Baudoin C, Deschenes G, et al. A new gel formulation of topical cysteamine for the treatment of corneal cystine crystals in cystinosis: the Cystadrops OCT-1 study. *Mol Genet Metab*. 2014;111(3):314-320.
- Wühl E, Haffner D, Offner G, et al. Long-term treatment with growth hormone in short children with nephropathic cystinosis. *J Pediatr*. 2001;138(6):880-887.
- Veys KR, D'Hauwers KW, van Dongen AJCM, et al. First successful conception induced by a male cystinosis patient. *JIMD Rep*. 2018;38:1-6.
- Reiss RE, Kuwabara T, Smith ML, Gahl WA. Successful pregnancy despite placental cystine crystals in a woman with nephropathic cystinosis. *N Engl J Med*. 1988;319:223-226.
- Gahl WA, Dalakas M, Charnas L, et al. Myopathy and cystine storage in muscles in a patient with nephropathic cystinosis. *N Engl J Med*. 1988;319:1461-1464.
- Sonies B, Ekman EF, Andersson H, et al. Swallowing dysfunction in nephropathic cystinosis. *N Engl J Med*. 1990;323:565-570.
- Langmann CB. Bone complications of cystinosis. *J Pediatr*. 2017; 183S(4):S2-S4.
- Kidney Disease: Improving Global Outcomes (KDIGO) CKD-MBD Work Group. KDIGO clinical practice guideline for the diagnosis, evaluation, prevention, and treatment of chronic kidney disease-mineral and bone disorder (CKD-MBD). *Kidney Int*. 2016; 89(6):1192-1203.

25. National Kidney Foundation. K/DOQI clinical practice guidelines for bone metabolism and disease in children with chronic kidney disease. *Am J Kidney Dis.* 2005;46:1-121.
26. Asplin JR, Donahue S, Kinder J, Coe FL. Urine calcium excretion predicts bone loss in idiopathic hypercalciuria. *Kidney Int.* 2006;70(8):1463-1467.
27. García-Nieto V, Ferrández C, Monge M, de Sequera M, Rodrigo MD. Bone mineral density in pediatric patients with idiopathic hypercalciuria. *Pediatr Nephrol.* 1997;11(5):578-583.
28. Fricke O, Beccard R, Semler O, Schoenau E. Analyses of muscular mass and function: the impact on bone mineral density and peak muscle mass. *Pediatr Nephrol.* 2010;25(12):2393-2400.
29. Besouw M, Cornelissen E, Cassiman D, Kluijtmans L, van den Heuvel L, Levchenko E. Carnitine Profile and Effect of Supplementation in Children with Renal Fanconi Syndrome due to Cystinosis. *JIMD Rep.* 2014;16:25-30.
30. Gaide Chevronnay HP, Janssens V, Van Der Smissen P, et al. A mouse model suggests two mechanisms for thyroid alterations in infantile cystinosis: decreased thyroglobulin synthesis due to endoplasmic reticulum stress/unfolded protein response and impaired lysosomal processing. *Endocrinology.* 2015;156(6):2349-2364.
31. Mehls O, Wühl E, Tönshoff B, Schaefer F, Nissel R, Haffner D. Growth hormone treatment in short children with chronic kidney disease. *Acta Paediatr.* 2008;97(9):1159-1164.
32. Rabkin R, Sun DF, Chen Y, Tan J, Schaefer F. Growth hormone resistance in uremia, a role for impaired JAK/STAT signaling. *Pediatr Nephrol.* 2005;20(3):313-318.
33. Cherqui S, Sevin C, Hamard G, et al. Intralysosomal cystine accumulation in mice lacking cystinosis, the protein defective in cystinosis. *Mol Cell Biol.* 2002;22(21):7622-7632.
34. Conforti A, Tranta A, Biagini S, et al. Cysteamine treatment restores the in vitro ability to differentiate along the osteoblastic lineage of mesenchymal stromal cells isolated from bone marrow of a cystinotic patient. *J Transl Med.* 2015;13:143.
35. Battafarano G, Rossi M, Rega LR, et al. Intrinsic bone defects in cystinotic mice. *Am J Pathol.* 2019;189(5):1053-1064.
36. Claramunt-Taberner D, Flammier S, Gaillard S, et al. Bone disease in nephropathic cystinosis is related to cystinosis-induced osteoclastic dysfunction. *Nephrol Dial Transplant.* 2018;33(9):1525-1532.
37. Ros I, Alvarez L, Guañabens N, et al. Hypophosphatemic osteomalacia: a report of five cases and evaluation of bone markers. *J Bone Miner Metab.* 2005;23(3):266-269.
38. Doyon A, Fischer DC, Bayazit AK, et al. Markers of bone metabolism are affected by renal function and growth hormone therapy in children with chronic kidney disease. *PLoS One.* 2015;10(2):e0113482.
39. Moe S, Druke T, Cunningham J, et al. Definition, evaluation, and classification of renal osteodystrophy: a position statement from kidney disease: improving global outcomes (KDIGO). *Kidney Int.* 2006;69:1945-1953.
40. Fischer DC, Mischek A, Wolf S, et al. Paediatric reference values for the C-terminal fragment of fibroblast-growth factor-23, sclerostin, bone-specific alkaline phosphatase and isoform 5b of tartrate-resistant acid phosphatase. *Ann Clin Biochem.* 2012;49(Pt 6):546-553.
41. Kanbay M, Siriopol D, Saglam M, et al. Serum sclerostin and adverse outcomes in nondialyzed chronic kidney disease patients. *J Clin Endocrinol Metab.* 2014;99(10):E1854-E1861.
42. Qureshi AR, Olauson H, Witasap A, et al. Increased circulating sclerostin levels in end-stage renal disease predict biopsy-verified vascular medial calcification and coronary artery calcification. *Kidney Int.* 2015;88(6):1356-1364.
43. Portale AA, Wolf M, Jüppner H, et al. Disordered FGF23 and mineral metabolism in children with CKD. *Clin J Am Soc Nephrol.* 2014;9(2):344-353.
44. Florenzano P, Ferreira C, Nesterova G, et al. Skeletal consequences of nephropathic cystinosis. *J Bone Miner Res.* 2018;33(10):1870-1880.
45. Leonard MB, Bachrach LK. Non-invasive techniques for bone mass measurement. *Pediatric Bone.* 2nd ed. San Diego, CA: Elsevier (Academic Press); 2012.
46. Fidan N, Inci A, Coban M, Ulman C, Kursat S. Bone mineral density and biochemical markers of bone metabolism in predialysis patients with chronic kidney disease. *J Investig Med.* 2016;64(4):861-866.
47. Leonard MB. A structural approach to skeletal fragility in chronic kidney disease. *Semin Nephrol.* 2009;29:133-143.
48. Griffin LM, Kalkwarf HJ, Zemel BS, et al. Assessment of dual-energy X-ray absorptiometry measures of bone health in pediatric chronic kidney disease. *Pediatr Nephrol.* 2012;27(7):1139-1148.
49. Weber LT, Mehls O. Limitations of dual x-ray absorptiometry in children with chronic kidney disease. *Pediatr Nephrol.* 2010;25(1):3-5.
50. Adams JE et al. Radiology. *Pediatric Bone.* 2nd ed. San Diego, CA: Elsevier (Academic Press); 2012.
51. Moorthi RN, Moe SM. Recent advances in the noninvasive diagnosis of renal osteodystrophy. *Kidney Int.* 2013;84(5):886-894.
52. Rauch F. *Pediatric Bone.* 2nd ed. San Diego, CA: Elsevier (Academic Press); 2012.
53. Dempster DW, Compston JE, Drezner MK, et al. Standardized nomenclature, symbols, and units for bone histomorphometry: a 2012 update of the report of the ASBMR Histomorphometry Nomenclature Committee. *J Bone Miner Res.* 2013;28(1):2-17.
54. Glorieux FH, Travers R, Taylor A, et al. Normative data for iliac bone histomorphometry in growing children. *Bone.* 2000;26(2):103-109.
55. Rauch F. Bone biopsy: indications and methods. *Endocr Dev.* 2009;16:49-57.
56. Pilz S, Iodice S, Zittermann A, Grant WB, Gandini S. Vitamin D status and mortality risk in CKD: a meta-analysis of prospective studies. *Am J Kidney Dis.* 2011;58(3):374-382.
57. Shroff R, Wan M, Nagler EV, et al. Clinical practice recommendations for native vitamin D therapy in children with chronic kidney disease stages 2-5 and on dialysis. *Nephrol Dial Transplant.* 2017;32(7):1098-1113.
58. Ketteler M, Elder GJ, Evenepoel P, et al. Revisiting KDIGO clinical practice guideline on chronic kidney disease-mineral and bone disorder: a commentary from a kidney disease: improving global outcomes controversies conference. *Kidney Int.* 2015;87(3):502-528.
59. Besouw MT, Van Dyck M, Francois I, Van Hoyweghen E, Levchenko EN. Detailed studies of growth hormone secretion in cystinosis patients. *Pediatr Nephrol.* 2012;27(11):2123-2127.
60. Jens D, Mandy W, Marjolein B, et al. Clinical practice recommendations for growth hormone treatment in children with chronic kidney disease. *Nat Rev Nephrol.* 2019. [Epub ahead of print].

61. Ketteler M, Block GA, Evenepoel P, et al. Executive summary of the 2017 KDIGO chronic kidney disease-mineral and bone disorder (CKD-MBD) guideline update: what's changed and why it matters. *Kidney Int.* 2017;92(1):26-36.
62. Klaus G, Watson A, Edefonti A, et al. Prevention and treatment of renal osteodystrophy in children on chronic renal failure: European guidelines. *Pediatr Nephrol.* 2006;21(2):151-159.
63. Haffner D, Schöler U. Metabolic bone disease after renal transplantation. *Curr Opin Pediatr.* 2014;26(2):198-206.
64. Franke D, Thomas L, Steffens R, et al. Patterns of growth after kidney transplantation among children with ESRD. *Clin J Am Soc Nephrol.* 2015;10(1):127-134.
65. Klare B, Montoya CR, Fischer DC, Stangl MJ, Haffner D. Normal adult height after steroid-withdrawal within 6 months of pediatric kidney transplantation: a 20 years single center experience. *Transpl Int.* 2012;25(3):276-282.

How to cite this article: Hohenfellner K, Rauch F, Ariceta G, et al. Management of bone disease in cystinosis: Statement from an international conference. *J Inherit Metab Dis.* 2019;42:1019–1029. <https://doi.org/10.1002/jimd.12134>