

Uvulo-glossopharyngeal dimensions in non-extraction, extraction with minimum anchorage, and extraction with maximum anchorage

Derya Germec-Cakan*, Tulin Taner** and Seden Akan**

Departments of Orthodontics, Faculties of Dentistry, *Yeditepe University, Istanbul and **Hacettepe University, Ankara, Turkey

Correspondence to: Seden Akan, Hacettepe Üniversitesi, Diş Hekimliği Fakültesi, Ortodonti Anabilim Dalı, Sıhhiye, 06100 Ankara, Turkey. E-mail: sedenakandt@hotmail.com

SUMMARY The aim of this study was to investigate upper respiratory airway dimensions in non-extraction and extraction subjects treated with minimum or maximum anchorage. Lateral cephalograms of 39 Class I subjects were divided into three groups (each containing 11 females and 2 males) according to treatment procedure: group 1, 13 patients treated with extraction of four premolars and minimum anchorage; group 2, 13 cases treated non-extraction with air-rotor stripping (ARS); and group 3, 13 bimaxillary protrusion subjects treated with extraction of four premolars and maximum anchorage. The mean ages of the patients were 18.1 ± 3.7 , 17.8 ± 2.4 , and 15.5 ± 0.88 years, respectively. Tongue, soft palate, hyoid position, and upper airway measurements were made on pre- and post-treatment lateral cephalograms and the differences between the mean measurements were tested using Wilcoxon signed-ranks test.

Superior and middle airway space increased significantly ($P < 0.05$) in group 1. In group 2, none of the parameters showed a significant change, while in group 3, middle and inferior airway space decreased ($P < 0.01$). The findings show that extraction treatment using maximum anchorage has a reducing effect on the middle and inferior airway dimensions.

Introduction

The role of uvulo-glossopharyngeal dimensions on the size and structure of the upper airway is well documented (Lyberg *et al.*, 1989; Bacon *et al.*, 1990). One aspect of the mechanism of breathing, nasal obstruction, predisposes a child to chronic mouth breathing. The resultant dentofacial deformity has been described by Ricketts (1968) as ‘respiratory obstruction syndrome’. Another view is that orthodontic treatment can cause differences in the size of the oral cavity, influence the size and function of the nasopharyngeal airway, and affect breathing (Kikuchi, 2005).

Changes in nasopharyngeal structures, which comprise hyoid bone position and the surrounding musculature and tongue and soft palate posture, tend to be related to changes in dentofacial structures (Fromm and Lundberg, 1970; Ozbek *et al.*, 1998; Battagel *et al.*, 1999; Abu Allhajja and Al-Khateeb, 2005; Marşan *et al.*, 2008, 2009).

Tongue pressure is considered to be particularly important in the diagnosis of malocclusion and the prognosis of orthodontic treatment. Changes in the size of the oral cavity due to different treatment protocols may affect tongue position and pharyngeal airway dimensions. Through multiple muscular and connective tissue attachments, the tongue is attached to the hyoid bone and posterior movement of the tongue results in a narrowing of the airway (Marşan *et al.*, 2009).

Changes in the size of nasopharyngeal airway dimensions have been reported following rapid maxillary expansion (Tecco *et al.*, 2007; Kilic and Oktay, 2008; Oliveira De Felipe *et al.*, 2008), the use of headgear (Pirilä-Parkkinen *et al.*, 1999; Hiyama *et al.*, 2001), functional appliances (Ozbek *et al.*, 1998), protraction facemask therapy (Sayinsu *et al.*, 2006; Kilinc *et al.*, 2008; Oktay and Ulukaya, 2008), and orthognathic surgery (Chemello *et al.*, 1994; Enacar *et al.*, 1994; Turnbull and Battagel, 2000; Guven and Saracoglu, 2005). However, the effects of non-extraction and premolar extraction therapy using different anchorage principles on the upper respiratory airway dimensions have not been previously evaluated.

A number of factors, such as dental arch width, crowding, growth direction, facial profile, and the patient’s age, should be considered when treating with extractions or non-extraction especially in borderline patients. The term ‘borderline’ was used first by Carey (1951) when referring to patients with moderate crowding and good facial balance and for whom it was uncertain as to whether extractions should be performed. Borderline patients can be treated with expansion, stripping, or extraction with minimum anchorage principles, whereas bimaxillary protrusion subjects require extraction especially in borderline patients treatment with maximum anchorage for correction of the

convex profile. These various treatment approaches may have different effects on the upper airway dimensions.

In a case report (Kikuchi, 2005), two sisters with a Class II malocclusion with bimaxillary dentoalveolar protrusion treated by different treatment modalities were presented. The elder sister, 12 years 11 months of age, was treated by extraction therapy, while the younger sister, aged 11 years 9 months, was treated non-extraction using the Herbst appliance. Superimposition of the initial cephalograms of the sisters revealed that their dentofacial features were almost the same at the beginning of treatment. After orthodontic therapy, the lower pharynx of the elder sister was reduced by 4 mm and that of the younger sister was increased by 3 mm. The author stated that orthodontic treatment influenced the size of airway.

To determine the most suitable treatment plan for patients, information should be available on the effects, benefits, and disadvantages of therapy. The purpose of this study was to assess changes in uvulo-glossopharyngeal dimensions in non-extraction and extraction subjects treated with minimum or maximum anchorage.

Materials and methods

Lateral cephalograms of 39 Class I subjects treated at the Department of Orthodontics, Faculty of Dentistry, Hacettepe University, Ankara, Turkey, were divided into three groups according to the treatment procedure; group 1, 13 borderline cases treated with the extraction of four premolars with minimum anchorage; group 2, 13 borderline cases treated without extraction by means of the air-rotor stripping (ARS) technique; and group 3, 13 bimaxillary protrusion cases treated with the extraction of four premolars with maximum anchorage. All three groups comprised 11 females and 2 males. The mean age of the subjects was 18.1 ± 3.7 , 17.8 ± 2.4 , and 15.5 ± 0.9 years in groups 1, 2, and 3, respectively. Treatment of the all three groups was performed with 0.018×0.025 inch slot fixed preadjusted edgewise appliances. The mean treatment times were 24.8 ± 6.9 , 17 ± 4.6 , and 27.5 ± 7.7 months in groups 1, 2, and 3, respectively.

The subjects in groups 1 and 2 were skeletal Class I with a mesofacial growth pattern. They had been classified as borderline with moderate maxillary and mandibular dental crowding and an orthognathic profile as evaluated by experienced orthodontists using intra- and extraoral photographs and cephalometric and model analyses and were randomly divided into groups (groups 1 and 2) in the order of their referral to the orthodontic clinic (Germec and Taner, 2008).

The mean pre-treatment maxillary and mandibular crowding in group 1 was 5.7 ± 1.5 and 5.9 ± 1.4 mm, respectively. The premolars were extracted and orthodontic treatment started with segmental canine distalization. After elimination of crowding, the remaining extraction spaces were closed with increased anterior labial crown torqued archwires. Minimum anchorage principles were used by further ligating all anterior teeth.

The mean maxillary and mandibular molar mesialization was approximately 3 mm. Average upper and lower incisor retraction was 1.6 ± 2.4 and 1.9 ± 1.9 mm relative to the pyterigoid vertical plane (PTV; Germec and Taner, 2008).

In group 2, the mean pre-treatment maxillary and mandibular crowding was 5.0 ± 1.3 and 5.9 ± 1.3 mm, respectively. Bite-wing radiographs were taken before ARS and the enamel thickness of the teeth was evaluated. The ARS technique was used on both posterior and anterior teeth with a specially designed ARS bur kit (Raintree Essix, Metairie, Louisiana, USA). A segmental approach was preferred to avoid excess protrusion of the incisors. This procedure has been explained in detail (Germec and Taner, 2008). As most crowding was resolved with ARS, the position of the maxillary incisors was maintained, whereas a slight mandibular proclination was observed (1.4 ± 1.2 mm). Mesial movement of the maxillary and mandibular teeth was approximately 0.7 mm post-treatment (Germec and Taner, 2008).

Group 3 included subjects with bimaxillary protrusion and average maxillary and mandibular crowding of 4.6 ± 3.0 and 4.3 ± 2.4 mm, respectively. Four premolars were extracted and maximum anchorage principles were used. All patients were treated with 0.018×0.025 inch slot fixed preadjusted edgewise appliances using transpalatal arches combined with a Nance appliance and headgear was added when necessary. The average maxillary and mandibular incisor retraction were 12.4 ± 3.5 and 9.6 ± 2.9 mm, respectively, relative to the PTV plane.

To analyse the effects of extraction and non-extraction treatment on upper airway dimensions, pre- and post-treatment lateral cephalograms were evaluated. The cephalograms were taken with the teeth in occlusion and the subjects standing upright in the natural head position (mirror position; Solow and Tallgren, 1971). The cephalometric landmarks and lines used to assess the changes in dentoskeletal structures, tongue, soft palate, hyoid position, and upper airway dimensions are shown in Table 1 and Figure 1. All measurements were carried out by the same author (SA).

Statistical analysis

All statistical analyses were performed with the Statistical Package for the Social Sciences (Windows 98, version 10.0; SPSS Inc., Chicago, Illinois, USA). For each variable, the arithmetic mean and standard deviation were calculated. Wilcoxon signed-ranks test was used to evaluate treatment changes within each group. Statistical significance was set at $P < 0.05$.

To evaluate the error in cephalometric tracing, all radiographs were retraced and re-evaluated by the same author after a 1 week interval. Random error was calculated with Dahlberg's (1940) formula. The method error was between 0.8 and 1.5 mm, the lowest value was for superior

Table 1 Cephalometric landmarks and lines used to evaluate changes in hyoid and tongue position, uvulo-glossopharyngeal dimensions, and skeletal and dental differences.

Point line	Definition
S	Centre of the sella turcica of the sphenoid bone
N	Most anterior point of the frontonasal suture in the midsagittal plane
Po	Most superior point of the external auditory meatus
Or	Lowest point in the inferior margin of the orbita
Point A	Most posterior point in the concavity between anterior nasal spine and the dental alveolus
Point B	Most posterior point on the concavity along the anterior surface of the symphysis
Go	The most convex point along the inferior border of the ramus
M	The most inferior point of the symphysis
Rgn	The most posterior point of symphysis
H	The most superior and anterior points on the body of the hyoid bone
TT	Tongue tip
V	Base of epiglottis
U	Tip of soft palate
C3	Antero-inferior limit of the third cervical vertebra
ANS	Tip of the anterior nasal spine
PNS	Tip of the posterior nasal spine
MxPl	Maxillary plane, a line joining PNS and ANS
MnPl	Mandibular plane, a line joining menton and gonion (Go)
Go-B line	A line joining Go and point B
U1	Axial inclination of the maxillary incisor
L1	Axial inclination of the mandibular incisor
Frankfort horizontal plane	Horizontal plane running through porion and orbitale

posterior airway space (SPAS) and the highest for soft palate length.

Results

Changes in hyoid, tongue position, soft palate, nasopharyngeal airway dimensions, and dentofacial measurements in group 1 are shown in Table 2. The mean SPAS (1.7 ± 2.4 mm, $P < 0.05$) and middle airway space (MAS; 1.0 ± 2.2 mm, $P < 0.05$) increased significantly following orthodontic treatment. No significant change was found in any other parameter. The mean U1-SN and IMPA decreased significantly after treatment (-5.3 ± 5.9 and -6.3 ± 3.8 degrees; $P < 0.05$ and $P < 0.01$).

Table 3 shows the changes in nasopharyngeal airway, soft tissue, and dentoskeletal measurements in group 2. No statistically significant changes in nasopharyngeal dimensions or dentoskeletal measurements were found after treatment.

The changes in group 3 are shown in Table 4. The subjects in this group were skeletal Class I with a dolichocephalic facial type and bimaxillary dentoalveolar protrusion. After treatment, the mean MAS and inferior airway space (IAS) decreased (-2.1 ± 1.5 and -3.8 ± 3.3 mm, respectively, $P < 0.01$), while soft palate length significantly increased ($1.3 \pm$

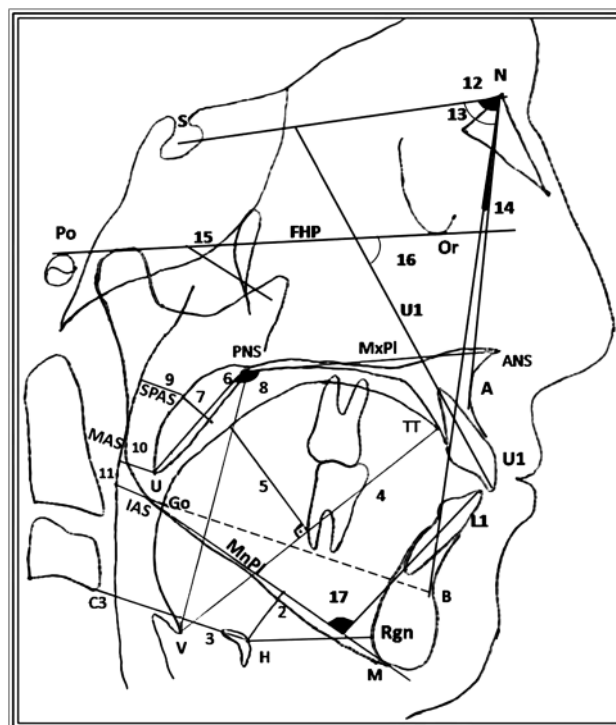


Figure 1 Lateral cephalometric landmarks, lines, and measurements. 1 Rgn-H, the distance between Rgn and H; 2 H-MnPl, the perpendicular distance from H to the MnPl; 3 C3H, distance between the hyoid bone and C3; 4 TGL, tongue length (V-TT); 5 TGH, tongue height (maximum height of the tongue along a perpendicular line of V-TT line to tongue dorsum); 6 PNS-U, soft palate length, the distance between PNS and U; 7 MPT, soft palate thickness (maximum thickness of the soft palate measured on a line perpendicular to PNS-U line); 8 Soft palate angle, the angle between soft palate length (PNS-U) and MxPl; 9 SPAS, superior posterior airway space (width of the airway behind the soft palate along a parallel line to the Go-B line); 10 MAS, middle airway space (width of the airway along a parallel line to the Go-B line through U); 11 IAS, inferior airway space (width of the airway space along the Go-B line); 12 SNA, angle formed by SN and NA; 13 SNB, angle formed by SN and NB; 14 ANB, angle formed by NA and NB; 15 FMA, angle formed by Frankfort horizontal plane and MnPl; 16 U1-SN, angle formed by the axial inclination of the maxillary incisor and SN; 17 IMPA, angle formed by the axial inclination of the mandibular incisor and MnPl.

2.2 mm, $P < 0.01$). For dentoskeletal measurements, the average decreases in U1-SN and IMPA were -14.1 ± 3.9 and -11.9 ± 3.9 degrees ($P < 0.01$), respectively.

Discussion

The effects of extraction treatment with minimum anchorage, non-extraction treatment by means of ARS, and extraction treatment with maximum anchorage on the nasopharyngeal airway dimensions were evaluated in this study. The effect of growth may play a role when evaluating dimensions of the pharyngeal airway. The nasopharyngeal airway dimensions continue to grow rapidly until 13 years of age (Handelman and Osborne, 1976; Linder-Aronson and Leighton, 1983). The sagittal depth of the nasopharynx is narrowest at 5 years of age due to increased thickness of

Table 2 Changes [mean and standard deviation (SD)] in hyoid and tongue position, uvulo-glossopharyngeal dimensions, and skeletal and dental differences after extraction treatment with minimum anchorage ($n = 13$).

	Pre-treatment (mean \pm SD)	Post-treatment (mean \pm SD)	Difference (post-pre; mean \pm SD)	<i>P</i>
Hyoid position				
Rgn-H (mm)	40.2 \pm 4.9	41.3 \pm 4.4	1.2 \pm 3.6	0.323
H-MnPl (mm)	13.4 \pm 5.8	14.3 \pm 6.9	0.9 \pm 2.3	0.178
C3H (mm)	35.1 \pm 5.9	35.8 \pm 6.1	0.7 \pm 2.6	0.347
Tongue position				
TGL (mm)	79.1 \pm 5.1	79.3 \pm 5.7	0.2 \pm 4.6	0.919
TGH (mm)	36.9 \pm 14.6	32.5 \pm 3.7	-4.3 \pm 13.9	0.265
Soft palate dimensions				
PNS-U (mm)	32.4 \pm 4.7	32.7 \pm 5.1	0.3 \pm 3.0	0.720
MPT (mm)	8.1 \pm 1.3	8.0 \pm 1.0	0.1 \pm 1.2	0.713
Soft palate angle ($^{\circ}$)	125.9 \pm 12.5	126.3 \pm 11.4	0.5 \pm 14.0	0.694
Upper airway dimensions				
SPAS (mm)	12.5 \pm 3.6	14.2 \pm 3.0	1.7 \pm 2.4	0.031*
MAS (mm)	9.0 \pm 2.7	10.0 \pm 2.2	1.0 \pm 2.2	0.048*
IAS (mm)	10.1 \pm 3.4	9.3 \pm 2.6	-0.7 \pm 1.9	0.190
Skeletal and dental				
SNA	79.5 \pm 3.6	79.5 \pm 2.9	0.0 \pm 1.5	0.821
SNB	77.2 \pm 2.2	76.9 \pm 2.5	-0.3 \pm 1.1	0.490
ANB	2.4 \pm 1.8	2.6 \pm 1.3	0.3 \pm 1.3	0.762
FMA	24.5 \pm 3.9	24.3 \pm 4.1	-0.2 \pm 0.8	0.186
U1-SN	104.1 \pm 2.8	98.8 \pm 5.7	-5.3 \pm 5.9	0.013*
IMPA	94.9 \pm 6.9	88.7 \pm 6.3	-6.3 \pm 3.8	0.002**

* $P < 0.05$, ** $P < 0.01$.

the adenoid tissues and then at 11 years of age, the adenoid tissues again increase (Linder-Aronson and Leighton, 1983; Preston *et al.*, 2004). There is a distinct difference in growth of the nasopharynx between males and females. Growth velocity decreases considerably earlier in females (12 years) compared with males (14 years; Preston *et al.*, 2004). However, those studies evaluated only the dimensions of the nasopharynx. An investigation on growth of the pharynx showed that antero-posterior dimensions are established earlier in infancy (King, 1952).

In the present study, oropharyngeal airway dimensions were evaluated and skeletally mature patients were included in groups 1 and 2 according to hand-wrist radiographic evaluation. The subjects were mostly females in all the groups (11 females and 2 males). The ages of the male patients were 20 and 21 years in group 1, 15.9 and 17.2 years in group 2, and 15.3 and 16.5 years in group 3. In group 3, the patients were younger than the other two groups and treatment time was longer; however, the sagittal depth of the pharynx decreased post-treatment, instead of the expected enlargement due to growth. This result together with the literature findings indicates that growth may have little if any effect on the sagittal depth of the pharyngeal airway.

Table 3 Changes [mean and standard deviation (SD)] in hyoid and tongue position, uvulo-glossopharyngeal dimensions, and skeletal and dental differences after non-extraction treatment with air-rotor stripping ($n = 13$).

	Pre-treatment (mean \pm SD)	Post-treatment (mean \pm SD)	Difference (post-pre; mean \pm SD)	<i>P</i>
Hyoid position				
Rgn-H (mm)	40.7 \pm 4.2	41.2 \pm 4.0	0.5 \pm 3.5	0.608
H-MnPl (mm)	14.2 \pm 6.5	13.8 \pm 6.7	-0.4 \pm 2.3	0.538
C3H (mm)	35.7 \pm 4.2	36.1 \pm 5.3	0.4 \pm 1.9	0.318
Tongue position				
TGL (mm)	80.0 \pm 7.2	82.4 \pm 5.2	2.4 \pm 4.2	0.070
TGH (mm)	32.2 \pm 2.9	32.7 \pm 3.9	0.5 \pm 3.6	0.502
Soft palate dimensions				
PNS-U (mm)	33.5 \pm 3.9	33.9 \pm 2.8	-0.4 \pm 2.9	0.559
MPT (mm)	7.9 \pm 1.1	7.8 \pm 0.9	-0.1 \pm 1.0	0.792
Soft palate angle ($^{\circ}$)	127.4 \pm 12.0	124.5 \pm 13.4	-3 \pm 8.9	0.399
Upper airway dimensions				
SPAS (mm)	14.6 \pm 2.9	14.5 \pm 3.6	-0.2 \pm 1.8	0.723
MAS (mm)	10.5 \pm 3.3	10.9 \pm 3.1	0.5 \pm 2.5	0.719
IAS (mm)	10.9 \pm 2.6	11.7 \pm 3.4	0.8 \pm 2.5	0.497
Skeletal and dental				
SNA	78.4 \pm 3.3	78.5 \pm 3.1	0.1 \pm 0.5	0.453
SNB	76.2 \pm 2.7	76.3 \pm 2.6	0.1 \pm 0.6	0.426
ANB	2.2 \pm 1.3	2.2 \pm 1.3	0.0 \pm 0.5	1.000
FMA	25.9 \pm 4.3	25.7 \pm 5.0	-0.2 \pm 2.1	0.656
U1-SN	103.3 \pm 6.5	101.7 \pm 5.6	-1.6 \pm 3.7	0.227
IMPA	92.9 \pm 5.5	94.7 \pm 4.5	1.8 \pm 3.0	0.059

The size of the nasopharyngeal airway on lateral cephalograms can be measured as the depth and height in the sagittal plane. Thus, there is an inherent limitation of the study as nasopharyngeal airway is a three-dimensional structure and can only be evaluated two dimensionally on lateral cephalometric films. However, a high correlation between posterior airway size on cephalometric radiographs and pharyngeal volume measured on computerized tomographic scans has been reported (Riley and Powell, 1990). Moreover, Miles *et al.* (1995) reported a high reliability of cephalometric landmarks and measurements.

Different orthodontic treatment modalities can change the airway dimensions. Forward movement of the jaws and the dentition may augment these dimensions. The size of the airway increases after orthodontic treatment with rapid palatal expansion (Tecco *et al.*, 2007; Kilic and Oktay, 2008; Oliveira De Felipe *et al.*, 2008), protraction face mask therapy (Sayinsu *et al.*, 2006; Kilic and Oktay, 2008; Oktay and Ulukaya, 2008), functional appliances (Ozbek *et al.*, 1998), and mandibular advancement surgery (Doff *et al.*, 2009) and decreases after mandibular setback surgery (Eggenesperger *et al.*, 2005; Kawakami *et al.*, 2005; Chen *et al.*, 2007) and cervical headgear therapy (Pirilä-Parkkinen *et al.*, 1999; Hiyama *et al.*, 2001).

Table 4 Changes [mean and standard deviation (SD)] in hyoid and tongue position, uvulo-glossopharyngeal dimensions, and skeletal and dental differences after extraction treatment with maximum anchorage ($n = 13$).

	Pre-treatment (mean \pm SD)	Post-treatment (mean \pm SD)	Difference (post-pre; mean \pm SD)	<i>P</i>
Hyoid position				
Rgn-H (mm)	36.0 \pm 3.7	37.9 \pm 3.9	1.9 \pm 4.1	0.130
H-MnPl (mm)	15.1 \pm 4.3	14.8 \pm 3.6	-0.4 \pm 2.8	0.407
C3H (mm)	36.2 \pm 2.2	37.4 \pm 3.4	1.2 \pm 2.5	0.070
Tongue position				
TGL (mm)	82.2 \pm 6.3	81.4 \pm 4.4	-0.8 \pm 5.8	0.752
TGH (mm)	34.8 \pm 12.8	32.3 \pm 4.5	-2.5 \pm 12.1	0.369
Soft palate dimensions				
PNS-U (mm)	34.8 \pm 3.0	36.5 \pm 3.0	1.7 \pm 1.9	0.017*
MPT (mm)	8.2 \pm 1.3	7.8 \pm 1.4	-0.4 \pm 1.1	0.248
Soft palate angle ($^{\circ}$)	133.2 \pm 8.4	135.4 \pm 8.4	2.2 \pm 4.4	0.131
Upper airway dimensions				
SPAS (mm)	12.8 \pm 3.7	11.5 \pm 3.3	-1.3 \pm 1.9	0.062
MAS (mm)	9.7 \pm 2.7	7.6 \pm 2.3	-2.1 \pm 1.5	0.002**
IAS (mm)	12.9 \pm 3.5	9.07 \pm 1.6	-3.8 \pm 3.3	0.002**
Skeletal and dental				
SNA	78.9 \pm 2.9	79.0 \pm 2.4	0.1 \pm 1.6	0.722
SNB	75.7 \pm 2.4	76.1 \pm 2.2	0.5 \pm 1.3	0.221
ANB	3.2 \pm 1.0	2.9 \pm 0.9	-0.3 \pm 0.9	0.234
FMA	31.1 \pm 4.8	31.7 \pm 4.3	0.6 \pm 2.6	0.280
U1-SN	107.8 \pm 3.3	93.8 \pm 4.9	-14.1 \pm 3.9	0.001**
IMPA	101.6 \pm 4.5	89.7 \pm 3.9	-11.9 \pm 3.9	0.001**

* $P < 0.05$, ** $P < 0.01$.

In the present study, the subjects in groups 1 and 2 had similar dentofacial characteristics and were diagnosed as borderline and thus could be treated either extraction or non-extraction. The patients in group 1 were treated with minimum anchorage so mesial molar movement was obtained after resolution of anterior crowding. The mean SPAS and MAS dimensions increased approximately 1.5 mm in this group after treatment. A possible explanation for this might be an increase in posterior tongue space after mesial molar movement. The average mesial molar movement was 3 mm in this group. This increase may also be due to continuing pharyngeal growth.

In group 2, ARS was used to resolve crowding in borderline cases and clinically insignificant mesial molar movement (approximately 0.7 mm) with slight proclination of the lower incisors was observed during treatment. Post-treatment, no significant change in nasopharyngeal soft tissue and airway dimensions was found in this group.

In group 3, the upper and lower incisors were retracted. At the same time, the mean MAS and IAS decreased significantly during treatment by approximately 3 mm. This amount of decrease cannot be explained by growth changes and might be due to narrowing of the tongue space after significant incisor retraction. Soft palate lengthening after treatment might also have contributed to

the decrease in MAS in group 3. After mandibular setback surgery, Nathanson and Moynihan (1966) and Marşan *et al.* (2008) reported a significant increase in soft palate length and stated that this occurred as an adaptation to decreased tongue pressure on the mandible and anterior teeth.

When changes in airway dimensions in these three groups were compared, airway dimensions increased in patients where mesial molar movement occurred, decreased when the incisors were retracted, and did not change when these teeth remained stable during treatment. The most suitable explanation for this was hypothesized as adaptational changes of the tongue (Heiser *et al.*, 2004). However, no clear cause and consequence relationship can be drawn from the present findings. Future research should investigate the effects of extraction treatment on posterior airway space with three-dimensional imaging and different tongue dimension measurement techniques. It is clear that nasopharyngeal airway size can be changed by orthodontic therapy. Thus, the respiratory form and size of the nasopharyngeal airway should be taken into consideration when planning orthodontic treatment.

Conclusions

1. Superior and middle airway size increased in subjects treated with extraction and minimum anchorage.
2. In patients treated non-extraction by ARS, no significant change was observed in airway dimensions.
3. Middle and inferior airway size narrowed in subjects treated with extraction and maximum anchorage.

References

- Abu Allhaja E S, Al-Khateeb S N 2005 Uvulo-glosso-pharyngeal dimensions in different anteroposterior skeletal patterns. *Angle Orthodontist* 75: 1012–1018
- Bacon W H, Turlot J C, Krieger J, Stierle J L 1990 Cephalometric evaluation of pharyngeal obstructive factors in patients with sleep apnea syndrome. *Angle Orthodontist* 60: 115–122
- Battagel J M, Johal A, L'Estrange P R, Croft C B, Kotecha B 1999 Changes in airway and hyoid position in response to mandibular protrusion in subjects with obstructive sleep apnoea (OSA). *European Journal of Orthodontics* 21: 363–376
- Carey C 1951 Diagnosis and case analysis in orthodontics. *American Journal of Orthodontics* 38: 149–161
- Chemello P D, Wolford L M, Buschang P H 1994 Occlusal plane alteration in orthognathic surgery—Part II: long-term stability of results. *American Journal of Orthodontics and Dentofacial Orthopedics* 106: 434–440
- Chen F, Terada K, Hua Y, Saito I 2007 Effects of bimaxillary surgery and mandibular setback surgery on pharyngeal airway measurements in patients with Class III skeletal deformities. *American Journal of Orthodontics and Dentofacial Orthopedics* 131: 372–377
- Dahlberg G 1940 Statistical methods for medical and biological students. Interscience, New York
- Doff M H, Hoekema A, Pruim G J, van der Hoeven J H, de Bont L G, Stegenga B 2009 Effects of a mandibular advancement device on the upper airway morphology: a cephalometric analysis. *Journal of Oral Rehabilitation* 36: 330–337

- Eggersperger N, Smolka W, Iizuka T 2005 Long-term changes of hyoid bone position and pharyngeal airway size following mandibular setback by sagittal split ramus osteotomy. *Journal of Cranio-Maxillofacial Surgery* 33: 111–117
- Enacar A, Aksoy A U, Sencift Y, Haydar B, Aras K 1994 Changes in hypopharyngeal airway space and in tongue and hyoid bone positions following the surgical correction of mandibular prognathism. *International Journal of Adult Orthodontics and Orthognathic Surgery* 9: 285–290
- Fromm B, Lundberg M 1970 Postural behaviour of the hyoid bone in normal occlusion and before and after surgical correction of mandibular protrusion. *Svensk Tandlakare Tidskrift* 63: 425–433
- Germeç D, Taner T U 2008 Effects of extraction and non-extraction therapy with air-rotor stripping on facial esthetics in postadolescent borderline patients. *American Journal of Orthodontics and Dentofacial Orthopedics* 133: 539–549
- Güven O, Saracoglu U 2005 Changes in pharyngeal airway space and hyoid bone positions after body osteotomies and sagittal split ramus osteotomies. *Journal of Craniofacial Surgery* 16: 23–30
- Handelman C S, Osborne G 1976 Growth of the nasopharynx and adenoid development from one to eighteen years. *Angle Orthodontist* 46: 243–259
- Heiser W, Niederwanger A, Baner B, Bittermann G, Neunteufel N, Kulmer S 2004 Three-dimensional dental arch and palatal form changes after extraction and non-extraction treatment. Part 3. Transversal and sagittal palatal form. *American Journal of Orthodontics and Dentofacial Orthopedics* 126: 91–99
- Hiyama S, Ono T, Ishiwata Y, Kuroda T 2001 Changes in mandibular position and upper airway dimension by wearing cervical headgear during sleep. *American Journal of Orthodontics and Dentofacial Orthopedics* 120: 160–168
- Kawakami M, Yamamoto K, Fujimoto M, Ohgi K, Inoue M, Kirita T 2005 Changes in tongue and hyoid positions, and posterior airway space following mandibular setback surgery. *Journal of Cranio-Maxillofacial Surgery* 33: 107–110
- Kikuchi M 2005 Orthodontic treatment in children to prevent sleep-disordered breathing in adulthood. *Sleep and Breathing* 9: 146–158
- Kilic N, Oktay H 2008 Effects of rapid maxillary expansion on nasal breathing and some naso-respiratory and breathing problems in growing children: a literature review. *International Journal of Pediatric Otorhinolaryngology* 72: 1595–1601
- Kilinc A S, Arslan S G, Kama J D, Ozer T, Dari O 2008 Effects on the sagittal pharyngeal dimensions of protraction and rapid palatal expansion in Class III malocclusion subjects. *European Journal of Orthodontics* 30: 61–66
- King E W 1952 A roentgenographic study of pharyngeal growth. *Angle Orthodontist* 22: 23–37
- Linder-Aronson S, Leighton B C 1983 A longitudinal study of the development of the posterior nasopharyngeal wall between 3 and 16 years of age. *European Journal of Orthodontics* 5: 47–58
- Lyberg T, Krogstad O, Djupesland G 1989 Cephalometric analysis in patients with obstructive sleep apnoea syndrome: II. Soft tissue morphology. *Journal of Laryngology and Otology* 103: 293–297
- Marşan G, Cura N, Emekli U 2008 Changes in pharyngeal (airway) morphology in Class III Turkish female patients after mandibular setback surgery. *Journal of Cranio-Maxillofacial Surgery* 36: 341–345
- Marşan G, Vasfi K S, Oztas E, Cura N, Susal Z, Emekli U 2009 Oropharyngeal airway changes following bimaxillary surgery in Class III female adults. *Journal of Cranio-Maxillofacial Surgery* 37: 69–73
- Miles P G, O'Reilly M, Close J 1995 The reliability of upper airway landmark identification. *Australian Orthodontic Journal* 14: 3–6
- Nathanson N R, Moynihan F M 1966 Prognathism: one-stage intraoral osteotomy. *Journal of Oral Surgery* 24: 410–421
- Oktay H, Ulukaya E 2008 Maxillary protraction appliance effect on the size of the upper airway passage. *Angle Orthodontist* 78: 209–214
- Oliveira De Felipe N L, Da Silveira A C, Viana G, Kusnoto B, Smith B, Evans C A 2008 Relationship between rapid maxillary expansion and nasal cavity size and airway resistance: short- and long-term effects. *American Journal of Orthodontics and Dentofacial Orthopedics* 134: 370–382
- Ozbek M M, Memikoglu T U, Gögen H, Lowe A A, Baspinar E 1998 Oropharyngeal airway dimensions and functional-orthopedic treatment in skeletal Class II cases. *Angle Orthodontist* 68: 327–336
- Pirilä-Parkkinen K *et al.* 1999 Cervical headgear therapy as a factor in obstructive sleep apnea syndrome. *Pediatric Dental Journal* 21: 39–45
- Preston C B, Tobias P V, Salem O H 2004 Skeletal age and growth of the nasopharynx in the sagittal plane: a cephalometric study. *Seminars in Orthodontics* 10: 16–38
- Ricketts R M 1968 Respiratory obstruction syndrome. *American Journal of Orthodontics* 54: 495–507
- Riley R W, Powell N B 1990 Maxillofacial surgery and obstructive sleep apnea syndrome. *Otolaryngologic Clinics of North America* 23: 809–826
- Sayinsu K, Isik F, Arun T 2006 Sagittal airway dimensions following maxillary protraction: a pilot study. *European Journal of Orthodontics* 28: 184–189
- Solow B, Tallgren A 1971 Natural head position in standing subjects. *Acta Odontologica Scandinavica* 29: 591–607
- Tecco S, Caputi S, Festa F 2007 Evaluation of cervical posture following palatal expansion: a 12-month follow-up controlled study. *European Journal of Orthodontics* 29: 45–51
- Turnbull N R, Battagel J M 2000 The effects of orthognathic surgery on pharyngeal airway dimensions and quality of sleep. *Journal of Orthodontics* 27: 235–247