

See discussions, stats, and author profiles for this publication at: <https://www.researchgate.net/publication/7632410>

Evaluation of mandibular bone density to predict osteoporosis in adolescents with constitutional delayed growth

Article in Saudi medical journal · September 2005

Source: PubMed

CITATIONS

3

7 authors, including:



Murat Ozbek

Hacettepe University

16 PUBLICATIONS 372 CITATIONS

[SEE PROFILE](#)



Nuray Kanbur

Hacettepe University

105 PUBLICATIONS 789 CITATIONS

[SEE PROFILE](#)

READS

93



Kaan Orhan

Ankara University

267 PUBLICATIONS 1,921 CITATIONS

[SEE PROFILE](#)



Cagri Delilbasi

Istanbul Medipol University School of Dentistry, School of Medicine

69 PUBLICATIONS 566 CITATIONS

[SEE PROFILE](#)

Some of the authors of this publication are also working on these related projects:



Imaging of the Temporomandibular Joint [View project](#)



FWO-TUBITAK Bilateral project [View project](#)

Evaluation of mandibular bone density to predict osteoporosis in adolescents with constitutional delayed growth

Sema Dural, DDS, PhD, Murat Ozbek, DDS, PhD, Aydan Kanli, DDS, PhD, Kaan Orhan, DDS, PhD, Nuray O. Kanbur, MD, PhD, Orhan Derman, MD, PhD, Cagri Delilbasi, DDS, PhD.

ABSTRACT

Objective: The aim of this study is to evaluate the correlation between constitutional delayed growth (CDG) and mandibular bone trabeculation as well as bone density on panoramic radiographs using a computer software program.

Methods: Panoramic radiographs obtained from 25 patients with CDG and 25 healthy adolescents were evaluated for this study. Patients were selected from admission to Hacettepe University, Faculty of Medicine, Section of Adolescent Medicine in the first half of the year 2002. All panoramic radiographs were taken under standard conditions, and were randomized and then converted to digital images for density analysis using a scanner. The images were transferred to Osiris computer software program for the evaluation of bone density from

4 different regions on the mandible (right and left mandibular angle and condyle).

Results: The CDG group had higher values for the risk of osteoporosis considering the right ($t=3.360, p=0.002$) and the left condyle ($t=3.620, p=0.001$) (t-test for independent samples). It was also seen that the CDG group was again at higher risk in comparison to the control group when left mandibular angle values were measured ($z=-2.447, p=0.014$) (Mann Whitney - U test).

Conclusion: We suggest that panoramic radiographs, which are transformed into digital format, can be valuable and economic tools for detecting the risk of osteoporosis in adolescents with CDG.

Saudi Med J 2005; Vol. 26 (8): 1235-1239

Constitutional delayed growth (CDG) describes a normal variant of maturational tempo characterized by short stature, but relatively normal growth pattern with a late and attenuated pubertal growth spurt during adolescence.¹ A CDG occurs in healthy adolescents with stature reduced for chronological age, but generally appropriate for bone age and stage of pubertal development, both of which are usually delayed.² A CDG is more

common in boys than in girls, and tends to have a familial pattern.³

Osteopenia has been reported in adult men with a history of CDG. This finding suggests that the timing of sexual maturation is an important determinant of adult bone mineral density (BMD).⁴ A highly significant correlation between skeletal BMD, and the interdental thickness of the mandibular alveolar process was found in earlier

From the Department of Oral Diagnosis and Radiology (Dural, Ozbek, Kanli), Faculty of Dentistry, Department of Pediatrics, Section of Adolescent Medicine (Kanbur, Derman), Faculty of Medicine, Hacettepe University, Department of Oral Diagnosis and Radiology (Orhan), Faculty of Dentistry, Ankara University, Ankara and the Department of Oral and Maxillofacial Surgery (Delilbasi), Faculty of Dentistry, Yeditepe University, Istanbul, Turkey.

Received 7th February 2005. Accepted for publication in final form 28th May 2005.

Address correspondence and reprint request to: Dr. Cagri Delilbasi, Department of Oral and Maxillofacial Surgery, Faculty of Dentistry, Yeditepe University, Bagdat Caddesi No. 238, 34728 Goztepe, Istanbul, Turkey. Tel. +90 (542) 5837240. Fax. +90 (216) 3636211. E-mail: cdelilbasi@yahoo.com

studies. The BMD in the mandible has been shown in a number of studies, to be positively correlated with that in the lumbar spine, femoral neck and forearm, which are important sites in osteoporosis.⁵ Osteoporosis has been associated in some studies with residual ridge resorption^{6,7}, periodontal bone loss,^{8,9} and bone quality.^{10,11} Panoramic radiograph is a common, clinically acceptable imaging system routinely used for screening and treatment planning in dentistry. Recent studies have used panoramic radiographs for studying the relationship between mandibular bone and osteoporosis. Mohajery and Brooks¹² used panoramic and intraoral radiographs in order to determine whether changes in osteoporotic patients also affect the mandible. Taguchi et al¹³ studied the relationship between mandibular bone mass, and the number of teeth present by using mandibular cortical width measured on panoramic radiographs. Webber¹⁴ also used intraoral and extraoral radiographs to evaluate osseous changes. Mohammad et al¹⁵ investigated the association of spinal bone density, and the density of selected mandibular sites from panoramic radiographs. The purpose of the present study was to investigate the density of the mandibular bone using a digital imaging software program in normal and CDG adolescents and to examine whether bone density in panoramic radiographs provide information for the risk of osteoporosis in CDG patients.

Methods. Indirect digital imaging test for mandibular bone density was carried out in 25 (8 females and 17 males) adolescents with CDG (study group) and in 25 (12 females and 13 males) healthy adolescents (control group). Selection criteria used for presumptive diagnosis of CDG are: no history of systemic disease; normal nutrition; normal physical examination including body proportions; normal thyroid hormone, normal insulin-like growth factor-1 (IGF-1) and insulin-like growth factor binding protein-3 (IGFBP-3) levels; normal complete blood count (CBC), sedimentation rate, electrolytes, blood urea nitrogen (BUN), height at or below the 10th percentile for Turkish children and adolescents, but with annual growth rate of >5th percentile for age, delayed bone age and normal predicted adult height: males: >163 cm (64 inches), females: >150 cm (59 inches). In the study group, mean chronological age \pm standard deviation (SD) was 12.68 ± 1.63 years, and mean bone age \pm SD was 10.43 ± 1.51 years. In the control group the mean chronological age \pm SD was 12.33 ± 1.90 years and the mean bone age \pm SD was 12.15 ± 1.81 years.

Firstly, panoramic images from both groups were taken under standard conditions with the conventional Planmeca 2002 CC panoramic system

(Focal spot size: 0.5 mm x 0.5 mm, Anode voltage: 60-80 kV, Anode current: 4-12 mA DC, total filtration: 2.5 mm Al, Planmeca-Helsinki, Finland). Just before exposure, the lateral head positioners were removed from the x-ray machine to eliminate density interference by the plastic. The panoramic radiographs (Kodak T-Mat G) were processed with Durr dental XR 25 S (Durr - Dental GmbH u Co.KG Bissingen/Germany) after obtaining conventional radiographs from both groups. The radiographs were masked and then numbered in order to randomized. A Mustek 1200 AT (Taiwan, R.O.C) flatbed scanner system with transparency adapter was used to digitalized the radiographs. Six hundred dots per inch, 16-bit gray level scanning, and transparency-scanning mode were used. The radiographs that to be digitalized were placed on the center of the scanner surface, and all areas outside the radiograph were masked out using a black opaque plastic in order to minimize the external light coming from transparency adapter. The operator was aware that the study involved bone density variation, but was blinded to the status of the patient.

The image analysis was performed using the Osiris computer software (University Hospital of Geneva, Switzerland). This program provided a complete range of image acquisition, processing, and analysis functions.¹⁶ This program is not commercially available, but can be used as a research tool. The software was operated on the PC computer running and MS WINDOWS 98 (Microsoft, WA, USA). On the digitalized images, the investigator applied 4 region of interest (ROI) to the images where ROIs were on both mandibular condyle and mandibular angle. Bone density measurements of the mandibular angle were made by drawing a line from the mandibular angle parallel to the inferior border of the radiograph. In order to identify a reproducible portion of the mandibular bone that did not include any cortical plate on the posterior or inferior aspects of the mandible, and did not extend to mandibular canal, elliptic ROI areas were drawn, which are tangent to this line, starting from the inner edge of the cortical layer (**Figure 1**). Bone density measurements of the condyle were made by drawing in 2 lines. The first line (L1) was parallel to inferior border of the radiograph and passing through the most superior point of the functional surface of the condyle. The second line (L2) was parallel to L1, and passing through the collum of the mandible. Elliptic ROI areas were then drawn between these lines and tangent to L1, starting from the inner edge of the cortical layer (**Figure 2**). Through prior pilot studies, the areas on panoramic films that, in general, had the fewest inherent variables were identified. Inherent variables included the ghosting of the spine, contralateral mandibular angles, and

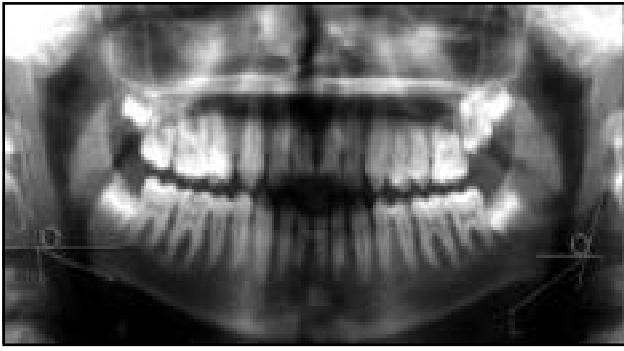


Figure 1 - The view of ROIs on left and right mandibular angle on panoramic radiograph. ROI - region of interest

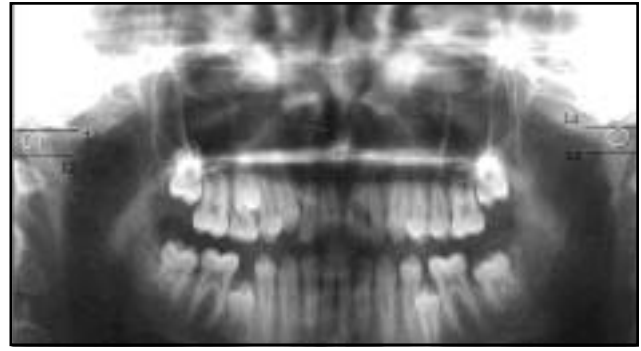

Figure 2 - The view of ROIs on left and right condyles on a panoramic radiograph. ROI - region of interest

Table 1 - The mean and standard deviation of statistical analysis (t-test for independent samples).

Group	Individual (n)	mean \pm SD	t-test	p-value	z	p-value
Right condyle						
CDG	25	133.680 \pm 31.400				
Control	25	104.760 \pm 29.425	3.360	0.002*		
Left condyle						
CDG	25	126.200 \pm 28.232				
Control	25	96.640 \pm 29.489	3.620	0.001*		
Right mandibular angle						
CDG	25	55.160 \pm 18.750			1.641	0.101 (ns)
Control	25	46.240 \pm 12.484				
Left mandibular angle						
CDG	25	54.280 \pm 18.474			2.447	0.014 (s)*
Control	25	44.920 \pm 8.149				
CDG - constitutional delayed growth, ns - not significant, *significant						

superimposed air spaces. The general area identified the least variable was the premolar area. In this area the film provided the least variable amount of interference. In this study, some patients were in the mixed dentition; therefore, the best area for density measurement was thought to be mandibular angle. Prior studies found out that the pathology of the condyle correlated with BMD in women.¹⁷ Therefore, we planned to investigate the bone density in the condyle as well.

The ROI values were measured and calculated with Osiris digital imaging software for bone density values. The results obtained from the patients and control groups have been evaluated by means of a "t-test for independent samples". Since the variances of right and left condyle values for the study and the control groups were homogeneous ($p > 0.05$) (in accordance with the Levene test), the statistical test was deemed valid.

It was also observed that the variances of right and left mandibular angle values for the study and the control groups were not homogeneous (in accordance with the Levene test) ($p < 0.05$). Therefore, Mann Whitney - U Test, which has a non-parametric equivalent, was used.

Results. The mean film density of right condyle for the study group was 133.680, while the mean film density of left condyle was 126.200. The mean density of right mandibular angle was 55.160, while the left mandibular angle was 54.280. For the control group, the mean density of the right condyle was 104.76, and the left condyle was 96.640. The mean density of the right angle was 46.240 and the left mandibular angle was 44.920 (Table 1).

When the study and the control groups were compared with each other in terms of right and left condyle, it was determined that mean densities in

the study group had higher values compared to the control group, ($t=3.360$, $p=0.002$ and $t=3.620$, $p=0.001$) (t-test for independent samples). In both groups, left and right mandibular angle data were analyzed by Mann Whitney-U test, as the data were not distributed homogeneously ($p > 0.05$). It was found that left mandibular angle mean densities in the study group were again higher in comparison to the control group ($z=-2.447$, $p=0.014$), but the difference between the right mandibular angle and mean densities were not significant ($z=-1.641$, $p=0.101$).

In the study group, when the differences between the right and left condyle mean densities were analyzed through a t- test for dependent samples, no significance was found ($t=1.686$, $p=0.105$). In the same manner, when the differences between the right and left angle values were analyzed in the same group by means of a t-test for dependent samples, no difference was found either ($t=0.336$, $p=0.740$). Furthermore, the differences between the right and left mandibular angle values in the control group were found to be insignificant ($t=0.845$, $p=0.406$) when analyzed by a t-test for dependent samples. However, in the control group the difference between the right condyle and the left condyle was found to be significant when analyzed through a t-test for dependent samples ($t=2.092$, $p=0.047$).

DISCUSSION. Constitutional delayed growth is a common problem mostly affecting up to 3% of otherwise normal adolescents. Decreased radial, spinal, and femoral BMD in CDG patients have been reported when compared to healthy subjects. Delay in pubertal development may impair the achievement of peak bone mass. Dental development is also adversely affected in CDG. Gaethofs et al³ revealed a significant retardation of dental maturation in CDG patients.

In this study, when the density of the bone in the condyle and mandibular angle region was investigated, it was observed that the mean film densities increased in the condyle region in the CDG group when compared with the control group, which indicated decreased BMD, and risk for developing osteoporosis. When right and left mandibular angle and condyle values were compared between groups, the left angle as well as right and left condyles were determined to be at risk for developing osteoporosis in adolescents with CDG. In our study, in order to obtain standardization, the same panoramic system and film process were applied to all the radiographs, which were scanned in the same way.

Geraets et al⁸ found that the radiographic trabecular pattern can be used as a noninvasive tool to study the architecture of bone in vivo. Klemetti et al¹⁹ and von Wowern et al⁹ had emphasized the

significant relationship among densities of different bones in the skeleton. Similar results were also obtained in studies conducted on animals.²⁰ Several methods have been developed for evaluating bone mass, including quantitative computed tomography, single and dual-photon absorptiometry and neutron activation analysis. Unfortunately, these techniques involve special radiographic procedures and are relatively expensive.²¹ Horner and Devlin¹⁰ stated that it might be feasible to use mandibular cortical thickness, and panoramic mandibular index as diagnostic indicators of mandibular BMD. Jonasson et al²² in their study showed that alveolar trabecular pattern might be a useful and simple warning signal in the detection of osteopenia or osteoporosis. They found that dense trabeculation is a reliable sign of normal BMD, whereas sparse trabeculation indicates osteopenia. Alternating dense and sparse trabeculation was found both in patients with low and normal BMD, but the existence of translucent lesions is a sign of low BMD. Significant relationships among mandibular bone mass, density, and cortical thickness at the gonion, and the skeletal bone in postmenopausal women with osteoporosis, indicated the association of skeletal and mandibular osteopenia.¹¹ Von Wowern and Stoltz²³ found that cortical thickness at the gonion was stable until the 5th to 6th decade. They also found that there was no difference in cortical bone mass in dentate, partially dentate or edentulous individuals. In our study, left mandibular angle values were higher in the CDG group, but no differences occurred on the right side. This may be due to changes in cortical bone that do not occur as rapidly as changes in the trabecular bone. Most dentists routinely take intraoral and sometimes extraoral radiographs. Use of dental radiographs for this purpose is not only more economical, but also minimizes exposure of the patient to radiation.²¹ Adolescents with CDG may catch up with a late and attenuated pubertal growth spurt and generally have the expected adult height with a regular bone age. However, the bone mineral density of these adolescents should be followed up for osteoporosis risk.²⁴ As a result of this study, although panoramic images have inherent limitations when used for diagnostic purposes, it may still be possible to use these films as preliminary screening tools for adolescents with CDG, who are at risk of developing systemic osteoporosis.

References

1. Reiter EO, Rosenfeld RG. Normal and aberrant growth. In: Wilson JD, editor. *Williams Textbook of endocrinology*. Philadelphia: WB Saunders Company; 1998. p. 1427-1507.
2. Prader A. Delayed adolescence. *Clin Endocrinol Metab* 1975; 4: 143-155.
3. Gaethofs M, Verdonck A, Carels C, de Zegher F. Delayed

- dental age in boys with constitutionally delayed puberty. *Eur J Orthod* 1999; 21: 711-715.
4. Finkelstein JS, Neer RM, Biller BM, Crawford JD, Klibanski A. Osteopenia in men with a history of delayed puberty. *N Engl J Med* 1992; 326: 600-604.
 5. von Wower N. In vivo measurement of bone mineral content of mandibles by dual-photon absorptiometry. *Scand J Dent Res* 1985; 93: 162-168.
 6. Hirai T, Ishijima T, Hashikawa Y, Yajima T. Osteoporosis and reduction in residual ridge in edentulous patients. *J Prosthet Dent* 1993; 69: 49-56.
 7. Jeffcoat MK, Chesnut CH 3rd. Systemic osteoporosis and oral bone loss: evidence shows increased risk factors. *J Am Dent Assoc* 1993; 124: 49-56.
 8. Klemetti E, Collin HL, Forss H, Markkanen H, Lassila V. Mineral status of the skeleton and advanced periodontal disease. *J Clin Periodontol* 1994; 21: 184-188.
 9. Von Wower N, Klausen B, Kollerup G. Osteoporosis: a risk factor in periodontal disease. *J Periodontol* 1994; 65: 1134-1138.
 10. Horner K, Devlin H. The relationship between mandibular bone mineral density and panoramic radiographic measurements. *J Dent* 1998; 26: 337-343.
 11. Kribbs PJ, Chesnut CH 3rd, Ott SM, Kilcoyne RF. Relationships between mandibular and skeletal bone in an osteoporotic population. *J Prosthet Dent* 1989; 62: 703-707.
 12. Mohajery M, Brooks SL. Oral radiographs in the detection of early signs of osteoporosis. *Oral Surg Oral Med Oral Pathol* 1992; 73: 112-117.
 13. Taguchi A, Tanimoto K, Sueti Y, Wada T. Tooth loss and mandibular osteopenia. *Oral Surg Oral Med Oral Pathol Oral Radiol Endod* 1995; 79: 127-132.
 14. Webber RL. Oral imaging a diagnostic tool for assessing osseous changes. *J Bone Miner Res* 1993; 8: 543-548.
 15. Mohammad AR, Alder M, McNally MA. A pilot study of panoramic film density at selected sites in the mandible to predict osteoporosis. *Int J Prosthodont* 1996; 9: 290-294.
 16. Ligier Y, Ratib O, Logean M, Girard C. Osiris: a medical image-manipulation system. *MD Comput* 1994; 11: 212-218.
 17. Lombardi GR, Jasinevicius TR, Pyle MA, Nelson S, Lalumandier JA, Sawyer DR et al. Relationship of CT analysis with mandibular bone measurements and temporomandibular joint degeneration. *J Dent Res* 2003; 82: Special issue B: 306.
 18. Geraets WG, Van der Stelt PF, Elders PM. The radiographic trabecular bone pattern during menopause. *Bone* 1993; 14: 859-864.
 19. Klemetti E, Vainio P, Lassila V, Alhava E. Trabecular bone mineral density of mandible and alveolar height in postmenopausal women. *Scand J Dent Res* 1993; 101: 166-170.
 20. Bresin A, Jonasson G, Kiliaridis S. Effects of occlusal strain on the development of the dentoalveolar process in the growing rat. *European Journal of Experimental Musculoskeletal Research* 1994; 3: 112-122.
 21. Law AN, Bollen AM, Chen SK. Detecting osteoporosis using dental radiographs: a comparison of four methods. *J Am Dent Assoc* 1996; 127: 1734-1742.
 22. Jonasson G, Bankvall G, Kiliaridis S. Estimation of skeletal bone mineral density by means of the trabecular pattern of the alveolar bone, its interdental thickness, and the bone mass of the mandible. *Oral Surg Oral Med Oral Pathol Oral Radiol Endod* 2001; 92: 346-352.
 23. Von Wower N, Stoltze K. Pattern of age related bone loss in mandibles. *Scand J Dent Res* 1980; 88: 134-146.
 24. Styne DM. Puberty and its disorders in boys. *Endocrinol Metab Clin North Am* 1991; 20: 43-49.