

# Recurrent Hemoptysis and a Mass in the Thorax in an Infant: The Split Notochord Syndrome

Mutlu Uysal Yazici<sup>1</sup> Saniye Ekinci<sup>2</sup> Ozlem Keskin Turkmen<sup>3</sup> Ebru Gunes Yalcin<sup>4</sup> Arbay O. Ciftci<sup>2</sup> Safak Gucer<sup>5</sup> Diclehan Orhan<sup>5</sup> Ilhan Tezcan<sup>6</sup>

<sup>1</sup>Department of Pediatrics, Hacettepe University Children's Hospital, Ankara, Turkey

<sup>2</sup>Department of Pediatric Surgery, Hacettepe University Children's Hospital, Ankara, Turkey

<sup>3</sup>Department of Pediatric Allergy and Immunology, Gaziantep University, Ankara, Turkey

<sup>4</sup>Department of Pediatric Pulmonology, Hacettepe University School of Medicine, Ankara, Turkey

<sup>5</sup>Department of Pediatric Pathology, Hacettepe University, Ankara, Turkey

<sup>6</sup>Department of Pediatric Immunology, Hacettepe University School of Medicine, Ankara, Turkey

**Address for correspondence** Mutlu Uysal Yazici, MD, Department of Pediatrics, Hacettepe University Children's Hospital, Altindag, Ankara 06100, Turkey (e-mail: mutluuysal@yahoo.com).

Eur J Pediatr Surg Rep 2014;2:38–42.

## Abstract

Split notochord syndrome is a rare group of developmental abnormalities caused by abnormal splitting or deviation of the notochord clinically resulting in the duplicated bowel associated with vertebral anomalies. We report on a case of 11-month-old female infant with mediastinal hyperechogenic cyst and intestinal duplication cyst associated with T5-T6 hemivertebrae, scoliosis, and nonfusion of posterior part of T6 vertebrae, presenting with severe hemoptysis and hematemesis. The cysts were surgically removed, and histopathologic analysis revealed that the mediastinal cyst was lined by gastric mucosa and intestinal one was lined with gastric mucosa including ectopic pancreatic tissue. After removal of the lesion the patient made an uneventful recovery and shows no signs of long-term pulmonary sequelae.

## Keywords

- ▶ neurenteric cyst
- ▶ hemoptysis
- ▶ intestinal duplication cyst
- ▶ hematemesis

## Introduction

Split notochord syndrome is a rare group of developmental abnormalities caused by abnormal splitting or deviation of the notochord clinically resulting in the duplicated bowel associated with vertebral anomalies. Duplication cysts represent 11 to 18% of mediastinal lesions seen during infancy and childhood and must be considered in the differential diagnosis of mediastinal masses. They are characteristically found in the posterior mediastinum, nearby pulmonary hilus and most commonly on the right side but may expand into either hemithorax. In this syndrome, clinical findings such as vomiting, abdominal pain,

and hemoptysis usually emerge before the age of 1 year and more commonly seen in boys than girls.

The notochord is present about the end of the third week of life. Early failure of splitting the notochord from the foregut results in a cyst or fistula (split-notochord syndrome) and the cyst is termed as “neurenteric cyst”. This cyst may interfere with anterior fusion of the vertebral mesoderm, and vertebral anomalies are seen in approximately 50% of cases.<sup>1,2</sup>

We report a case of 11-month-old female infant who was admitted to the hospital with the complaints of severe hemoptysis, hematemesis, and hematochezia which was recently diagnosed as split notochord syndrome.

received  
March 19, 2013  
accepted after revision  
July 25, 2013  
published online  
September 13, 2013

DOI <http://dx.doi.org/10.1055/s-0033-1354745>.  
ISSN 2194-7619.

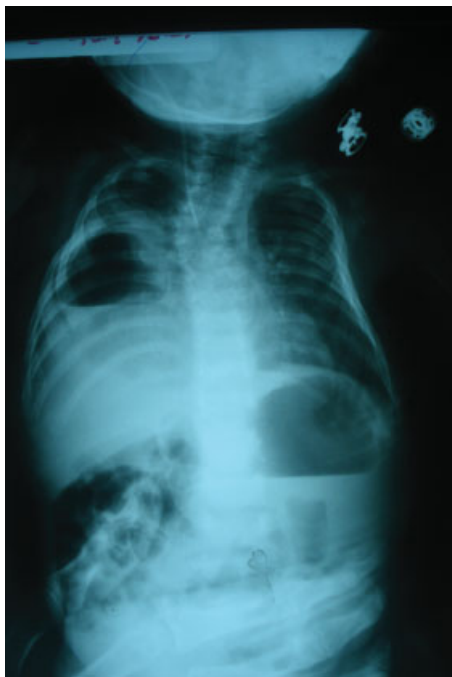© 2014 Georg Thieme Verlag KG  
Stuttgart · New York

License terms



## Case Report

An 11-month-old female infant was admitted to our hospital with a complaint of hemoptysis, hematemesis, and hematochezia. The baby was born weighing 3,100 g after an unremarkable pregnancy. The history of cough, cyanosis, or vomiting started since she was 10 days of age and these complaints were unrelated with feeding. At the age of 7 months, a diagnosis of pneumonia was made and the patient was hospitalized for 50 days in the intensive care unit of a regional hospital. She was given antibiotics and mechanical ventilation support. On physical examination, a marked pallor, intercostal and suprasternal retraction, diminished breath sounds at right hemithorax and bilaterally fine crackles have been detected. A chest X-ray revealed right middle zone hyperechogenic cyst (→Fig. 1). A thoracic computed tomography (CT) scan confirmed the presence of cystic lesion located in right lower pulmonary field with two additional similar cystic lesions, which have no extension to neighboring structures especially to thoracic vertebrae. She was given packed red cells every day because of severe hemoptysis, hematemesis, and hematochezia. To delineate the etiology of hemoptysis, hematemesis, and hematochezia, upper gastrointestinal endoscopy and colonoscopy was performed and yielded no pathological findings. Patient had undergone a right thoracotomy for excision of the cystic lesion before admission to our center. The cyst has been excised in fragments and histological examination revealed that the cyst was lined by gastric mucosa exhibiting extensive squamous metaplasia. After the operation, the patient still had hemoptysis and hematochezia so at the age of 11 months she was referred to our hospital. On admission to our hospital, physical examination revealed failure to thrive and bilateral



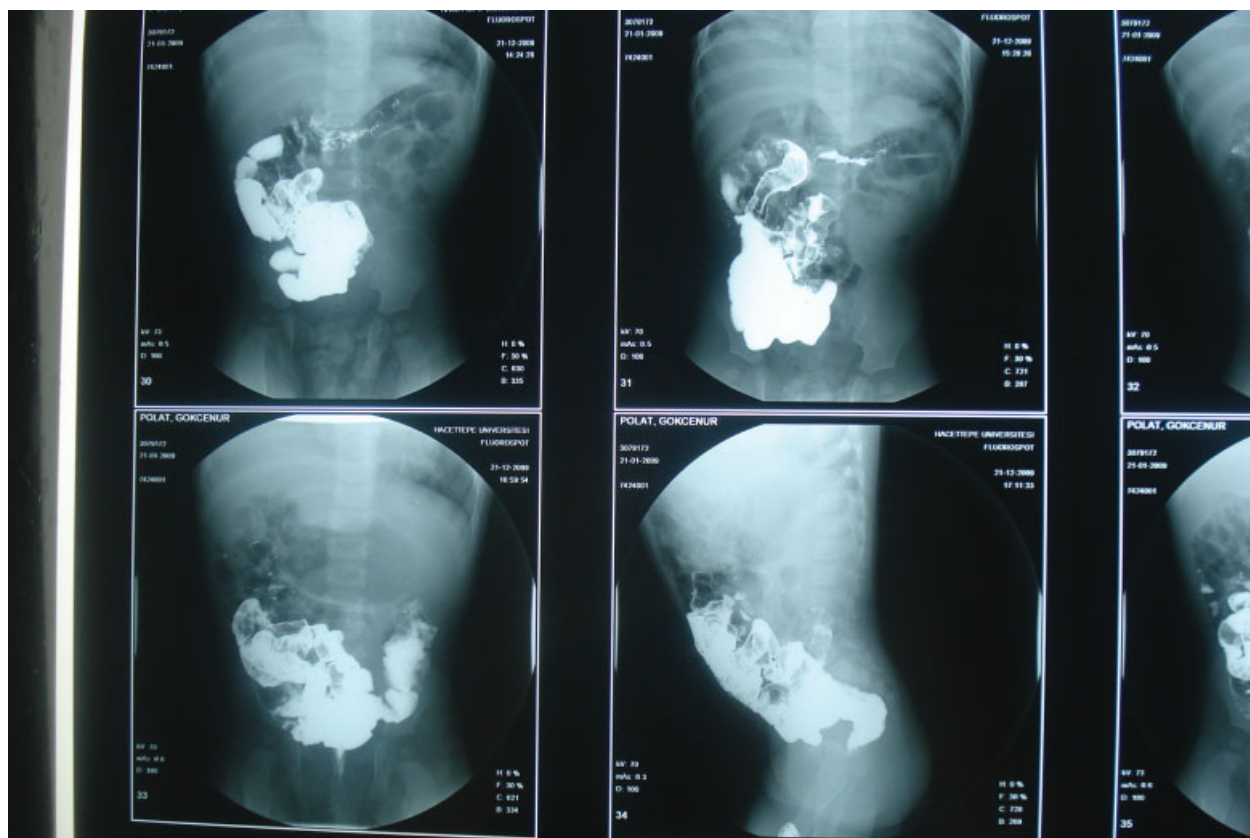
**Fig. 1** Chest X-ray revealing a cystic lesion in the lung.

fine crackles at the base of lungs on auscultation whereas other clinical findings were unremarkable. Complete blood count revealed microcytic hypochromic anemia (Hb: 9.7 gr/dL) with white blood cell count and platelet counts, 15,100 /mL and 426,000/mL, respectively. Laboratory tests, including renal function tests, serum electrolytes, liver enzymes, and blood gas analyses were normal. Sweat chloride level was in normal range. Echocardiography revealed patent foramen ovale. Chest X-Ray demonstrated T5-T6 hemivertebrae, scoliosis, and nonfusion of posterior part of T6 vertebrae. On the basis of the vertebral anomalies and history of mediastinal cyst a diagnosis of split notochord syndrome was made. The patient's neurological examination was normal. Therefore, we did not consider about consultation to neurosurgery and neurology departments. Diagnostic bronchoscopic examination confirmed bloody discharge from right lower lobe bronchus, but bronchography did not show any fistula, any connection to an extra lobar structure, or any other pathology to explain etiology of hemoptysis. The right lower lobe was consolidated because of chronic infection and erosion caused by the duplication cyst. She had thoracic computed tomography just before the first thoracotomy and the recent chest X-rays showed us the remaining cysts. Therefore, we did not perform additional imaging studies. The patient underwent right lower lobectomy and pathological examination demonstrated the ectopic gastric mucosa with squamous metaplasia of bronchial epithelium. Hemoptysis of the patient was ceased, but she still had hematochezia. Abdominal ultrasonographic examination was normal. Therefore, 99mTc pertechnetate scintigraphy and barium swallow study were obtained to detect any intestinal duplication. Barium swallow study demonstrated midgut malrotation and 99mTc pertechnetate scintigraphy revealed ectopic mucosa indicating intestinal duplication (→Fig. 2). Laparotomy and exploration revealed tubular duplication of terminal ileum extending to below right diaphragm and midgut malrotation. The duplicated segment was totally excised and Ladd procedure was applied. Pathological examination demonstrated ileal duplication including gastric mucosa and ectopic pancreatic tissue (→Figs. 3 and 4). Infant had an uneventful postoperative period and she is symptom free and thriving 2 months of follow-up.

## Discussion

In infancy period, differential diagnosis of hematemesis include esophagitis such as reflux, infectious, caustic, foreign body, cow milk allergy, localized reactive gastritis/ulcer, esophageal, or gastric varices, hemorrhagic gastritis, perforated ulcer, or eroded vessel, vascular malformations: angiodysplasia, hemangioma, and Dieulafoy lesion.<sup>3</sup> Severe hemoptysis may present as bloody vomiting and can be misdiagnosed as hematemesis.

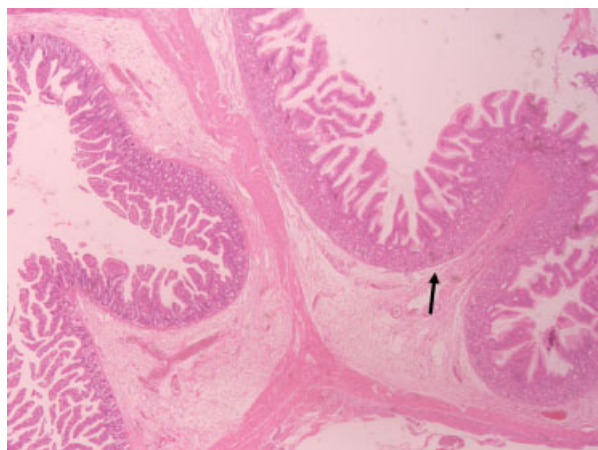
Generally, foregut duplications are seen at any age but majority of them present before 2 year of age and seen predominantly in males. These duplications may arise anywhere in the gastrointestinal tract. There are several theories, which try to explain how cysts occur, but most popular one is



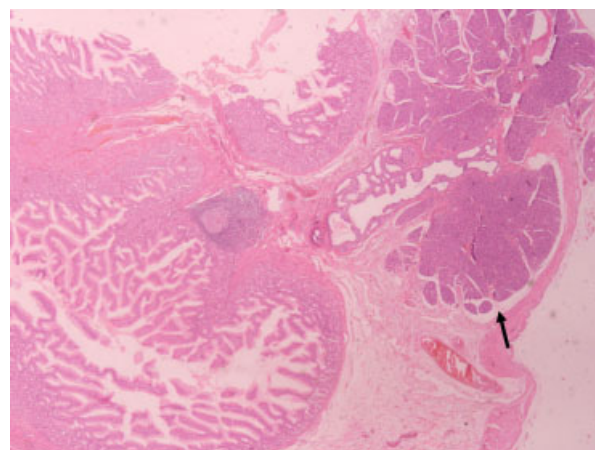
**Fig. 2** Barium swallow showing midgut malrotation.

split notochord syndrome. Split notochord syndrome is failure of splitting the notochord from the foregut resulting in a cyst or fistula. The attachment of the cyst to notochord prevents fusion of vertebral bodies and resulting in vertebral column anomalies such as scoliosis, hemivertebrae, and spina bifida.<sup>4</sup> These cysts usually move caudally as the embryo grows and the intrathoracic viscera descend, and the vertebral anomalies encountered are often in the lower cervical spine.<sup>5</sup> The clinical findings of duplicated cysts can differ because of the origin, size, and nature of cysts. Midgut

duplications are the most common ones.<sup>6</sup> Duplication cysts are often lined by more than one epithelial cell type as in our case. Gastric mucosa is the predominant cell type. This case had gastric mucosa and pancreatic tissue lining the duplication cyst. Foregut duplications are associated with multiple intestinal duplications, esophageal and cardiac anomalies. In this case we could not detect any cardiac defect other than patent foramen ovale or any esophageal defect. However, we detected that the intestinal duplication cyst was extending to the thorax.



**Fig. 3** Intestinal duplication cyst with ectopic gastric mucosa (Black arrow).



**Fig. 4** Intestinal duplication cyst with ectopic pancreatic mucosa (Black arrow).

Theoretically, split notochord syndrome can be seen at any level of spine. However, most of the reported cases are seen at cervical and thoracic region.<sup>7</sup> Our case has multiple thoracic vertebral anomalies.

The modalities to diagnose the intrathoracic foregut duplication cyst are chest X-ray, barium swallow studies, ultrasonography, CT, and magnetic resonance imaging (MRI).<sup>8–11</sup> With the help of barium swallow studies, communication between the cyst and the alimentary tract may be demonstrated. By CT or MRI, localization of the cyst and associated abnormalities can be determined. <sup>99m</sup>Tc pertechnetate scintigraphy is frequently used to detect ectopic gastric mucosa.

The most common symptoms, which are dysphagia, acute respiratory distress, or chest pain similar to current case, will depend upon the location and size of the intrathoracic cyst.<sup>12</sup> Symptoms can be present at birth, or may be insidious with cough, wheezing, or recurrent respiratory infections. Late presentations in complicated intrathoracic cysts with infection or bleeding within the cysts could be related to either compression or their spontaneous rupture with fistulation into neighboring structures such as bronchus, esophagus, pericardium, or pleura.<sup>12,13</sup> Sudden infant deaths have been reported in association with bronchogenic cysts.<sup>14</sup> Chronic symptoms such as asthma-like illness, failure to thrive, anemia, and dysphagia have been reported.<sup>12,13</sup> In addition, cardiac arrhythmias due to retrocardiac cysts are known to occur.<sup>14</sup> Ectopic gastric mucosa can also lead to erosion and bleeding.<sup>15</sup>

There may be life-threatening complications of conservative treatment of cysts such as peptic ulceration due to ectopic gastric tissue and mediastinitis secondary to infection resulting in severe hemoptysis. Malignant transformation is a potential hazard and has been reported in residual tissue after incomplete excision of duplication cyst, so that these cysts are best managed by early and complete resection.<sup>12,16</sup>

In a study from Royal Hospital, 21 children were treated for foregut duplications for over 42-year period.<sup>6</sup> The mean age of diagnosis was 1.5 years and initial presentation was within the 6 months of life in 14 cases. Our case was symptomatic at infancy period. Respiratory and gastrointestinal symptoms predominated. The diagnosis was made by chest X-Ray,<sup>14</sup> barium swallow study, surgical exploration, or by ultrasound. All patients were treated surgically and mortality was 10%. The histology of the epithelial lining of duplications revealed gastric mucosa in 15 cases; of these 15 cases, 5 was lined by more than one cell type, as in our case. One of the patients had duplication cyst lined by gastric mucosa, which ulcerated into the bronchial tree, and presented with respiratory distress and hemoptysis. Similarly, our case also had hemoptysis and respiratory distress. Our patient's hemoptysis symptom can be explained by thoracic cyst lined by ectopic gastric mucosa and its ulceration into bronchial tree. Therefore, we believe that hemoptysis symptoms were secondary to the ulcerated gastric mucosa lining thoracic cyst and hematemeses was associated with the gastric mucosa lining the intestinal cyst.

Furthermore, prenatal diagnosis of intrathoracic gastric duplication may be possible by the help of fetal ultrasonog-

raphy. Until now, two reports on prenatal diagnosis of intrathoracic foregut duplication cysts have been published.<sup>17,18</sup> Daher et al reported an intrathoracic gastric duplication cyst detected antenatally on obstetrical ultrasonography at 33 week of gestation.<sup>17</sup> After birth, the newborn was directly intubated and at day 19, the intrathoracic cyst was removed. The prenatal detection of intrathoracic gastric duplication allows appropriate management at birth. Our patient had to be hospitalized at intensive care unit as long as 50 days before diagnosis has been established. Antenatal detection of the cyst may allow appropriate management at birth, early investigations, and quick removal before the complications occur.<sup>17</sup>

This case emphasizes that clinicians should be aware that duplications cysts can occur anywhere in alimentary tract and should be considered in a child with unusual respiratory and gastrointestinal symptoms. In the presence of thoracic neurenteric cyst, abdominal duplication should be searched. Also, signs of the abnormal vertebra should be forward us to further imaging of vertebrae. Early surgical treatment will prevent complications, which may lead to death when proper treatment is not given.

#### Conflict of Interest

None.

#### References

- Carachi R, Azmy A. Foregut duplications. *Pediatr Surg Int* 2002;18 (5-6):371–374
- Hocking M, Young DG. Duplications of the alimentary tract. *Br J Surg* 1981;68(2):92–96
- Ildstad ST, Tollerud DJ, Weiss RG, Ryan DP, McGowan MA, Martin LW. Duplications of the alimentary tract. Clinical characteristics, preferred treatment, and associated malformations. *Ann Surg* 1988;208(2):184–189
- Thurston SE, Lenn NJ. The association of spinal and gastroesophageal anomalies. Case report and review. *Clin Pediatr (Phila)* 1984; 23(11):652–654
- Rodgers BM, Ghren ED III. Esophagus. In: Oldham KT, Colombani PM, Foglia RP, eds. *Surgery of Infants and Children: Scientific Principles and Practice*. Philadelphia, PA: Lippincott-Raven; 1997: 1005–1020
- Parikh D, Samuel M. Congenital cystic lung lesions: is surgical resection essential? *Pediatr Pulmonol* 2005;40(6):533–537
- Adzick NS, Flake AW, Crombleholme TM. Management of congenital lung lesions. *Semin Pediatr Surg* 2003;12(1):10–16
- Birmole BJ, Kulkarni BK, Vaidya AS, Borwankar SS. Intrathoracic enteric foregut duplication cyst. *J Postgrad Med* 1994;40(4): 228–230
- Burgner DP, Carachi R, Beattie TJ. Foregut duplication cyst presenting as neonatal respiratory distress and haemoptysis. *Thorax* 1994;49(3):287–288
- Snyder ME, Luck SR, Hernandez R, Sherman JO, Raffensperger JG. Diagnostic dilemmas of mediastinal cysts. *J Pediatr Surg* 1985; 20(6):810–815
- Fitch SJ, Tonkin IL, Tonkin AK. Imaging of foregut duplication cysts. *Radiographics* 1986;6(2):189–201
- Geller A, Wang KK, DiMugno EP. Diagnosis of foregut duplication cysts by endoscopic ultrasonography. *Gastroenterology* 1995; 109(3):838–842



- 13 Kim KW, Kim WS, Cheon JE, et al. Complex bronchopulmonary foregut malformation: extralobar pulmonary sequestration associated with a duplication cyst of mixed bronchogenic and oesophageal type. *Pediatr Radiol* 2001;31(4):265–268
- 14 Carachi R, Azmy A. Foregut duplications. *Pediatr Surg Int* 2002;18(5-6):371–374
- 15 Daher P, Karam L, Riachy E. Prenatal diagnosis of an intrathoracic gastric duplication: a case report. *J Pediatr Surg* 2008;43(7):1401–1404
- 16 Chuang MT, Barba FA, Kaneko M, Tierstein AS. Adenocarcinoma arising in an intrathoracic duplication cyst of foregut origin: a case report with review of the literature. *Cancer* 1981;47(7):1887–1890
- 17 Alrabeeh A, Gillis DA, Giacomantonio M, Lau H. Neurenteric cysts—a spectrum. *J Pediatr Surg* 1988;23(8):752–754
- 18 Arora NK, Ganguly S, Mathur P, Ahuja A, Patwari A. Upper gastrointestinal bleeding: etiology and management. *Indian J Pediatr* 2002;69(2):155–168