



Original Article

# Evaluation of time lapse for establishing distal tubal occlusion diagnosis during hysterosalpingography procedure performed by using water soluble contrast media

Serkan Kahyaoglu <sup>a,\*</sup>, Omer Hamid Yumusak <sup>a</sup>, Inci Kahyaoglu <sup>b</sup>, Gokce Naz Kucukbas <sup>a</sup>, Alev Esercan <sup>a</sup>, Yasemin Tasci <sup>a</sup>

<sup>a</sup> Department of Reproductive Endocrinology, Zekai Tahir Burak Women's Health Education and Research Hospital, Ankara, Turkey

<sup>b</sup> Department of Reproductive Endocrinology, Etlik Zubeyde Hanim Women's Health Teaching and Research Hospital, Ankara, Turkey

Received June 27, 2016; accepted September 2, 2016

## Abstract

**Background:** Hysterosalpingography (HSG) is the most frequently used diagnostic measure for simultaneously determining uterine abnormalities and tubal status among subfertile women. Despite several broader advantages such as availability and increased experience, the subjectivity involved during administration of the HSG procedure itself, and necessary imaging review, decreases the reliability and accuracy of HSG. In this study, we evaluated the time intervals between X-ray imaging during HSG procedure to establish the presence of distal tubal occlusion.

**Methods:** Our study evaluated the HSG records of 89 women who underwent diagnostic laparoscopy for infertility work-up. Patients who were diagnosed with distal tubal occlusion upon receiving HSG and patients who demonstrated tubal patency on HSG were included in the study, to compare the time intervals in seconds from the tubal visualization view to the last fluoroscopic X-ray shot during the HSG procedure with tubal patency on diagnostic laparoscopy.

**Results:** A statistically significant correlation regarding tubal patency between HSG procedures and diagnostic laparoscopy chromopertubation procedures was demonstrated. Although nearly statistically significant, the interval in seconds between the first HSG imaging and distal tubal filling was shorter for patients with patent tubes on diagnostic laparoscopy than patients with bilateral tubal occlusion ( $8.4 \pm 31.9$  and  $12.0 \pm 19.7$ , respectively;  $p = 0.057$ ). Time period intervals between the first and the last HSG, and between distal tubal filling to the last HSG of patients with patent tubes on diagnostic laparoscopy and patients with bilateral distal tubal occlusion were found to be statistically similar.

**Conclusion:** Although a trend exists towards shorter time period intervals between the first uterine visualization and distal tubal filling graphy among patients with tubal patency, rather than patients with distal tubal occlusion confirmed by diagnostic laparoscopy, clinically reliable objective time period intervals for finalizing the HSG procedure and proceeding with diagnostic laparoscopy due to distal tubal occlusion diagnosis on HSG could not be detected.

Copyright © 2016, the Chinese Medical Association. Published by Elsevier Taiwan LLC. This is an open access article under the CC BY-NC-ND license (<http://creativecommons.org/licenses/by-nc-nd/4.0/>).

**Keywords:** diagnostic imaging; hysterosalpingography; reliability; tubal patency

## 1. Introduction

Despite the increasing availability of treatment options, infertility remains an important public health issue for almost 15% of couples. Congenital Müllerian abnormalities, fertilization and implantation defects, anovulation, male factor, and tubal occlusion are main etiological factors that are associated with infertility.<sup>1</sup> Uterine cavity abnormalities can be a

Conflicts of interest: The authors declare that they have no conflicts of interest related to the subject matter or materials discussed in this article.

\* Corresponding author. Dr. Serkan Kahyaoglu, Zekai Tahir Burak Women's Health Education and Research Hospital, Reproductive Endocrinology Clinic, Talatpasa Avenue, Hamamonu-Altindag, Ankara, Turkey.

E-mail address: [mdserkankahyaoglu@gmail.com](mailto:mdserkankahyaoglu@gmail.com) (S. Kahyaoglu).

<http://dx.doi.org/10.1016/j.jcma.2016.09.006>

1726-4901/Copyright © 2016, the Chinese Medical Association. Published by Elsevier Taiwan LLC. This is an open access article under the CC BY-NC-ND license (<http://creativecommons.org/licenses/by-nc-nd/4.0/>).

contributing cause of subfertility in 10% of women. Abnormal uterine findings like endometrial polyps, fibroids or intra-uterine adhesions which potentially can interfere with implantation and result in pregnancy loss can be detected using hysterosalpingography (HSG).<sup>2</sup> Among all etiological factors impacting women's infertility, fallopian tube abnormalities account for up to 40% of female subfertility. Thus, during fertility evaluations, assessment of tubal patency has priority. HSG is the most commonly utilized first-line diagnostic test for evaluation of the tubal status. The discriminative feature of HSG as a diagnostic imaging study is its ability to evaluate the morphology and the patency of the fallopian tubes, which normally appear as thin, smooth lines that widen in the ampullary portion. Congenital abnormalities, tubal occlusion due to spasm or infection are tubal abnormalities which can be observed with HSG. An abrupt blockage of contrast media passage with nonopacification of the distal fallopian tube either unilateral or bilateral, and prevention of contrast media from freely spilling into the abdominal cavity by pelvic pathologies, are commonly seen tubal pathologies on HSG examination.<sup>3,4</sup> Intrinsic (ascending salpingitis, including salpingitis isthmica nodosa) and extrinsic (peritonitis, endometriosis, and pelvic surgery) etiological factors can result in tubal damage and functional insufficiency. Serum chlamydia antibody immunoglobulin G titer has been found to be correlated with the severity of tubal damage found in infertile women.<sup>5</sup> In the past, efforts to correct tubal occlusion have generally started with tubal surgery by infertility specialists. The success rates of *in vitro* fertilization-embryo transfer procedures resulted in a decline in tubal surgery attempts for tubal occlusion. When assisted reproduction techniques, particularly *in vitro* fertilization-embryo transfer, are not an option for a woman with tubal occlusion, diagnostic and operative surgery for tubal reconstruction becomes a primary treatment choice. HSG is the primary diagnostic measure to evaluate uterine cavity and tubal passage during a female infertility work-up. Unlike a high specificity rate, the relatively low sensitivity rate of HSG causes unnecessary surgeries for evaluation of tubal patency, which predisposes the women to risks of anesthesia and surgery itself. Increased awareness about the appropriate HSG technique will increase the sensitivity of the procedure and decrease unnecessary surgeries.

HSG is performed by the passage of a radio-opaque dye from the cervical canal into the uterine cavity under fluoroscopic guidance. HSG can be performed using water- or oil-soluble contrast medium (WSCM or OSCM). Potential complications of OSCM use are oil embolism and granulomatous inflammation in the presence of an obstructed or inflamed fallopian tube, despite an increase in spontaneous pregnancy rates following the HSG procedure. When compared with OSCM, superior radiographic images are captured with WSCM utilization during HSG that makes WSCM the preferred medium for an HSG procedure. However, an increased frequency and duration of bleeding after HSG, and higher post HSG miscarriage rates have been linked to WSCM usage during HSG. Technically, a subsequent plain X-ray imaging is undertaken 24 hours following the HSG procedure with OSCM

under fluoroscopic guidance to evaluate tubal patency. This is not an obligation for WSCM usage, because the contrast agent directly spreads to the abdominal cavity through the fallopian tubes, which is easily witnessed on fluoroscopy during the procedure. To the best of our knowledge, during HSG procedures performed by using WSCM, the time period necessary to finalize the procedure and decide tubal patency or distal tubal occlusion based on the passage of contrast media has not been previously determined by investigators. Determination of an "at least" time period for finalizing the HSG procedure with great reliability will decrease unnecessary laparoscopy procedures attributable to false positive HSG results. In this study, we investigated this objective to increase the accuracy and reliability of distal tubal occlusion diagnoses during HSG procedures, which will prevent infertile women from undergoing sham surgeries without any benefit to their future prognosis.

## 2. Methods

HSG examinations of the patients were scheduled within 7 days after cessation of their menstruation to ensure a thin endometrium and to avoid a concurrent pregnancy. A serum human chorionic gonadotropin test was also routinely performed before the HSG procedures, to exclude an early pregnancy. Pregnancy, active vaginal infection, acute pelvic inflammatory disease, and severe allergy against iodine contrast agents were considered as contraindications for the procedure. At our institution, HSG is not performed under intravenous sedation due to the potential risks for aspiration or allergic reaction. An oral nonsteroidal anti-inflammatory drug was appropriately administered to all patients 1 hour before the procedure. Prophylactically, a doxycycline 100 mg pill twice a day was routinely administered to all patients for 1 week, starting 1 hour before the procedure. HSG procedures were performed by the gynecologists with a Cohen catheter (manufactured by Storz, Tuttlingen, Germany) through cannulation of the cervical os. When the catheter was in place, water-soluble noniodinated contrast medium (Omnipaque 300 mg I/mL containing 647 mg iohexol/mL equivalent to 300 mg iodine/mL, GE Healthcare, Carrigtobhill, Ireland) was applied under fluoroscopic control. A single X-ray shot was taken upon visualization of the uterine cavity during injection of the WSCM. A second shot was taken upon visualization of the fallopian tubes under fluoroscopy. The third and further shots were taken based on the spillage of contrast media into the pelvic cavity without any established time restriction to finalize the procedure. The HSG results of the patients were reviewed for the purpose of making a decision whether to proceed with further diagnostic laparoscopy, as indicated by the presence of septated uterus or tubal occlusion views on HSG. The HSG records of women who had undergone diagnostic laparoscopy for infertility work-up were evaluated on the Picture Archiving Communication System (PACS, SarusPACS, Ankara, Turkey) of a tertiary education and research hospital between February 2014 and October 2015. Based on the PACS records, 218 HSG views of the diagnostic laparoscopy patients were detected. Patients who underwent

diagnostic laparoscopy due to a proximal tubal occlusion view on HSG procedures were excluded. Patients who were diagnosed with distal tubal occlusion on HSG and patients who demonstrated tubal patency on HSG were included to the study for comparing the time period intervals in seconds between the tubal visualization view and the last fluoroscopic X-ray shot during the HSG procedure. Patients who were diagnosed with uterine septum on HSG were also included in the study to evaluate the effect of uterine septum on HSG reliability regarding tubal patency. A total of 89 patients were included in the study following these inclusion and exclusion criteria.

The demographic features of the patients were evaluated. The timing information of the X-ray graphies of the HSG procedure were achieved from the PACS images. The time periods between the first HSG graphy, distal tubal filling view graphy, tubal passage view graphy (if any), and the last view graphy were evaluated for purposes of comparison. Only one investigator (S.K.) evaluated the HSG views and diagnostic laparoscopy operation notes regarding chromopertubation with methylene blue dye usage results for precluding inter-observer subjectivity. Statistical analysis was performed as follows: normal distribution of data was evaluated by using the Kolmogorov-Smirnov test. The continuous variables were presented by means  $\pm$  standard deviation and compared by using the independent samples *t* test. The nonparametric variables and data without normal distribution were tested by use of the Mann–Whitney *U* test, and correlation analysis was performed by using Spearman's correlation test. The comparison of categoric values was made by using Fisher's exact test, or the Chi-square test. All *p* values < 0.05 were considered statistically significant.

### 3. Results

A total of 89 patients' HSG views on PACS images and diagnostic laparoscopy operation records were evaluated by the same investigator (SK). Forty-six patients (51.7%) had bilateral distal tubal occlusion and 43 patients (49.3%) had at least one tubal patency upon HSG procedures. All 43 patients

(48.3%) with patent tubes on HSG also had patent tubes during diagnostic laparoscopy. Among 46 patients with non-patent tubes on HSG (51.7%), nine patients (19.6%) were found to exhibit bilateral tubal occlusion during chromopertubation with methylene blue dye usage upon diagnostic laparoscopy ( $p = 0.003$ ). The demographic and clinic characteristics of the study group are demonstrated in Table 1. Time intervals in seconds between HSG views are noted in Table 2, according to the contrast passage course of the WSCM under fluoroscopy during the HSG procedure regarding tubal patency on diagnostic laparoscopy. A statistically significant correlation regarding tubal patency between HSG procedures and diagnostic laparoscopy chromopertubation procedures was demonstrated (Pearson's correlation coefficient *r*, 0.324;  $p = 0.002$ ). Both time period intervals (in seconds) from the first to the last HSG imaging and from the distal tubal filling to the last HSG imaging of patients were found to be statistically similar when compared with patients having patent tubes or bilateral distal tubal occlusion on diagnostic laparoscopy (Table 2). Although close to statistically significant, the time interval (in seconds) between the first HSG imaging and distal tubal filling was shorter for patients with patent tubes on diagnostic laparoscopy than patients with bilateral tubal occlusion ( $8.4 \pm 31.9$  and  $12.0 \pm 19.7$ , respectively;  $p = 0.057$ ). A Receiver Operating Characteristic (ROC) curve analysis was also made for evaluating the relationship of the time interval between the first HSG graphy and distal tubal filling graphy, and tubal patency on diagnostic laparoscopy which virtually demonstrated a positive but statistically insignificant relationship (Fig. 1) [N = 89; Area Under Curve (AUC): 0.67; 95% confidence interval (CI): 0.67e0.86;  $p = 0.09$ ]. Another ROC curve analysis was also made for evaluating the predictive value of the time interval between distal tubal filling graphy and last HSG graphy to estimate tubal patency on diagnostic laparoscopy, and no statistically significant relationship was demonstrated regarding this time interval (N = 89; AUC: 0.54; 95% CI: 0.33–0.75;  $p = 0.65$ ). The ROC curve analysis of the whole study group for the time interval between distal tubal filling

Table 1  
Demographic and clinic characteristics of the study group (N = 89).

Parameter	N	Minimum	Maximum	Mean	Standard deviation
Infertility duration (years)	89	1,0	4,0	2.50	0.79
Age (years)	89	19	44	28.03	5.57
Gravida	89	0	4	0.29	0.66
Parity	89	0	1	0.08	0.27
Body mass index (BMI) (kg/height <sup>2</sup> )	89	17	43	25.63	4.96
Primary infertile	70 (78.7)	NA	NA	NA	NA
Secondary infertile	19 (21.3)	NA	NA	NA	NA
Uterine septum resection (+)	49 (55.1)	NA	NA	NA	NA
Uterine septum resection (–)	40 (44.)	NA	NA	NA	NA
Diagnostic laparoscopy result					
Bilateral tubal patency	72 (80.9)	NA	NA	NA	NA
Bilateral tubal occlusion	9 (10.1)				
Unilateral tubal patency	8 (8.9)				

Data are presented as *n* (%).

NA = not applicable.

Table 2  
Patient characteristics and time intervals in seconds between hysterosalpingography (HSG) views according to the contrast passage course of the water-soluble contrast medium (WSCM) under fluoroscopy during HSG procedure regarding tubal patency on diagnostic laparoscopy ( $N = 89$ ).

Parameter	Tubal patency (+) ( $N = 80$ )	Tubal patency (-) ( $N = 9$ )	$p$
Age (years)	$27.9 \pm 5.6$	$28.4 \pm 5.1$	0.91 <sup>b</sup>
BMI (ratio)	$25.2 \pm 4.7$	$29.3 \pm 5.7$	0.02 <sup>a,*</sup>
Infertility duration (years)	$2.5 \pm 0.7$	$2.1 \pm 0.8$	0.10 <sup>a</sup>
Infertility type			
Primary infertile	63 (78.7)	7 (77.8)	0.94 <sup>c</sup>
Secondary infertile	17 (21.3)	2 (22.2)	
Uterine septum surgery			
Uterine septum resection (+)	48 (60)	1 (11.1)	0.005 <sup>c,*</sup>
Uterine septum resection (-)	32 (40)	8 (88.9)	
Time interval between the first HSG graphy and distal tubal filling (seconds)	$8.4 \pm 31.9$	$12.0 \pm 19.7$	0.057 <sup>a</sup>
Time interval between the first HSG graphy and last HSG graphy (seconds)	$68.5 \pm 56.4$	$79.4 \pm 51.5$	0.36 <sup>a</sup>
Time interval between distal tubal filling and last HSG graphy (seconds)	$57.9 \pm 46.9$	$79.6 \pm 68.4$	0.65 <sup>a</sup>
Time interval between distal tubal filling and tubal passage graphy (seconds)	$22.1 \pm 25.4$	NA	NA
Time interval between the first HSG graphy and tubal passage graphy (seconds)	$30.4 \pm 40.2$	NA	NA

Data are presented as  $n$  (%) or mean  $\pm$  standard deviation.

NA = not applicable.

\*  $p < 0.05$ .

<sup>a</sup> Mann–Whitney  $U$  test.

<sup>b</sup> Independent samples  $t$  test.

<sup>c</sup> Pearson Chi-square test.

and the last HSG imaging, and tubal patency on diagnostic laparoscopy did not reveal any statistically significant relationship between these parameters (Fig. 2;  $N = 89$ ; AUC: 0.54; 95% CI: 0.33–0.75;  $p = 0.65$ ). When only patients whose HSG procedures revealed bilateral tubal patency were evaluated for statistical analysis of HSG duration and tubal patency

on diagnostic laparoscopy, total HSG duration was found to be similar between patients with patent and non-patent tubes on diagnostic laparoscopy ( $N = 46$ ; HSG durations:  $85.0 \pm 66.0$  and  $79.4 \pm 51.5$ , respectively;  $p = 0.84$ ). An ROC curve analysis was also made for the same analysis, which did not reveal any significant association ( $N = 46$ ; AUC: 0.47; 95% CI: 0.25–0.69;  $p = 0.84$ ).

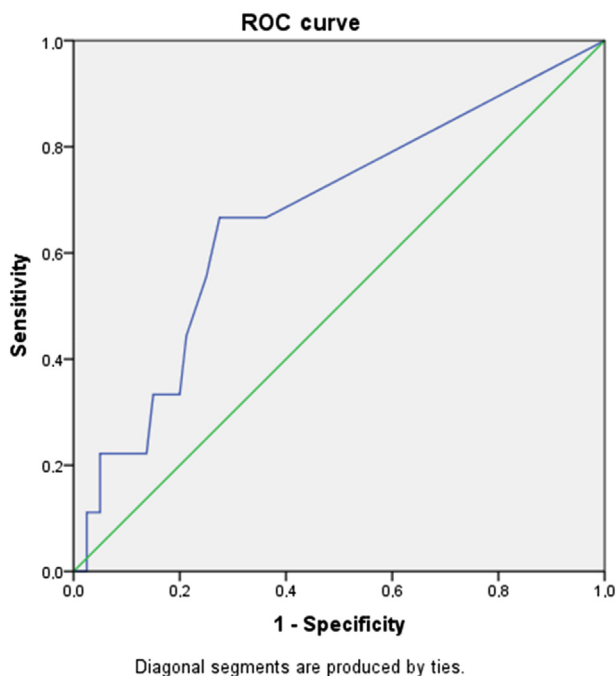


Fig. 1. Receiver Operating Characteristic (ROC) curve analysis of the relationship between the time lapse in seconds from the first hysterosalpingography (HSG) graphy to distal tubal filling graphy and tubal patency on diagnostic laparoscopy which virtually demonstrated a positive but statistically insignificant relationship [ $N = 89$ ; Area Under Curve (AUC): 0.67; 95% confidence interval (CI): 0.67–0.86;  $p = 0.09$ ].

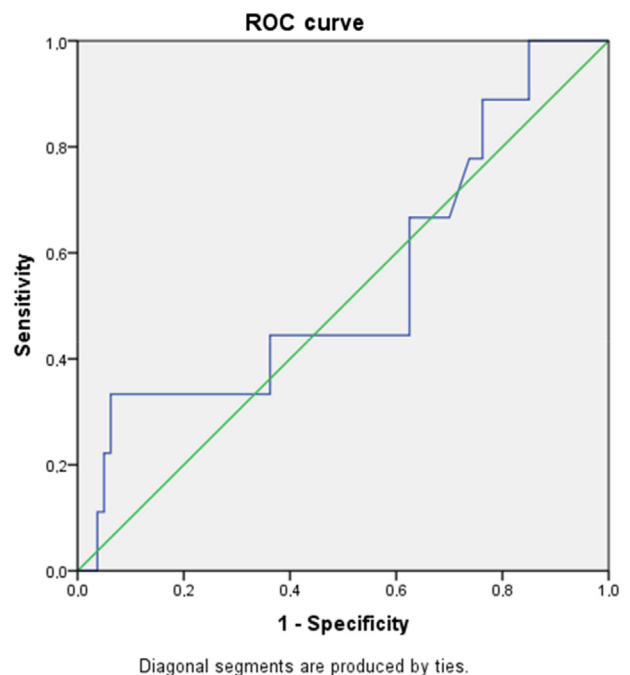


Fig. 2. Receiver Operating Characteristic (ROC) curve analysis of the relationship between the time lapse in seconds from distal tubal filling hysterosalpingography (HSG) graphy to last graphy and tubal patency on diagnostic laparoscopy [ $N = 89$ ; Area Under Curve (AUC): 0.54; 95% confidence interval (CI): 0.33–0.75;  $p = 0.65$ ].

#### 4. Discussion

Due to its wide availability and postprocedure spontaneous pregnancy inducing effect, HSG remains a frequently used tool to evaluate tubal patency during infertility work-up of women. Although hysterosalpingo-contrast-sonography (HyCoSy) is another noninvasive alternative diagnostic modality for evaluation of tubal patency, clinical experience and skills for performing this procedure are lacking for most infertility specialists. High false positive rates for proximal tubal occlusion, most likely because of spasms, delineates the importance of delayed imaging after injection of antiperistaltic agents.<sup>6</sup> HSG has recently been performed by using OSCM because of the improved implantation and pregnancy rates following utilization of oil-based contrast media. Although studies have demonstrated the spontaneous pregnancy enhancing effect of OSCM, the pathophysiological mechanism underlying this positive effect of OSCM has not been previously proven. Oil embolism and granulomatous inflammation in the presence of obstructed or inflamed fallopian tubes are two potential complications of OSCM utilization during HSG procedures. These risks have resulted with the increased usage of WSCM for this relatively frequent diagnostic procedure. However, technical differences between WSCM and OSCM utilization during HSG procedures do exist, which should be kept in mind for evaluation of the HSG views. HyCoSy, which has become an important tool for uterine and tubal abnormalities, has a higher sensitivity than HSG (80% vs. 53%) despite having a similar specificity (84% vs. 87%).<sup>7–9</sup> Major drawbacks of HyCoSy are its superior assessment feature of the uterine cavity than the fallopian tubes, and its longer learning curve when compared with HSG. The advantages of HyCoSy to HSG are low cost, less pain, no exposure to radiation, and no anesthesia, which can be bothersome and risky for infertile women. A review article published by Panchal and Nagori<sup>10</sup> mentioned that saline infusion sonography (SIS) has also been proven to be a fairly reliable noninvasive imaging technique for tubal evaluation. Including pulse Doppler and color Doppler to SIS improves its diagnostic accuracy. Unlike SIS, ultrasound wave enhancing contrast media is used during HyCoSy, as contrast media improves the visibility of the tubal lumen. Due to its accuracy and reliability proven by comparison with the laparoscopic chromopertubation dye test, HyCoSy is offered as an alternative to HSG for determining tubal patency and evaluating the uterine cavity in an infertility work-up.<sup>10,11</sup> Saunders et al<sup>12</sup> evaluated the scientific literature on current methods of uterine cavity and tubal patency assessment, and concluded that evidence has been building in support of the HyCoSy procedure as an acceptable screening study for subfertile patients. This is due to the potential advantages of its comprehensive evaluation, methodologically simple, cost-effective, and timely efficient properties when compared with HSG and laparoscopy as alternative diagnostic measures for tubal assessment.<sup>12</sup> They emphasized that an ideal diagnostic imaging technique for tubal assessment should be diagnostically accurate, timely, cost-effective, reliable, and minimally invasive, and recommended HyCoSy as

the optimal technique which enables providers to simultaneously evaluate ovarian reserve and structure, uterine cavity contour and myometrial structure, and tubal architecture and patency. Strandell et al<sup>13</sup> conducted a prospective study evaluating the role of HyCoSy as a screening test for endometrial and tubal pathology at the start of the infertility investigation protocol, involving 103 subfertile women who completed the HyCoSy using Echovist-200 as the contrast media followed by traditional HSG within 1–2 hours. The observed concordance between HyCoSy and HSG procedures for the endometrial cavity was 90%, and for fallopian tube patency it was 72%. Of the 103 participants, 43 also completed laparoscopy with chromopertubation within 3 months of the HyCoSy and HSG procedures. Both HSG and HyCoSy showed a relatively high concordance with laparoscopy, 83% (70/84) and 80% (68/85), respectively.<sup>13</sup> However, the lack of availability and clinical experience of the HyCoSy procedure and previously reported enhanced conception rates following HSG procedures still makes HSG a first line diagnostic imaging technique, especially for tubal patency evaluation, despite its rare but serious complication rates. In a Cochrane review meta-analysis, pregnancy rates (PR) varied from 17% to 23% after using WSCM, and from 24% to 38% after using OSCM, compared with a PR of 8–21% without the HSG procedure. OSCM was found to be associated with significantly higher PRs than WSCM, with an odds ratio of 1.92 (95% CI: 1.6–2.29).<sup>14</sup> Although previous studies report a post HSG serious infection rate of 0.3–1.3%, a 2-year retrospective analysis reported a post HSG infection incidence of 14 out of 464 patients (3.1%).<sup>15</sup> Increased sensitivity and specificity rates of HSG will eventually decrease unnecessary surgeries, so an elevated awareness of clinicians for pitfalls during the performance of a reliable HSG procedure is mandatory. Prevention of false positive proximal tubal occlusion images during HSG is usually done by administration of uterine muscle relaxant medication preceding the procedure. When a clinician has a nonresolving distal tubal occlusion image during HSG performed by using WSCM, the optimal interval time period from visualization of uterine tubes to abdominopelvic spillage for finalizing the procedure to diagnose distal tubal occlusion and proceed with diagnostic laparoscopy remains unresolved by earlier clinical studies. To the best of our knowledge, this is the first study which evaluates HSG technique as a first line diagnostic imaging procedure for tubal patency by calculating the time periods passed during the tubal journey of WSCM. We compared the HSG images of patients who underwent surgery for tubal patency evaluation using the hospital's PACS system. Those patients harboring uterine septum and demonstrating patent tubes based on HSG views were intentionally included in the study, because these patients' surgeries were performed under diagnostic laparoscopy during hysteroscopic septum resection to avoid uterine perforation upon uterine septum resection. These patients' tubal patency situations were confirmed by laparoscopic chromopertubation, and the time intervals during hysterosalpingographic views were retrospectively reviewed to conclude a sufficient duration for deciding tubal patency on HSG procedure. When the patients

were placed into two groups regarding actual tubal patency on diagnostic laparoscopy, we observed a shorter time period interval in seconds between the first HSG imaging and distal tubal filling for patients with patent uterine tubes than patients with distal tubal occlusion (Table 2;  $8.4 \pm 31.9$  seconds vs.  $12.0 \pm 19.70$  seconds, respectively;  $p = 0.57$ ). Although statistically nonsignificant, this association was found to be close to a level of significance and deserves to be investigated through future research. Although shorter time period trends upon HSG procedures were observed for actual patent uterine tubes, the time period interval between the first and the last HSG imaging, and the time period interval between distal tubal filling and the last HSG imaging were found to be similar, and clinical evaluation of these time periods during review of HSG images were determined to be inconclusive. Although statistically insignificant but close to significance, patients with tubal patency exhibited shorter time intervals in seconds between the first HSG and distal tubal filling than patients with bilateral distal tubal occlusion on HSG, which can be proven to be statistically significant in future studies with higher patient numbers. The mean time interval between the first HSG imaging and tubal passage imaging was  $30.4 \pm 40.2$  seconds for patients with tubal patency on diagnostic laparoscopy. Although a low rate of distal tubal occlusion was detected in our study, a relatively high uterine septum rate was detected in patients with tubal patency compared to patients with distal tubal occlusion on diagnostic laparoscopy. This demonstrates that the absence of uterine septum increases the probability of tubal pathology for infertility etiology of the related patients rather than uterine anatomic abnormalities. Technicians performing HSG procedures are subjectively prone to wait for a statistically nonsignificant time period during finalization of the HSG procedure, when they encounter distal tubal occlusion. Ignorance of possible late spillage of WSCM following the finalization of fluoroscopic imaging of the uterine tubes can result in unnecessary surgeries performed for tubal evaluation. Another solution for overcoming this issue can be a late X-ray imaging performed following finalization of the HSG procedure by taking into account rapid absorption of WSCM, which is unlike OSCM. This ideal time period needs to be evaluated in future randomized controlled studies with higher patient numbers to determine a reliable HSG procedure finalizing the time period when distal tubal occlusion ensues upon fluoroscopic images.

In conclusion, despite its several advantages regarding availability and postprocedure conception enhancing effect, HSG currently does not demonstrably appear to be an ideal diagnostic imaging technique for tubal assessment, in that the procedure lacks the necessary accuracy, timeliness, cost-

effectiveness, reliability, and level of minimal invasiveness. Lowering the subjectivity in this assessment by determining objective time period intervals for X-ray shots under fluoroscopy during the performance of an HSG procedure itself will increase the reliability of the reviewing process of HSG images and decrease unnecessary surgeries for tubal assessment.

## References

- Farhi J, Ben-Haroush A. Distribution of causes of infertility in patients attending primary fertility clinics in Israel. *Isr Med Assoc J* 2011;**13**: 51–4.
- Brown SE, Coddington CC, Schnorr J, Toner JP, Gibbons W, Oehninger S. Evaluation of outpatient hysteroscopy, saline infusion hysterosonography, and hysterosalpingography in infertile women: a prospective, randomized study. *Fertil Steril* 2000;**74**:1029–34.
- Simpson Jr WL, Beitia LG, Mester J. Hysterosalpingography: a re-emerging study. *Radiographics* 2006;**26**:419–31.
- Mol BW, Collins JA, Burrows EA, van der Veen F, Bossuyt PM. Comparison of hysterosalpingography and laparoscopy in predicting fertility outcome. *Hum Reprod* 1999;**14**:1237–42.
- Akande V, Turner C, Horner P, Horne A, Pacey A. Impact of Chlamydia trachomatis in the reproductive setting: British Fertility Society Guidelines for practice. *Hum Fertil* 2010;**13**:115–25.
- Schankath AC, Fasching N, Urech-Ruh C, Hohl MK, Kubik-Huch RA. Hysterosalpingography in the workup of female infertility: indications, technique and diagnostic findings. *Insights Imaging* 2012;**3**:475–83.
- Lim CP, Hasafa Z, Bhattacharya S, Maheshwari A. Should a hysterosalpingogram be a first-line investigation to diagnose female tubal subfertility in the modern subfertility workup? *Hum Reprod* 2011;**26**:967–71.
- Broeze KA, Opmeer BC, Van Geloven N, Coppus SF, Collins JA, Den Hartog JE, et al. Are patient characteristics associated with the accuracy of hysterosalpingography in diagnosing tubal pathology? An individual patient data meta-analysis. *Hum Reprod Update* 2011;**17**:293–300.
- Tanawattanacharoen S, Suwajanakorn S, Uerpairojkit B, Boonkasemsanti W, Virutamasen P. Transvaginal hysterosalpingo-contrast sonography (HyCoSy) compared with chromolaparoscopy. *J Obstet Gynaecol Res* 2000;**26**:71–5.
- Panchal S, Nagori C. Imaging techniques for assessment of tubal status. *J Hum Reprod Sci* 2014;**7**:2–12.
- Luciano DE, Exacoustos C, Johns DA, Luciano AA. Can hysterosalpingo-contrast sonography replace hysterosalpingography in confirming tubal blockage after hysteroscopic sterilization and in the evaluation of the uterus and tubes in infertile patients? *Am J Obstet Gynecol* 2011;**204**: 79.e1–5.
- Saunders RD, Shwayder JM, Nakajima ST. Current methods of tubal patency assessment. *Fertil Steril* 2011;**95**:2171–9.
- Strandell A, Bourne T, Bergh C, Granberg S, Asztely M, Thorburn J. The assessment of endometrial pathology and tubal patency: a comparison between the use of ultrasonography and X-ray hysterosalpingography for the investigation of infertility patients. *Ultrasound Obstet Gynecol* 1999;**14**:200–4.
- Luttjeboer F, Harada T, Hughes E, Johnson N, Lilford R, Mol BW. Tubal flushing for subfertility. *Cochrane Database Syst Rev* 2007:CD003718.
- Stumpf PG, March CM. Febrile morbidity following hysterosalpingography: identification of risk factors and recommendations for prophylaxis. *Fertil Steril* 1980;**33**:487–92.