

ESCMID[†] and ECMM[‡] joint clinical guidelines for the diagnosis and management of mucormycosis 2013

O. A. Cornely^{1,†,‡,§}, S. Arikan-Akdagli^{2,†,§}, E. Dannaoui^{3,§}, A. H. Groll^{4,†,‡,§}, K. Lagrou^{5,†,§}, A. Chakrabarti^{6,§}, F. Lanternier^{7,8}, L. Pagano⁹, A. Skiada¹⁰, M. Akova², M. C. Arendrup¹¹, T. Boekhout^{12,13,14}, A. Chowdhary¹⁵, M. Cuenca-Estrella^{16,†,‡}, T. Freiburger^{17,18,†}, J. Guinea^{19,†,‡}, J. Guarro^{20,†}, S. de Hoog^{12,†}, W. Hope^{21,†}, E. Johnson^{22,†}, S. Kathuria¹⁵, M. Lackner^{23,†}, C. Lass-Flörl^{23,†,‡}, O. Lortholary^{7,†,‡}, J. F. Meis^{24,25,†,‡}, J. Meletiadis^{26,†}, P. Muñoz^{19,†}, M. Richardson^{27,28,†,‡}, E. Roilides^{29,†,‡}, A. M. Tortorano^{30,†}, A. J. Ullmann^{31,†,‡}, A. van Diepeningen¹², P. Verweij^{25,32,†,‡} and G. Petrikos^{33,†,‡,§}

1) Department I of Internal Medicine, Clinical Trials Centre Cologne, ZKS Köln, BMBF 01KNI106, Centre for Integrated Oncology CIO KölnBonn, Cologne Excellence Cluster on Cellular Stress Responses in Aging-Associated Diseases (CECAD), University of Cologne, Cologne, Germany, 2) Department of Medical Microbiology, Hacettepe University Medical School, Ankara, Turkey, 3) Laboratoire de Microbiologie, Hôpital Européen, Unité de Parasitologie—Mycologie, Paris, France, 4) Infectious Disease Research Programme, Department of Paediatric Haematology/Oncology, Centre for Bone Marrow Transplantation, University Children's Hospital Münster, Münster, Germany, 5) Clinical Department of Laboratory Medicine, Department of Microbiology and Immunology, KU Leuven, Leuven, Belgium, 6) Department of Medical Microbiology, Postgraduate Institute of Medical Education & Research, Chandigarh, India, 7) Institut Pasteur, Centre National de Référence Mycoses Invasives et Antifongiques, CNRS, Unité de Mycologie Moléculaire, 8) Service des Maladies Infectieuses et Tropicales, Hôpital Necker-Enfants malades, APHP, Centre d'Infectiologie Necker-Pasteur, IHU Imagine, Université Paris Descartes, Paris, France, 9) Dipartimento di Ematologia, Università Cattolica del Sacro Cuore, Roma, Italy, 10) 1st Department of Propaedeutic Medicine, Laikon Hospital, National and Kapodistrian University of Athens, Athens, Greece, 11) Unit of Mycology, Department Microbiology & Infection Control, Statens Serum Institut, Copenhagen, Denmark, 12) CBS Fungal Biodiversity Centre [CBS-KNAW], 13) Department of Internal Medicine and Infectious Diseases, University Medical Centre, Utrecht, the Netherlands, 14) Shanghai Key Laboratory of Molecular Medical Mycology, Institute of Dermatology and Medical Mycology, Changzheng Hospital, Second Military Medical University, Shanghai, China, 15) Department of Medical Mycology, Vallabh Patel Chest Institute, University of Delhi, Delhi, India, 16) Instituto de Salud Carlos III, Centro Nacional de Microbiología, Madrid, Spain, 17) Centre for Cardiovascular Surgery and Transplantation, Molecular Genetics Lab, 18) Molecular Immunology and Microbiology RG, Central European Institute of Technology (CEITEC), Masaryk University, Brno, Czech Republic, 19) Departamento de Medicina, Clinical Microbiology and Infectious Diseases, Hospital General Universitario Gregorio Marañón, Universidad Complutense, Madrid, 20) Unitat de Microbiologia, Facultat de Medicina, IISPV, Universitat Rovira i Virgili, Reus, Spain, 21) Department of Molecular and Clinical Pharmacology, Antimicrobial Pharmacodynamics and Therapeutics, University of Liverpool, Liverpool, 22) PHE South West Laboratory, PHE Mycology Reference Laboratory and National Collection of Pathogenic Fungi, Bristol, UK, 23) Division of Hygiene and Medical Microbiology, Innsbruck Medical University, Innsbruck, Austria, 24) Department of Medical Microbiology and Infectious Diseases, Canisius Wilhelmina Hospital, Nijmegen, the Netherlands, 25) Department of Medical Microbiology, Radboud University Nijmegen Medical Centre, Nijmegen, the Netherlands, 26) Clinical Microbiology Laboratory, 'Attikon' University General Hospital, National and Kapodistrian University of Athens, Haidari, Athens, Greece, 27) Mycology Reference Centre, University Hospital of South Manchester, 28) Manchester Academic Health Science Centre, University of Manchester, Manchester, UK, 29) Infectious Diseases Unit, 3rd Department of Paediatrics, Hipokraton Hospital, Aristotle University School of Medicine, Thessaloniki, Greece, 30) Department of Biomedical Science for Health, Università degli Studi di Milano, Milano, Italy, 31) Department of Internal Medicine II, Julius-Maximilians-University, Würzburg, Germany, 32) Nijmegen Institute for Infection, Inflammation and Immunity, Nijmegen, the Netherlands and 33) 4th Department of Internal Medicine, National and Kapodistrian University of Athens Medical School, University General Hospital 'Attikon', Haidari, Greece

Abstract

These European Society for Clinical Microbiology and Infectious Diseases and European Confederation of Medical Mycology Joint Clinical Guidelines focus on the diagnosis and management of mucormycosis. Only a few of the numerous recommendations can be summarized here. To diagnose mucormycosis, direct microscopy preferably using optical brighteners, histopathology and culture are strongly recommended. Pathogen identification to species level by molecular methods and susceptibility testing are strongly recommended to establish epidemiological knowledge. The recommendation for guiding treatment based on MICs is supported only marginally. Imaging is strongly recommended to determine the extent of disease. To differentiate mucormycosis from aspergillosis in haematological malignancy and stem cell transplantation recipients, identification of the reverse halo sign on computed tomography is advised with moderate strength. For adults and children we strongly recommend surgical debridement in addition to immediate first-line antifungal treatment with liposomal or lipid-complex amphotericin B with a minimum dose of 5 mg/kg/day. Amphotericin B deoxycholate is better avoided because of severe adverse effects. For salvage treatment we strongly recommend posaconazole 4 × 200 mg/day. Reversal of predisposing conditions is strongly recommended, i.e. using granulocyte colony-stimulating factor in haematological patients with ongoing neutropenia, controlling hyperglycaemia and ketoacidosis in diabetic patients, and limiting glucocorticosteroids to the minimum dose required. We recommend against using deferasirox in haematological patients outside clinical trials, and marginally support a recommendation for deferasirox in diabetic patients. Hyperbaric oxygen is supported with marginal strength only. Finally, we strongly recommend continuing treatment until complete response demonstrated on imaging and permanent reversal of predisposing factors.

Keywords: Diagnosis, fungal infection, guideline, mucormycosis, mycosis, prophylaxis, treatment, zygomycosis

Article published online: 30 January 2014

Clin Microbiol Infect 2014; 20 (Suppl. 3): 5–26

Corresponding author: O. A. Cornely, MD, Department I for Internal Medicine, University of Cologne, Kerpener Str. 62, 50937 Cologne, Germany

E-mail: oliver.cornely@ctuc.de

This guideline was presented in part at ECCMID 2013, Berlin, Germany.

[†]European Society for Clinical Microbiology and Infectious Diseases. [‡]European Confederation of Medical Mycology. [§]Members of the subgroup committee mainly responsible for setting up this manuscript.

Introduction

Mucormycosis is a very aggressive invasive fungal disease [1,2]. It is a fungal emergency that affects a variety of patient groups [3]. The disease, previously termed zygomycosis [4], is caused by mucoralean fungi, which have collectively also been called Mucormycetes [5,6]. However, we prefer to use the name of the order, i.e. Mucorales.

The genera causing the majority of mucormycoses are *Rhizopus*, *Mucor*, *Lichtheimia* (previously classified as *Absidia*), *Cunninghamella*, *Rhizomucor*, *Apophysomyces* and *Saksenaia* [7]. Granulocytopenia, immunosuppression, diabetes and penetrating trauma are the most prevalent predisposing diseases associated with mucormycosis [7]. Cavitory pulmonary disease due to *Rhizopus homothallicus* has been described as a distinct pattern in diabetic patients in India [8]. Besides patients with these typical risk factors, mucormycosis has been reported in otherwise healthy individuals in India and China, e.g. in the forms of renal mucormycosis and chronic (sub-)cutaneous infections due to *Mucor irregularis* (*Rhizomucor variabilis*) [8–16]. Recently, the different clinical manifestations have been reviewed [17].

Arnold Paltauf reported the first histologically proven case of *Mycosis mucorina* at the University of Graz, Austria in 1885 [18]. Though the disease has been known for a long time, the epidemiology is not well defined. In a study from France mucormycosis had increasingly been diagnosed over the past years, culminating in a general population incidence of 1.2 per million/year [19]. Two further studies from Spain and California report incidences between 0.4 and 1.7 cases per million population/year [20,21]. In patients with haematological malignancy mucormycosis was less common than invasive aspergillosis, but mucormycosis independently predicted death in these patients [22,23]. Lymphocytopenia has recently been identified as independently predicting death in this setting [24]. Mortality rates in patients with mucormycosis remain high and in recent reports they ranged from 24% to 49% [7,19,25,26].

Guidance for diagnosis and treatment of mucormycosis is needed, because in rare diseases it is difficult to execute comparative clinical trials and to accumulate substantial personal experience. This is particularly true for a disease that is likely to be underdiagnosed and in which individual prognosis is driven by early treatment [2,27]. This guidance document will provide help to improve management of invasive mucormycosis.

Methods

An expert group (OAC, SAA, AC, ED, AHG, KL, FL, LP, GP and AS) was set up by the European Society of Clinical

Microbiology and Infectious Diseases (ESCMID) Fungal Infection Study Group (EFISG) and the European Confederation of Medical Mycology (ECMM) and searched the literature using the search string 'mucormycos* OR zygomycos* NOT entomophthoramycos* NOT phycomycos*'. Documents and views were shared by email, teleconferences and face-to-face meetings during April 2012 to April 2013. Once a structured first consensus was reached the preliminary recommendations were presented to the whole group, i.e. the other authors, discussed, developed further and finalized as a group consensus. The methods to evaluate the quality of evidence and to reach group consensus recommendations are described in the context of the ESCMID clinical guidelines on *Candida* infection [28]. For the present guideline we applied the same system to diagnostic procedures. The definition of the strength of recommendation is given in Table 1. The quality of the published evidence is defined in Table 2(a). To increase transparency regarding the evaluation of available evidence we added an index (Table 2b) to the level II recommendations, where appropriate. Of note, the evaluation of the strength of recommendation and of the quality of evidence was performed in two separate evaluations, so allowing for a recommendation strongly supporting a procedure even if there is a lower level of evidence. If ESCMID EFISG and ECMM marginally support a recommen-

TABLE 1. Definition of the strength of recommendation

Grade	ESCMID EFISG and ECMM
A	Strongly support a recommendation for use
B	Moderately support a recommendation for use
C	Marginally support a recommendation for use
D	Support a recommendation against use

TABLE 2. Definition of the quality of evidence

Level	ESCMID EFISG and ECMM
(a)	
I	Evidence from at least one properly designed randomized, controlled trial
II	Evidence from at least one well-designed clinical trial, without randomization; from cohort or case-control analytic studies (preferably from more than one centre); from multiple time series; or from dramatic results of uncontrolled experiments
III	Evidence from opinions of respected authorities, based on clinical experience, descriptive case studies, or reports of expert committees
Index	ESCMID EFISG and ECMM
(b)	
r	Meta-analysis or systematic review of randomized controlled trials
t	Transferred evidence, i.e. results from different patients' cohorts, or similar immune status situation
h	Comparator group is a historical control
u	Uncontrolled trial
a	Abstract published at an international meeting

dation for use, the respective intervention can be considered optional [28].

Results

Recommendations on diagnostics in mucormycosis

Conventional microbiological methods. Direct microscopy of clinical specimens, preferably using optical brighteners, allows a rapid presumptive diagnosis of mucormycosis. Blankophor and Calcofluor bind to chitin and cellulose and fluoresce in ultraviolet light [29]. Hyphae of Mucorales have a variable width (6–25 µm), are non-septate or pauci-septate and have an irregular, ribbon-like appearance. The angle of branching is variable and includes wide-angle (90°) bifurcations. Culture of specimens is considered an essential investigation. Although the sensitivity of culture is not optimal, it allows identification and susceptibility testing of the isolate in case of growth. Histopathological examination of tissue specimens may allow differentiation between hyphae of *Aspergillus* or morphologically related fungi, and hyphae of Mucorales, which is important for treatment decisions. Mucormycosis is characterized by prominent infarcts, angioinvasion and perineural invasion.

Evidence—The value of fluorescent whiteners for computed tomography (CT) -guided percutaneous lung biopsy specimens was assessed in 61 patients with CT findings highly suggestive of an invasive fungal infection [30]. Calcofluor white staining revealed fungal elements in 49 specimens (80%) and allowed the differentiation between septate ($n = 36$) and non-septate ($n = 13$) hyphae. The DNA of mucoralean fungi was detected by PCR in all samples with non-septate hyphae. Calcofluor white analysis was considered false negative in 5% of specimens [30]. In a patient with acute myelogenous leukaemia and periodontal mucormycosis, intraoperative calcofluor white fluorescence microscopy was used for a prompt diagnosis and to guide the extent of surgical debridement. Maxillary biopsies with intraoperative calcofluor white analysis were used to rule out persistent oral mucormycosis in this case [31].

Mucorales grow well on both non-selective and fungus-selective media and the growth tends to be rapid, i.e. covers the entire plate in a few days. The recovery of Mucorales from tissues may be problematic and negative cultures seem to be correlated with aggressive processing of the specimens before plating. Grinding of specimens should therefore be avoided [32]. The specimen is preferably incubated at 37°C [33–35].

Histopathological review of tissue samples from 20 patients with rhinocerebral disease ($n = 11$), pulmonary disease ($n = 6$), or a fungus ball ($n = 3$) revealed that the inflammatory

responses were predominantly neutrophilic (50%), pyogranulomatous (25%) or absent (20%). Invasive disease was characterized by prominent infarcts (94%), angioinvasion (100%) and prominent perineural invasion (90%) in biopsies that contained nerve structures for evaluation. The presence of septa in the hyphae was rare and hyphal branching angles varied from 45 to 90° [36]. Pulmonary mucormycosis in cancer patients ($n = 20$, 19 patients with haematological malignancy) is characterized by angioinvasion (100%), haemorrhagic infarction (90%), coagulative necrosis (85%) and intra-alveolar haemorrhage (85%). Neutropenic patients had more extensive angioinvasion compared with non-neutropenic patients [37]. In recent registries of mucormycosis, histopathology led to the diagnosis in 63% [26] and 66% [7] of cases. The diagnosis of 75 cases from an Indian tertiary-care hospital was based on histopathology [38].

In a separate report three cases of mucormycosis were diagnosed by immunohistochemistry using monoclonal antibodies against somatic antigens of *Rhizopus oryzae*; two of three had been misclassified as aspergillosis based on histopathology alone [39].

Recommendations—Direct microscopy of clinical specimens preferably using optical brighteners and culture is strongly recommended for the diagnosis of mucormycosis. Histopathology may allow differentiation of mucormycosis from aspergillosis—and other hyalohyphomycoses and phaeohyphomycoses—and is strongly recommended. Notably, scrapings do not reliably prove tissue invasion. Any microscopic examination should evaluate morphology, width, branching angle and septation. Direct microscopy is not useful for species identification, and immunohistochemistry is only marginally supported for the diagnosis of mucormycosis due to the lack of commercially available monoclonal antibodies and clinical validation. For further recommendations refer to Table 3.

Detection of antigen and Mucorales-specific T cells. There are no standardized assays available for the detection of Mucorales-specific antigens. The healthcare provider should have a high level of suspicion that the patient has mucormycosis rather than aspergillosis in patients with CT lesions that are highly suggestive for invasive fungal disease, specifically if *Aspergillus* galactomannan test results on serum and broncho-alveolar lavage are negative [40]. Of note, 1,3-β-D-glucan is a common component of the cell wall of a wide variety of fungi but not of the Mucorales.

Evidence—At two centres with a high autopsy rate, mucormycosis diagnosis was missed using a diagnostic strategy with regular galactomannan testing of serum samples [41,42]. In a study of breakthrough invasive mould infections in patients

TABLE 3. Recommendations on diagnosis of mucormycosis: laboratory diagnosis using conventional, serological and molecular methods

Population	Intention	Method/Finding	SoR	QoE	References	Comment
Any	To diagnose mucormycosis	Direct microscopy preferably using optical brighteners	A	IIu	30,31	Allows rapid presumptive diagnosis; non-septate or pauci-septate, irregular, ribbon-like hyphae, angle of branching 45–90°, identification to genus and species level not possible, hyphal diameter in aspergillosis 2–3 µm, in mucormycosis 6 to >16 µm
Any	To diagnose	Culture	A	IIIr	32,35	Avoid grinding, preferred temperature 37°C
Any	To diagnose	Histopathology	A	IIu	7,26,36–38	Features as in direct microscopy, does not allow for genus or species differentiation; perineural invasion commonly seen, if nerves sampled
Any	To diagnose	Immunohistochemistry	C	IIu	39	No commercial assay available Monoclonal antibodies commercially available
Any	To diagnose	Galactomannan in blood or bronchoalveolar lavage	B	III	41 43 192	$n = 2$ $n = 1$ $n = 2/8$ missed mucormycoses: consider mucormycosis, if galactomannan test negative, but radiology positive
Any	To diagnose	1,3-β-D-glucan in blood	D	III	44,45	Not a reliable marker
Haematological malignancy	To monitor treatment	ELISPOT	C	IIu	46	No commercial assay available
Any	To diagnose	Molecular based tests on fresh clinical material	B	IIu	30,47,193,194	No commercial assay available; fresh material preferred over paraffin-embedded
Any	To diagnose	Molecular based tests on paraffin slides	B	IIu	48,49, 51	No commercial assay available

treated with caspofungin, two cases of mucormycoses occurred among eight patients in whom galactomannan tests remained negative [43].

In vitro analysis of culture supernatants of different species causing mucormycosis ($n = 8$, four different species) revealed a low antigen reactivity compared with other mould isolates, presumably because of their low cell wall 1,3-β-D-glucan concentrations [44]. Three patients with mucormycosis had negative 1,3-β-D-glucan results in a multicentre evaluation of the performance of the 1,3-β-D-glucan test for the diagnosis of invasive fungal infections [45].

Mucorales-specific T cells were detected by an enzyme-linked immunospot (ELISPOT) assay in three haematological patients developing invasive mucormycosis at diagnosis and throughout the entire course of the invasive disease but not for long after resolution of the infection. None of the 25 control patients without mucormycosis had Mucorales-specific T cells [46].

Recommendations—The use of galactomannan detection is moderately supported for the diagnosis of invasive mucormycosis. In patients with a possible invasive fungal infection, negative galactomannan test results in serum and BAL increase the likelihood of invasive mucormycosis. 1,3-β-D-Glucan testing is not recommended for the diagnosis of invasive mucormycosis. For further recommendations refer to Table 3.

Molecular-based methods for direct detection. Evidence—An in-house semi-nested PCR that targets the 18S ribosomal DNA of Mucorales was evaluated on fresh tissue specimens in

two prospective studies [30,47]. In the first study, PCR was performed on 56 respiratory biopsy specimens obtained by different procedures from immunocompromised patients suspected of having a mould infection. The PCR was positive in six samples with histopathological detection of Mucorales hyphae but culture was positive in only two of these samples. One false-positive result was obtained (2% of samples tested) [47]. The second study was conducted on CT-guided percutaneous lung biopsy specimens obtained from 46 patients with a haematological malignancy and 15 patients with solid-organ transplantation. PCR detected mucoralean fungi in all specimens with non-septate hyphae ($n = 13$, sensitivity 100%) whereas culture remained negative in five cases [30].

The performance of the same semi-nested PCR as described above was also evaluated on formalin-fixed paraffin-embedded tissue specimens in two different studies [48,49]. Mucorales PCR was positive in 22 of 27 tissue specimens from patients with a haematological malignancy or a haematopoietic stem cell transplant who were diagnosed with mucormycosis [48] and in 14 of 23 specimens from patients with the diagnosis of mucormycosis based on histopathology [49]. The failure to amplify specific DNA might result from fungal DNA concentrations below detection limits, a focal infection with varying amounts of fungal elements within the tissue or the destruction of DNA during formalin fixation. In four cases no human β-globin DNA could be detected by the control PCR [49]. A recent exercise evaluated a pan-fungal real-time PCR-based technique in formalin-fixed paraffin-embedded tissue specimens [50]. In a total of 89 biopsies from patients with invasive fungal diseases the average

sensitivity of the PCR assay was 89% and Mucorales were detected in 11% of biopsies, although the technique exhibited some limitations to detect *Rhizopus microsporus*, *Rhizopus oryzae* and *Saksenaia vasiformis* [50]. In an interlaboratory evaluation of the reproducibility of an internal transcribed spacer (ITS) PCR performed on formalin-fixed paraffin-embedded tissue specimens from experimentally infected mice, positive results were obtained in 93% of samples with 30 slide cuts of 10 µm. Sensitivity decreased to 27% when tissue quantity was reduced to one section. Interlaboratory reproducibility was excellent [50,51]. Mucorales DNA was detected in 40–60% of plasma samples with real-time PCR as early as one day post-inoculation in a rabbit model of experimental pulmonary mucormycosis [52].

Recommendations—Currently, in the absence of a standardized test, the use of molecular methods on both fresh clinical material and paraffin slides for the diagnosis of mucormycosis is moderately supported. Fresh material is preferred over paraffin-embedded tissue because formalin damages DNA. For further recommendations refer to Table 3.

Genus and species identification. There is no strong evidence that identification to the genus/species level may be important to guide treatment. Identification to the species level is of interest for a better epidemiological knowledge of mucormycosis and may be of value for outbreak investigation. Molecular techniques are more reliable than phenotypic identification of Mucorales in culture to the species level. Sequencing of ITS is currently the best molecular technique for species identification. Carbon assimilation profiles using the commercialized kits ID32C and API 50 CH (bioMérieux, Marcy l'Etoile, France) allowed precise and accurate identification of Mucorales to the species level [53]. Alternative techniques such as matrix-assisted laser desorption/ionization time-of-flight (MALDI-TOF) mass spectrometry are promising but not yet validated for all species.

Evidence—Although some genera, such as *Cunninghamella*, may be associated with a higher mortality rate in patients [3,5] and have been shown to be more virulent in experimental models [54], there is currently sparse evidence that identification of the causative Mucorales to the genus and/or species level could guide the choice of the antifungal treatment [55,56].

In contrast, identification to the species level is of interest for better epidemiological knowledge of the disease. In particular, the clinical picture may be different depending on the species [3,5,57]. Moreover, species identification could be valuable for investigation of healthcare-associated mucormycosis and outbreaks [58].

Identification of Mucorales in culture by standard mycological methods such as morphology is notoriously difficult because the different species share similar morphological characteristics. This has been highlighted by recent molecular description of cryptic species that can hardly be distinguished morphologically [59–62]. Moreover, some species fail to sporulate in standard media, precluding a timely and easy morphological identification [63]. A comparison of morphological versus molecular identification of 19 isolates of Mucorales from patients with mucormycosis showed that identification by morphology was erroneous in >20% of the cases [64]. A high level of concordance (>90%) between morphology and molecular identification may be only seen in reference laboratories [65].

Several DNA targets have been evaluated for a reliable identification to the species level. The best informative target should have a large interspecific (between species) and a low intraspecific (within a given species) sequence variability. Moreover, a comprehensive and accurate database must be available. In a study of 54 isolates from 16 different species it has been shown that ITS sequencing was a reliable and accurate method for identification to the species level [66]. Similar results were obtained by other authors [67,68]. Based on published results and expert opinions, the CLSI has proposed ITS sequencing as a valuable method for identification of genus and also of species [69]. More recently, the International Society for Human and Animal Mycology (ISHAM) working group on fungal molecular identification has recommended using ITS sequencing as a first-line method for species identification of Mucorales [70]. Other DNA targets have also been evaluated including 18S, 28S, cytochrome *b* or FTR I [71–75] and could be used as alternatives but for some of these targets there is less evidence of their usefulness.

Alternative methods for rapid identification of filamentous fungi in clinical microbiology laboratories have been recently evaluated. In particular, using ID32C strips or API 50 CH carbon assimilation strips and 57 Mucorales strains, intraspecies variation was found to be low, whereas large differences were found between genera and species, allowing identification to the species level for all included strains except for *Rhizopus oryzae*. The clustering of isolates based on their carbon assimilation profiles was in accordance with DNA-based phylogeny of Mucorales [53]. MALDI-TOF mass spectrometry may be of interest although limited data are currently available for Mucorales [76–78]. In an analysis of 103 filamentous fungi by MALDI-TOF, the eight tested Mucorales were correctly identified to species level [77]. In a more recent study it was shown that 34 strains of *Lichtheimia* spp. could be reliably identified by comparison to an in-house database constructed

with 19 strains belonging to eight species [78]. Although MALDI-TOF identification of Mucorales seems promising, more data are needed to validate this technique and commercially available databases should be validated.

Recommendations—Identification to the genus and species level is strongly supported for a better epidemiological knowledge of the disease. Guiding treatment by identifying to the genus level is marginally supported. Carbon assimilation is moderately supported and molecular identification is strongly supported in comparison to morphology. The best technique for molecular identification is ITS sequencing. There are currently limited data for MALDI-TOF as an identification method. For further recommendations refer to Table 4.

Susceptibility testing. Evidence—European Committee on Antimicrobial Susceptibility Testing (EUCAST) and CLSI (CLSI M38-A2) [79,80] reference microdilution methods are used as standard assays for antifungal susceptibility testing of Mucorales. Using methods other than the reference assays such as Etest[®] [21,55] or XTT assay [81,82] remains investigational. Except for posaconazole, moderate (<80%) correlation of Etest[®] and Sensititre YeastOne[®] with the CLSI M38-A2 method was noted in antifungal susceptibility testing of Mucorales [21,79]. Rapid (within 6–8 h) susceptibility testing can be achieved with the XTT assay [81]. Currently, there are no validated MIC breakpoints for any of the drugs against fungal genera in this order and so determination of susceptibility categories (S, I and R) is not possible.

A correlation between the generated MIC and clinical outcome was addressed in only a few studies. In a retrospective analysis of 16 patients infected with *Apophysomyces elegans*, an amphotericin B MIC of <1 µg/mL correlated with recovery.

Of those infected with strains with an amphotericin B MIC of ≥1 µg/mL, 43% failed to respond [83]. Animal studies for determination of *in vitro*–*in vivo* correlation are also limited. In murine models of infections due to *Rhizopus microsporus* [84] and *Rhizopus oryzae* [85] posaconazole was shown to be more effective in infections due to strains with an MIC of 0.25 µg/mL compared with those with an MIC of 2 µg/mL. On the other hand, a low minimum fungicidal concentration, i.e. 0.5 µg/mL of posaconazole was associated with response in mice infected with *Rhizopus oryzae*. High posaconazole minimum fungicidal concentration values, i.e. >16 µg/mL, correlated with clinical failure in a similar murine model [82].

Antifungal susceptibility testing of the strains in the order Mucorales has been performed mostly for epidemiological purposes. The data presented in these studies provide significant clues for the expected susceptibility profiles and are useful to evaluate genus-, species- and strain-based variations in susceptibility. Fluconazole [84,86,87], voriconazole [84,86–91], echinocandins [84,87,90,91] and flucytosine [84,87,88,90,91] lack meaningful *in vitro* activity against Mucorales. In general, amphotericin B and posaconazole are the most active drugs *in vitro* [84,86–92]. The comparative activities of amphotericin B and posaconazole may vary depending on the genus and species of the infecting strain. Although amphotericin B yields lower MICs against *Mucor circinelloides* compared with posaconazole [55,92], posaconazole MICs are lower than those of amphotericin B against *Cunninghamella bertholletiae* [92,93]. On the other hand, high MICs of both amphotericin B and posaconazole have been reported for strains of *Cunninghamella echinulata* [93]. Species-specific differences in azole and terbinafine susceptibilities are noted particularly for *Rhizopus* and *Mucor* [84,85,88,90]. Finally, strain-based variations have also been described, as for

TABLE 4. Recommendations on molecular based methods of identification

Population	Intention	Method/Finding	SoR	QoE	Comment	References
Any	To guide treatment	Identification to genus level	C	IIu	Some species may be more virulent and/or associated with higher mortality, e.g. <i>Cunninghamella</i>	3,5,54
Any	To establish epidemiological knowledge and for outbreak investigation	Identification to species level	A	IIu		3,5,25,65
Any	To establish epidemiological knowledge	Molecular identification to species level versus morphology	A	IIu	<i>n</i> = 19; ITS sequencing, concordance 79%, morphology not reliable.	64
Any	To establish epidemiological knowledge	Molecular identification to species level by ITS sequencing	A	IIu	<i>n</i> = 190; ITS sequencing concordance 93%	65
Any	To establish epidemiological knowledge	Molecular identification to species level with other DNA targets	C	IIu	Good discrimination of genera and species, first-line technique	66–70
					28S PCR plus sequencing	71
					18S PCR plus RFLP	72
					28S MicroSeq kit	73
					Cytochrome b gene real-time PCR	74
					FTR1 gene sequencing	75
Any	To establish epidemiological knowledge	Carbon assimilation for species identification	B	II	ID32C and API 50 CH kits allowed precise and accurate identification	66
Any	To establish epidemiological knowledge	MALDI-TOF identification	C	IIu	Limited data, in house databases	77,78

ITS, internal transcribed spacer; MALDI-TOF, matrix-assisted laser desorption/ionization time-of-flight mass spectrometry; QoE, quality of evidence; RFLP, restriction fragment length polymorphism; SoR, strength of recommendation.

posaconazole susceptibility of *Rhizopus oryzae* strains [85,91]. Despite the lack of preference for its use in treatment of mucormycosis, itraconazole MICs are relatively low for a number of strains, including those of *Rhizomucor* [90,92] and *Lichtheimia* [86,88,90,92].

Efficacy of combination therapy was addressed in murine models of mucormycosis. Improved survival was observed with the combination of amphotericin B lipid complex and caspofungin compared with monotherapy and untreated controls in diabetic ketoacidotic mice infected with a more virulent brain isolate of *Rhizopus oryzae*. However, improved organ clearance was not achieved with combination therapy [94]. In a murine model of disseminated mucormycosis caused by *Rhizopus oryzae*, posaconazole combined with amphotericin B at low dose (0.3 mg/kg/day) prolonged survival, and reduced tissue burden was observed compared with monotherapy and controls. However, it was not superior to amphotericin B (0.8 mg/kg/day) alone [95].

In vitro combination studies have also been performed to explore the interaction of antifungal agents against members of the order Mucorales. The previously published reports include data for combinations of amphotericin B and rifampin (69% synergy, 31% indifference), amphotericin B and flucytosine (100% indifference), amphotericin B and terbinafine (80% indifference, 20% synergy), and terbinafine and voriconazole (56% indifference, 44% synergy) for miscellaneous genera of Mucorales ($n = 35$) [96]. Data are also available for combinations of amphotericin B and posaconazole: miscellaneous genera ($n = 21$) with indifference in all strains [91]; *Rhizopus oryzae* ($n = 11$), indifference in all strains [89]. The above combination was more synergistic against hyphae than conidia of miscellaneous genera ($n = 30$) [97]. Further data are available for amphotericin B and anidulafungin (miscellaneous genera, $n = 21$, indifference in 20 and synergy in one strain)

[91], for posaconazole and caspofungin (miscellaneous genera, $n = 12$; synergy in all strains) [98], for posaconazole and anidulafungin (miscellaneous genera, $n = 21$, indifference in all strains) [91], and for itraconazole and terbinafine (miscellaneous genera, $n = 17$; synergy in 14 strains) [99].

Overall, and of major importance, the clinical significance of these and other *in vitro* and *in vivo* combination data remains uncertain [100].

Recommendations—Given the relative lack of clinical break-points and still limited sufficient data to indicate a clear reading correlation between MIC or minimum fungicidal concentration values and clinical outcome, use of antifungal susceptibility testing for guiding treatment in mucormycosis is recommended only with marginal strength. Susceptibility testing for attaining epidemiological data is strongly recommended. For further recommendations refer to Table 5.

Imaging. There are obvious limitations for the differential diagnosis between filamentous fungal infections if no histological or cultural evidence is available. Some imaging characteristics have been evaluated regarding their potential to differentiate between fungal genera.

Evidence—The halo sign, i.e. a ring of ground glass opacity surrounding a nodular infiltrate, and the air crescent sign, are clinical criteria indicating lower respiratory tract fungal disease [101], but they were not predictive of the genus of an invasive fungal pathogen in a historical control study [102].

The reversed halo sign (also known as inverted halo sign or atoll sign) is an area of ground glass opacity surrounded by a ring of consolidation (Fig. 1). In an uncontrolled study on 189 patients treated for proven or probable invasive fungal pneumonia the reversed halo was present in 19% of patients

TABLE 5. Recommendations on susceptibility testing in mucormycosis

Population	Intention	Method/Finding	SoR	QoE	Comment	References
Any	To guide treatment	EUCAST/CLSI reference microdilution methods	C	IIu	Clinical relevance uncertain. No data available to correlate MIC and outcome	79,80,83
Any	To guide treatment	Correlation of MIC with <i>in vivo</i> outcome	C	IIu	For <i>Apophysomyces elegans</i> , limited retrospective data suggest correlation	83
Any	To guide treatment	Correlation of MIC/MFC with <i>in vivo</i> outcome	B	III	Animal, posaconazole better in <i>Rhizopus microsporus</i> and <i>Rhizopus oryzae</i> strains MIC 0.25 µg/mL than in those with MICs 2 µg/mL	82,84,85
Any	To establish epidemiological knowledge	Susceptibility testing	A	IIu	$n = 37$ $n = 36$ $n = 217$ $n = 45$ $n = 77$ $n = 18$, <i>Apophysomyces elegans</i> $n = 21$ $n = 66$ Review	86 88 87 21 92 83 91 90 195
Any	To establish epidemiological knowledge	MIC determined by reference method	A	III	e.g. Etest® not validated for Mucorales	79,80

MFC, minimum fungicidal concentration; QoE, quality of evidence; SoR, strength of recommendation.

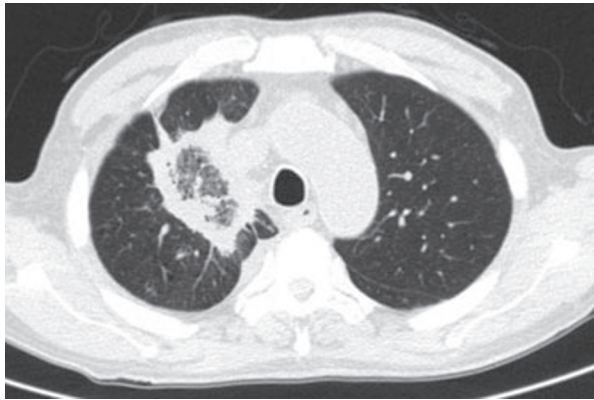


FIG. 1. Computed tomography in mucormycosis revealing a reversed halo sign, also known as inverted halo or atoll sign.

with mucormycosis, in <1% of patients with invasive aspergillosis, and in no patient with fusariosis. The majority of patients with a reversed halo sign had undergone haematopoietic stem cell transplantation for acute myelogenous or chronic lymphatic leukaemia [103]. As a wide range of infectious and non-infectious diseases may present with a reversed halo sign on CT, the diagnostic value of this finding depends on the pre-test probability [104].

Patients with more than ten nodular infiltrates were more likely to have mucormycosis than aspergillosis in one historical control study [102], whereas in a separate patient series this was not the case [104].

If mucormycosis is the suspected diagnosis, histological proof is urgently needed. Computed tomography-guided needle biopsy was successfully applied in 61 patients with possible invasive fungal diseases. Mucormycosis was diagnosed in 13 (21%) [30]. In a separate series of 56 patients with pulmonary nodular infiltrates on CT, biopsy identified proven

mucormycosis in six (11%) [47]. In both series a prerequisite was a minimum platelet count of 50 000/ μ L, which can be achieved by platelet transfusion [30].

Pleural effusion independently predicted mucormycosis in a historical control study ($n = 16$) [102], and was found in all patients of a second, independent series ($n = 18$) [104].

In a population of patients with haematological malignancies ($n = 59$) about 20% of patients had disseminated disease, so that cranial, thoracic and abdominal imaging studies appear warranted [105]. In a historical control study, 31% of mucormycosis patients had sinus involvement [102].

In the 1980s, in two series ($n = 10$, each) of patients with poorly controlled diabetes and mucormycosis cranial CT revealed typical signs of sinusitis and orbital involvement [106,107].

Sinusitis was more commonly associated with mucormycosis than with invasive aspergillosis in patients with haematological disease [102]. Mucosal thickening without air/fluid levels was the usual finding in two series comprising ten patients each [106,107].

In case of bone destruction diagnosed on CT, magnetic resonance imaging should be used to reveal the full extent of disease [108,109]. In an institutional series of patients with mucormycosis ($n = 27$) approximately half of the patients with sinus involvement showed intracranial spread of disease [110].

Recommendations—In patients with haematological malignancy it is recommended that the possibility of mucormycosis be considered, particularly in the case of a lung infiltrate with a reversed halo sign on CT. If mucormycosis is a potential differential diagnosis, biopsy should be pursued. Once mucormycosis has been proven in a patient with underlying

TABLE 6. Recommendations on diagnosis of mucormycosis: imaging to differentiate between pulmonary mucormycosis and invasive pulmonary aspergillosis

Population	Intention	Method/Finding	SoR	QoE	References
Patients with haematological malignancy	To differentiate mucormycosis from invasive pulmonary aspergillosis	CT/reversed halo	B	IIu	103,104
Patients with haematological malignancy	To differentiate mucormycosis from invasive pulmonary aspergillosis	CT/pleural effusion	C	IIh	102,104
Patients with haematological malignancy	To differentiate mucormycosis from invasive pulmonary aspergillosis	CT/>10 nodular infiltrates	C	IIh	102,104
Patients with haematological malignancy	To determine extent of disease	CT cranial, sinus, thoracic, abdominal	B	III	105
Diabetic with facial pain, sinusitis, proptosis, amaurosis	To diagnose invasive mould disease and to determine extent of disease	Cranial CT/destruction of bone ^a	A	IIu	106–108
As above, but with bone destruction on CT	To determine extent of disease (orbit, cerebral, cavernous sinus thrombosis)	Cranial MRI	A	IIu	109,110
Asia, specifically China and India: No underlying disease, flank pain, fever, haematuria, renal infarct on Doppler ultrasound	To diagnose renal mucormycosis	CT or MRI	A	IIu	9–11
Any	To diagnose mucormycosis	CT-guided biopsy	A	IIu	30,47

CT, computed tomography; MRI, magnetic resonance imaging; QoE, quality of evidence; SoR, strength of recommendation.

^aSame approach for invasive aspergillosis.

malignancy, cranial, thoracic and abdominal imaging studies are recommended to determine the extent of disease. For further recommendations refer to Table 6.

Recommendations on treatment of mucormycosis

Prophylaxis. Evidence—In two well-designed clinical trials evaluating primary antifungal prophylaxis during high-risk periods of immunosuppressed patients, i.e. during long-lasting neutropenia in acute myelogenous leukaemia and during graft-versus-host disease with augmented immunosuppression, the incidence rates of invasive fungal diseases were successfully reduced by posaconazole 200 mg three times daily. Mucormycosis only occurred in the comparator treatment arms of the trials, i.e. fluconazole or itraconazole, but the overall rate was very low [111,112]. The prospective SEIFEM-B 2010 registry on newly diagnosed acute myelogenous leukaemia (n = 515) compared posaconazole with itraconazole prophylaxis and no mucormycosis cases were diagnosed in either group [113]. While fluconazole [114] and voriconazole [115] are not active against mucormycosis, itraconazole may yield some activity, but may be inferior to posaconazole [116].

In immunosuppressed patients with a previous diagnosis of mucormycosis (n = 3) surgery in combination with secondary antifungal prophylaxis successfully prevented recurrence [117]. Another study reported a single case in support of this approach [118].

Recommendations—During periods of graft-versus-host disease with augmented immunosuppression and during outbreak situations posaconazole primary prophylaxis is recommended with marginal support for the specific prevention of mucormycosis. We acknowledge that this is a rather artificial scenario, since prophylaxis of invasive aspergillosis will be given already. In patients with previous mucormycosis, surgical resection and individualized secondary antifungal prophylaxis are strongly supported. The last effective antifungal in the respective individual should be preferred. For further recommendations refer to Table 7.

Fever-driven treatment. Evidence—No clinical trial has been conducted evaluating the timing of fever-driven treatment

directed against mucormycosis. In general, a diagnosis-driven antifungal treatment is preferable [119].

Recommendations—If institutional epidemiology advocates mucormycosis to be part of the antifungal spectrum, refer to drugs and doses used for targeted treatment.

Targeted first-line treatment. Evidence—In the field of mucormycosis no well-designed randomized clinical efficacy trial has been published. In a retrospective study on 30 patients combined with a literature analysis of 225 patients with mucormycosis, surgical debridement of lung involvement was associated with a decrease of mortality from 62% to 11%. Procedures were lobectomy, pneumonectomy or wedge resection and patients with non-disseminated disease were more likely to be treated surgically [120]. Two recent literature reviews documented higher survival rates with a combined modality approach of surgical and medical treatment [3,121]. A large institutional series reinforced the need for a combined therapeutic approach [38] and in posaconazole salvage treatment of mucormycosis the highest cure rates were achieved when surgery was part of the strategy [122]. A multivariate analysis from an ECMM case registry [7] and a retrospective analysis of a national case series also found surgery associated with survival [25]. Surgery is of major importance in rhino-orbito-cerebral locations, as evidenced in a retrospective study, where the impact of local control on survival was striking [123].

In an uncontrolled study in patients with haematological malignancy the 12-week mortality rate increased two-fold with medical treatment deferred for 6 or more days from onset of symptoms [27].

Murine models suggest that liposomal amphotericin B is more effective than the deoxycholate formulation against mucormycosis [124], and that for liposomal amphotericin B and amphotericin B lipid complex efficacy was dose-dependent [125]. Actually the lipid complex formulation reached higher lung concentrations and better fungal tissue clearance than liposomal amphotericin B [125]. Whereas both formulations had similar efficacy in neutropenic and diabetic ketoacidotic mice, liposomal amphotericin B was more effective in reducing

TABLE 7. Recommendations on prophylaxis of mucormycosis

Population	Intention	Intervention	SoR	QoE	Comment	References
Neutropenic or GvHD patients in an outbreak situation	To prevent	Posaconazole 3 × 200 mg/day	C	III	n = 1/602 n = 1/600 n = 0/353	111 112 113
Neutropenic or GvHD patients in an outbreak situation	To prevent	Fluconazole, itraconazole, voriconazole, any dose	D	II	In vitro	114–116
Immunosuppressed, previous diagnosis of mucormycosis	To prevent recurrence, 'secondary prophylaxis'	Surgical resection and last drug effective in the same patient, same dose as for treatment	A	III	n = 3 n = 1	117 118

GvHD, graft versus host disease; N/A, not applicable; QoE, quality of evidence; SoR, strength of recommendation.

brain fungal burden [126]. In central nervous system disease amphotericin deoxycholate and liposomal amphotericin achieved the highest efficacy in a rabbit model; however, this model evaluated candidiasis [127].

In an uncontrolled retrospective study on patients with haematological malignancy multivariate analysis revealed treatment with liposomal amphotericin B 3 mg/kg/day to be independently associated with cure [105]. An analysis from the ECMM FungiScope™ registry (www.fungiscope.net) demonstrated that liposomal amphotericin B at an average dose of 5 mg/kg/day was associated with increased response and survival rates [26]. The ECMM mucormycosis registry (www.zygomycosis.net) reported that a liposomal amphotericin B median dose of 5 mg/kg/day (range 3–10 mg/kg/day) leads to favourable response rates [7]. In invasive aspergillosis high-dose liposomal amphotericin B (10 mg/kg/day) caused significantly more renal toxicity than the standard dose of 3 mg/kg/day, but proved the general feasibility of high-dose regimens [128]. A subsequent non-comparative clinical trial evaluated the feasibility and efficacy of liposomal amphotericin B 10 mg/kg/day for the initial treatment of mucormycosis [129]. Renal toxicity was frequent (40%), but treatment was feasible in more than half of the patients; at week 12 the response rate was 45% [57].

First-line treatment with amphotericin B lipid complex 5 mg/kg/day has been reported in a very limited number of patients only [7,130]. In conjunction with the evidence from animal models, central nervous system involvement should be excluded if this formulation is to be used [126,127].

In immunocompetent mice amphotericin B prolonged survival, whereas for itraconazole and posaconazole there are heterogeneous effects depending on the fungal species used for infection [131–133]. The ECMM clinical registries reported successful first-line treatment with posaconazole in about 50–60% of patients [7,26]. Split doses of posaconazole yield higher exposure, so that posaconazole 200 mg four times daily is the preferred dosing regimen in mucormycosis treatment [134].

Concomitant treatment with an amphotericin B formulation and caspofungin has been described as successful in a limited number of predominantly diabetic patients with rhinocerebral mucormycosis [135].

Amphotericin B deoxycholate has been used as standard treatment when no alternative was available [3]. When the comparison to liposomal amphotericin B in fever-driven treatment provided objective proof of its substantial toxicity, the deoxycholate formulation was no longer appropriate, although it is still used where resources are a constraint [136,137]. Amphotericin B deoxycholate did not correlate with superior recovery in a multivariate analysis in a haema-

tological malignancy population [105], in a large institutional series with a variety of underlying diseases [38], and most recently in an ECMM registry [7].

Recommendations—In patients with mucormycosis, surgery whenever possible is strongly recommended to be combined with medical treatment. Immediate treatment initiation is strongly supported to increase survival rates. Liposomal amphotericin B is the drug of choice and the dose should be at least 5 mg/kg/day. The use of amphotericin B deoxycholate is discouraged. For further recommendations refer to Table 8.

Salvage treatment. Evidence—Salvage treatment may be necessary because of refractoriness of disease, or because of intolerance towards previous antifungal therapy, or because of a combination of both.

In the posaconazole compassionate use programme, investigators were allowed to switch between two oral suspension dosing regimens, i.e. 200 mg four times daily and 400 mg twice daily. Rates of complete and partial response [138] as well as survival approached 80% in patients with refractory disease and in patients intolerant to previous therapy [122]. A second analysis of a larger population from the same programme described a treatment response rate of 60% (overlap between both articles was 11 patients). An additional 20% of patients achieved stable disease [139,140]. In the ECMM registry on mucormycosis patients the survival rate of patients receiving posaconazole was 72% [7]. A retrospective analysis of 96 published case reports of posaconazole treatment found a 73% complete response rate [141].

Other reports on salvage treatment cover series of smaller patient numbers ($n = 2$ to $n = 323$). Liposomal amphotericin B 5 mg/kg/day has been used in patients intolerant to previous amphotericin B deoxycholate treatment [105]. Amphotericin B lipid complex 5 mg/kg/day was given in some patients with refractory disease [130,142], in those intolerant to previous therapy or with pre-existing renal disease [130]. In the latter group, use of amphotericin B colloidal dispersion 5 mg/kg/day was also reported [143].

The combination of lipid-based amphotericin B plus caspofungin has been described in a few patients [135]. In models of neutropenic and ketoacidotic mice the combination of liposomal amphotericin B and posaconazole did not improve survival rates or reduce fungal tissue burden [144]. However, in a recent report on 32 patients with mainly haematological diseases, combinations of lipid-based, mostly liposomal, amphotericin B 3–5 mg/kg/day and posaconazole 800 mg/day were analysed [145]. Three months after

TABLE 8. Recommendations on targeted first-line treatment of mucormycosis in adult patients

Population	Intention	Intervention	SoR	QoE	Comment	References
Any	To increase survival rates	Surgical debridement	A	IIu	n = 32 n = 90 n = 45 n = 9 n = 59 n = 92, paediatric	120 3 38 7 25 121
Any	To cure and to increase survival rates	Surgical debridement in addition to antifungal treatment	A	IIu	n = 470 n = 19 n = 90 n = 92, paediatric	3 122 7 121
Immunocompromised	To increase survival rates	Immediate treatment initiation	A	IIu	n = 70	27
Any	To cure and to increase survival rates	Amphotericin B, liposomal ≥ 5 mg/kg ^a	A	IIu	n = 4 n = 16 n = 5 n = 21 n = 28 n = 130 n = 40 Animal model Animal model Animal model Animal model	105 196 128 26 152 7 57 124 125 127 126 130 7 126 127
CNS	To cure	Amphotericin B, liposomal 10 mg/kg, initial 28 days ^a	A	II		125
Any, except CNS	To cure	Amphotericin B, lipid complex 5 mg/kg ^a	B	IIu	n = 10 n = 7 Animal model Animal model	130 7 126 127
Any	To cure	Posaconazole 4 × 200 mg/day or 2 × 400 mg/day ^a	B	IIu	n = 8 n = 17 Animal model	26 7 131
Any	To cure	Lipid-based amphotericin plus caspofungin ^a	C	III	n = 7	135
Any	To cure	Amphotericin B, deoxycholate, any dose ^a	D	I	Renal toxicity n = 9 n = 532 Renal toxicity n = 10 n = 21	137 105 3 136 38 7

CNS, central nervous system; QoE, quality of evidence.
^aTreatment duration is determined on a case-by-case basis and depends, for example, on extent of surgery and organs involved.

initiation of treatment 56% had responded to treatment [145].

Recommendations—For salvage treatment posaconazole 200 mg four times daily is strongly recommended, while lipid-based formulations of amphotericin B and combination of these two compounds are supported with moderate strength. For further recommendations refer to Table 9.

Specific patient settings

Children. Mucormycosis is a life-threatening disease in immunocompromised children and adolescents with haematological malignancies, transplantation, immunosuppressive therapy, diabetes, trauma or burns, and may also occur in premature neonates. Whereas gastrointestinal and cutaneous disease is the most common reported presentation in neonates, older children and adolescents typically present with pulmonary, rhino-orbito-cerebral, cutaneous, and disseminated disease. Overall mortality is 64% in neonates and 42–56% in children. Dissemination and age below one year are independent risk factors for death in children. Similar to adults, surgery combined with antifungal therapy is a factor associated with survival [121,146–149]. Of note, in a large epidemiological study from the USA, the incidence of mucormycosis was stable

over time and no relationship to the increasing use of voriconazole among children was found [150].

Evidence—While the recommendations are similar to those for adults, there are, however, subtle but important differences for paediatric patients. These differences are consistent with paediatric development regulations and guidelines from the European Medicines Agency (EMA) whose concepts have been adopted by the 2012 ESCMID guideline for prevention and management of invasive *Candida* infections in neonates and children [151]. On the basis of this conceptual framework, the group considered four components for grading of therapeutic interventions: (i) evidence for efficacy from adult phase II trials and case series; (ii) existence and quality of paediatric pharmacokinetic data and dosing recommendations; (iii) specific paediatric safety data and supportive efficacy data; and (iv) regulatory approval for use in paediatric age group(s) [151].

Recommendations—Due to the absence of substantially different and/or separate paediatric data, recommendations for diagnosis (patient evaluation, diagnostic methods), principles of management (antifungal therapy, control of the predisposing condition, surgery), adjunctive treatments (granulocyte transfusions, cyto-

TABLE 9. Recommendations on salvage treatment of mucormycosis in adult patients

Population	Intention	Intervention	SoR	QoE	Comment	References
Refractory to prior antifungal therapy	To cure	Posaconazole, oral suspension, 4 × 200 mg/day or 2 × 400 mg/day ^a	A	llu	n = 19 n = 81 ^b n = 61 n = 15 ^c	122 139 7 141
Intolerant to prior antifungal	To cure	Posaconazole, oral suspension, 4 × 200 mg/day or 2 × 400 mg/day ^a	A	llu	n = 5 n = 43 ^b n = 15 ^c	122 139 141
Intolerant to prior antifungal	To cure	Amphotericin B, liposomal, 5 mg/kg	B	llu	n = 8	105
Refractory to prior antifungal therapy	To cure	Amphotericin B, lipid complex, 5 mg/kg	B	llu	n = 16 n = 23	142 130
Intolerant to prior antifungal	To cure	Amphotericin B, lipid complex, 5 mg/kg	B	llu	n = 12	130
Intolerant due to pre-existing renal disease	To cure	Amphotericin B, lipid complex, 5 mg/kg	B	llu	n = 18	130
Intolerant due to pre-existing renal disease	To cure	Amphotericin B colloidal dispersion 5 mg/kg	B	llu	n = 21	143
Refractory disease or intolerant to prior antifungal therapy	To cure	Polyene plus caspofungin	C	lll	n = 2	135
Any	To cure	Polyene plus posaconazole	B	llu	n = 32	145

SoR, strength of recommendation; QoE, quality of evidence.

^aTreatment duration is determined on a case-by-case basis and depends, for example, on extent of surgery and organs involved.

^bThirty-three patients had both refractory disease and intolerance, 11 individuals are part of the Greenberg report, too.

^cThe reason for salvage treatment, i.e. refractoriness versus intolerance, was not reported in this study.

kines, hyperbaric oxygen, deferasirox), and timing/duration of antifungal treatment of paediatric mucormycosis are similar to those outlined for adults and are not recapitulated here.

Prompt initiation of treatment with amphotericin B and consideration of surgery are critical for successful management [121,146,148]. Based on observational data in adults [7,26,130,142,152], paediatric pharmacokinetics [153–155], safety data [148,154,156–159] and the existence of a paediatric label, the choices for first-line treatment in neonates, children and adolescents include amphotericin B lipid complex and liposomal amphotericin B. For pharmacokinetic and pharmacodynamic reasons liposomal amphotericin B is the preferred drug for infections involving the central nervous system [127]. While amphotericin B deoxycholate may have acceptable safety and tolerability profiles in neonates [160], its use is discouraged based on superior outcomes of lipid-amphotericin B in animal models and adults [124,136]. Predominantly due to the lack of clinical efficacy data in adults in this setting, posaconazole [7,26] and the combination of lipid-amphotericin B plus caspofungin [135] are only recommended with marginal strength for first-line therapy of paediatric patients.

Indications for salvage therapy include refractory disease and life-threatening toxicities of lipid amphotericin B; considering the high mortality of mucormycosis, pre-existing kidney dysfunction is not a priori a contraindication for treatment with lipid amphotericin B. Options for salvage therapy of mucormycosis in children ≥ 2 years and adolescents include posaconazole. This recommendation is based on adult efficacy data [122,139] and limited paediatric pharmacokinetic [161,162] and safety data [161–164]. Although no data for mucormycosis exist, demonstrating a trough serum concentration of 0.7–1.0 $\mu\text{g/mL}$ is reasonable to assume exposure on

the basis of treatment data obtained in patients with invasive aspergillosis [165]. Further options for salvage therapy include the combination of lipid amphotericin B plus caspofungin [121,135,166–170], both compounds are approved for all age groups, and the combination of lipid amphotericin B plus posaconazole for children ≥ 2 years of age [95,144]. Of note, posaconazole may also be used for consolidation treatment and as secondary prophylaxis, respectively. For further recommendations on first-line treatment refer to Table 10, and for salvage treatment refer to Table 11.

Haematological malignancy. Evidence—With the intent to cure infection, granulocyte colony-stimulating factor has been applied to shorten neutropenia as the key predisposing factor for mucormycosis in this patient group. The results are difficult to interpret because of the small published patient numbers ($n = 5$ to $n = 18$) [3,105,171–175]. Granulocyte transfusion has been reported in an even more limited number of patients ($n = 7$ to $n = 8$) to cure mucormycosis [3,105,175]. Granulocyte transfusion has been combined with recombinant interferon- γ 1b ($n = 4$) [176].

Recommendations—In patients with neutropenia, granulocyte colony-stimulating factor is strongly recommended. The dose should be chosen as licensed. For further recommendations refer to Table 12.

Solid organ transplant recipients. Evidence—In solid organ transplant recipients use of liposomal amphotericin B has been reported to be associated with increased response rates [25,177–179]. Specifically in pulmonary mucormycosis [177] and in sino-nasal-cerebral disease surgery was associated with

TABLE 10. Recommendations for mucormycosis in paediatric patients: first-line

Population	Intention	Intervention	SoR	QoE	Comment	References
Paediatric Paediatric beyond neonatal period	To cure To cure	Amphotericin B and surgery Amphotericin B, lipid complex 5 mg/kg/day	A A	II II	Paed. Paed. PK Paed. safety Paed. safety Adult Adult	121,146,148 153 156 157 142 155
Paediatric beyond neonatal period	To cure	Amphotericin B, liposomal ≥ 5 mg/kg/day	A	II	Paed. PK Paed. safety Paed, n = 20 Adult Adult	159 148 26 152 7
Paediatric beyond neonatal period and ≥ 2 years old	To cure	Posaconazole 4 \times 200 or 2 \times 400 mg/day; <13 years old: body-weight-based ≤ 34 kg 18-24 mg/kg/day given in 4 divided doses.	C	III	Adult Paed. PK Paed. safety Paed, n = 5 Adult n <17 Adult TDM	161,162,200 163 164 26 7 165
Paediatric patients beyond the neonatal period	To cure	Amphotericin B lipid-based plus caspofungin	C	III	n = 7, adult, 2nd line Paed. PK Paed. PK Paed. safety	135 168 169 170
Neonates, in particular premature neonates	To cure To cure	Amphotericin B, lipid complex 5 mg/kg/day Amphotericin B, liposomal ≥ 5 mg/kg/day	A A	II II	Neo PK Paed safety Paed safety Adult Adult Adult Neo safety Paed safety Paed, n = 20 Adult Adult Adult	154 156 157 142 130 158 159 148 26 152 7
	To cure	Amphotericin B, lipid-based plus caspofungin	C	III	Neo PK Adult, second line	167 135
	To cure	Amphotericin B, deoxycholate 1–1.5 mg/kg/day	D	III	Animal	124
CNS involved	To cure	Amphotericin B, liposomal 5–10 mg/kg/day	A	II	Animal	127

CNS, central nervous system; Neo, neonates; Paed, paediatric; PK, pharmacokinetics; QoE, quality of evidence; SoR, strength of recommendation.

TABLE 11. Recommendations for mucormycosis in paediatric patients: salvage treatment

Population	Intention	Intervention	SoR	QoE	Comment	References
Paediatric beyond neonatal period and ≥ 2 years old	To cure	Posaconazole, 4 \times 200 mg/day or 2 \times 400 mg/day; <13 years old: body-weight-based	A	II	Paed. PK Paed. PK Paed. safety Paed, n = 5 Adult Adult Adult TDM	161 162 163 164 122 139 165
Paediatric including neonates	To cure	Amphotericin B, lipid-based, plus caspofungin	C	III	Adult, n = 7 Animal Neo PK cas, Paed PK cas Paed PKcas Safety cas	135 166 167 168 169 170
Paediatric beyond neonatal period and ≥ 2 years old	To cure	Amphotericin B, lipid-based, plus posaconazole	C	III	Animal Animal	144 95

cas, caspofungin; Neo, neonates; Paed, paediatric; PK, pharmacokinetics; QoE, quality of evidence; SoR, strength of recommendation; TDM, therapeutic drug monitoring.

increased survival rates [179].

Recommendations—In solid organ transplant recipients surgery and liposomal amphotericin B—usually in combination—are strongly recommended. For further recommendations refer to Table 13.

HIV infection and AIDS. Evidence—Mucormycosis may be found in human immunodeficiency virus (HIV)-infected patients; indeed, 2% of all mucormycosis patients in a large literature

review were infected with HIV. However, HIV and AIDS are not considered risk factors specifically for mucormycosis [3].

Recommendations—Recommendations do not differ from other populations described above. In HIV patients drug–drug interactions of protease inhibitors and non-nucleoside reverse transcriptase inhibitors would need to be considered.

Diabetes. Evidence—Control of hyperglycaemia and ketoacidosis was suggested to be a beneficial reversal of a risk factor

for mucormycosis in a review of 145 patients (87 with diabetes) [180], and in two institutional cohorts of 35 and 33 diabetic patients [38,181].

Surgery was associated with improved cure and survival rates in a retrospective analysis of 101 patients with mucormycosis, 23 of these were diabetic patients with a 64% rate of rhinocerebral involvement [25]. Institutional cohorts of diabetic patients found surgery associated with increased survival rates [38,181]. Across these studies *Rhizopus oryzae* was the most frequently identified single pathogen [25,38,180,181].

Recommendations—In uncontrolled diabetes mellitus the control of hyperglycaemia and ketoacidosis is strongly supported. Surgery should be part of the therapeutic approach. For further recommendations refer to Table 14.

Trauma patients. Evidence—Trauma is the third major group of patients with mucormycosis [25]. Natural disaster and accidents are the usual settings [2,182]. In trauma patients mortality rates are lower than in patients with underlying haematological malignancy or diabetes [3,25]. In addition, trauma patients may be more likely to receive surgery and less likely to develop disseminated disease. Although a shorter duration of antifungal treatment may be feasible, a multimodal approach of surgical debridement (until clear margins) and

antifungal treatment should improve response rates and has therefore been advocated [2,7,67,182].

Recommendations—Surgical debridement and antifungal treatment are strongly recommended in trauma patients with mucormycosis (Table 15).

Adjunctive treatments and general management. Iron overload may be a risk factor for mucormycosis [183,184], consequently iron depletion through chelators could be a useful adjunctive treatment.

Evidence—In murine models the iron chelator deferasirox protected from mucormycosis [183] and enhanced the efficacy of liposomal amphotericin B [185]. Furthermore, deferasirox was found to be safe in a phase II study in patients ($n = 8$) with proven mucormycosis [186]. However, when deferasirox was added to liposomal amphotericin B in a small ($n = 20$) prospective, double blind, placebo-controlled trial in haematological patients, the combination treatment group had a higher mortality rate (82% versus 22%) at 90 days [187]. These results are difficult to interpret and may have been caused by imbalanced baseline characteristics between the treatment groups. In any case, it is difficult to prescribe chelators in haematological patients with mucormycosis, although it is unclear whether other patient groups, e.g. diabetic patients

TABLE 12. Recommendations for mucormycosis in haematological malignancy

Population	Intention	Intervention	SoR	QoE	Comment	References
Haematological malignancy with ongoing neutropenia	To cure infection	GCSF, dose not reported	A	IIu	$n = 8$ $n = 12$ $n = 18$ $n = 18$ $n = 5$	171 175 105 3 174
Haematological malignancy with ongoing neutropenia	To cure infection	Granulocyte transfusion	C	IIu	$n = 8$ $n = ?$ $n = 8$	173 105 175
Haematological malignancy with ongoing neutropenia	To cure infection	Granulocyte transfusion plus interferon- γ 1b	C	III	$n = 7$ $n = 4$	3 176

GCSF, granulocyte colony-stimulating factor; QoE, Quality of evidence; SoR, Strength of recommendation.

TABLE 13. Recommendations for mucormycosis in solid organ transplant recipients

Population	Intention	Intervention	SoR	QoE	Comment	References
Solid organ transplantation	To cure	AmB lipid formulation	A	IIh	$n = 25$ $n = 14$, pulmonary	178 177
Solid organ transplantation	To cure	Surgery	A	IIu	$n = 3$ $n = 11$, pulmonary $n = 10$, sinu-nasal-cerebral	25 177 179

QoE, quality of evidence; SoR, strength of recommendation.

TABLE 14. Recommendations for mucormycosis in diabetic patients

Population	Intention	Intervention	SoR	QoE	Comment	References
Uncontrolled diabetes	To cure	Control of hyperglycaemia and ketoacidosis	A	IIu	<i>n</i> = 87 <i>n</i> = 35 <i>n</i> = 33 Review	180 181 38 197
Uncontrolled diabetes with rhinocerebral involvement	To cure and to increase survival	Surgery	A	III	<i>n</i> = 26 <i>n</i> = 14 <i>n</i> = 23 <i>n</i> = 14	181 38 25 123
Uncontrolled diabetes	To cure	GM-CSF 250–425 µg/day	C	III	<i>n</i> = 3, adjunctive to medical and surgical treatment	198

GM-CSF, granulocyte–macrophage colony-stimulating factor; QoE, quality of evidence; SoR, strength of recommendation.

TABLE 15. Recommendations for mucormycosis in trauma patients

Population	Intention	Intervention	SoR	QoE	Comment	References
Trauma	To cure	Surgical debridement and antifungal treatment	A	II	<i>n</i> = 38 <i>n</i> = 5/129 <i>n</i> = 3/8 <i>n</i> = 44/929 <i>n</i> = 39/230 <i>n</i> = 13/13 <i>n</i> = 18/101	182 199 67 3 7 2 25

QoE, quality of evidence; SoR, strength of recommendation.

TABLE 16. Recommendations for adjunctive treatments and general management in mucormycosis

Population	Intention	Intervention	SoR	QoE	Comment	References
Haematological malignancy	To cure	Deferasirox 20 mg/kg/day, days 1–14	D ^a	II	<i>n</i> = 8 <i>n</i> = 20, increased mortality	186 187
Haematological malignancy	To cure	Exposure to 100% hyperbaric oxygen	C	IIIr	<i>n</i> = 3	3,191
Other than haematological malignancy	To cure	Deferasirox, any dose	C	III		No reference found.
Other than haematological malignancy	To cure	Exposure to 100% hyperbaric oxygen	C	IIr	<i>n</i> = 28, primarily patients with improvable risk factors, i.e. diabetes, trauma	3,191
Glucocorticosteroid recipients	To cure	Stop, if feasible, if not: reduce dose of glucocorticosteroids to minimum required	A	IIr		190
Uncontrolled diabetes	To cure	Hyperbaric oxygen	C	IIu	<i>n</i> = 5	107
Any	To cure	Lovastatin	C	III	<i>In vitro</i> animal model	188 189
Any	To cure	Continue treatment until complete response (on imaging) and permanent reversal of immunosuppression are achieved.	A	III	Optimal duration of treatment has not been studied prospectively	No reference found.

QoE, quality of evidence; SoR, strength of recommendation.
^aVotes: C 4, D 9, abstain 3.

with rhinocerebral mucormycosis, are suitable for such treatment. This is one of the rare occasions when the group had to vote on a recommendation (Table 16).

Lovastatin inhibits the *in vitro* growth of *Rhizomucor pusillus* [188]. In a *Drosophila* model lovastatin had activity against *Mucor* sp. and *Rhizopus* sp., and exhibited a synergistic effect when combined with voriconazole, which species in the order Mucorales are intrinsically resistant [189]. It is unknown whether these observations are clinically meaningful.

Glucocorticosteroid treatment is a risk factor for fungal infection and in patients with mucormycosis it should be avoided. If this is not feasible then the dose should be reduced to the minimum required [190].

Hyperbaric oxygen has been reported in small numbers of patients in uncontrolled settings [3]. In a review of 28

published cases treated with adjunctive hyperbaric oxygen mortality was only 6%. Besides small patient numbers, bias in selecting patients suitable for the procedure, publication bias and generally lower survival rates in haematological patients limit the quality of evidence [107,191].

The optimal duration of treatment has not been studied prospectively and is generally unknown. Duration of any of the treatments above is based on individual decision.

Recommendations—In haematological patients with mucormycosis, adjunctive treatment with deferasirox is discouraged, whereas in other patient groups it is recommended with marginal strength. It is strongly recommended to stop glucocorticosteroid treatment in patients with mucormycosis. We strongly recommend continuing antifungal treatment until

complete resolution as demonstrated on imaging and permanent reversal of risk factors is achieved. For further recommendations refer to Table 16.

Acknowledgements

We thank Karen Pankraz for excellent secretarial work and Elizabeth New and Katrin McCloy, Cologne, Germany for rapid and reliable literature retrieval and distribution. ESCMID and ECMM covered travel costs related to face-to-face meetings and for literature retrieval.

Transparency Declarations

OAC is supported by the German Federal Ministry of Research and Education (BMBF 01KN1106), has received research grants from 3M, Actelion, Astellas, Basilea, Bayer, Celgene, Cubist, F2G, Genzyme, Gilead, GSK, Merck/MSD, Miltenyi, Optimer, Pfizer, Quintiles and Viropharma, is a consultant to 3M, Astellas, Basilea, Cubist, F2G, Gilead, GSK, Merck/MSD, Optimer, Pfizer and Sanofi Pasteur, and received lecture honoraria from Astellas, Gilead, Merck/MSD and Pfizer. SAA has received research grants from Pfizer and lecture honoraria from Merck and Pfizer. ArC has no conflict of interest to declare. ED has received research grants from BioRad, Gilead and Pfizer, is a consultant to Astellas and Innothra, received travel support from Merck/Schering, Astellas and Gilead, and received lecture honoraria from Gilead and Merck/Schering. AHG has received research grants from Gilead and Merck Sharp & Dohme, is a consultant to Astellas, Gilead, Merck Sharp & Dohme and Schering-Plough, and received lecture honoraria from Astellas, Gilead, Merck Sharp & Dohme, Schering-Plough and Zeneus/Cephalon. KL has received research grants from Gilead, MSD and Pfizer, has given expert testimony for Merck/Schering and Pfizer, is a consultant to Gilead, Merck/Schering and Pfizer, received travel support from MSD, Pfizer and Gilead and received lecture honoraria from Gilead, Merck/Schering and Pfizer. FL has received research grants from Gilead, received travel support from Gilead, MSD and Schering, and received lecture honoraria from Gilead. LP is a board member of Gilead and Merck is a consultant to Gilead, Merck and Pfizer, and received lecture honoraria from Astellas, Gilead, Merck and Pfizer. AS has received travel support from Merck, Gilead, Astellas and Pfizer. MA has received research grants from Gilead, Merck and Pfizer, is a consultant to Gilead, Merck and Pfizer, has received travel support from Merck, Gilead and Pfizer, and received lecture honoraria from Gilead, Merck and Pfizer.

MCA has received research grants from Astellas, Gilead, Merck/Schering and Pfizer, is a consultant to Merck, Gilead, Pfizer, received travel support from Astellas, Merck/Schering and Pfizer and received lecture honoraria from Astellas, Gilead, Merck/Schering and Pfizer. TB has received royalties from Elsevier and is in part supported by QNRF grant NPRP5-298-3-086. AnC has no conflicts of interest to declare. MCE has received research grants from MSD, Astellas, Pfizer, Gilead and Ferrer, is a consultant to MSD, Astellas, Pfizer, Gilead and Ferrer, has provided expert testimony for MSD, Astellas, Pfizer, Gilead and Ferrer and received lecture honoraria from MSD, Astellas, Pfizer, Gilead and Ferrer. TF is a consultant to Hutman AG. JeG has received research grants from Basilea, BioMerieux, Astellas, Pfizer, Fundacion Mutua Madrilenia, Fondo de Investigacion Sanitaria (FIS), and received lecture honoraria from Astellas, Pfizer, Gilead, MSD and Hickma Pharma. JoG has no conflicts of interest to declare. SdH has no conflicts of interest to declare. WH has received research grants from Pfizer, Astellas, Gilead and F2G, is a consultant to Pfizer, Astellas, Gilead and F2G, and received lecture honoraria from Astellas, Gilead, Merck/Schering and Pfizer. EJ is a consultant to Astellas, Gilead, Merck/Schering and Pfizer, received travel support from Astellas, Merck/Schering and Pfizer, received payment for development of educational presentations from Astellas, Merck/Schering and Pfizer, and received lecture honoraria from Astellas, Gilead, Merck/Schering and Pfizer. SK has no conflicts of interest to declare. ML has no conflicts of interest to declare. CLF has received research grants from Astellas, Gilead, Pfizer, Schering-Plough and MSD, is a consultant to Gilead, MSD, Pfizer and Schering-Plough, received payment for development of educational presentations from Pfizer, received travel support from Gilead, MSD, Pfizer, Astellas and Schering-Plough, and received lecture honoraria from Astellas, Gilead, Merck/Schering and Pfizer. OL is a consultant to Astellas and Gilead, and received lecture honoraria from Astellas, Gilead, Merck/Schering and Pfizer. JFM has received research grants from Astellas, Merck and MSD, is a consultant to Astellas, Basilea, Merck and MSD, received travel support from Astellas, and received lecture honoraria from Merck. JoM has received research grants from Gilead, Merck/Schering and Pfizer, and received lecture honoraria from Gilead, Pfizer and Liofilchem. PM is a consultant to Astellas, Gilead, Merck/Schering and Pfizer, received payment for development of educational presentations from Merck, and received lecture honoraria from Astellas, Gilead, Merck/Schering and Pfizer. MR has received payment for development of educational presentations from Pfizer, received royalties from Blackwell Publishing, received travel support from Astellas, is a consultant to Gilead and MSD, and received lecture honoraria from Astellas and

Pfizer. ER has received research grants from Enzon, Gilead, Pfizer and Schering, is a consultant to Astellas, Gilead, Merck, Pfizer and Schering, and received lecture honoraria from Astellas, Aventis, Cephalon, Gilead, Merck, Pfizer, Schering and Wyeth. AT has received research grants from Astellas and MSD, and received lecture honoraria from Astellas, Gilead and MSD. AJU has received research grants from Astellas, Gilead, Merck/Schering and Pfizer, is a consultant to Astellas, Basilea, Gilead, Merck/Schering and Pfizer, received payment for development of educational presentations from Gilead, and received lecture honoraria from Astellas, Gilead, Merck/Schering and Pfizer. AvD has no conflicts of interest to declare. PV has received research grants from Astellas, Gilead, Merck/Schering and Pfizer, is a consultant to Astellas, Gilead, Merck and Pfizer, received payment for development of educational presentations from Merck and Pfizer, and received lecture honoraria from Astellas, Gilead, Merck/Schering and Pfizer. GP has received research grants from Pfizer, Gilead, AstraZeneca, Novartis, Astellas, GSK, is a consultant to MSD, received travel support from Gilead, Astellas and Pfizer and received lecture honoraria from MSD, and Astellas.

References

- Christopeit M, Lindner A, Surov A et al. Right flank pain and high fever in a neutropenic patient with acute lymphoblastic leukaemia. *Mycoses* 2013; 56: 90–92.
- Neblett Fanfair R, Benedict K, Bos J et al. Necrotizing cutaneous mucormycosis after a tornado in Joplin, Missouri, in 2011. *N Engl J Med* 2012; 367: 2214–2225.
- Roden MM, Zaoutis TE, Buchanan WL et al. Epidemiology and outcome of zygomycosis: a review of 929 reported cases. *Clin Infect Dis* 2005; 41: 634–653.
- Ajello L, Dean DF, Irwin RS. The zygomycete *Saksenaea vasiformis* as a pathogen of humans with a critical review of the etiology of zygomycosis. *Mycologia* 1976; 68: 52–62.
- Gomes MZ, Lewis RE, Kontoyiannis DP. Mucormycosis caused by unusual mucormycetes, non-*Rhizopus*, -*Mucor*, and -*Lichtheimia* species. *Clin Microbiol Rev* 2011; 24: 411–445.
- Kwon-Chung KJ. Taxonomy of fungi causing mucormycosis and entomophthoromycosis (zygomycosis) and nomenclature of the disease: molecular mycologic perspectives. *Clin Infect Dis* 2012; 54 (Suppl. 1): S8–S15.
- Skiada A, Pagano L, Groll A et al. Zygomycosis in Europe: analysis of 230 cases accrued by the registry of the European Confederation of Medical Mycology (ECMM) Working Group on Zygomycosis between 2005 and 2007. *Clin Microbiol Infect* 2011; 17: 1859–1867.
- Chakrabarti A, Marak RS, Shivaprakash MR et al. Cavitary pulmonary zygomycosis caused by *Rhizopus homothallicus*. *J Clin Microbiol* 2010; 48: 1965–1969.
- Chugh KS, Sakhuja V, Gupta KL et al. Renal mucormycosis: computerized tomographic findings and their diagnostic significance. *Am J Kidney Dis* 1993; 22: 393–397.
- Sharma R, Shivanand G, Kumar R et al. Isolated renal mucormycosis: an unusual cause of acute renal infarction in a boy with aplastic anaemia. *Br J Radiol* 2006; 79: e19–e21.
- Marak RS, Misra R, Ansari MS et al. Successful medical management of renal zygomycosis: a summary of two cases and a review of the Indian literature. *Med Mycol* 2010; 48: 1088–1095.
- Hemashettar BM, Patil RN, O'Donnell K, Chaturvedi V, Ren P, Padhye AA. Chronic rhinofacial mucormycosis caused by *Mucor irregularis* (*Rhizomucor variabilis*) in India. *J Clin Microbiol* 2011; 49: 2372–2375.
- Li DM, Lun LD. *Mucor irregularis* infection and lethal midline granuloma: a case report and review of published literature. *Mycopathologia* 2012; 174: 429–439.
- Lu QY, Yu J, Gao LJ, Zheng G, Li RY. [Quantitative real-time polymerase chain reaction for the diagnosis of invasive fungal disease]. *Zhonghua Yi Xue Za Zhi* 2012; 92: 822–826.
- Lu XL, Liu ZH, Shen YN et al. Primary cutaneous zygomycosis caused by *Rhizomucor variabilis*: a new endemic zygomycosis? A case report and review of 6 cases reported from China. *Clin Infect Dis* 2009; 49: e39–e43.
- Xia ZK, Wang WL, Yang RY. Slowly progressive cutaneous, rhinofacial, and pulmonary mucormycosis caused by *Mucor irregularis* in an immunocompetent woman. *Clin Infect Dis* 2013; 56: 993–995.
- Petrikos G, Skiada A, Lortholary O, Roilides E, Walsh TJ, Kontoyiannis DP. Epidemiology and clinical manifestations of mucormycosis. *Clin Infect Dis* 2012; 54 (Suppl. 1): S23–S34.
- Paltauf A. Mycosis mucorina. Ein Beitrag zur Kenntniss der menschlichen Fadenpilzkrankungen. *Archiv für pathologische Anatomie* 1885; 102: 543–564.
- Bitar D, Van Cauteren D, Lanternier F et al. Increasing incidence of zygomycosis (mucormycosis), France, 1997–2006. *Emerg Infect Dis* 2009; 15: 1395–1401.
- Rees JR, Pinner RW, Hajjeh RA, Brandt ME, Reingold AL. The epidemiological features of invasive mycotic infections in the San Francisco Bay area, 1992–1993: results of population-based laboratory active surveillance. *Clin Infect Dis* 1998; 27: 1138–1147.
- Torres-Narbona M, Guinea J, Martinez-Alarcon J, Pelaez T, Bouza E. *In vitro* activities of amphotericin B, caspofungin, itraconazole, posaconazole, and voriconazole against 45 clinical isolates of zygomycetes: comparison of CLSI M38-A, Sensititre YeastOne, and the Etest. *Antimicrob Agents Chemother* 2007; 51: 1126–1129.
- Pagano L, Girmenia C, Mele L et al. Infections caused by filamentous fungi in patients with hematologic malignancies. A report of 391 cases by GIMEMA Infection Program. *Haematologica* 2001; 86: 862–870.
- Lewis RE, Cahyame-Zuniga L, Leventakos K et al. Epidemiology and sites of involvement of invasive fungal infections in patients with haematological malignancies: a 20-year autopsy study. *Mycoses* 2013; 56: 638–645.
- Lewis RE, Georgiadou SP, Sampsonas F, Chamilos G, Kontoyiannis DP. Risk factors for early mortality in haematological malignancy patients with pulmonary mucormycosis. *Mycoses* 2013. doi: 10.1111/myc.12101. [Epub ahead of print].
- Lanternier F, Dannaoui E, Morizot G et al. A global analysis of mucormycosis in France: the RetroZygo Study (2005–2007). *Clin Infect Dis* 2012; 54 (Suppl. 1): S35–S43.
- Rüping MJ, Heinz WJ, Kindo AJ et al. Forty-one recent cases of invasive zygomycosis from a global clinical registry. *J Antimicrob Chemother* 2010; 65: 296–302.
- Chamilos G, Lewis RE, Kontoyiannis DP. Delaying amphotericin B-based frontline therapy significantly increases mortality among patients with hematologic malignancy who have zygomycosis. *Clin Infect Dis* 2008; 47: 503–509.
- Ullmann AJ, Cornely OA, Donnelly JP et al. ESCMID* guideline for the diagnosis and management of *Candida* diseases 2012: developing European guidelines in clinical microbiology and infectious diseases. *Clin Microbiol Infect* 2012; 18 (Suppl. 7): 1–8.
- Hamer EC, Moore CB, Denning DW. Comparison of two fluorescent whiteners, Calcofluor and Blankophor, for the detection of fungal

- elements in clinical specimens in the diagnostic laboratory. *Clin Microbiol Infect* 2006; 12: 181–184.
30. Lass-Flörl C, Resch G, Nachbauer D *et al.* The value of computed tomography-guided percutaneous lung biopsy for diagnosis of invasive fungal infection in immunocompromised patients. *Clin Infect Dis* 2007; 45: e101–e104.
 31. McDermott NE, Barrett J, Hipp J *et al.* Successful treatment of periodontal mucormycosis: report of a case and literature review. *Oral Surg Oral Med Oral Pathol Oral Radiol Endod* 2010; 109: e64–e69.
 32. Ribes JA, Vanover-Sams CL, Baker DJ. Zygomycetes in human disease. *Clin Microbiol Rev* 2000; 13: 236–301.
 33. Larone DH. *Medically important fungi: a guide to identification*. Washington DC: ASM Press, 2011.
 34. Garcia LS. *Clinical microbiology procedures handbook*. Washington DC: ASM Press, 2010.
 35. Kontoyiannis DP, Chamilos G, Hassan SA, Lewis RE, Albert ND, Tarrand JJ. Increased culture recovery of Zygomycetes under physiologic temperature conditions. *Am J Clin Pathol* 2007; 127: 208–212.
 36. Frater JL, Hall GS, Procop GW. Histologic features of zygomycosis: emphasis on perineural invasion and fungal morphology. *Arch Pathol Lab Med* 2001; 125: 375–378.
 37. Ben-Ami R, Luna M, Lewis RE, Walsh TJ, Kontoyiannis DP. A clinicopathological study of pulmonary mucormycosis in cancer patients: extensive angioinvasion but limited inflammatory response. *J Infect* 2009; 59: 134–138.
 38. Chakrabarti A, Chatterjee SS, Das A *et al.* Invasive zygomycosis in India: experience in a tertiary care hospital. *Postgrad Med J* 2009; 85: 573–581.
 39. Jensen HE, Salonen J, Ekfors TO. The use of immunohistochemistry to improve sensitivity and specificity in the diagnosis of systemic mycoses in patients with haematological malignancies. *J Pathol* 1997; 181: 100–105.
 40. Jha AK, Bansal D, Chakrabarti A, Shivaprakash MR, Trehan A, Marwaha RK. Serum galactomannan assay for the diagnosis of invasive aspergillosis in children with haematological malignancies. *Mycoses* 2013; 56: 442–448.
 41. Sinko J, Csomor J, Nikolova R *et al.* Invasive fungal disease in allogeneic hematopoietic stem cell transplant recipients: an autopsy-driven survey. *Transpl Infect Dis* 2008; 10: 106–109.
 42. Maertens J, Glasmacher A, Selleslag D *et al.* Evaluation of serum sandwich enzyme-linked immunosorbent assay for circulating galactomannan during caspofungin therapy: results from the caspofungin invasive aspergillosis study. *Clin Infect Dis* 2005; 41: e9–e14.
 43. Pang KA, Godet C, Fekkar A *et al.* Breakthrough invasive mould infections in patients treated with caspofungin. *J Infect* 2012; 64: 424–429.
 44. Odabasi Z, Paetznick VL, Rodriguez JR, Chen E, McGinnis MR, Ostrosky-Zeichner L. Differences in β -glucan levels in culture supernatants of a variety of fungi. *Med Mycol* 2006; 44: 267–272.
 45. Ostrosky-Zeichner L, Alexander BD, Kett DH *et al.* Multicenter clinical evaluation of the (1 \rightarrow 3) β -D-glucan assay as an aid to diagnosis of fungal infections in humans. *Clin Infect Dis* 2005; 41: 654–659.
 46. Potenza L, Vallerini D, Barozzi P *et al.* Mucorales-specific T cells emerge in the course of invasive mucormycosis and may be used as a surrogate diagnostic marker in high-risk patients. *Blood* 2011; 118: 5416–5419.
 47. Rickerts V, Mousset S, Lambrecht E *et al.* Comparison of histopathological analysis, culture, and polymerase chain reaction assays to detect invasive mold infections from biopsy specimens. *Clin Infect Dis* 2007; 44: 1078–1083.
 48. Hammond SP, Bialek R, Milner DA, Petschnigg EM, Baden LR, Marty FM. Molecular methods to improve diagnosis and identification of mucormycosis. *J Clin Microbiol* 2011; 49: 2151–2153.
 49. Bialek R, Konrad F, Kern J *et al.* PCR based identification and discrimination of agents of mucormycosis and aspergillosis in paraffin wax embedded tissue. *J Clin Pathol* 2005; 58: 1180–1184.
 50. Buitrago MJ, Aguado JM, Ballen A *et al.* Efficacy of DNA amplification in tissue biopsy samples to improve the detection of invasive fungal disease. *Clin Microbiol Infect* 2013; 19: E271–E277.
 51. Dannaoui E, Schwarz P, Slany M *et al.* Molecular detection and identification of zygomycetes species from paraffin-embedded tissues in a murine model of disseminated zygomycosis: a collaborative European Society of Clinical Microbiology and Infectious Diseases (ESCMID) Fungal Infection Study Group (EFISG) evaluation. *J Clin Microbiol* 2010; 48: 2043–2046.
 52. Kasai M, Harrington SM, Francesconi A *et al.* Detection of a molecular biomarker for zygomycetes by quantitative PCR assays of plasma, bronchoalveolar lavage, and lung tissue in a rabbit model of experimental pulmonary zygomycosis. *J Clin Microbiol* 2008; 46: 3690–3702.
 53. Schwarz P, Lortholary O, Dromer F, Dannaoui E. Carbon assimilation profiles as a tool for identification of zygomycetes. *J Clin Microbiol* 2007; 45: 1433–1439.
 54. Petraitis V, Petraitiene R, Antachopoulos C *et al.* Increased virulence of *Cunninghamella bertholletiae* in experimental pulmonary mucormycosis: correlation with circulating molecular biomarkers, sporangiospore germination and hyphal metabolism. *Med Mycol* 2013; 51: 72–82.
 55. Khan ZU, Ahmad S, Brazda A, Chandry R. *Mucor circinelloides* as a cause of invasive maxillofacial zygomycosis: an emerging dimorphic pathogen with reduced susceptibility to posaconazole. *J Clin Microbiol* 2009; 47: 1244–1248.
 56. Salas V, Pastor FJ, Calvo E *et al.* *In vitro* and *in vivo* activities of posaconazole and amphotericin B in a murine invasive infection by *Mucor circinelloides*: poor efficacy of posaconazole. *Antimicrob Agents Chemother* 2012; 56: 2246–2250.
 57. Lanternier F, Poiree S, Elie C *et al.* Pilot prospective study of high dose (10 mg/kg/day) liposomal amphotericin B for the initial treatment of mucormycosis: ‘AMBIZYGO’ Trial (M-1707). 52nd Inter-science Conference on Antimicrobial Agents and Chemotherapy. San Francisco, 2012.
 58. Rammaert B, Lanternier F, Zahar JR *et al.* Healthcare-associated mucormycosis. *Clin Infect Dis* 2012; 54 (Suppl. 1): S44–S54.
 59. Garcia-Hermoso D, Hoinard D, Gantier JC, Grenouillet F, Dromer F, Dannaoui E. Molecular and phenotypic evaluation of *Lichtheimia corymbifera* (formerly *Absidia corymbifera*) complex isolates associated with human mucormycosis: rehabilitation of *L. ramosa*. *J Clin Microbiol* 2009; 47: 3862–3870.
 60. Alastruey-Izquierdo A, Hoffmann K, de Hoog GS *et al.* Species recognition and clinical relevance of the zygomycetous genus *Lichtheimia* (syn. *Absidia pro parte*, *Mycocladius*). *J Clin Microbiol* 2010; 48: 2154–2170.
 61. Alvarez E, Garcia-Hermoso D, Sutton DA *et al.* Molecular phylogeny and proposal of two new species of the emerging pathogenic fungus *Saksenaea*. *J Clin Microbiol* 2010; 48: 4410–4416.
 62. Alvarez E, Stchigel AM, Cano J *et al.* Molecular phylogenetic diversity of the emerging mucoralean fungus *Aphophysomyces*: proposal of three new species. *Rev Iberoam Micol* 2010; 27: 80–89.
 63. Padhye AA, Ajello L. Simple method of inducing sporulation by *Aphophysomyces elegans* and *Saksenaea vasiformis*. *J Clin Microbiol* 1988; 26: 1861–1863.
 64. Kontoyiannis DP, Lionakis MS, Lewis RE *et al.* Zygomycosis in a tertiary-care cancer center in the era of *Aspergillus*-active antifungal therapy: a case-control observational study of 27 recent cases. *J Infect Dis* 2005; 191: 1350–1360.
 65. Alvarez E, Sutton DA, Cano J *et al.* Spectrum of zygomycete species identified in clinically significant specimens in the United States. *J Clin Microbiol* 2009; 47: 1650–1656.

66. Schwarz P, Bretagne S, Gantier JC et al. Molecular identification of Zygomycetes from culture and experimentally infected tissues. *J Clin Microbiol* 2006; 44: 340–349.
67. Chakrabarti A, Ghosh A, Prasad GS et al. *Apophysomyces elegans*: an emerging zygomycete in India. *J Clin Microbiol* 2003; 41: 783–788.
68. Nagao K, Ota T, Tanikawa A et al. Genetic identification and detection of human pathogenic *Rhizopus* species, a major mucormycosis agent, by multiplex PCR based on internal transcribed spacer region of rRNA gene. *J Dermatol Sci* 2005; 39: 23–31.
69. CLSI. *Interpretive criteria for bacteria and fungi identification by DNA target sequencing*; Approved Guideline MM-18A. Wayne, PA: Clinical and Laboratory Standards Institute, 2008.
70. Balajee SA, Borman AM, Brandt ME et al. Sequence-based identification of *Aspergillus*, *Fusarium*, and mucorales species in the clinical mycology laboratory: where are we and where should we go from here? *J Clin Microbiol* 2009; 47: 877–884.
71. Voigt K, Cigelnik E, O'Donnell K. Phylogeny and PCR identification of clinically important Zygomycetes based on nuclear ribosomal-DNA sequence data. *J Clin Microbiol* 1999; 37: 3957–3964.
72. Machouart M, Larche J, Burton K et al. Genetic identification of the main opportunistic mucorales by PCR-restriction fragment length polymorphism. *J Clin Microbiol* 2006; 44: 805–810.
73. Hall L, Wohlfiel S, Roberts GD. Experience with the MicroSeq D2 large-subunit ribosomal DNA sequencing kit for identification of filamentous fungi encountered in the clinical laboratory. *J Clin Microbiol* 2004; 42: 622–626.
74. Hata DJ, Buckwalter SP, Pritt BS, Roberts GD, Wengenack NL. Real-time PCR method for detection of zygomycetes. *J Clin Microbiol* 2008; 46: 2353–2358.
75. Nyilasi I, Papp T, Csernetics A, Krizsan K, Nagy E, Vagvolgyi C. High-affinity iron permease (FTR1) gene sequence-based molecular identification of clinically important Zygomycetes. *Clin Microbiol Infect* 2008; 14: 393–397.
76. Cassagne C, Ranque S, Normand AC et al. Mould routine identification in the clinical laboratory by matrix-assisted laser desorption ionization time-of-flight mass spectrometry. *PLoS ONE* 2011; 6: e28425.
77. De Carolis E, Posteraro B, Lass-Flörl C et al. Species identification of *Aspergillus*, *Fusarium* and Mucorales with direct surface analysis by matrix-assisted laser desorption ionization time-of-flight mass spectrometry. *Clin Microbiol Infect* 2012; 18: 475–484.
78. Schrodh W, Heydel T, Schwartze VU et al. Direct analysis and identification of pathogenic *Lichtheimia* species by matrix-assisted laser desorption ionization-time of flight analyzer-mediated mass spectrometry. *J Clin Microbiol* 2012; 50: 419–427.
79. CLSI. *Reference method for broth dilution antifungal susceptibility testing of filamentous fungi*. CLSI Document M38-A2. Wayne, PA: CLSI, 2008.
80. Rodriguez Tudela JL, Donnelly JP, Arendrup MC et al. EUCAST Technical Note on the method for the determination of broth dilution minimum inhibitory concentrations of antifungal agents for conidia-forming moulds. *Clin Microbiol Infect* 2008; 14: 982–984.
81. Antachopoulos C, Meletiadis J, Roilides E, Sein T, Walsh TJ. Rapid susceptibility testing of medically important zygomycetes by XTT assay. *J Clin Microbiol* 2006; 44: 553–560.
82. Spreghini E, Orlando F, Giannini D, Barchiesi F. *In vitro* and *in vivo* activities of posaconazole against zygomycetes with various degrees of susceptibility. *J Antimicrob Chemother* 2010; 65: 2158–2163.
83. Chakrabarti A, Shivaprakash MR, Curfs-Breuker I, Baghela A, Klaassen CH, Meis JF. *Apophysomyces elegans*: epidemiology, amplified fragment length polymorphism typing, and *in vitro* antifungal susceptibility pattern. *J Clin Microbiol* 2010; 48: 4580–4585.
84. Rodriguez MM, Pastor FJ, Calvo E, Salas V, Sutton DA, Guarro J. Correlation of *in vitro* activity, serum levels, and *in vivo* efficacy of posaconazole against *Rhizopus microsporus* in a murine disseminated infection. *Antimicrob Agents Chemother* 2009; 53: 5022–5025.
85. Rodriguez MM, Pastor FJ, Sutton DA et al. Correlation between *in vitro* activity of posaconazole and *in vivo* efficacy against *Rhizopus oryzae* infection in mice. *Antimicrob Agents Chemother* 2010; 54: 1665–1669.
86. Sun QN, Fothergill AW, McCarthy DI, Rinaldi MG, Graybill JR. *In vitro* activities of posaconazole, itraconazole, voriconazole, amphotericin B, and fluconazole against 37 clinical isolates of zygomycetes. *Antimicrob Agents Chemother* 2002; 46: 1581–1582.
87. Almyroudis NG, Sutton DA, Fothergill AW, Rinaldi MG, Kusne S. *In vitro* susceptibilities of 217 clinical isolates of zygomycetes to conventional and new antifungal agents. *Antimicrob Agents Chemother* 2007; 51: 2587–2590.
88. Dannaoui E, Meletiadis J, Mouton JW, Meis JF, Verweij PE. *In vitro* susceptibilities of zygomycetes to conventional and new antifungals. *J Antimicrob Chemother* 2003; 51: 45–52.
89. Arikan S, Sancak B, Alp S, Hascelik G, McNicholas P. Comparative *in vitro* activities of posaconazole, voriconazole, itraconazole, and amphotericin B against *Aspergillus* and *Rhizopus*, and synergy testing for *Rhizopus*. *Med Mycol* 2008; 46: 567–573.
90. Vitale RG, de Hoog GS, Schwarz P et al. Antifungal susceptibility and phylogeny of opportunistic members of the order Mucorales. *J Clin Microbiol* 2012; 50: 66–75.
91. Drogari-Apiranthitou M, Mantopoulou FD, Skiada A et al. *In vitro* antifungal susceptibility of filamentous fungi causing rare infections: synergy testing of amphotericin B, posaconazole and anidulafungin in pairs. *J Antimicrob Chemother* 2012; 67: 1937–1940.
92. Alastruey-Izquierdo A, Castelli MV, Cuesta I, Monzon A, Cuenca-Estrella M, Rodriguez-Tudela JL. Activity of posaconazole and other antifungal agents against Mucorales strains identified by sequencing of internal transcribed spacers. *Antimicrob Agents Chemother* 2009; 53: 1686–1689.
93. Pastor FJ, Ruiz-Cendoya M, Pujol I, Mayayo E, Sutton DA, Guarro J. *In vitro* and *in vivo* antifungal susceptibilities of the Mucoralean fungus *Cunninghamella*. *Antimicrob Agents Chemother* 2010; 54: 4550–4555.
94. Spellberg B, Fu Y, Edwards JE Jr, Ibrahim AS. Combination therapy with amphotericin B lipid complex and caspofungin acetate of disseminated zygomycosis in diabetic ketoacidotic mice. *Antimicrob Agents Chemother* 2005; 49: 830–832.
95. Rodriguez MM, Serena C, Marine M, Pastor FJ, Guarro J. Posaconazole combined with amphotericin B, an effective therapy for a murine disseminated infection caused by *Rhizopus oryzae*. *Antimicrob Agents Chemother* 2008; 52: 3786–3788.
96. Dannaoui E, Afeltra J, Meis JF, Verweij PE. *In vitro* susceptibilities of zygomycetes to combinations of antimicrobial agents. *Antimicrob Agents Chemother* 2002; 46: 2708–2711.
97. Perkhofor S, Locher M, Cuenca-Estrella M et al. Posaconazole enhances the activity of amphotericin B against hyphae of zygomycetes *in vitro*. *Antimicrob Agents Chemother* 2008; 52: 2636–2638.
98. Guembe M, Guinea J, Pelaez T, Torres-Narbona M, Bouza E. Synergistic effect of posaconazole and caspofungin against clinical zygomycetes. *Antimicrob Agents Chemother* 2007; 51: 3457–3458.
99. Gomez-Lopez A, Cuenca-Estrella M, Mellado E, Rodriguez-Tudela JL. *In vitro* evaluation of combination of terbinafine with itraconazole or amphotericin B against Zygomycota. *Diagn Microbiol Infect Dis* 2003; 45: 199–202.
100. Zhang S, Li R, Yu J. Drug combinations against *Mucor irregularis* *in vitro*. *Antimicrob Agents Chemother* 2013; 57: 3395–3397.
101. de Pauw B, Walsh TJ, Donnelly JP et al. Revised definitions of invasive fungal disease from the European Organization for Research and Treatment of Cancer/Invasive Fungal Infections Cooperative Group and the National Institute of Allergy and Infectious Diseases Mycoses

- Study Group (EORTC/MSG) Consensus Group. *Clin Infect Dis* 2008; 46: 1813–1821.
102. Chamilos G, Marom EM, Lewis RE, Lionakis MS, Kontoyiannis DP. Predictors of pulmonary zygomycosis versus invasive pulmonary aspergillosis in patients with cancer. *Clin Infect Dis* 2005; 41: 60–66.
 103. Wahba H, Truong MT, Lei X, Kontoyiannis DP, Marom EM. Reversed halo sign in invasive pulmonary fungal infections. *Clin Infect Dis* 2008; 46: 1733–1737.
 104. Marchiori E, Zanetti G, Escuissato DL et al. Reversed halo sign: high-resolution CT scan findings in 79 patients. *Chest* 2012; 141: 1260–1266.
 105. Pagano L, Offidani M, Fianchi L et al. Mucormycosis in hematologic patients. *Haematologica* 2004; 89: 207–214.
 106. Centeno RS, Bentson JR, Mancuso AA. CT scanning in rhinocerebral mucormycosis and aspergillosis. *Radiology* 1981; 140: 383–389.
 107. Gamba JL, Woodruff WW, Djang WT, Yeates AE. Craniofacial mucormycosis: assessment with CT. *Radiology* 1986; 160: 207–212.
 108. Herrera DA, Dublin AB, Ormsby EL, Aminpour S, Howell LP. Imaging findings of rhinocerebral mucormycosis. *Skull Base* 2009; 19: 117–125.
 109. Koc Z, Koc F, Yerdelen D, Ozdogu H. Rhino-orbital-cerebral mucormycosis with different cerebral involvements: infarct, hemorrhage, and ophthalmoplegia. *Int J Neurosci* 2007; 117: 1677–1690.
 110. Mohindra S, Mohindra S, Gupta R, Bakshi J, Gupta SK. Rhinocerebral mucormycosis: the disease spectrum in 27 patients. *Mycoses* 2007; 50: 290–296.
 111. Cornely OA, Maertens J, Winston DJ et al. Posaconazole vs. fluconazole or itraconazole prophylaxis in patients with neutropenia. *N Engl J Med* 2007; 356: 348–359.
 112. Ullmann AJ, Lipton JH, Vesole DH et al. Posaconazole or fluconazole for prophylaxis in severe graft-versus-host disease. *N Engl J Med* 2007; 356: 335–347.
 113. Pagano L, Caira M, Candoni A et al. Evaluation of the practice of antifungal prophylaxis use in patients with newly diagnosed acute myeloid leukemia: results from the SEIFEM 2010-B registry. *Clin Infect Dis* 2012; 55: 1515–1521.
 114. Singh J, Rimek D, Kappe R. *In vitro* susceptibility of 15 strains of zygomycetes to nine antifungal agents as determined by the NCCLS M38-A microdilution method. *Mycoses* 2005; 48: 246–250.
 115. Guinea J, Pelaez T, Recio S, Torres-Narbona M, Bouza E. *In vitro* antifungal activities of isavuconazole (BAL4815), voriconazole, and fluconazole against 1,007 isolates of zygomycete, *Candida*, *Aspergillus*, *Fusarium*, and *Scedosporium* species. *Antimicrob Agents Chemother* 2008; 52: 1396–1400.
 116. Rambach G, Oberhauser H, Speth C, Lass-Flörl C. Susceptibility of *Candida* species and various moulds to antimycotic drugs: use of epidemiological cutoff values according to EUCAST and CLSI in an 8-year survey. *Med Mycol* 2011; 49: 856–863.
 117. Nosari A, Ravini M, Cairoli R et al. Surgical resection of persistent pulmonary fungus nodules and secondary prophylaxis are effective in preventing fungal relapse in patients receiving chemotherapy or bone marrow transplantation for leukemia. *Bone Marrow Transplant* 2007; 39: 631–635.
 118. Hoover M, Morgan ER, Kletzel M. Prior fungal infection is not a contraindication to bone marrow transplant in patients with acute leukemia. *Med Pediatr Oncol* 1997; 28: 268–273.
 119. Cornely OA, Bassetti M, Calandra T et al. ESCMID* guideline for the diagnosis and management of *Candida* diseases 2012: non-neutropenic adult patients. *Clin Microbiol Infect* 2012; 18 (Suppl. 7): 19–37.
 120. Tedder M, Spratt JA, Anstadt MP, Hegde SS, Tedder SD, Lowe JE. Pulmonary mucormycosis: results of medical and surgical therapy. *Ann Thorac Surg* 1994; 57: 1044–1050.
 121. Zaoutis TE, Roilides E, Chiou CC et al. Zygomycosis in children: a systematic review and analysis of reported cases. *Pediatr Infect Dis J* 2007; 26: 723–727.
 122. Greenberg RN, Mullane K, van Burik JA et al. Posaconazole as salvage therapy for zygomycosis. *Antimicrob Agents Chemother* 2006; 50: 126–133.
 123. Vironneau P, Verillaud B, Tran H et al. [Rhino-orbital-cerebral mucormycosis, surgical treatment, state of the art]. *Med Sci (Paris)* 2013; 29: 31–35.
 124. Ibrahim AS, Avanesian V, Spellberg B, Edwards JE Jr. Liposomal amphotericin B, and not amphotericin B deoxycholate, improves survival of diabetic mice infected with *Rhizopus oryzae*. *Antimicrob Agents Chemother* 2003; 47: 3343–3344.
 125. Lewis RE, Albert ND, Liao G, Hou J, Prince RA, Kontoyiannis DP. Comparative pharmacodynamics of amphotericin B lipid complex and liposomal amphotericin B in a murine model of pulmonary mucormycosis. *Antimicrob Agents Chemother* 2010; 54: 1298–1304.
 126. Ibrahim AS, Gebremariam T, Husseiny MI et al. Comparison of lipid amphotericin B preparations in treating murine zygomycosis. *Antimicrob Agents Chemother* 2008; 52: 1573–1576.
 127. Groll AH, Giri N, Petraitis V et al. Comparative efficacy and distribution of lipid formulations of amphotericin B in experimental *Candida albicans* infection of the central nervous system. *J Infect Dis* 2000; 182: 274–282.
 128. Cornely OA, Maertens J, Bresnik M et al. Liposomal amphotericin B as initial therapy for invasive mold infection: a randomized trial comparing a high-loading dose regimen with standard dosing (AmBi-Load trial). *Clin Infect Dis* 2007; 44: 1289–1297.
 129. Lanternier F, Lortholary O. AMBIZYGO: Phase II study of high dose liposomal amphotericin B (AmBisome) [10 mg/kg/day] efficacy against zygomycosis. *Med Mal Infect* 2008; 38 (Suppl. 2): S90–S91.
 130. Larkin JA, Montero JA. Efficacy and safety of amphotericin B lipid complex for zygomycosis. *Infect Med* 2003; 20: 201–206.
 131. Dannaoui E, Meis JF, Loebenberg D, Verweij PE. Activity of posaconazole in treatment of experimental disseminated zygomycosis. *Antimicrob Agents Chemother* 2003; 47: 3647–3650.
 132. Salas V, Pastor FJ, Calvo E et al. Experimental murine model of disseminated infection by *Saksenea vasiformis*: successful treatment with posaconazole. *Med Mycol* 2012; 50: 710–715.
 133. Salas V, Pastor FJ, Calvo E et al. Efficacy of posaconazole in a murine model of disseminated infection caused by *Apophysomyces variabilis*. *J Antimicrob Chemother* 2012; 67: 1712–1715.
 134. Ullmann AJ, Cornely OA, Burchardt A et al. Pharmacokinetics, safety, and efficacy of posaconazole in patients with persistent febrile neutropenia or refractory invasive fungal infection. *Antimicrob Agents Chemother* 2006; 50: 658–666.
 135. Reed C, Bryant R, Ibrahim AS et al. Combination polyene-caspofungin treatment of rhino-orbital-cerebral mucormycosis. *Clin Infect Dis* 2008; 47: 364–371.
 136. Ullmann AJ, Sanz MA, Tramarin A et al. Prospective study of amphotericin B formulations in immunocompromised patients in 4 European countries. *Clin Infect Dis* 2006; 43: e29–e38.
 137. Walsh TJ, Finberg RW, Arndt C et al. Liposomal amphotericin B for empirical therapy in patients with persistent fever and neutropenia. National Institute of Allergy and Infectious Diseases Mycoses Study Group. *N Engl J Med* 1999; 340: 764–771.
 138. Segal BH, Herbrecht R, Stevens DA et al. Defining responses to therapy and study outcomes in clinical trials of invasive fungal diseases: Mycoses Study Group and European Organization for Research and Treatment of Cancer consensus criteria. *Clin Infect Dis* 2008; 47: 674–683.
 139. van Burik JA, Hare RS, Solomon HF, Corrado ML, Kontoyiannis DP. Posaconazole is effective as salvage therapy in zygomycosis: a retrospective summary of 91 cases. *Clin Infect Dis* 2006; 42: e61–e65.

140. Cornely OA, Vehreschild JJ, Ruping MJ. Current experience in treating invasive zygomycosis with posaconazole. *Clin Microbiol Infect* 2009; 15 (Suppl. 5): 77–81.
141. Vehreschild JJ, Birtel A, Vehreschild MJ et al. Mucormycosis treated with posaconazole: review of 96 case reports. *Crit Rev Microbiol* 2012; 39: 310–324.
142. Walsh TJ, Hiemenz JW, Seibel NL et al. Amphotericin B lipid complex for invasive fungal infections: analysis of safety and efficacy in 556 cases. *Clin Infect Dis* 1998; 26: 1383–1396.
143. Herbrecht R, Letscher-Bru V, Bowden RA et al. Treatment of 21 cases of invasive mucormycosis with amphotericin B colloidal dispersion. *Eur J Clin Microbiol Infect Dis* 2001; 20: 460–466.
144. Ibrahim AS, Gebremariam T, Schwartz JA, Edwards JE Jr, Spellberg B. Posaconazole mono- or combination therapy for treatment of murine zygomycosis. *Antimicrob Agents Chemother* 2009; 53: 772–775.
145. Pagano L, Cornely O, Busca A et al. Combined antifungal approach for the treatment of invasive mucormycosis in patients with hematological diseases: a report from the SEIFEM and FUNGISCOPE registries. *Haematologica* 2013; 98: e127–e130.
146. Roilides E, Zaoutis TE, Katragkou A, Benjamin DK Jr, Walsh TJ. Zygomycosis in neonates: an uncommon but life-threatening infection. *Am J Perinatol* 2009; 26: 565–573.
147. Dabritz J, Attarbaschi A, Tintelnot K et al. Mucormycosis in paediatric patients: demographics, risk factors and outcome of 12 contemporary cases. *Mycoses* 2011; 54: e785–e788.
148. Dehority W, Willert J, Pong A. Zygomycetes infections in pediatric hematology oncology patients: a case series and review of the literature. *J Pediatr Hematol Oncol* 2009; 31: 911–919.
149. Phulpin-Weibel A, Rivier A, Leblanc T, Bertrand Y, Chastagner P. Focus on invasive mucormycosis in paediatric haematology oncology patients: a series of 11 cases. *Mycoses* 2013; 56: 236–240.
150. Prasad PA, Vaughan AM, Zaoutis TE. Trends in zygomycosis in children. *Mycoses* 2012; 55: 352–356.
151. Hope WW, Castagnola E, Groll AH et al. ESCMID* guideline for the diagnosis and management of *Candida* diseases 2012: prevention and management of invasive infections in neonates and children caused by *Candida* spp. *Clin Microbiol Infect* 2012; 18 (Suppl. 7): 38–52.
152. Shoham S, Magill SS, Merz WG et al. Primary treatment of zygomycosis with liposomal amphotericin B: analysis of 28 cases. *Med Mycol* 2010; 48: 511–517.
153. Walsh TJ, Whitcomb P, Piscitelli S et al. Safety, tolerance, and pharmacokinetics of amphotericin B lipid complex in children with hepatosplenic candidiasis. *Antimicrob Agents Chemother* 1997; 41: 1944–1948.
154. Würthwein G, Groll AH, Hempel G, Adler-Shohet FC, Lieberman JM, Walsh TJ. Population pharmacokinetics of amphotericin B lipid complex in neonates. *Antimicrob Agents Chemother* 2005; 49: 5092–5098.
155. Hong Y, Shaw PJ, Nath CE et al. Population pharmacokinetics of liposomal amphotericin B in pediatric patients with malignant diseases. *Antimicrob Agents Chemother* 2006; 50: 935–942.
156. Walsh TJ, Seibel NL, Arndt C et al. Amphotericin B lipid complex in pediatric patients with invasive fungal infections. *Pediatr Infect Dis J* 1999; 18: 702–708.
157. Wiley JM, Seibel NL, Walsh TJ. Efficacy and safety of amphotericin B lipid complex in 548 children and adolescents with invasive fungal infections. *Pediatr Infect Dis J* 2005; 24: 167–174.
158. Juster-Reicher A, Flidel-Rimon O, Amitay M, Even-Tov S, Shinwell E, Leibovitz E. High-dose liposomal amphotericin B in the therapy of systemic candidiasis in neonates. *Eur J Clin Microbiol Infect Dis* 2003; 22: 603–607.
159. Kolve H, Ahlke E, Fegeler W, Ritter J, Jurgens H, Groll AH. Safety, tolerance and outcome of treatment with liposomal amphotericin B in paediatric patients with cancer or undergoing haematopoietic stem cell transplantation. *J Antimicrob Chemother* 2009; 64: 383–387.
160. Chiou CC, Walsh TJ, Groll AH. Clinical pharmacology of antifungal agents in pediatric patients. *Expert Opin Pharmacother* 2007; 8: 2465–2489.
161. Krishna G, Sansone-Parsons A, Martinho M, Kantesaria B, Pedicone L. Posaconazole plasma concentrations in juvenile patients with invasive fungal infection. *Antimicrob Agents Chemother* 2007; 51: 812–818.
162. Welzen ME, Bruggemann RJ, Van Den Berg JM et al. A twice daily posaconazole dosing algorithm for children with chronic granulomatous disease. *Pediatr Infect Dis J* 2011; 30: 794–797.
163. Döring M, Müller C, Johann PD et al. Analysis of posaconazole as oral antifungal prophylaxis in pediatric patients under 12 years of age following allogeneic stem cell transplantation. *BMC Infect Dis* 2012; 12: 263.
164. Lehrnbecher T, Attarbaschi A, Duerken M et al. Posaconazole salvage treatment in paediatric patients: a multicentre survey. *Eur J Clin Microbiol Infect Dis* 2010; 29: 1043–1045.
165. Walsh TJ, Raad I, Patterson TF et al. Treatment of invasive aspergillosis with posaconazole in patients who are refractory to or intolerant of conventional therapy: an externally controlled trial. *Clin Infect Dis* 2007; 44: 2–12.
166. Ibrahim AS, Gebremariam T, Fu Y, Edwards JE Jr, Spellberg B. Combination echinocandin-polyene treatment of murine mucormycosis. *Antimicrob Agents Chemother* 2008; 52: 1556–1558.
167. Sáez-Llorens X, Macias M, Maiya P et al. Pharmacokinetics and safety of caspofungin in neonates and infants less than 3 months of age. *Antimicrob Agents Chemother* 2009; 53: 869–875.
168. Walsh TJ, Adamson PC, Seibel NL et al. Pharmacokinetics, safety, and tolerability of caspofungin in children and adolescents. *Antimicrob Agents Chemother* 2005; 49: 4536–4545.
169. Neely M, Jafri HS, Seibel N et al. Pharmacokinetics and safety of caspofungin in older infants and toddlers. *Antimicrob Agents Chemother* 2009; 53: 1450–1456.
170. Zaoutis T, Lehrnbecher T, Groll AH et al. Safety experience with caspofungin in pediatric patients. *Pediatr Infect Dis J* 2009; 28: 1132–1135.
171. Pagano L, Ricci P, Tonso A et al. Mucormycosis in patients with haematological malignancies: a retrospective clinical study of 37 cases. GIMEMA Infection Program (Gruppo Italiano Malattie Ematologiche Maligne dell'Adulto). *Br J Haematol* 1997; 99: 331–336.
172. Kontoyiannis DP. Decrease in the number of reported cases of zygomycosis among patients with diabetes mellitus: a hypothesis. *Clin Infect Dis* 2007; 44: 1089–1090.
173. Pagano L, Valentini CG, Posteraro B et al. Zygomycosis in Italy: a survey of FIMUA-ECMM (Federazione Italiana di Micopatologia Umana ed Animale and European Confederation of Medical Mycology). *J Chemother* 2009; 21: 322–329.
174. Kara IO, Tasova Y, Uguz A, Sahin B. Mucormycosis-associated fungal infections in patients with haematologic malignancies. *Int J Clin Pract* 2007; 63: 134–139.
175. Kontoyiannis DP, Wessel VC, Bodey GP, Rolston KV. Zygomycosis in the 1990s in a tertiary-care cancer center. *Clin Infect Dis* 2000; 30: 851–856.
176. Safdar A, Rodriguez GH, Lichtiger B et al. Recombinant interferon γ 1b immune enhancement in 20 patients with hematologic malignancies and systemic opportunistic infections treated with donor granulocyte transfusions. *Cancer* 2006; 106: 2664–2671.
177. Sun HY, Aguado JM, Bonatti H et al. Pulmonary zygomycosis in solid organ transplant recipients in the current era. *Am J Transplant* 2009; 9: 2166–2171.
178. Singh N, Aguado JM, Bonatti H et al. Zygomycosis in solid organ transplant recipients: a prospective, matched case-control study to assess risks for disease and outcome. *J Infect Dis* 2009; 200: 1002–1011.
179. Sun HY, Forrest G, Gupta KL et al. Rhino-orbital-cerebral zygomycosis in solid organ transplant recipients. *Transplantation* 2010; 90: 85–92.

180. Yohai RA, Bullock JD, Aziz AA, Markert RJ. Survival factors in rhino-orbital-cerebral mucormycosis. *Surv Ophthalmol* 1994; 39: 3–22.
181. Bhansali A, Bhadada S, Sharma A *et al.* Presentation and outcome of rhino-orbital-cerebral mucormycosis in patients with diabetes. *Postgrad Med J* 2004; 80: 670–674.
182. Patino JF, Castro D. Necrotizing lesions of soft tissues: a review. *World J Surg* 1991; 15: 235–239.
183. Ibrahim AS, Gebermariam T, Fu Y *et al.* The iron chelator deferasirox protects mice from mucormycosis through iron starvation. *J Clin Invest* 2007; 117: 2649–2657.
184. Liu M, Spellberg B, Phan QT *et al.* The endothelial cell receptor GRP78 is required for mucormycosis pathogenesis in diabetic mice. *J Clin Invest* 2010; 120: 1914–1924.
185. Ibrahim AS, Gebremariam T, French SW, Edwards JE Jr, Spellberg B. The iron chelator deferasirox enhances liposomal amphotericin B efficacy in treating murine invasive pulmonary aspergillosis. *J Antimicrob Chemother* 2010; 65: 289–292.
186. Spellberg B, Andes D, Perez M *et al.* Safety and outcomes of open-label deferasirox iron chelation therapy for mucormycosis. *Antimicrob Agents Chemother* 2009; 53: 3122–3125.
187. Spellberg B, Ibrahim AS, Chin-Hong PV *et al.* The Deferasirox-Am-Bisome Therapy for Mucormycosis (DEFEAT Mucor) study: a randomized, double-blinded, placebo-controlled trial. *J Antimicrob Chemother* 2012; 67: 715–722.
188. Lukacs G, Papp T, Nyilasi I, Nagy E, Vagvolgyi C. Differentiation of *Rhizomucor* species on the basis of their different sensitivities to lovastatin. *J Clin Microbiol* 2004; 42: 5400–5402.
189. Chamilos G, Lewis RE, Kontoyiannis DP. Lovastatin has significant activity against zygomycetes and interacts synergistically with voriconazole. *Antimicrob Agents Chemother* 2006; 50: 96–103.
190. Lionakis MS, Kontoyiannis DP. Glucocorticoids and invasive fungal infections. *Lancet* 2003; 362: 1828–1838.
191. John BV, Chamilos G, Kontoyiannis DP. Hyperbaric oxygen as an adjunctive treatment for zygomycosis. *Clin Microbiol Infect* 2005; 11: 515–517.
192. Maertens J, Theunissen K, Verhoef G *et al.* Galactomannan and computed tomography-based preemptive antifungal therapy in neutropenic patients at high risk for invasive fungal infection: a prospective feasibility study. *Clin Infect Dis* 2005; 41: 1242–1250.
193. Bernal-Martinez L, Buitrago MJ, Castelli MV, Rodriguez-Tudela JL, Cuenca-Estrella M. Development of a single tube multiplex real-time PCR to detect the most clinically relevant Mucormycetes species. *Clin Microbiol Infect* 2013; 19: E1–E7.
194. Millon L, Larosa F, Lepiller Q *et al.* Quantitative polymerase chain reaction detection of circulating DNA in serum for early diagnosis of mucormycosis in immunocompromised patients. *Clin Infect Dis* 2013; 56: e95–e101.
195. Alastruey-Izquierdo A, Castelli MV, Cuesta I *et al.* *In vitro* activity of antifungals against Zygomycetes. *Clin Microbiol Infect* 2009; 15 (Suppl. 5): 71–76.
196. Gleissner B, Schilling A, Anagnostopoulou I, Siehl I, Thiel E. Improved outcome of zygomycosis in patients with hematological diseases? *Leuk Lymphoma* 2004; 45: 1351–1360.
197. Rammaert B, Lanternier F, Poiree S, Kania R, Lortholary O. Diabetes and mucormycosis: a complex interplay. *Diabetes Metab* 2012; 38: 193–204.
198. Garcia-Diaz JB, Palau L, Pankey GA. Resolution of rhinocerebral zygomycosis associated with adjuvant administration of granulocyte-macrophage colony-stimulating factor. *Clin Infect Dis* 2001; 32: e145–e150.
199. Chakrabarti A, Das A, Sharma A *et al.* Ten years' experience in zygomycosis at a tertiary care centre in India. *J Infect* 2001; 42: 261–266.
200. Bernardo VA, Cross SJ, Crews KR *et al.* Posaconazole therapeutic drug monitoring in pediatric patients and young adults with cancer. *Ann Pharmacother* 2013; 47: 976–83.