

Leukoaraiosis and Intracerebral Hematoma

Kaynak Selekleler, MD, and Canan Erzen, MD

We studied 33 consecutive patients with computed tomographic findings of decreased density in the periventricular white matter (leukoaraiosis). Computed tomograms in five (aged 56–75 years) of the 33 demonstrated intracerebral hematoma. The hemorrhages were situated in the thalamic area in four and in the parietotemporal area in one patient. These five patients were hypertensive and had signs characteristic of parenchymal hemorrhage. Three of the five patients had progressive dementia prior to the ictus, and two of the three also had a history of single or multiple strokes. There was no significant difference in the clinical findings of hematoma patients with or without leukoaraiosis. (*Stroke* 1989;20:1016–1020)

Improved contrast resolution of currently available computed tomographic (CT) scanners has resulted in the frequent demonstration of white matter lucencies in the brains of elderly patients. Bilateral and symmetric periventricular white matter lucencies, or leukoaraiosis,¹ found on CT scans has been attributed to several diseases (such as multi-infarct dementia or Binswanger's disease or dementia of the Alzheimer type) and to normal aging.^{2–16} In the last few years, the same type images have been encountered in demented and nondemented patients with cerebrovascular disease.^{5,14,17,18} A high prevalence of lacunar infarcts has been reported in most studies of patients with leukoaraiosis.^{4,10,11,16–18} On the other hand, intracerebral hematoma has been reported in only a few cases.^{4,14}

We describe five patients who had leukoaraiosis and intracerebral hematoma on their CT scans, and we discuss the possible mechanisms of periventricular white matter lucencies and intracerebral hematoma.

Subjects and Methods

From February to July 1988, 2,275 patients underwent technically satisfactory brain imaging at the CT unit of Hacettepe University Medical School during routine clinical operation. The CT scans were done using a third-generation scanner (Philips Tomoscan 350, Eindhoven, The Netherlands). A diagnosis of leukoaraiosis based on cranial CT examinations of adults was made when two investigators independently found that the white matter of the cerebral hemispheres, including not only the periventricular white matter but also the core of the centrum semiovale, was hypodense. An area was

considered lucent if the density was between that of normal white matter and the cerebrospinal fluid. The extent of the periventricular lucencies was graded as mild or marked based on visual impression. The CT scans were also analyzed for ventricular and sulcal enlargement, for cortical atrophy in the frontal, temporal, parietal, and occipital regions, and for central atrophy in the frontal and occipital regions. The presence and location of infarcts and hematomas were also evaluated.

Each patient with leukoaraiosis received a neurologic and a complete physical examination, and a neurologic history was taken. Patients were considered hypertensive if their sustained blood pressure was $\geq 140/90$ mm Hg or if they were receiving antihypertensive medications because that diagnosis had been previously established.

We excluded patients with multiple sclerosis, watershed infarction, radiation leukoencephalopathy, a history of anoxia, leukodystrophy, tumors, trauma, or other nonvascular causes of white matter disease.

Results

We identified leukoaraiosis in 33 (13 women and 20 men aged 50–82 [mean 67] years) of the 2,275 patients examined by CT during the 5 months (incidence 1.5%) (Table 1). The incidence of hypertension among the 33 patients was 94%. Twenty-one were considered demented (incidence 64%), but this may be a falsely low figure because of the insensitivity of the bedside mental status examination for mild degrees of dementia. Fifteen patients had been referred for CT examination because of recent cerebrovascular attacks, and eight patients had a history of stroke. Thus, cerebrovascular disease was present in 23 of the 33 patients (incidence 70%).

Among the 2,275 patients, CT revealed that 42 had a spontaneous intracerebral hematoma. Among the 33 patients with leukoaraiosis, five (aged 56–75

From the Departments of Neurology (K.S.) and Radiology (C.E.), Hacettepe University Medical School, Ankara, Turkey.

Address for correspondence: Dr. Kaynak Selekleler, Department of Neurology, Hacettepe University Medical School, 06100 Ankara, Turkey.

Received January 6, 1989; accepted March 23, 1989.

TABLE 1. Computed Tomographic Characteristics of 33 Patients With Leukoaraiosis

Characteristic	n	%
Ventricular enlargement	22	67
Gyral atrophy	24	73
Lacunar infarct	25	76
Cortical infarct	4	12
Intracerebral hematoma	5	15

[mean 65] years) had an intracerebral hematoma (incidence 15%). Thus, the prevalence of leukoaraiosis among the 42 patients with intracerebral hematoma was 12%.

The CT characteristics of the five patients with both leukoaraiosis and intracerebral hematoma were varied. Two had small deep hematomas; four of the hemorrhages were in the thalamic area and the other was in the parietotemporal area (Figures 1–3). One patient with a thalamic hematoma (Case 1) had had a hemorrhage 1 year prior to her examination; her last CT scan 1 year after the hemorrhage showed a cystic area that resembled a thalamic lacune (Figure 1). Only one of the thalamic hemorrhages (in Case 3) and the lobar hematoma (in Case 5) showed ventricular extension. A follow-up CT scan performed in Case 5 22 days after the initial study showed resolution of the hematoma with ring enhancement; there was no postcontrast opacification of abnormal serpiginous vascular channels adjacent to the hematoma nor were there calcium deposits in its vicinity (Figure 3).

All five patients with both leukoaraiosis and intracerebral hemorrhage had chronic arterial hypertension; the degree of hypertension was mild in one (Case 3), moderate in one (Case 2), and severe in the other three. Case 3 was not receiving any medication; the others received treatment on an irregular basis. Case 3 had normal fundoscopic findings, but the other four patients had hyperten-

sive arteriosclerotic changes. The electrocardiograms showed no abnormality in Cases 1 and 2 or left ventricular hypertrophy in Cases 3–5.

Three patients (Cases 2, 4, and 5) had histories of dementia prior to the ictus. Case 2 had a history of three previous strokes before the last incident of hemorrhage. Case 4 had right hemiparesis and aphasia 1 year previously, and CT at that time revealed bilateral periventricular hypodense areas.

Table 2 summarizes the clinical and CT characteristics of the five patients with both leukoaraiosis and intracerebral hemorrhage. The patients with hematomas in the thalamic area (Cases 1–4) showed neurologic abnormalities consistent with thalamo-capsular involvement. The three patients with left hemisphere localization (Cases 2–4) were aphasic; none had vertical gaze paralysis. The patient with the right parietotemporal lobar hematoma (Case 5) had minor parietal lobe findings, such as denial and contralateral visual and tactile extinction, in addition to minimal left hemiparesis and left homonymous hemianopsia.

None of the five patients was taking warfarin or sympathomimetic agents at the time of their hemorrhage, and none had diabetes, coagulation disorders, or brain tumor. Angiography and surgery were not performed in any patient. They all survived with different degrees of residual findings.

Discussion

The incidence of intracerebral hematoma in patients with leukoaraiosis was 15% in our series. Three of these five patients had histories of insidious progression of memory deficit; two also had had single or multiple strokes. On the other hand, there were no significant differences in the clinical findings of hematoma patients with or without leukoaraiosis.

The etiopathogenesis of leukoaraiosis is controversial. The periventricular hypodense nonenhancing lesions demonstrated on CT scans have been

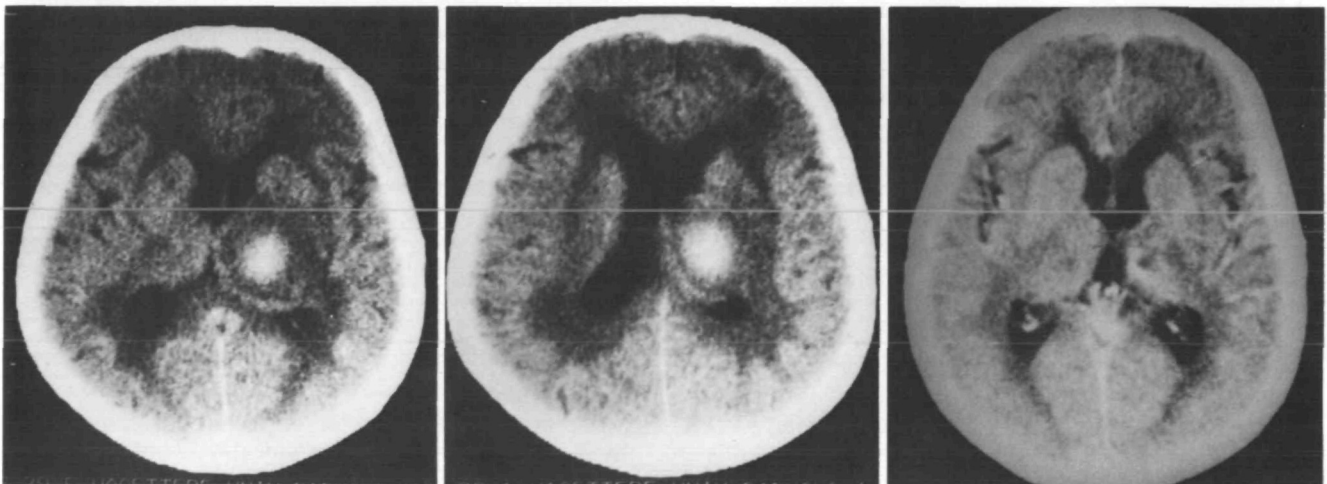


FIGURE 1. Case 1. Left and Middle: Contiguous computed tomographic (CT) sections of patient with right thalamic hematoma. Beside hemorrhage, note marked degree of diffuse periventricular lucencies (leukoaraiosis) Right: One year after initial event, CT shows cystic area in same location that resembles lacune.

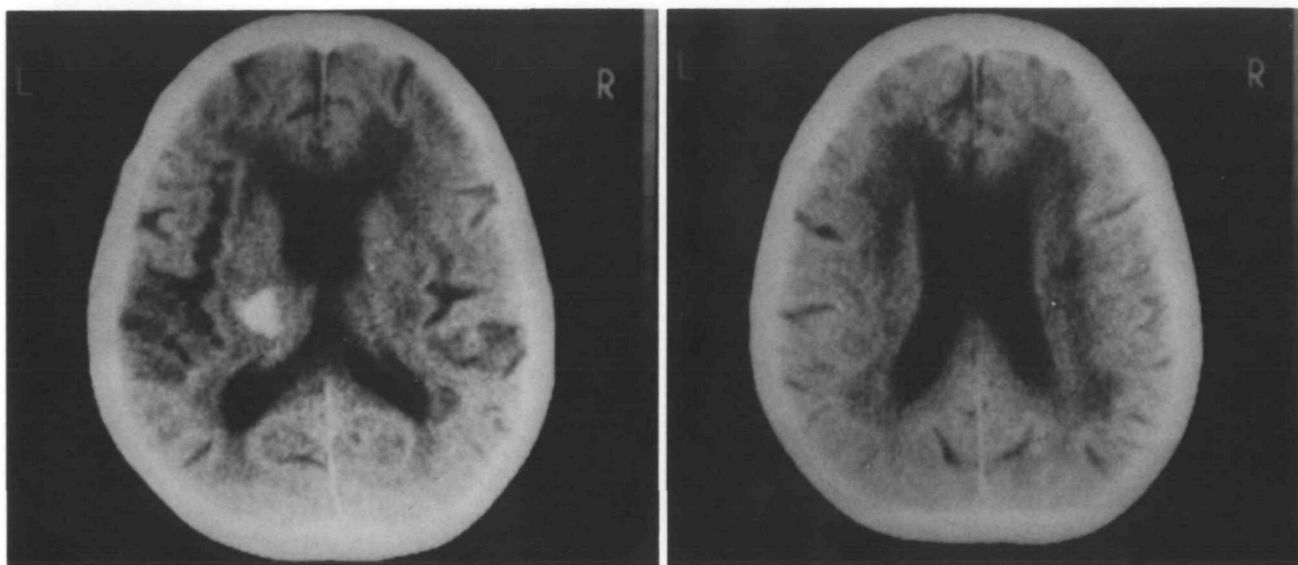


FIGURE 2. Case 4. Computed tomographs of another patient with leukoaraiosis and intracerebral hematoma. Hemorrhage is located in posterior part of internal capsule and thalamus.

attributed to either transependymal exudate or to subcortical arteriosclerotic encephalopathy (Binswanger's disease).^{2,3,5} Pathologic studies of subjects with Binswanger's disease have stressed the role of hypertension and stroke.^{17,19,20} Hypertension per se was considered the possible cause of leukoencephalopathy by some authors.^{2-4,17,19} Hypertension is also a major risk factor for intracerebral hemorrhage.²¹ Intizari et al¹⁷ showed that both hypertension and lacunes were significantly linked with leukoaraiosis. On the other hand, Fisher^{22,23} pointed out that cerebral hemorrhage was frequently associated with lacunes. In a morphometric study of subarachnoid and white matter arteries in "Binswanger's encephalopathy," hypertensive encephalopathy, and hypertensive intracerebral hemorrhage, prominent medial hypertrophy was qualitatively similar.²⁴ These studies suggest that the arteriosclerotic changes related to hypertension may be the etiologic factor in the development of lacunes, intracerebral hemorrhage, and leukoaraiosis. Therefore, intracerebral hemorrhage with leukoaraiosis may also be explained by the effect of hypertension.

It is surprising that there are only a few reported intracerebral hematomas in patients with CT-diagnosed leukoaraiosis. One patient of Loizou et al,⁴ who had hypertension and white matter low-attenuation areas on CT, also had a cerebellar hematoma, and a patient of McQuinn and O'Leary¹⁴ survived a left frontal intracerebral hemorrhage 1 year prior to her examination. However, intracerebral hemorrhage was not mentioned in many CT series of cases with leukoaraiosis.^{5,6,8-13,15,17}

Magnetic resonance imaging (MRI) is more sensitive in identifying white matter changes in patients with intracerebral hemorrhage. Kertesz et al²⁵ recently showed that MRI was clearly better than

CT in demonstrating periventricular hyperintensities in more than half of their infarct and hemorrhage cases. In their series of 142 patients and controls with periventricular changes, 18 had intracerebral hemorrhage (incidence 12.7%), which is in accordance with our findings.

Another possible cause of leukoaraiosis and intracerebral hemorrhage is cerebral amyloid angiopathy, which must now be considered an important etiologic factor in primary nontraumatic brain hemorrhage.²⁶ Although many cases are normotensive, a significant proportion (>30%) of individuals with cerebral amyloid angiopathy-related intracerebral hemorrhage have clinically documented hypertension.²⁶⁻²⁸ Cerebral amyloid angiopathy-related intracerebral hemorrhage occurs in elderly, frequently demented individuals as a cerebral lobar hemorrhage, and over time several lobes on both sides of the brain may be involved.²⁶⁻²⁸ The vessels of the basal ganglia, cerebellum, and brainstem are seldom involved,²⁸ and thalamic²⁷ and basal ganglionic^{29,30} hemorrhage occurs only rarely.

Dubas et al³¹ suggested that amyloid changes occur in patients with leukoencephalopathy. In pathologic examination, Roullet et al³²⁻³⁴ observed severe white matter changes in patients with diffuse and severe cerebral amyloid angiopathy. Only four of their 10 patients had CT scans, but bilateral hypodensities of the hemispheric white matter consistent with leukoaraiosis were demonstrated in these patients.

The final diagnosis of cerebral amyloid angiopathy requires brain biopsy or autopsy,²⁶ but cerebral amyloid angiopathy should be suspected in any elderly patient presenting with intracerebral hemorrhage in an atypical site.³⁵ Although we do not have microscopic verification, the etiologic factor (in our

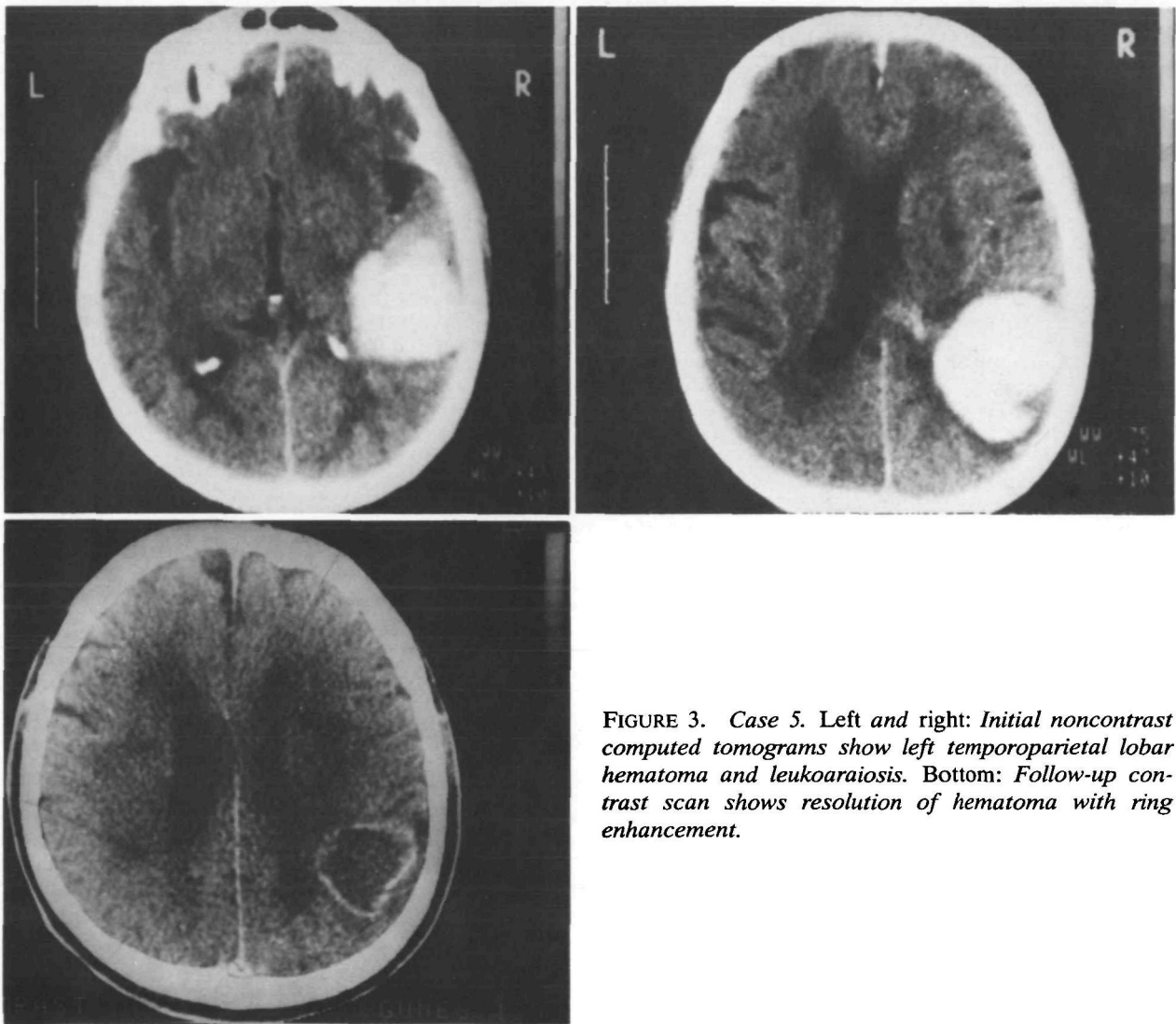


FIGURE 3. Case 5. Left and right: Initial noncontrast computed tomograms show left temporoparietal lobar hematoma and leukoaraiosis. Bottom: Follow-up contrast scan shows resolution of hematoma with ring enhancement.

patient with lobar hematoma) may have been cerebral amyloid angiopathy.

In conclusion, we detected intracerebral hemorrhage in five of 33 patients who also had leukoaraiosis on CT examination. We believe that this is not a coincidental finding. Although occlusive-type vascular lesions are common in patients with leukoarai-

osis, intracerebral hematoma can also be seen in 15%. Hypertension and/or cerebral amyloid angiopathy may therefore play a role in the development of leukoaraiosis in association with intracerebral hematoma.

Note added in proof. Since the submission of this study, Case 5 was hospitalized because of a recent

TABLE 2. Clinical and Computed Tomographic Findings of Five Patients With Both Leukoaraiosis and Intracerebral Hematoma

Pt/age/sex	Clinical findings					Computed tomographic findings					
	HBP	LOC	Deficit			LA	Site of hematoma	Ventricular			Gyral atrophy
			Motor	Hemi-sensory	Aphasia			Extension	Enlargement	Lac	
1/56/F	+	Alert	L hemiparesis	+	-	Marked	R thalamus	-	Mild	-	-
2/75/M	+	Lethargic	R hemiparesis	+	+	Marked	L thalamus	-	Severe	+	Severe
3/62/M	+	Alert	R hemiparesis	-	+	Mild	L thalamus	+	-	-	-
4/65/F	+	Lethargic	R hemiparesis	+	+	Marked	L thalamus	-	Mild	+	Moderate
5/68/M	+	Alert	L hemiparesis	-	-	Marked	R parietotemporal	+	-	+	Mild

Pt, case number; HBP, hypertension; LOC, level of consciousness; LA, degree of leukoaraiosis; Lac, lacunes; F, female; M, male; L, left; R, right.

left thalamic hematoma 14 months after his initial admission, which supports the diagnosis of cerebral amyloid angiopathy.

References

- Hachinski VC, Potter P, Merskey H: Leuko-araiosis. *Arch Neurol* 1987;44:21-23
- Rosenberg GA, Kornfeld M, Stovring J, Bicknell JM: Subcortical arteriosclerotic encephalopathy (Binswanger): Computerized tomography. *Neurology* 1979;29:1102-1106
- Zeumer H, Schonsky B, Sturm KW: Predominant white matter involvement in subcortical arteriosclerotic encephalopathy (Binswanger's disease). *J Comput Assist Tomogr* 1980;4:14-19
- Loizou LA, Kendall BE, Marshall J: Subcortical arteriosclerotic encephalopathy: A clinical and radiological investigation. *J Neurol Neurosurg Psychiatry* 1981;44:294-304
- Goto K, Ishii N, Fukasawa H: Diffuse white-matter disease in the geriatric population. A clinical, neuropathological, and CT study. *Radiology* 1981;141:687-695
- Kinkel WR, Jacobs L, Polachini I, Bates V, Heffner RR Jr: Subcortical arteriosclerotic encephalopathy (Binswanger's disease). Computer tomographic, nuclear magnetic resonance, and clinical correlations. *Arch Neurol* 1985;42:951-959
- George AE, deLeon MJ, Gentes CI, Miller J, London E, Budzilovich GN, Ferris S, Chase N: Leukoencephalopathy in normal and pathologic aging: 1. CT of brain lucencies. *AJNR* 1986;7:561-566
- London E, de Leon MJ, George AE, Englund E, Ferris S, Gentes C, Reisberg B: Periventricular lucencies in the CT scans of aged and demented patients. *Biol Psychiatry* 1986;21:960-962
- Erkinjuntti T, Ketonen L, Sulkava R, Sipponen J, Vuoriohalo M, Iivanainen M: Do white matter changes on MRI and CT differentiate vascular dementia from Alzheimer's disease? *J Neurol Neurosurg Psychiatry* 1987;50:37-42
- Erkinjuntti T, Ketonen L, Sulkava R, Vuoriohalo M, Palo J: CT in the differential diagnosis between Alzheimer's disease and vascular dementia. *Acta Neurol Scand* 1987;75:262-270
- Steingart A, Hachinski VC, Lau C, Fox AJ, Diaz F, Cape R, Lee D, Intizari D, Merskey H: Cognitive and neurologic findings in subjects with diffuse white matter lucencies on computed tomographic scan (leuko-araiosis). *Arch Neurol* 1987;44:32-35
- Steingart L, Hachinski VC, Lau C, Fox AJ, Fox H, Lee D, Intizari D, Merskey H: Cognitive and neurologic findings in demented patients with diffuse white matter lucencies on computed tomographic scan (leuko-araiosis). *Arch Neurol* 1987;44:36-39
- Rezek DL, Morris JC, Fulling KH, Gado MH: Periventricular white matter lucencies in senile dementia of the Alzheimer type and in normal aging. *Neurology* 1987;37:1365-1368
- McQuinn BA, O'Leary DH: White matter lucencies on computed tomography, subacute arteriosclerotic encephalopathy (Binswanger's disease), and blood pressure. *Stroke* 1987;18:900-905
- Gupta SR, Naheedy MH, Young JC, Ghobrial M, Rubino FA, Hindo W: Periventricular white matter changes and dementia. Clinical, neuropsychological, radiological, and pathological correlation. *Arch Neurol* 1988;45:637-641
- Aharon-Peretz J, Cummings JL, Hill MA: Vascular dementia and dementia of the Alzheimer type. Cognition, ventricular size, and leuko-araiosis. *Arch Neurol* 1988;45:719-721
- Intizari D, Diaz F, Fox A, Hachinski VC, Steingart A, Lau C, Donald A, Wade J, Mulic H, Merskey H: Vascular risk factors and leuko-araiosis. *Arch Neurol* 1987;44:42-47
- Bogousslavsky J, Regli F, Uske A: Leukoencephalopathy in patients with ischemic stroke. *Stroke* 1987;18:896-899
- Caplan LR, Schoene WC: Clinical features of subcortical arteriosclerotic encephalopathy (Binswanger disease). *Neurology* 1978;28:1206-1215
- Babikian V, Ropper AH: Binswanger's disease: A review. *Stroke* 1987;18:2-12
- Dyken ML, Wolf PA, Barnett HJM, Bergan JJ, Hass WK, Kannell WB, Kuller L, Kurtzke JF, Sundt TM: Risk factors in stroke. A statement for physicians by the subcommittee on risk factors and stroke of the stroke council. *Stroke* 1984;15:1105-1111
- Fisher CM: Lacunes: Small, deep cerebral infarcts. *Neurology* 1965;15:774-784
- Fisher CM: Lacunar strokes and infarcts: A review. *Neurology* 1982;32:871-876
- Okeda R: Morphometrische Verleischuntersuchungen an Hirnarterien bei Binswangerscher Encephalopathie und Hochdruckencephalopathie (in German). *Acta Neuropathol (Berl)* 1973;26:23-43
- Kertesz A, Black SE, Tokar G, Benke T, Carr T, Nicholson L: Periventricular and subcortical hyperintensities on magnetic resonance imaging. 'Rims, caps, and unidentified bright objects.' *Arch Neurol* 1988;45:404-408
- Vinters HV: Cerebral amyloid angiopathy. A critical review. *Stroke* 1987;18:311-323
- Cosgrove GR, Leblanc R, Meagher-Villemure K, Ethier R: Cerebral amyloid angiopathy. *Neurology* 1985;35:625-631
- Briceno CE, Resch L, Bernstein M: Cerebral amyloid angiopathy presenting as a mass lesion. *Stroke* 1987;18:234-239
- Kalyan-Raman UP, Kalyan-Raman K: Cerebral amyloid angiopathy causing intracranial hemorrhage. *Ann Neurol* 1984;16:321-329
- Masuda J, Tanaka K, Ueda K, Omae T: Autopsy study of incidence and distribution of cerebral amyloid angiopathy in Hisayama, Japan. *Stroke* 1988;19:205-210
- Dubas F, Gray F, Rouillet E, Escourolle R: Leucoencephalopathies artériopathiques: Dix-sept observation anatomocliniques (in French). *Rev Neurol (Paris)* 1985;141:93-108
- Gray F, Dubas F, Rouillet E, Escourolle R: Leukoencephalopathy in diffuse hemorrhagic cerebral amyloid angiopathy. *Ann Neurol* 1985;18:54-59
- Rouillet E, Baudrimont M, Singer B, Ollat H, Mahieux F, Hauw JJ, Orcel L, Marteau R, Contamin F: Angiopathie amyloïde cérébrale: Deux observations anatomoclinique. *Arch Anat Cytol Pathol* 1986;34:95-98
- Rouillet E, Gray FF, Dubas F: Leuko-araiosis in severe amyloid angiopathy (letter). *Arch Neurol* 1988;45:140-141
- Sobel F, Baker E, Anderson B, Kretzschmar H: Cerebral amyloid angiopathy associated with massive intracerebral hemorrhage. *Neuroradiology* 1985;27:318-321

KEY WORDS • hematoma • small-vessel disease • white matter