

## **Superiority of Echocardiographically Assisted Blade Atrial Septostomy**

Süheyla ÖZKUTLU, M.D.\* *and* Muhsin SARAÇLAR, M.D.\*

### **SUMMARY**

Blade atrial septostomy has been applied in 3 patients with transposition of the great arteries under two-dimensional echocardiography instead of fluoroscopy. The blade at the tip of the catheter was seen on an echo screen when it was in the left atrium. The blade was then extended and pulled slowly across the atrial septum from the left into the right atrium, under echocardiographic monitoring. The procedure was successful in all 3 patients. Interatrial communication measured echocardiographically was sufficient in size. Since the interatrial septum is clearly seen by means of echocardiography during blade atrial septostomy, the method is thought to be superior to fluoroscopy in the prevention of complications.

### **Key Words:**

Blade atrial septostomy Two-dimensional echocardiography Transposition of the great arteries

**B**ALLOON atrial septostomy is still a valuable palliative technique for creating an atrial septal defect in patients with certain congenital heart disease. Conventionally, this method is applied under fluoroscopy. In previous reports the usefulness of echocardiographic monitoring has been discussed.<sup>1),2)</sup>

In patients with a thick interatrial septum, balloon atrial septostomy is unsuccessful and surgical septectomy is needed. Since surgery may result in complications, blade atrial septostomy performed under fluoroscopy is preferred. However, the application of echocardiographic monitoring during this procedure seems to be a useful alternative.<sup>3)</sup> The study was conducted to evaluate further the value of this method.

---

From the Department of Cardiology, Hacettepe University, Institute of Child Health, Ankara, Turkey.

\* Professor of Pediatrics and Pediatric Cardiologist.

Address for correspondence: Süheyla Özkutlu, M.D., Cumhurbaşkanlığı Lojmanlari, B-Blok, No. 2, Cankaya, Ankara, Turkey.

Received for publication October 28, 1991.

Accepted December 9, 1991.

## MATERIALS AND METHODS

Three infants were studied. The age range was between 65 and 81 days. The diagnosis was established by M-mode, two-dimensional, Doppler echocardiography as transposition of the great arteries. Two patients had a ventricular septal defect in addition. The interatrial communication was measured echocardiographically and determined to be inadequately sized in all patients. Considering the ages of the babies, it was decided that instead of balloon atrial septostomy, blade atrial septostomy was indicated.

For echocardiographic investigation a Toshiba 60A echocardiograph with 2.5 MHz Doppler and 5 MHz two-dimensional transducers was used.

In the cardiac catheterization laboratory a 5 F NIH catheter was inserted intravenously by cut-down technique. The pressures and O<sub>2</sub> saturations were measured. In all 3 patients there was a significant pressure gradient between the two atria, indicating the need for septostomy.

The 6 F catheter with a sheath was inserted into the femoral vein under fluoroscopy. The catheter entered the right atrium. Then a 5 MHz echo transducer was placed over the subcostal region. The tip of the catheter and foramen ovale or atrial septal defect were visualized. With manipulation, the catheter entered the left atrium through the interatrial communication. The sheath was then left in the left atrium. The inside catheter was replaced with the blade catheter. The tip of the blade catheter was denser than the other parts echocardiographically (Fig. 1). The blade was extended by ad-

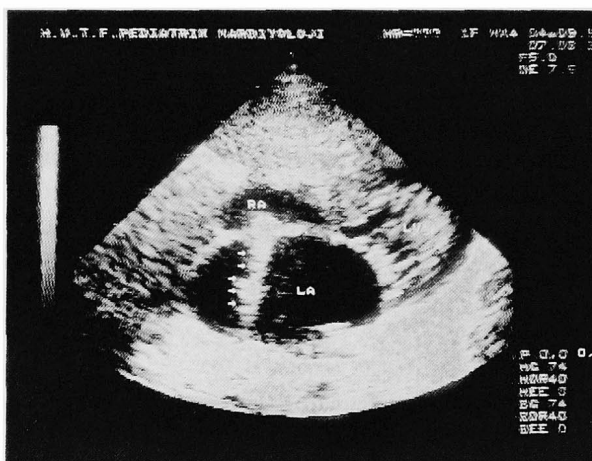

Fig. 1. Subcostal echocardiogram. The tip of the blade catheter introduced from the right atrium into the left atrium through the interatrial communication is seen as a dense image (arrows). RA=right atrium; LA=left atrium; LV=left ventricle; RV=right ventricle.

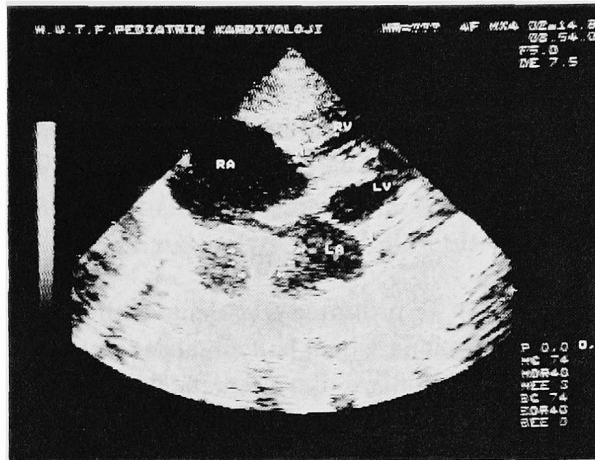


Fig. 2. Subcostal echocardiogram. The extended blade in the left atrium (arrows) is illustrated. Abbreviations as in Fig. 1.

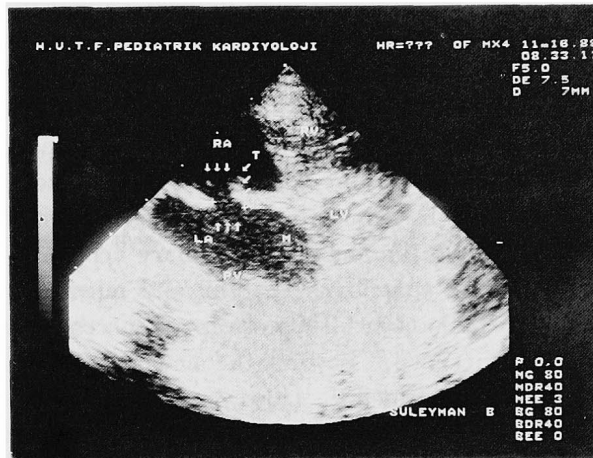


Fig. 3. Subcostal echocardiogram demonstrates the newly created interatrial opening (arrows). M=mitral valve; T=tricuspid valve; RV=right ventricle; PV=pulmonary vein. Other abbreviations as in Fig. 1.

vancing the blade control wire holder gently toward the catheter tip under echocardiographic control (Fig. 2). The blade was then pulled slowly across the atrial septum, from the left into the right atrium under echocardiographic monitoring. Following this the blade was retracted into the catheter in the right atrium. The septum was crossed 2 to 3 times in the same manner. Echocardiographic measurement of the interatrial communication showed that the septostomy was successful and communication was sufficient (Fig. 3). The procedure was ended following pressure measurement in both atria.

## RESULTS

Post procedure evaluation of the patients showed that the pressures in both atria were equal and oxygen saturations were increased. The sizes of the interatrial communications in all patients are shown in Table I.

## DISCUSSION

In a previous report we presented 6 patients with d-transposition and 1 patient with tricuspid atresia in whom balloon atrial septostomy was performed successfully with the aid of two-dimensional echocardiography.<sup>2)</sup> In that study the superiority of echocardiography to fluoroscopy during balloon atrial septostomy was emphasized. With this method, prior to withdrawal of the balloon from the left atrium, the mitral valve, cordae tendinae, papillary muscles and pulmonary veins can be seen by two-dimensional echocardiography and those structures can be protected from damage caused by the balloon.<sup>2)</sup> In addition, the accidental spontaneous passage of the inflated balloon into the left ventricle through the mitral valve can be detected by two-dimensional echocardiography.<sup>2)</sup> Thus, possible damage to the mitral valve can be prevented. This method also shows both the atrial septum and balloon clearly and the septostomy procedure can be followed on the echo screen.

Balloon septostomy is used in babies with transposition of the great arteries, tricuspid atresia, total anomalous pulmonary venous connection, pulmonary atresia with intact ventricular septum, and mitral atresia with ventricular septal defect. Balloon atrial septostomy is successful when the interatrial septum is not thickened. Beyond the newborn period surgical septostomy must usually be performed.<sup>4)</sup> However transvenous blade septostomy under fluoroscopy is an established alternative to surgical septectomy in infants and children.<sup>4),5)</sup> The overall complication rate in 63 published procedures was 8 to 10 percent.<sup>4),6),7)</sup> Among the complications laceration of the left atrial wall resulting in death, and perforation of the right ventricular outflow tract have been reported.<sup>4)</sup> In addition, we can speculate that in those

Table I. Size of Atrial Septal Defect after Blade Atrial Septostomy

Case No.	Age (days)	Diagnosis	Approximate size of ASD created (cm)
1	65	TGA, VSD	1
2	76	TGA, VSD	0.7
3	81	TGA	1.2

TGA=transposition of great arteries; VSD=ventricular septal defect.

cases with a hypoplastic left atrium as seen in mitral atresia with ventricular septal defect or total anomalous pulmonary venous connection, the blade may easily damage the left atrial wall if the procedure is carried out under fluoroscopy.

Echocardiographically assisted blade atrial septostomy may minimize complications. As a matter of fact, Lin et al described their successful application of blade atrial septostomy with the aid of two-dimensional echocardiography in 2 patients.<sup>3)</sup>

In our study, application of blade atrial septostomy was successful in all these patients. No complications were seen. However, the fluoroscopy assisted method is a blind technique. One cannot see the interatrial septum, but must imagine that the septum is just next to the blade. Since in the echocardiographically assisted procedure the interatrial septum is clearly seen, this technique should be safer.

#### REFERENCES

1. Beitzke A, Stein JI, Suppan C: Balloon atrial septostomy under two-dimensional echocardiographic control. *Int J Cardiol* **30**: 33, 1991
2. Özkutlu S, Özme S, Saraçlar M, Baysal K: Balloon atrial septostomy using echocardiographic monitoring. *Jpn Heart J* **29**: 415, 1988
3. Lin AE, Di Sessa TG, Williams RG, et al: Balloon and blade atrial septostomy facilitated by two-dimensional echocardiography. *Am J Cardiol* **57**: 273, 1986
4. Radtke W, Lock J: Blade atrial septostomy. *Pediatric Clinics of North America* **37**: 204, 1990
5. Park SC, Neches WH, Zuberbuhler JR, Lenox CC, Mathews RA, Fricker GJ, Zoltun RA: Clinical use of blade atrial septostomy. *Circulation* **58**: 600, 1978
6. Park SC, Neches WH, Mullins GE, et al: Blade atrial septostomy: Collaborative study. *Circulation* **66**: 258, 1982
7. Perry SB, Lang P, Keane JF, Jonas RA, Sanders SP, Lock JE: Creation and maintenance of an adequate interatrial communication in left atrioventricular valve atresia or stenosis. *Am J Cardiol* **58**: 622, 1986