

# The Efficacy of Interferon-alpha in a Patient with Resistant Familial Mediterranean Fever Complicated by Polyarteritis Nodosa

Meral CALGUNERI, Sule APRAS, Zeynep OZBALKAN\* and M. Akif OZTURK\*\*

## Abstract

**Familial Mediterranean fever (FMF) is a recurrent self-limiting polyserositis. Polyarteritis nodosa (PAN) complicating FMF is very rare. Here, we present a 17-year-old male patient with FMF who subsequently developed PAN 2 weeks after hepatitis A infection. This case was also complicated with perirenal haematoma, and right nephrectomy was performed. The clinical condition of the patient was improved after therapy with intravenous and oral corticosteroid and intravenous cyclophosphamide. However, the FMF attacks and vasculitic skin lesions again occurred while he was using colchicine plus immunosuppressive agents a few months later. Interferon-alpha therapy was administered and the attacks were resolved within 3 months. He has not experienced any other symptom during the follow-up period of 28 months.**

**(Internal Medicine 43: 612–614, 2004)**

**Key words:** Familial Mediterranean fever, vasculitis, polyarteritis nodosa, hepatitis A, interferon-alpha

## Introduction

Familial Mediterranean fever (FMF) is an autosomal recessive disease characterized by recurrent self-limited attacks of fever accompanied by peritonitis, pleuritis, arthritis and erythema resembling erysipelas (1). Vasculitides has been increasingly reported in FMF (1, 2). Approximately 1% of individuals with FMF have been reported to have polyarteritis nodosa (PAN) (2). Factors which trigger the development of vasculitides in FMF patients remain to be de-

termined. In this report, we present an FMF patient who developed PAN 2 weeks after acute hepatitis A infection and was complicated with perirenal hematoma. His symptoms were controlled and he remained stable for 12 months with intravenous corticosteroids and cyclophosphamide in addition to colchicine. However, he later developed febrile peritonitis attacks and vasculitic skin lesions, which responded well to interferon.

## Case Report

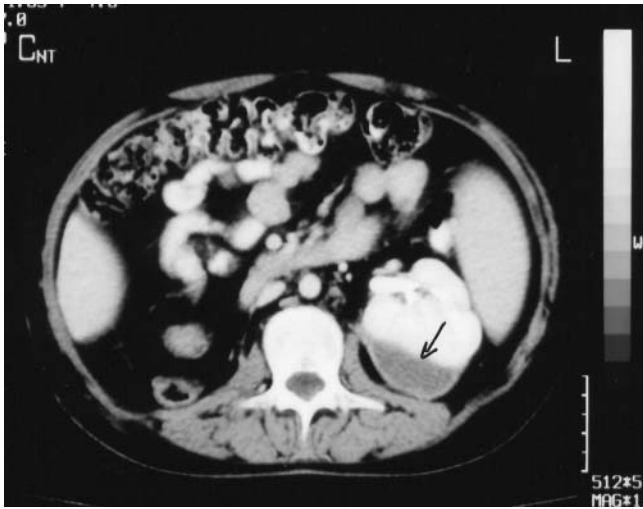A 17-year old Turkish boy was admitted to our clinic with complaints of weight loss, fatigue and abdominal pain. He had been on colchicine therapy for 6 years with the diagnosis of FMF. He fulfilled the Tel-Hashomer criteria for FMF (3). In January 2000, he had been diagnosed as having acute hepatitis A infection with jaundice and elevated liver enzymes and bilirubin levels with positive serology in another center. Two weeks later he was hospitalized in the same clinic due to severe abdominal pain and an abrupt decrease in his hemoglobin values. Constitutional symptoms like fatigue, malaise, arthralgia and myalgia also accompanied the abdominal pain. A right renal subcapsular haematoma was demonstrated by computerized tomography (CT). During follow-up hemoglobin values progressively declined and the haematoma showed enlargement in control CT. Accordingly right nephrectomy was performed. After the patient was stabilized clinically and biochemically, he was discharged. However, he was again hospitalized with similar complaints 4 days later. This time subcapsular haematoma was demonstrated in the left kidney and he was referred to our hospital in March 2000. On physical examination blood pressure was 160/125 mmHg. Abdominal tenderness and direct/indirect rebound were positive on abdominal palpation; livedoreticularis on extremities and muscle weakness were the other

---

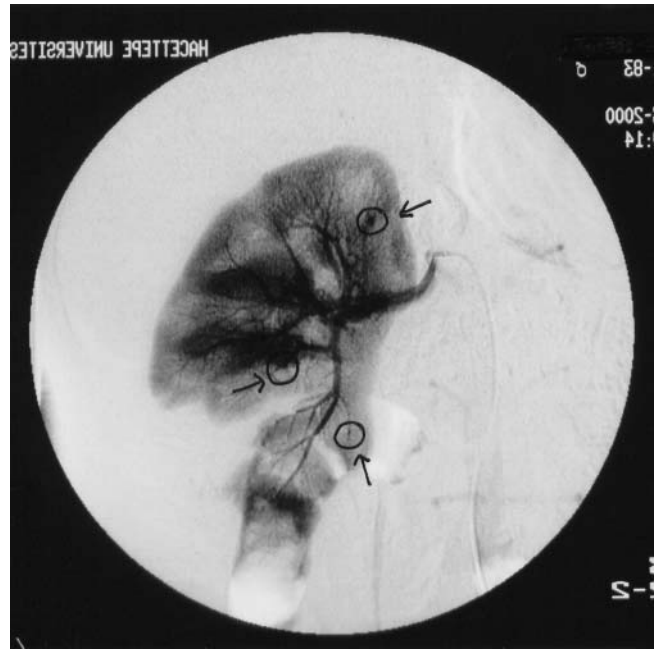
From Hacettepe University Faculty of Medicine, Internal Medicine Department, Section of Rheumatology, Ankara-Turkey, \*Ankara Numune Training and Research Hospital, Internal Medicine Department, Section of Rheumatology, Ankara-Turkey and \*\*Gazi University Faculty of Medicine, Internal Medicine Department, Section of Rheumatology, Ankara-Turkey

Received for publication February 26, 2003; Accepted for publication January 23, 2004

Reprint requests should be addressed to Dr. Zeynep Ozbalkan, Sehit Cetin Gorgu Sok. Ugur Apt. 17/3, 06570-Maltepe, Ankara, Turkey



**Figure 1.** Developed peri-renal haematoma (arrow) around the left kidney of the patient due to PAN.



**Figure 2.** Angiographic findings of the left kidney demonstrating the developed micro aneurysm (arrows) due to PAN.

physical examination findings. Laboratory evaluation demonstrated anemia and elevated erythrocyte sedimentation rate and C-reactive protein [ESR: 84 mm/h, CRP: 7 mg/dl (0–1.1)]. Serum urea and creatinin levels and liver enzymes were within normal limits. Serological tests for anti-hepatitis B surface antigen, anti-hepatitis A IgG and IgM were positive. The urine analysis showed the presence of microscopic hematuria (red blood cell >5/HPF). MEF 694V mutation analysis was positive for both alleles.

Nephrectomy slides were re-evaluated in our pathology department. Focal polymorphonuclear leukocyte and lymphocytes infiltration and fibrinoid necrosis were seen at the wall of the small and medium sized vessels. Patchy and segmental areas of renal infarct were demonstrated. No amyloid deposits could be noted in the histopathology specimens. Renal angiography demonstrated micro-aneurysms on intertubular arteries. Together with these clinical, radiological and histopathological findings the diagnosis of PAN was established according to the American College of Rheumatology defined criteria (4). Methylprednisolone was given 1 gr three consecutive days and then three times with one-week intervals, three times with ten-day intervals, three times with 15-day intervals, three times with 20-day intervals and then once every month. Intravenous 500 mg cyclophosphamide was started to be given after the first three methylprednisolone administrations and then continued according to the above given schema after each steroid pulses. Antihypertensive therapy was also added. Control abdominal ultrasonography and magnetic resonance imaging two months after the initiation of immune suppressive therapy were normal except for compensatory hypertrophy of the left kidney. Subcapsular haematoma was resorbed; CRP and ESR decreased. However after 12 months he re-developed abdominal pain and fever attacks two times a week, and vasculitic

skin eruption was observed over the lower extremities. CRP and fibrinogen were elevated (CRP: 2.43 mg/dl, fibrinogen: 493 mg/dl). Interferon 3 million units/2 times a week was added to the combination of cyclophosphamide and methylprednisolone. His symptoms were resolved, CRP and fibrinogen levels decreased (CRP: 1.12 mg/dl, fibrinogen: 390 mg/dl) within 10 days and he did not develop another attack during the follow-up period of 16 months.

## Discussion

Vasculitides is now considered as an uncommon manifestation of FMF. However, the underlying pathogenetic mechanisms that lead to the development of vasculitis as a complication of FMF are largely unknown. It has previously been proposed that an exaggerated, uncontrolled inflammatory response caused by infection-related antigenic stimuli could trigger the development of vasculitis in FMF patients (2, 4–6). Therefore, the hepatitis A infection and/or previous hepatitis B infection might have been responsible for the development of PAN in this patient. The vasculitic symptoms in FMF patients usually respond dramatically to corticosteroids with or without immunosuppressive agents (7). However, in the present case while our patient was taking colchicines plus methylprednisolone and cyclophosphamide, febrile peritonitis attacks relapsed and vasculitic cutaneous lesions re-developed.

Interferon is an antiviral agent with immunomodulatory properties. Recent reports suggest that interferon could be effective to control the symptoms in FMF patients which were

resistant to colchicines (8, 9). Patients with hepatitis-related vasculitis including PAN respond to interferon therapy. Interferon can clear pre-core promoter HBV infection and cure PAN. Considering the effectiveness of interferon on FMF and PAN; we preferred to give this agent in addition to conventional therapies with methylprednisolone and cyclophosphamide (8–13). Likewise, our patient responded well to the addition of the interferon therapy. The attacks and vasculitic findings subsided within 3 months, and he remained completely asymptomatic during a 28-month follow-up period.

In conclusion, hepatitis A and/or hepatitis B infection might be among the triggers of PAN in patients with an immune dysregulation, such as FMF. Interferon may be a useful adjuvant for the treatment of resistant attacks in FMF patients with vasculitis

## References

- 1) Akpolat T, Yilmaz E, Ozen S, Akpolat I. M 6801/Arm2/M694V (Med) mutations in a patient with familial Mediterranean fever and polyarteritis nodosa. *Nephrol Dial Transplant* **13**: 2633–2635, 1998.
- 2) Tekin M, Yalcinkaya F, Tumer N, Akar N, Misirlioglu M, Cakar N. Clinical, laboratory and molecular characteristics of children with familial Mediterranean fever-associated vasculitis. *Acta Paediatrica* **89**: 177–182, 2000.
- 3) Livneh A, Langevitz P, Zemer D, et al. Criteria for the diagnosis of familial Mediterranean fever. *Arthritis Rheum* **40**: 1879–1885, 1997.
- 4) Lightfoot RW, Michel BA, Bloch DA, et al. The American College of Rheumatology 1990 criteria for the classification of polyarteritis nodosa. *Arthritis Rheum* **33**: 1088–1093, 1990.
- 5) Basaranoglu M, Mert A, Tabak F. A case of familial Mediterranean fever and polyarteritis nodosa complicated by spontaneous bilateral perirenal and subcapsular splenic haemorrhage. *Rheumatol (Oxford)* **38**: 794–796, 1999.
- 6) Ozdogan H, Arisoy N, Kasapcopur O, Sever L, Caliskan S. Vasculitis in familial Mediterranean fever. *J Rheumatol* **24**: 323–327, 1997.
- 7) Tekin M, Yalcinkaya F, Tumer N, et al. Familial Mediterranean fever renal involvement by disease other than amyloid. *Nephrol Dial Transplant* **14**: 475–479, 1999.
- 8) Xing T, Zang L, Lu Q. IFN-alpha therapy can modulate Th1/Th2 type cytokines, and its relation to its clinical effects. *Chin Med (Engl)* **114**: 921–924, 2001.
- 9) Tunca M, Tankur E, Akbaylar H, Akar S. The efficacy of interferon alpha on colchicine resistant familial Mediterranean fever attacks: a pilot study. *Br J Rheumatol* **36**: 1005–1008, 1997.
- 10) Deleaval P, Stadler P, Descombes E, et al. Life-threatening complications of hepatitis B virus-related polyarteritis nodosa developing despite interferon-alpha 2b therapy: successful treatment with a combination of interferon, lamivudin, plasma exchanges and steroids. *Clin Rheumatol* **20**: 290–292, 2001.
- 11) Wortelle-Blodou C, Lagon J, Trepo C, et al. Successful combination therapy of polyarteritis nodosa associated with a pre-core promoter mutant hepatitis B virus infection. *J Hepatol* **34**: 774–779, 2001.
- 12) Guillevin L, Lhote F. Classification and management of necrotizing vasculitides. *Drugs* **53**: 805–816, 1997.
- 13) Guillevin L, Lhote F, Cohen P, et al. Polyarteritis nodosa related to hepatitis B virus. A prospective study with long-term observation of 41 patients. *Medicine (Baltimore)* **74**: 238–253, 1995.