




Available online at www.sciencedirect.com

SciVerse ScienceDirect

journal homepage: www.e-jmii.com



CASE REPORT

Trichosporon asahii sepsis in a patient with pediatric malignancy



Aslinur Ozkaya-Parlakay^a, Eda Karadag-Oncel^{a,*},
Ali Bulent Cengiz^a, Ates Kara^a, Atilla Yigit^b, Safak Gucer^c,
Deniz Gur^d

^a Department of Pediatric Infectious Diseases, Faculty of Medicine, Hacettepe University, Ankara, Turkey

^b Department of Pediatrics, Faculty of Medicine, Hacettepe University, Ankara, Turkey

^c Department of Pediatric Pathology, Faculty of Medicine, Hacettepe University, Ankara, Turkey

^d Department of Microbiology, Faculty of Medicine, Hacettepe University, Ankara, Turkey

Received 20 June 2012; received in revised form 30 October 2012; accepted 9 January 2013

Available online 16 February 2013

KEYWORDS

Child;
Sepsis;
Trichosporon asahii

Trichosporon asahii is a rare opportunistic infection, especially in children, causing a life-threatening fungal infection underlying hematologic malignancies. Predisposing factors for infection with this pathogen are immunodeficiency including underlying malignancy, organ transplantation, extensive burns, human immunodeficiency virus infection, corticosteroid therapy, prosthetic valve surgery, and peritoneal dialysis. In the literature, a breakthrough under caspofungin, micafungin therapy is reported. In this article we report on a 16-year-old patient with Ewing sarcoma who had *T. asahii* sepsis. The patient died although he had been receiving caspofungin for less than 3 months and amphotericin B therapy for 3 days. A postmortem study of conchal tissues revealed *T. asahii* and mucormycosis histopathologically, and blood culture grew *T. asahii*.

Copyright © 2013, Taiwan Society of Microbiology. Published by Elsevier Taiwan LLC. This is an open access article under the CC BY-NC-ND license (<http://creativecommons.org/licenses/by-nc-nd/4.0/>).

Introduction

Trichosporon asahii is a rare opportunistic yeast-like fungus causing rare infections in children. Despite antifungal

therapy with amphotericin B, the mortality rate is high (80%) and early initiation of treatment may increase survival of these patients.¹ Herein, we report on a previously treated patient with Ewing sarcoma who died because of *T. asahii* sepsis. Three days of liposomal amphotericin B therapy following 3 months of caspofungin therapy did not help to achieve a favorable outcome.

* Corresponding author. Department of Pediatric Infectious Diseases, Faculty of Medicine, Hacettepe University, Sıhhiye 06100, Ankara, Turkey.

E-mail address: dredakaradag@gmail.com (E. Karadag-Oncel).

Case report

A 16-year-old boy previously had been treated for Ewing sarcoma in the region of the right superior pubic ramus. He had received intensive chemotherapy and underwent hemipelvectomy after radiotherapy. A lesion with recurrent pus discharge on the area of radiotherapy (right inguinal area) had worsened, with urine leakage from the lesion despite antibiotic therapy. The patient underwent a second operation for implant insertion to the right pelvic area in August 2008, and had been hospitalized seven times between September 2008 and January 2011 for pus discharge at the right inguinal area after receiving appropriate antibiotic therapy. He and his family had been advised that surgery was necessary for removal of the implant, but they did not provide consent for this process. He eventually was hospitalized to undergo implant removal in June 2011.

Surgery included implant excision and bypass between the saphenous vein, iliac artery, and femoral artery. Because of massive arterial bleeding postoperatively, the patient underwent a second operation for right hip dislocation, total right lower extremity amputation, and urinary bladder reconstruction. Because he could not be extubated and was in septic shock with hypotension, anuria, and worsening kidney function tests, antibiotic therapy was planned with meropenem, ciprofloxacin, colistin, and linezolid because of the extended spectrum beta-lactamase activity of *Acinetobacter baumannii* (colistin sensitive) and *Escherichia coli* (meropenem, imipenem, ciprofloxacin, and amikacin sensitive).

The patient's hypotension did not respond to dopamine and dobutamine therapy, a chest X-ray revealed pleural effusion, thoracentesis revealed fluid with characteristics of transudate, and a black-colored necrotic edematous lesion was present in the nasal area (Fig. 1).

Although the patient did not have a positive blood culture, ongoing local infection was present. Therefore, antimicrobial therapy including meropenem, colistin, teicoplanin, and caspofungin was reorganized to include meropenem, colistin, teicoplanin, and liposomal amphotericin B. Paranasal CT yielded increased density in the right maxillary sinus compatible with infection or hemorrhage, with increased subcutaneous nodular density suggesting infection in the left middle meatus. In the following hours the patient had cutaneous necrosis in the dorsal area necrosis in the nasal bone. The patient's disease progress was so rapid that mortality could not be prevented, 3 days after the skin findings occurred. Blood culture yielded *T. asahii* after minimum inhibitory concentration values were exceeded for that isolate at 4 µg/mL for fluconazole and 0.03 µg/mL for voriconazole. Postmortem study of tissues from the nose and conchae revealed widespread necrosis, karyorrhexis, and mixed inflammatory infiltrate along with septated fungal hyphae and spores (Fig. 2). Additionally, a group of nonseptated mucormycotic hyphae was also detected. However *T. asahii* was the only infectious agent isolated from the cultures of necropsy samples.

Discussion

The non-*Candida* yeast-*Trichosporon* species is an increasingly common pathogen in immunocompromised hosts. These species have been isolated from various types of

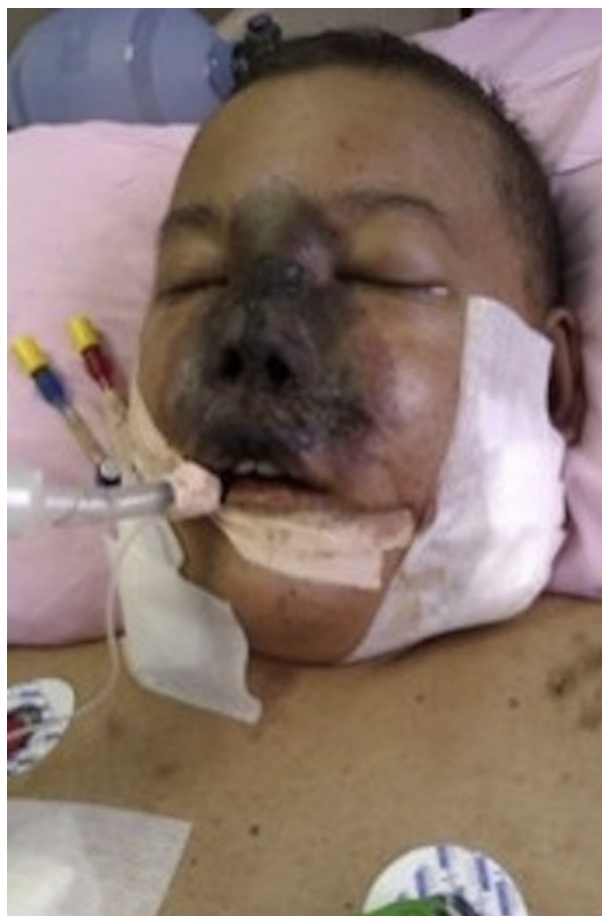

Figure 1. Necrotic lesion in the nasal area.

clinical specimens, including blood, skin biopsy, and urine specimens,²⁻⁴ and reported as colonization of the gastrointestinal tract, skin, mucosal surfaces and in addition to stool, central venous catheter, sputum, and hair.² *T. asahii* is the most frequent species involved in disseminated infections.^{5,6} Cutaneous involvement with papulonodular or pustular lesions, especially necrotic appearance, has been

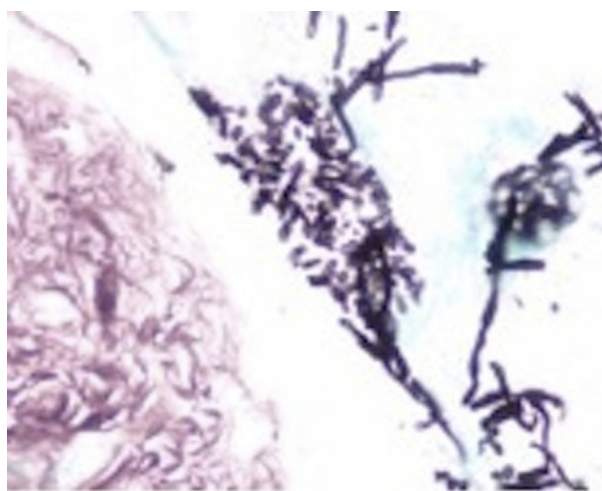


Figure 2. Fungal elements including several true hyphae and blastoconidia in samples of conchal lesion.

frequently observed and could be indicative of trichosporonosis. Biopsies of these skin lesions have revealed *Trichosporon* species in more than 75% of the cases, and are helpful to promptly confirm the etiology and initiate appropriate treatment.⁶ Papulonodular or pustular skin findings, which are frequently seen and described in the literature, were absent in our patient.

Early diagnosis of trichosporonosis remains a challenge, and the *Trichosporon* species are less susceptible to some empirical or prophylactic antifungal drugs such as caspofungin and amphotericin B.⁷ Amphotericin B has been shown to have a limited *in vitro* effect against *Trichosporon* species.⁵ Susceptibilities to antifungal agents are variable in the literature; *in vitro* activity does not always correlate with efficacy *in vivo*. Recently, new azoles have appeared as promising therapies for this infection. *In vitro* studies have shown that azoles, particularly voriconazole, were more potent than amphotericin B.⁸ In a recent study voriconazole and itraconazole were found to be the most active drugs *in vitro* against all the *Trichosporon* species tested, whereas caspofungin and amphotericin B demonstrated poor activity.⁹ In patients who cannot be treated with voriconazole because of its adverse effects, amphotericin B, flucytosine, fluconazole, and itraconazole might be alternative antifungal agents,¹⁰ although multidrug resistance to these agents leading to treatment failure has been reported.² It is reported that echinocandins have low activity against *Trichosporon* species and are not recommended for the treatment of trichosporonosis.^{11,12} To the best of our knowledge, 14 patients have been reported in the literature with invasive trichosporonosis during the use of echinocandins.¹³ Therefore, the risk of *Trichosporon* infection should not be overlooked in patients with risk factors and those receiving echinocandins empirically or prophylactically as did our patient.

Mucormycosis is a rare but highly invasive infection, which may manifest in different anatomic locations such as in paranasal sinuses, the rhinoorbital and rhinoorbitocerebral regions, pulmonary system, gastrointestinal tract, and cutaneous sites, and rarely, in disseminated form. The disease has a high mortality rate; however, better prognosis can be achieved with cutaneous infections, and mucormycosis was rarely seen in a disseminated form.¹⁴ In a report of 12 pediatric cases overall mortality was reported at 67%.¹⁵ Although mucormycosis was diagnosed in histologic nasal specimens, *T. asahii* was cultured from the nasal region, hemodialysis catheter, and peripherally but mortality could still be associated with coinfection of *T. asahii* together with mucormycosis in our patient. The first case report of the coinfection with mucormycosis and *Trichosporon* in the literature was published in 2006¹⁶; posaconazole together with a high dose of amphotericin B, aggressive surgical debridement and hyperbaric oxygen therapy resulted in cure of a disseminated fungal necrotizing fasciitis.

In the literature, breakthrough trichosporonosis has been reported during the administration of various antifungal agents, including amphotericin B, caspofungin, micafungin, and azoles.^{5,14,15} Unfortunately, our patient experienced rapid deterioration although he was treated with caspofungin and *Trichosporon* could only be cultured and shown in postmortem studies. Factors that enhance mucosal colonization and subsequent invasion of

Trichosporon species include broad-spectrum antibiotic treatment and breaks in mucosal barriers.^{3,11} Because our patient had renal function impairment, antifungal therapy was initiated with caspofungin. It is highly likely that combination therapy with drugs acting synergistically on different sites such as caspofungin and amphotericin B for trichosporonosis, as aspergillosis, may have better outcomes than fungicidal activity of antifungal agents when used alone.^{7–9} Unfortunately, the antifungal treatment in our case did not yield a successful outcome. However, therapy with liposomal amphotericin B was found to be effective in eradicating *T. asahii* from blood, and was also well tolerated and associated with resolution of fever in our patient. The mortality of our patient makes it clear that it is vital to keep in mind the possibility of trichosporonosis even under antifungal therapy especially echinocandins. In addition, early diagnosis together with initiation of rapid and appropriate therapy could be a life-saving process and assist in achieving a favorable outcome.

Conflicts of interest

All contributing authors declare no conflict of interest.

References

1. Thibeault R, Champagne M, de Repentigny L, Fournet JC, Tapiero B, Moghrabi A, et al. Fatal disseminated *Trichosporon asahii* infection in a child with acute lymphoblastic leukemia. *Can J Infect Dis Med Microbiol* 2008;19:203–5.
2. Wolf DG, Falk R, Hacham M, Theelen B, Boekhout T, Scorzetti G, et al. Multidrug-resistant *Trichosporon asahii* infection of nongranulocytopenic patients in three intensive care units. *J Clin Microbiol* 2001;39:4420–5.
3. Itoh T, Hosokawa H, Kohdera U, Toyazaki N, Asada Y. Disseminated infection with *Trichosporon asahii*. *Mycoses* 1996;39:195–9.
4. Mirza SH. Disseminated *Trichosporon beigelii* infection causing skin lesions in a renal transplant patient. *J Infect* 1993;27:67–70.
5. Walsh TJ, Melcher GP, Rinaldi MG, Lecciones J, McGough DA, Kelly P, et al. *Trichosporon beigelii*, an emerging pathogen resistant to amphotericin. *J Clin Microbiol* 1990;28:1616–22.
6. Fournier S, Pavageau W, Feuillhade M, Deplus S, Zagdanski AM, Verola O, et al. Use of voriconazole to successfully treat disseminated *Trichosporon asahii* infection in a patient with acute myeloid leukemia. *Eur J Microbiol Infect Dis* 2002;21:892–6.
7. Pfaller MA, Diekema DJ. Rare and emerging opportunistic fungal pathogens: concern for resistance beyond *Candida albicans* and *Aspergillus fumigatus*. *J Clin Microbiol* 2004;42:4419–31.
8. Paphitou NI, Ostrosky-Zeichner L, Paetznick VL, Rodriguez JR, Chen E, Rex JH. *In vitro* antifungal susceptibilities of *Trichosporon* species. *Antimicrob Agents Chemother* 2002;46:1144–6.
9. Guo LN, Xiao M, Kong F, Chen SC, Wang H, Sorrell TC, et al. Three-locus identification, genotyping, and antifungal susceptibilities of medically important *Trichosporon* species from China. *J Clin Microbiol* 2011;49:3805–11.
10. Girmenia C, Pagano L, Martino B, D'Antonio D, Fanci R, Specchia G, et al. Invasive infections caused by *Trichosporon* species and *Geotrichum capitatum* in patients with hematological malignancies: a retrospective multicenter study from

- Italy and review of the literature. *J Clin Microbiol* 2005;**43**: 1818–28.
11. Shao PL, Huang LM, Hsueh PR. Invasive fungal infection—diagnosis and antifungal treatment. *J Microbiol Immunol Infect* 2006;**39**:178–88.
 12. Walsh TJ, Groll A, Hiemenz J, Fleming R, Roilides E, Anaissie E. Infections due to emerging and uncommon medically important fungal pathogens. *Clin Microbiol Infect* 2004;**10**:48–66.
 13. Liao Y, Hartmann T, Zheng T, Yang RY, Ao JH, Wang WL. Breakthrough trichosporonosis in patients receiving echinocandins: case report and literature review. *Chin Med J (Engl)* 2012;**125**:2632–5.
 14. Goodman D, Pamer E, Jakubowski A, Morris C, Sepkowitz K. Breakthrough trichosporonosis in a bone marrow transplant recipient receiving caspofungin acetate. *Clin Infect Dis* 2002;**35**:35–6.
 15. Däbritz J, Attarbaschi A, Tintelnot K, Kollmar N, Kremens B, von Loewenich FD, et al. Mucormycosis in paediatric patients: demographics, risk factors and outcome of 12 contemporary cases. *Mycoses* 2011;**54**:785–8.
 16. De Decker K, Van Poucke S, Wojciechowski M, Ieven M, Colpaert C, Vogelaers D, et al. Successful use of posaconazole in a pediatric case of fungal necrotizing fasciitis. *Pediatr Crit Care Med* 2006;**7**:482–5.