

A Clinically Variant Fibrosis Syndrome in a Turkish Family Maps to the CFEOM1 Locus on Chromosome 12

Emin C. Sener, MD; Bjorn A. Lee, AB; Banu Turgut, MD; A. Nurten Akarsu, MD, PhD; Elizabeth C. Engle, MD

Objectives: To describe the phenotype of a Turkish family with variably expressed congenital fibrosis of the extraocular muscles (CFEOM), and to determine the genetic location of their disorder.

Methods: Participants were examined and had blood extracted for genetic analysis. The clinical features of the family's disorder were studied, and the disorder was tested for linkage to the 3 known CFEOM loci (CFEOM1, CFEOM2, and CFEOM3).

Results: Twenty-nine affected and 31 unaffected family members participated in the study. Eighteen affected individuals had congenital bilateral ptosis and restrictive infraductive (downward) ophthalmoplegia, consistent with the published descriptions of classic CFEOM families linked to the CFEOM1 locus. Eleven affected individuals, however, had eye(s) in a neutral primary position, residual upgaze, and/or absence of ptosis, thus de-

viating from previous descriptions of CFEOM1-linked families. Analysis of the autosomal dominant variably expressed disorder in this family revealed linkage to the CFEOM1 locus on chromosome 12 with a maximum lod score of 10.8 at *D12S85*.

Conclusions: This Turkish family segregates a variably expressed form of CFEOM that most closely resembles CFEOM3-linked CFEOM, but maps to the CFEOM1 locus.

Clinical Relevance: These data establish that there is much greater phenotypic heterogeneity at the CFEOM1 locus than previously reported, and this may blur our ability to distinguish the different CFEOM loci based solely on clinical presentation.

Arch Ophthalmol. 2000;118:1090-1097

THE SYNDROMES known as congenital fibroses of the extraocular muscles (CFEOM) are congenital oculomotor motility disorders that manifest as restrictive ophthalmoplegias with ptosis. Although these syndromes are thought to arise from dysfunction of part or all of the oculomotor nerve and/or the muscles that this nerve innervates, their molecular etiology remains unknown. Several inherited forms have been described, and 3 genetic loci (CFEOM1, CFEOM2, and CFEOM3) have been identified.¹⁻⁴

The classic form of CFEOM (classic CFEOM) is the most common of the CFEOM syndromes. Affected individuals have bilateral ptosis and bilateral restrictive ophthalmoplegia. The primary vertical position of each eye is fixed below the horizontal, typically by at least 10°. The secondary position of the hypotropic eye (exotropic, esotropic, or neutral) and the degree of residual horizontal movement within the lower quadrants (full to completely restricted) can vary within and between affected individuals, but none can bring ei-

ther eye above the horizontally neutral position. Genetic studies of multiple families with classic CFEOM have demonstrated linkage to the centromeric region of chromosome 12, and this locus is now referred to as CFEOM1.^{1,2} All families linked to the CFEOM1 locus have demonstrated full penetrance. There have been no reports of individuals with chromosome 12-linked CFEOM who did not have the classic CFEOM phenotype. There have been no reports of individuals whose eyes were in a neutral primary position, who could raise their eyes above the midline, or who had unilateral or absent ptosis.

A second CFEOM syndrome has been identified in 3 consanguineous Saudi Arabian families.³ Similar to individuals with classic CFEOM, these individuals have restrictive, bilateral external ophthalmoplegia and ptosis, with virtually absent voluntary eye movements. Studies have revealed, however, that these individuals vary both phenotypically and genotypically from individuals with classic CFEOM.³ The primary fixed position of each eye is in abduction with marked exo-

From the Department of Ophthalmology (Drs Sener and Turgut) and Child Health Institute (Dr Akarsu), Hacettepe University, Ankara, Turkey; Division of Genetics (Mr Lee and Dr Engle) and Department of Neurology (Dr Engle), Children's Hospital, Harvard Medical School, Boston, Mass.

PARTICIPANTS AND METHODS

CLINICAL STUDIES

Retrospective pedigree ascertainment was performed using the index case (**Figure 1**, IV:35) from the Hacettepe University Pediatric Ophthalmology and Strabismus Registry, Ankara, Turkey. Ophthalmologic examinations were performed and blood samples were obtained from all participants during a field visit by a team of physicians (E.C.S., B.T., and A.N.A.). Hacettepe University and Children's Hospital, Boston, Mass, approved this study. Informed consent was obtained from all adult participants and from parents or legal guardians of participating minors.

For each participant, the primary position of each globe was recorded with the head held straight (correcting for abnormal head position). Ductions and versions with cover test were analyzed and quantified in 6 diagnostic positions of gaze using a grading system of 0 (no movement) to 4 (full movement) in that field of action. Globe retraction and/or aberrant movements were recorded. An individual was diagnosed as having ptosis if the upper lid covered 2 mm or more of the iris. Ptosis was graded as mild if the upper lid covered the iris above the upper pupillary margin, moderate if it occluded up to half the pupil, and severe if it occluded more than half of the pupil. Levator function was measured from the upper lid margin while the patient attempted supraduction from the infraducted position without recruitment of the frontalis muscle. Visual acuity with the participant's existing correction was measured with a Snellen optotype chart held at 6 m, and non-cycloplegic refraction was obtained in individuals of decreased visual acuity when possible. Direct and indirect

pupillary reactions were recorded. Photographic and videographic documentation of each participant's ophthalmologic examination was obtained whenever possible.

MOLECULAR STUDIES

Blood samples were obtained from all participating family members and lymphocyte DNA was extracted according to standard procedures. Linkage studies were conducted using polymorphic DNA microsatellite markers from the CFEOM1,^{1,2} CFEOM2,³ and CFEOM3⁴ regions. The primer sequences for these polymorphisms are available from the Genome Data Base (<http://gdbwww.gdb.org>). Primers were purchased from Genosys Biotechnologies, Inc (<http://www.genosys.com>). Genotypes were determined by 30 cycles of polymerase chain reaction amplification of 10- μ L reaction volumes containing 40 to 60 ng of genomic DNA, 40 ng of each primer, 200- μ mol/L each of deoxyadenosine triphosphate, deoxythymidine triphosphate, deoxyguanosine triphosphate, and deoxycytidine triphosphate (dCTP), 0.037 MBq α -³²P dCTP (111 MBq mmol⁻¹), and 0.5 U *Taq* polymerase (Perkin Elmer). The polymerase chain reaction products were separated on 6% denaturing polyacrylamide sequencing gels, and the alleles were visualized by autoradiography.¹

For lod score calculations, an individual was scored as affected based on the consensus of the examining physicians. Lod scores were calculated using the Fastlink version 3.0 package of programs.⁵ Assumptions made were autosomal dominant inheritance, incomplete penetrance, 10 marker alleles of equal frequency, and a disease incidence of 1 in 1 million births, as described previously.^{3,4} Scores were calculated using penetrances of 90%, 95%, and 97%.

tropia, in contrast to the classic CFEOM phenotype, in which each eye is primarily fixed downward with marked hypotropia. Furthermore, unlike classic CFEOM, which is inherited in an autosomal dominant fashion, the disorder in these families is inherited as an autosomal recessive trait, and likely arose in this population from a founder mutation. Genetic linkage studies of these Saudi Arabian families have demonstrated linkage to chromosome 11q13, and this locus is referred to as CFEOM2.³

A third CFEOM syndrome has been identified in a large Canadian family.⁴ The disorder in this family is inherited as an autosomal dominant trait with probable incomplete penetrance. The phenotype of affected family members is much more variable than that reported at either the CFEOM1 or CFEOM2 locus. Severely affected family members have bilateral ptosis and restrictive external ophthalmoplegia with the eyes fixed in an infraducted and exotropic position, not unlike a subset of individuals with classic CFEOM. Mildly affected family members, however, have normally positioned eyes, only minimal limitation of vertical gaze, and unilateral or absent ptosis, features not reported at either the CFEOM1 or CFEOM2 locus. Genetic analysis of this family revealed linkage to chromosome 16q24.2-q24.3, and this locus is referred to as CFEOM3.⁴

We present the clinical findings and genetic evaluation of a Turkish family with autosomal dominant

CFEOM. This evaluation demonstrates that the phenotype of families whose disease genes map to the CFEOM1 and CFEOM3 loci can overlap to an even greater extent than previously reported. The phenotype in this family is markedly variable in its expression and overlaps with both classic CFEOM1 families and the nonclassic CFEOM3 family, but more closely resembles the CFEOM3-linked family. Genetic linkage analysis, however, reveals that this family's disease gene is linked to the CFEOM1 locus. These findings establish that there is greater phenotypic heterogeneity at the CFEOM1 locus than previously reported, and suggests that phenotype alone is not sufficient to distinguish among the 3 genotypically distinct CFEOM syndromes.

RESULTS

CLINICAL FINDINGS

The 5-generation family, referred to as pedigree BW, lives in Bayat County, Ankara, Turkey. The pedigree consists of 94 individuals, 84 of whom were living at the time of the study. Sixty individuals (29 clinically affected family members, 22 clinically unaffected family members, and 9 spouses) participated in the study (**Figure 1**), and all underwent clinical examination and donated a blood sample for genetic analysis. Congenital fibrosis of the ex-

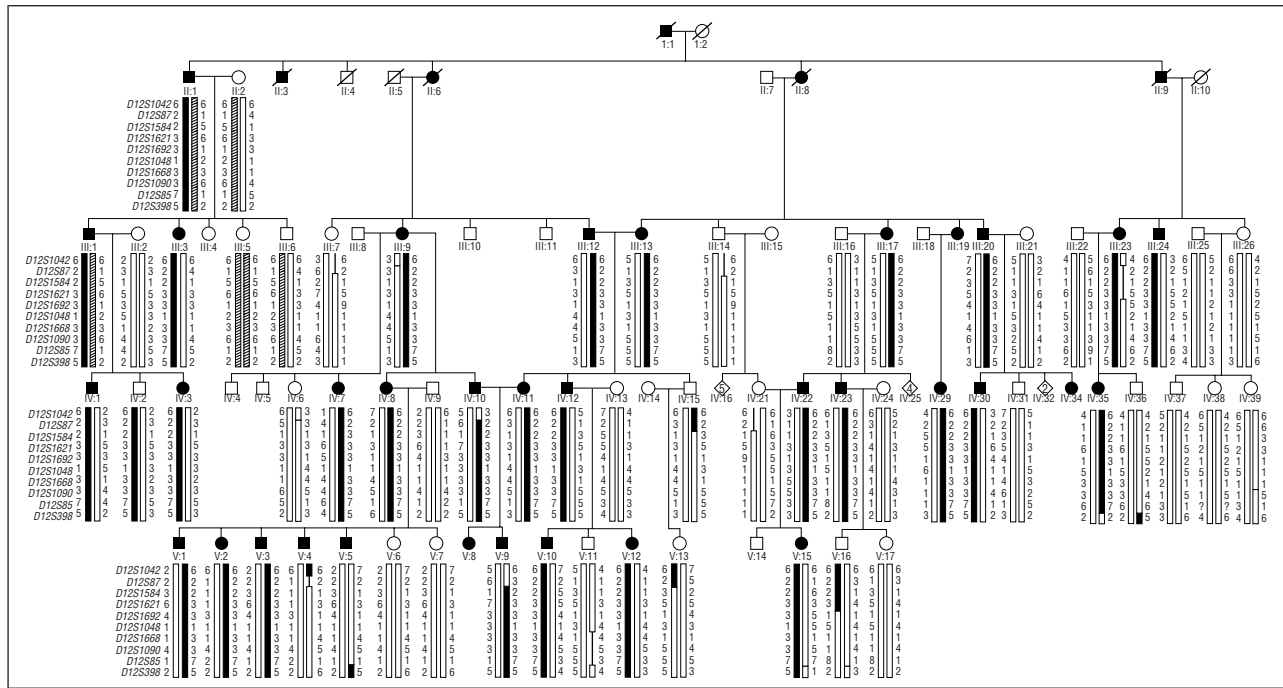


Figure 1. Pedigree diagram and haplotype analysis of the Turkish congenital fibrosis of the extraocular muscles (CFEOM) family BW. Black symbols denote individuals clinically affected with CFEOM. Diagonal slash denotes that the individual is deceased. Genotyping data and schematic haplotype bars for CFEOM1 chromosome 12 centromeric markers are shown below the symbol for each individual who participated in the study and indicate regions of recombination. Black bars denote the disease-associated region. Horizontally hatched bars highlight the inheritance of specific non-disease-associated haplotypes.

traocular muscles is inherited in pedigree BW as an autosomal dominant trait with extreme variability in its expressivity. There are 3 recognized consanguineous loops in the pedigree, and 2 of these are marriages between 2 affected individuals (III:12 and III:13, IV:10 and IV:11). These marriages produced 5 offspring of whom 4 are affected with CFEOM. No phenotypic distinctions were made between these 4 cases.

The phenotypic expression of the disorder in 18 of the affected participants is consistent with that described for classic CFEOM.^{2,6} These individuals have bilateral ptosis and restrictive external ophthalmoplegia with their eyes fixed in an infraducted position. They have no upgaze and display variable degrees of restriction in the other diagnostic positions of gaze. All have an abnormal head position with a chin-up posture. The majority have aberrant convergence that is most pronounced on attempted upgaze and aberrant divergence that is most pronounced on attempted downgaze. Globe retraction and other abnormal movements were not observed. This phenotype is indistinguishable from that described for CFEOM1-linked classic CFEOM, and is diagrammed in **Figure 2**, group 1, and demonstrated in photographs of individual III:24 (**Figure 3**).

The phenotypic expression of CFEOM in the remaining 11 affected family members, however, is not consistent with that reported for classic CFEOM, and is indistinguishable from that described in moderately and mildly affected members of the CFEOM3 family. Individual findings are described below, diagrammed in Figure 2, group 2, and documented in photographs of individuals V:2 (**Figure 4**) and III:20 (**Figure 5**). These individuals differ from previously described individuals with CFEOM1-linked classic CFEOM in (1) the fixed position of their eyes,

(2) the ability to elevate their eyes, and/or (3) the absence of ptosis. All 11 individuals have at least 2 of these 3 atypical features. First, both eyes of individuals III:1, III:20, and V:12, and 1 eye of individuals II:1, III:3, III:13, III:23, IV:3, and V:2 are in a neutral, rather than an infraducted, primary position. Similarly, the eyes of individual III:9 are in the horizontal midline but are bilaterally esotropic. Second, 7 of the 11 individuals can elevate their eyes above the midline, although none have full, unrestricted upgaze. Individuals II:1, III:20, and III:23 have some degree of bilateral elevation, and individuals IV:3, IV:35, V:2, and V:12 have some degree of unilateral elevation. Although family members reported individual III:20 to be unaffected, our field examination and review of videotaped eye movements confirmed that he has a mild bilateral restriction of upgaze, with normal bilateral levator functions of 12 mm (Figure 5). Third, 3 individuals (III:20, III:23, and V:12) have absence of ptosis, and 7 individuals have unilateral ptosis (4 right-sided and 3 left-sided). Therefore, of the 11 individuals with atypical findings, only 1 (IV:35) has bilateral infraduction, only 4 have absent upgaze (III:1, III:3, III:9, and III:13), and only 1 (II:1) has bilateral ptosis.

In addition to the ocular-motility findings described above, complete restriction of abduction, resembling a sixth nerve palsy, was found unilaterally in 2 typically (IV:8 and IV:29) and 3 atypically (II:1, III:13, and IV:35) affected individuals, and bilaterally in 1 atypically affected individual (III:9). The degree of ptosis, levator function, visual acuity, and refraction (when available) are presented in Figure 2. Direct and indirect pupillary reactions were normal in all individuals.

Observations during strabismus surgery in individuals III:23 and IV:35 confirm the restrictive nature of the oph-

| Right Eye | | Left Eye | | Ptosis | | Levator Function | | Chin-up | VA | Refraction |
|---------------------------------------------------------------------------|----|----------|----------|----------|------|------------------|-------------|---------|----|------------------------------|
| SR | IO | IO | SR | Right | Left | Chin-up | (Corrected) | | | |
| LR | MR | MR | LR | | | | | | | |
| IR | SO | SO | IR | | | | | | | |
| Group 1: Typical Severe "Classic" CFEOM | | | | | | | | | | |
| III:12, 17, 24; IV:1, 7, 8, 10, 11, 12, 22, 23, 29, 30; V:1, 3, 9, 10, 15 | | | | | | | | | | |
| | | | | + | | + | | + | | |
| Group 2: Atypical CFEOM | | | | | | | | | | |
| 3 | | | Severe | Severe | + | OD:20/200 | OD:20/200 | | | Senile Cataracts |
| III:1 | | | 0 mm | 0 mm | | | | | | |
| 13 | | | Moderate | - | - | OD:20/30 | OD:20/30 | | | -1.0 |
| III:13 | | | 7 mm | 13 mm | | | | | | -1.0 |
| 15 | | | - | Moderate | + | OD:20/20 | OD:20/40 | | | -0.50 |
| III:15 | | | 15 mm | 7 mm | | | | | | -0.50 |
| 24 | | | Severe | - | - | CF | CF | | | Senile Cataracts and Leukoma |
| III:24 | | | 2 mm | 12 mm | | | | | | |
| 21 | | | - | Severe | + | OD:20/80 | OD:20/60 | | | +1.5+0.50x90 |
| III:21 | | | 14 mm | 6 mm | | | | | | +2.0 |
| 33 | | | - | - | - | OD:20/20 | OD:20/20 | | | Emmetropia |
| III:20 | | | 12 mm | 12 mm | | | | | | Emmetropia |
| 36 | | | - | - | - | OD:20/20 | OD:20/20 | | | +1.0 |
| III:23 | | | 13 mm | 10 mm | | | | | | Emmetropia |
| 42 | | | Moderate | - | - | | | | | |
| IV:3 | | | 4 mm | 14 mm | | | | | | |
| 90 | | | - | Mild | + | OD:20/30 | OD:20/60 | | | +4.25 |
| IV:35 | | | 12 mm | 7 mm | | | | | | +3.25+2.0x90 |
| 80 | | | - | Severe | - | OD:20/20 | OD:20/230 | | | Emmetropia |
| V:2 | | | 15 mm | 0 mm | | | | | | -1.50 |
| 76 | | | - | - | + | OD:20/20 | OD:20/20 | | | Emmetropia |
| V:16 | | | 15 mm | 15 mm | | | | | | Emmetropia |

Figure 2. Clinical ocular findings in members of congenital fibrosis of the extraocular muscles (CFEOM) family BW. Figure shows right and left eye diagrams of muscle range of movement and pupillary position. Black dot denotes the pupillary position with the head held straight. IR indicates inferior rectus; SR, superior rectus; LR, lateral rectus; MR, medial rectus; SO, superior oblique; IO, inferior oblique; VA, visual acuity; CF, counting fingers; 4, full range of movement; 3, marked restriction; 2, moderate restriction; 1, mild restriction; and 0, no movement. Movements are measured from each eye's primary resting position. Group 1 summarizes the findings from individuals with typical "classic" CFEOM, and group 2 summarizes the findings from individuals with atypical "nonclassic" CFEOM.

thalmoplegia in this family. Both of these individuals had severely restricted motility upon traction testing under general anesthesia. Individual IV:35, the proband for this pedigree, presented with 8 prism diopters of esotropia, 40 prism diopters of hypotropia, mild ptosis, and levator function of 7 mm in her left eye. Her right eye was also hypotropic, but only mildly restricted in upgaze and had normal levator function of 12 mm. Four years prior she underwent a 4-mm left inferior rectus recession. On follow-up evaluation her limited motility was unchanged. Her left eye, however, showed an improvement, with only 25 prism diopter hypotropia. Individual III:23 presented with 14 prism diopters of esotropia and 25 prism diopters of hypotropia

in the left eye. She recently underwent a 4.5-mm left inferior rectus and a 5.5-mm left medial rectus recession. On follow-up evaluation she was left with only a 16 prism diopter left hypotropia.

Of note, individual IV:37 was born with severe unilateral left-sided ptosis and no levator function. In addition, he has mild dysmorphic features including a high forehead, small upturned nose with anteverted nostrils, and a long, wide philtrum. His ocular motility, however, is completely normal bilaterally. Since CFEOM is defined as a restrictive deficit of ocular motility, he did not meet clinical criteria and was scored as unaffected. His mother (III:26) is also clinically unaffected.

LINKAGE TO THE CFEOM1 LOCUS ON CHROMOSOME 12

The CFEOM1, CFEOM2, and CFEOM3 loci were analyzed for linkage to the family's disorder. Linkage to the CFEOM2 and CFEOM3 loci was excluded at 97% penetrance as follows. At the 2.5-centimorgan (cM) region surrounding the CFEOM2 locus on chromosome 11q13,² a lod score of less than -2.0 (indicating an odds ratio of 100:1 against linkage) was obtained at marker *D11S1369* with a recombination frequency (θ) of 0.06. At the 5.6-cM critical region surrounding the CFEOM3 locus near the telomere of chromosome 16q,⁴ lod scores of less than -2.0 were obtained at markers *D16S671* and *D16S498* with a θ of 0.20 and 0.12, respectively.

Analysis of chromosome 12 markers revealed linkage to the 3-cM CFEOM1 locus, which falls between markers *D12S1584* (AFM136xf6) and *D12S1668* (AFMb320wd9).² The critical region for the disease gene in family BW is defined by a recombination event in affected individual V:9 at marker *D12S87* on the short arm of chromosome 12, and by a recombination event in affected individual IV:35 at marker *D12S398* on the long arm of chromosome 12 (Figure 1 and **Table**). *D12S1584*, *D12S1621*, *D12S1692*, *D12S1048*, *D12S1668*, *D12S1090*, and *D12S85* cosegregate with the disease gene without recombination events in any of the affected individuals; the affected haplotype for these markers is 2-3-3-1-3-3-7 (Figure 1). All of these markers have maximum lod scores greater than 3.0 (Table) when calculated at penetrances of 90%, 95%, and 97%, and a maximum lod score of 10.8 was obtained at the most informative marker, *D12S85*, at penetrances of both 90% and 97%. Clinically unaffected individuals IV:15, IV:36, and V:16 inherited a portion of the disease haplotype. Because it is unknown if they are unaffected or are nonpenetrant carriers of the mutation, these recombination data cannot be used to narrow the critical region. Thus, the critical region for the disease gene in this family encompasses the entire CFEOM1 locus.

The penetrance of the CFEOM mutation in this family is calculated to be 97%. Twenty-nine of 30 individuals carrying the disease-associated haplotype are clinically affected. In calculating penetrance, 2 individuals are noteworthy. Individual IV:2 is unaffected based on results of clinical examination but inherited the entire disease haplotype from his affected father, III:1, and is assumed to be a nonpenetrant carrier of the disease

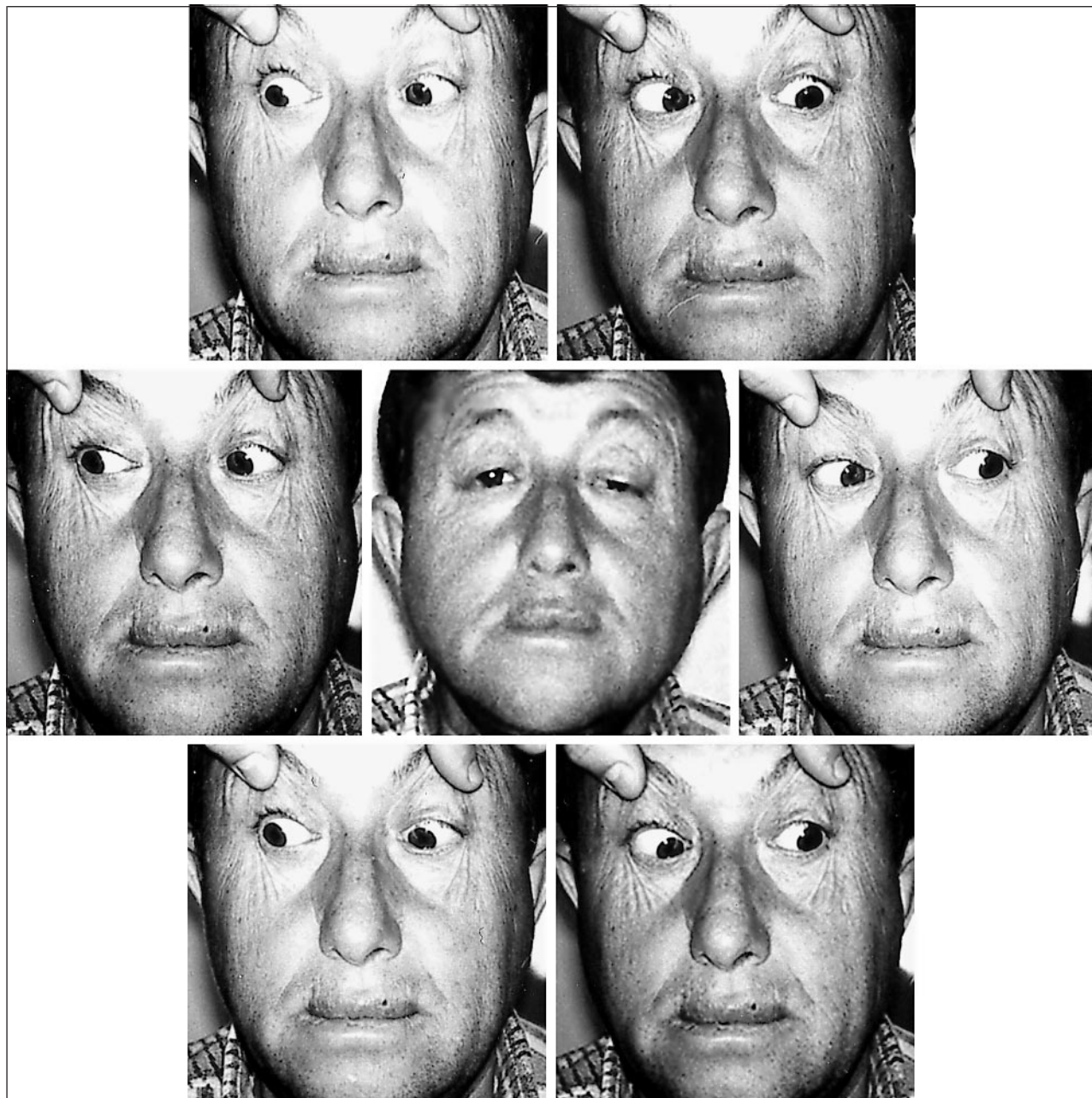

Figure 3. Photographs of individual III:24, who demonstrates the typical features of “classic” congenital fibrosis of the extraocular muscles (CFEOM). The photographs are taken with the individual in primary gaze (center), and attempting to look in 6 diagnostic positions of gaze (in clockwise order from top right: up and left, left, down and left, down and right, right, up and right). Note bilateral ptosis, globe infraduction, and inability to raise either eye to a neutral position.

mutation. Individual IV:37, described clinically above as not meeting diagnostic criteria, exhibits linkage data consistent with our clinical interpretation.

Of note, the data do not permit one to determine the effect of the homozygous inheritance of this mutation. First, none of the affected offspring of the consanguineous marriages who participated in the study (IV:11, IV:12, and V:9) are homozygous for the disease-associated haplotype. Second, neither of the mothers of these offspring (III:13 and IV:11) has had miscarriage or fetal loss, which could be increased in incidence if homozygous inheritance of the putative disease gene were fatal.

COMMENT

Our data establish that the CFEOM gene segregating in pedigree BW is linked to the chromosome 12 CFEOM1 locus. Consistent with this genetic finding, severely affected members of this family appear to be clinically indistinguishable from affected members of families with classic CFEOM; they have bilateral ptosis and restrictive ophthalmoplegia, and their eyes are infraducted with or without secondary esotropia or exotropia. As a group, the phenotype in these severely affected individuals is not consistent with the phenotype described for CFEOM2 or CFEOM3; in these disorders all severely affected in-

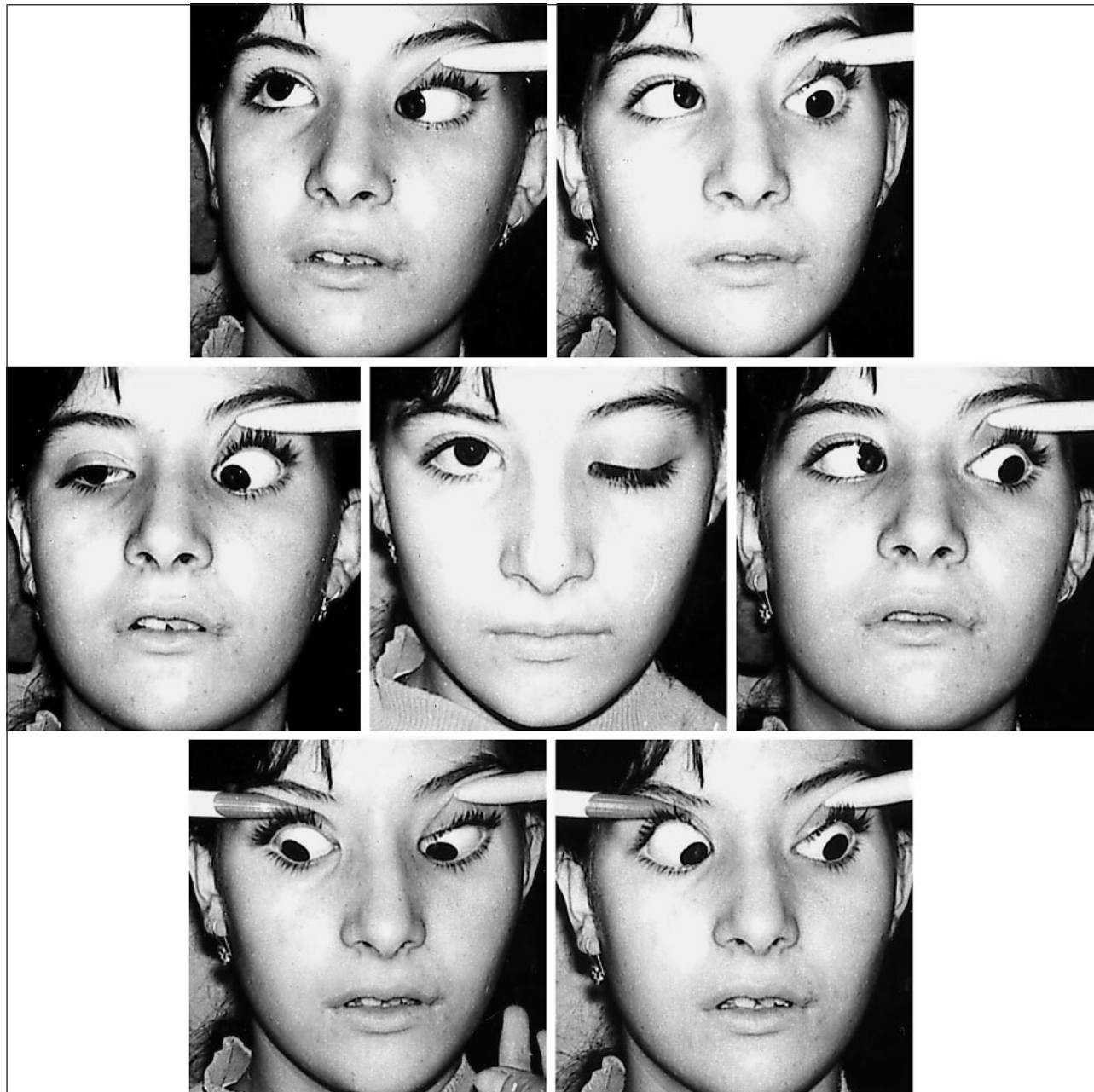


Figure 4. Photographs of individual V:2, showing variation from the features of “classic” congenital fibrosis of the extraocular muscles (CFEOM). The photographs are taken as described for Figure 3. Note that the young girl’s left eye is infraducted, does not elevate to neutral, and has significant ptosis (consistent with classic CFEOM). In contrast, her right eye is in neutral position at rest, elevates above the midline, and does not have ptosis (consistent with findings at the CFEOM3 locus).

dividuals have primary or secondary exotropia. Inconsistent with this genetic finding, however, are the phenotypes of the 11 atypically affected members. Their phenotypes differ from the classic CFEOM phenotype by having 2 or more of the following findings: (1) one or both eyes are in a neutral rather than an infraducted primary position, (2) one or both eyes can be raised above the midline with only moderate or mild restriction of upgaze, and/or (3) ptosis is unilateral or completely absent. Unlike the severely affected members, the phenotype of this second group of family members is indistinguishable from mildly and moderately affected members of the CFEOM3 family.⁴ Thus, pedigree BW establishes that there is greater phenotypic heterogeneity

at the CFEOM1 locus than previously reported, and suggests that phenotype alone may not be sufficient to distinguish between CFEOM1 and CFEOM3.

The mutation in this family appears to exhibit reduced penetrance and marked variability in its clinical expression. Individual IV:2, who is clinically unaffected, carries the complete disease-associated haplotype, which he inherited from his affected father. This is the first report of such an individual in a CFEOM1-linked family. Unfortunately, although there are family members who are minimally affected and have severely affected offspring, there are no skipped generations to definitively establish reduced penetrance. Such marked variability in clinical expression has also not been re-

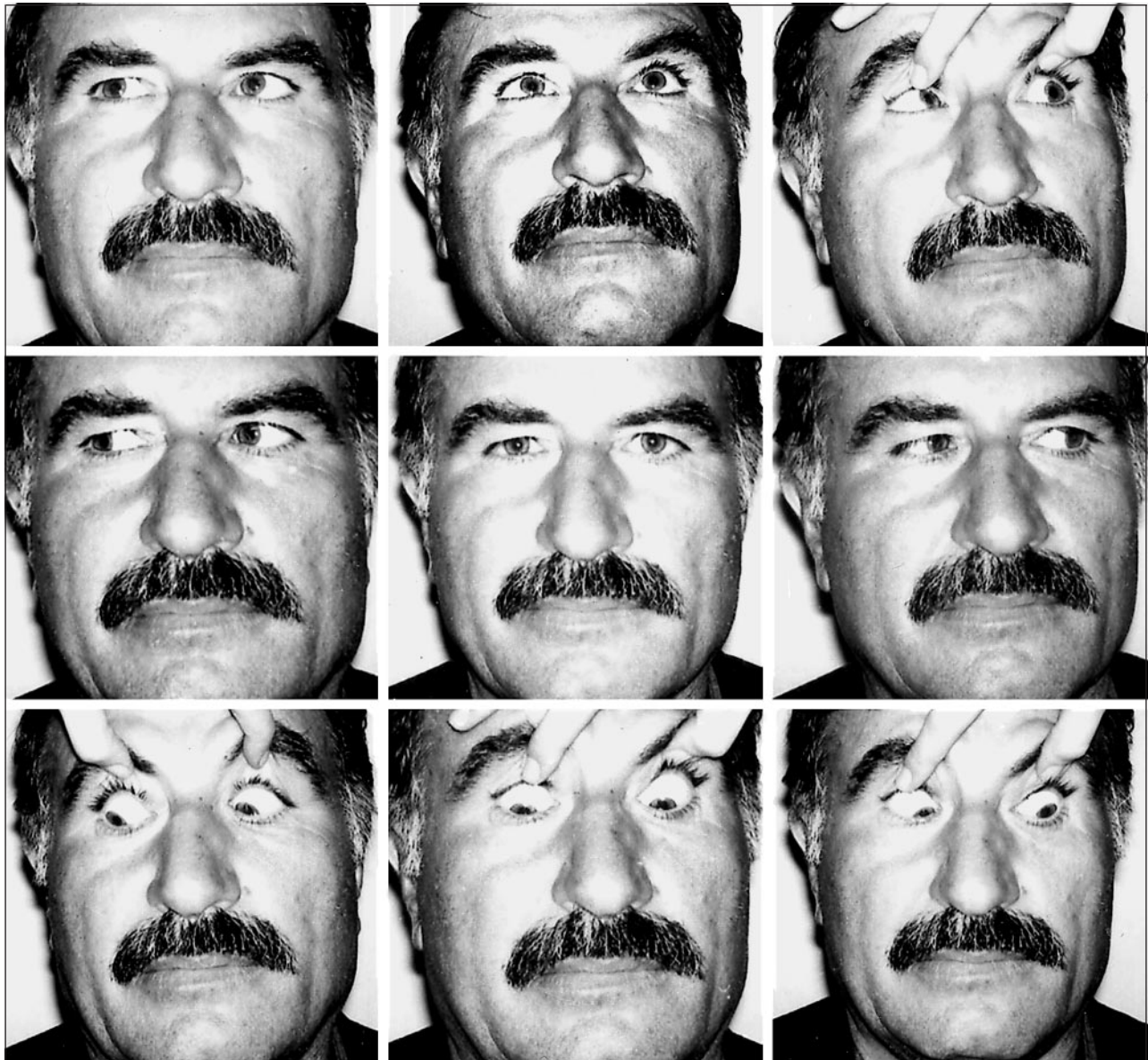


Figure 5. Photographs of individual III:20, whose son (IV:30) inherited “classic” congenital fibrosis of the extraocular muscles (CFEOM), but who demonstrates minimal abnormalities of ocular motility (consistent with findings at the CFEOM3 locus). The photographs are taken with the individual in primary gaze (center), and attempting to look in 8 diagnostic positions of gaze (in clockwise order from top right: up and left, left, down and left, down, down and right, right, up and right, and up). Note the neutral position of the eyes at rest, the minimal restriction of upgaze, and the absence of ptosis.

ported previously at the CFEOM1 locus. Prior to this family study, we hypothesized that the CFEOM gene in families with members who have unilateral affection or only mild motility defects would likely map to the CFEOM3, and not the CFEOM1, locus.⁴ Family BW, therefore, demonstrates that a variable phenotype can occur within the same family as the result of a CFEOM1 mutation and that the mutation may have incomplete penetrance. Although the frequency of this second CFEOM1 phenotype with variable expressivity and reduced penetrance is not known, it is likely not to be isolated to only family BW, as there are several clinically similar published pedigrees⁷⁻¹⁰ that could also map to the CFEOM1 locus. In addition, we have recently studied a CFEOM family whose linkage analysis establishes genetic heterogeneity for autosomal recessive CFEOM and suggests that a second recessive locus may be allelic to CFEOM1, further sup-

porting the concept of phenotypic heterogeneity at the CFEOM1 locus.¹¹ Therefore, the current trend suggests that phenotype alone will not permit definitive distinction between the various CFEOM syndromes, and that appropriate diagnosis and counseling of individuals and families with CFEOM will depend on the combination of clinical and genetic evaluations.

The neuropathologic mechanisms underlying the ocular-motility defect in family BW are not known. Post-mortem neuropathologic examination of an affected individual from a classic CFEOM1-linked family, however, demonstrated an absence of the superior branch of the oculomotor nerve and its corresponding subnuclei in the midbrain, and marked abnormalities of the superior rectus and levator palpebrae superioris muscles that this branch normally innervates.⁶ The phenotype in family BW suggests a similar anatomic defect affecting the

Lod Scores of CFEOM1 (Congenital Fibrosis of the Extraocular Muscles) Markers in Family BW

| Locus | Lod Score at Θ | | | | | | | Zmax* | Θ max† |
|--------------|-----------------------|------|------|-----|-----|-----|-----|-------|---------------|
| | 0.0 | 0.01 | 0.05 | 0.1 | 0.2 | 0.3 | 0.4 | | |
| D12S1042 | -3.7‡ | 2.0 | 3.0 | 3.2 | 2.8 | 2.1 | 1.1 | 3.17 | 0.105 |
| D12S87 | -6.5 | 0.6 | 2.1 | 2.4 | 2.1 | 1.4 | 0.6 | 2.43 | 0.115 |
| D12S1584 | 8.2 | 8.3 | 8.2 | 7.7 | 6.0 | 4.0 | 1.5 | 8.30 | 0.025 |
| D12S1621 | 2.5 | 2.8 | 3.1 | 3.1 | 2.6 | 1.6 | 0.6 | 3.17 | 0.071 |
| D12S1692 | 9.6 | 9.5 | 9.0 | 8.1 | 6.0 | 3.7 | 1.2 | 9.61 | 0.001 |
| D12S1048 | 5.2 | 5.2 | 5.1 | 4.7 | 3.6 | 2.3 | 1.0 | 5.20 | 0.008 |
| D12S1668 | 9.4 | 9.2 | 8.5 | 7.6 | 5.6 | 3.4 | 1.2 | 9.34 | 0.001 |
| D12S1090 | 10.7 | 10.7 | 10.1 | 9.2 | 7.0 | 4.5 | 1.8 | 10.73 | 0.001 |
| D12S85 | 10.8 | 10.7 | 10.0 | 7.2 | 7.0 | 4.6 | 1.9 | 10.78 | 0.001 |
| D12S3910.738 | -2.6 | 0.1 | 2.6 | 3.4 | 3.3 | 2.5 | 1.2 | 3.51 | 0.142 |

*Maximum likelihood estimate of the lod score.

†Maximum likelihood estimate of Θ .

‡Lod score calculated on the assumption of 97% penetrance.

superior more than the inferior division of the oculomotor nerve and its corresponding subnuclei. Some family members, however, have superior rectus dysfunction in the absence of levator palpebrae superioris dysfunction and vice versa, suggesting that, unlike classic CFEOM, in some family members the individual subnuclei/nerves within the superior branch of the oculomotor nerve may be selectively targeted.

Similar to the findings in families with classic CFEOM, dysfunction of the superior rectus and levator palpebrae superioris muscles alone does not account for all of the ocular-motility defects in family BW. We cannot determine from the motility examinations, however, if these defects result from abnormal innervation and/or from mechanical restriction secondary to muscle contracture with or without fibrosis. Affected family members have positive forced ductions and some demonstrate aberrant ocular movements. Most frequent is the finding of convergent motion in attempted supraversion and divergent motion in attempted infraversion that creates an A-pattern deviation. This is similar to reports of classic CFEOM individuals who often demonstrate abnormally directed eye movements, including synergistic convergence and divergence on attempted vertical gaze,^{6,12,13} and could result from aberrant innervation or from failure of contracted inferior rectus fibers to relax. One individual has unilateral absence of horizontal movements, and several individuals have unilateral absence of abduction. This horizontal restriction could result from primary dysfunction of the abducens nerve in addition to the oculomotor nerve, from aberrant innervation of the lateral recti muscles, and/or from secondary contractures.

The phenotypic variation at the CFEOM1 locus found in family BW could theoretically result from one of several mechanisms. Most likely, the family has a unique mutation in the CFEOM1 gene that results in a variant phenotype. Less likely, there could be a second CFEOM gene that maps within the CFEOM1 critical region and it is this gene, not the CFEOM1 gene, that is mutated in this family. It is also possible that the variable expressivity results from the effects of a distant gene that modifies the classic CFEOM phenotype. Once the CFEOM1

gene is identified, it will be possible to determine if it is mutated in this family. Uncovering the molecular basis of the phenotypic variation in family BW should lead to a greater understanding of the function of the CFEOM1 gene in the development of the oculomotor axis.

Accepted for publication January 4, 2000.

This study was supported by grants K11-EY0336 and R01-EY12498 from the National Institutes of Health, Bethesda, Md (Dr Engle).

We thank the family members for their participation.

Reprints: Elizabeth C. Engle, MD, Division of Genetics, Enders 5, The Children's Hospital, 300 Longwood Ave, Boston, MA 02115 (e-mail: engle@rascal.med.harvard.edu).

REFERENCES

- Engle EC, Kunkel LM, Specht LA, Beggs AH. Mapping a gene for congenital fibrosis of the extraocular muscles to the centromeric region of chromosome 12. *Nat Genet.* 1994;7:69-73.
- Engle EC, Marondel I, Houtman WA, et al. Congenital fibrosis of the extraocular muscles (autosomal dominant congenital external ophthalmoplegia): genetic homogeneity, linkage refinement, and physical mapping on chromosome 12. *Am J Hum Genet.* 1995;57:1086-1094.
- Wang S, Zwaan J, Mullaney P, et al. Congenital fibrosis of the extraocular muscles type 2 (CFEOM2), an inherited exotropic strabismus fixus, maps to distal 11q13. *Am J Hum Genet.* 1998;63:517-525.
- Doherty E, Macy M, Wang S, et al. CFEOM3: a new extraocular congenital fibrosis syndrome that maps to 16q24.2-q24.3. *Invest Ophthalmol Vis Sci.* 1999;40:1687-1694.
- Cottingham RW Jr, Idury RM, Schäffer AA. Faster sequential genetic linkage computations. *Am J Hum Genet.* 1993;53:252-263.
- Engle EC, Goumernov B, McKeown CA, et al. Oculomotor nerve and muscle abnormalities in congenital fibrosis of the extraocular muscles. *Ann Neurol.* 1997;41:314-325.
- Hiatt RL, Halle AA. General fibrosis syndrome. *Ann Ophthalmol.* 1983;15:1103-1109.
- Roggenkamper P. General fibrosis syndrome. In: Nemet P, Weiss S, eds. *Acta Strabologica, Proceedings of the International Symposium on Strabismus and Amblyopia; Tel Aviv, Israel.* 1985:241-246.
- Singh V, Sinha S. Familial involvement in congenital fibrosis syndrome, a rare association with myopia. *Ind J Ophthalmol.* 1993;41:29-32.
- Gillies W, Harris A, Brooks A, Rivers CA, Wolfe R. Congenital fibrosis of the vertically acting extraocular muscles: a new group of dominantly inherited ocular fibrosis with radiologic findings. *Ophthalmology.* 1995;102:607-612.
- Traboulsi E, Lee B, Mousawi A, Khamis A, Engle E. Evidence of genetic heterogeneity in autosomal recessive congenital fibrosis of the extraocular muscles (CFEOM). *Am J Ophthalmol.* In press.
- Brodsky MC, Pollock SC, Buckley EG. Neural misdirection in congenital ocular fibrosis syndrome: implications and pathogenesis [see comments]. *J Pediatr Ophthalmol Strabismus.* 1989;26:159-161.
- Rumph M. Fibrose du muscle droit inferieur, anomalies d'insertions et aplasies musculaires, une cause rare de troubles hereditaires non progressifs et congenitaux de la motilite oculaire. *Ann Oculistique.* 1974;207:831-829.